


# Clinical decision about asymptomatic mandibular third molars. Comparative study: Portugal vs. Spain



Alves-Pereira, D\*; Pereira-Silva, D; Amaral J; Valmaseda-Castellón E

Dentistry School, Coimbra University, Portugal  
Dentistry School, Barcelona University, Spain



## Introduction

It is estimated that about 1 and 5 million third molar extractions are performed each year in the UK and USA, respectively. Despite the existence of defined indications and contraindications for the extraction of these teeth, there is some controversia about the treatment when the third molar is asymptomatic, even in literature.

The National Institute of Clinical Excellence (NICE) discourages the prophylactic extraction of the third molar. However the American Association of Oral and Maxillofacial Surgeons (AAOMS) includes the prophylactic extraction among the indications.

Scientific evidence is scarce and frequently misinterpreted. Besides, there are few studies documenting which factors should be considered when facing an mandibular third molar (3M) extraction.

## Hypothesis

Analyse the indications regarding the extraction of asymptomatic mandibular 3M in a group of experienced Portuguese and Spanish dentists.

## Subjects and Methods

*Epidemiological observational cross-sectional study*

Clinical cases randomly selected through email to all Portuguese and Spanish dentists and maxillofacial surgeons.

Online questionnaire <http://surveygizmo.com>:

**First part:** practitioner's personal and clinical information

**Second part:** presentation of 29 mandibular 3M, with panoramic radiography and clinical information.

For each 3M presented and considering an ideal treatment plan performed in a healthy and cooperative patient, the practitioner should indicate:

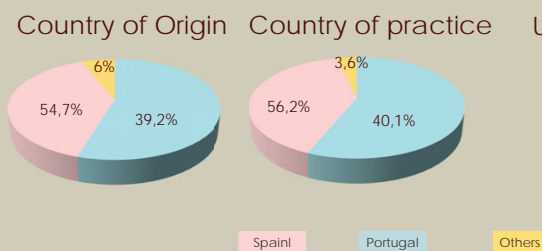
- ✓ His recommendation wether to extract or not extract
- ✓ Justification of his decision among a list of options
- ✓ Identification the degree of difficulty of the extraction according to Lickert scale.

The clinical cases selection obeyed to a similar distribution regarding the teeth position, inclination and degree of inclusion, as well as patient's gender and age.

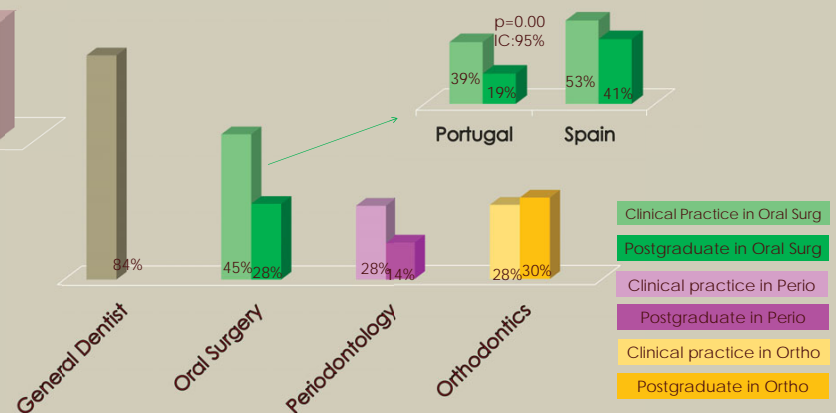
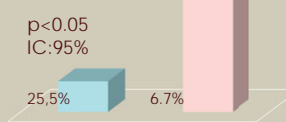
The results were statistically analysed using the IBM SPSS 20 (IBM Corp.,New York, EEUU).

## Results

411 Dentists  
229 ♀  
182 ♂



University Professor



Asymptomatic mandibular third molars extraction		
Clinicians	Main indications	Main contraindications
Portuguese	Pericoronaritis Risk of caries in 3M Risk of caries in 2M Resorption of the 2M Periodontal disease of the 2M Mandibular incisor crowding No function	Risk of mandibular fracture Patient's age Risk of 2M damage during the surgery Capacity of 3M eruption
Spanish	Pericoronaritis Risk of caries on the 2M No funtion	Risk of inferior alveolar nerve damage Agressive surgery No indication for extration

- Average year of graduation: Portuguese - 2001+/-9 ; Spanish - 2000+/-10
- Higher degree of difficulty of the extractions with deeper inclusions and less MD space available
- In 93% of the cases, Spanish give the extractions a higher score in terms of difficulty
- Degree of difficulty is lower among those with more clinical experience (p<0.05; CI 95%)
- 59.3% of the practicians choose not to proceed with the extraction when facing an asymptomatic 3M
- Portuguese dentists are those who tend to extract these teeth more often

## Conclusions

- ✓ The decision to remove mandibular third molar is based more upon Individual clinician factors rather than on category of practitioner or country of origin or practice.
- ✓ Postgraduation and daily oral surgery clinical practice increases knowledge and surgical ability leading to a wiser decision when facing an asymptomatic 3M.
- ✓ experience rises confidence and surgical ability, leading to a lower difficulty degree evaluation of the extraction
- ✓ Clinical decision when facing asymptomatic mandibular third molar is related to dentists academic education and surgical experience.
- ✓ There is a need for further studies to define indications of asymptomatic third molar extractions.

## Clinical outcomes

The definition of updated guide lines would allow diagnosis criteria standardisation and appropriate decisions among asymptomatic third molars.

## References

1-Boughner JC. Maintaining perspective on third molar extraction. J Can Dent Assoc 2013;79:106-107. 2- Phillips C, White RP. How predictable is the position of third molars over the time? J Oral Maxillofac Surg 2012;70:11-14. 3- American Association of Oral and Maxillofacial Surgeons. White paper on third molar data. March 2007. 4-Singh H, Lee K, Ayoub AF. Management of asymptomatic impacted wisdom teeth: A multicentre comparison. Br J Oral Maxillofac Surg 1996;34:389-393. 5-Lago-Méndez L, Diniz-Freitas M, Senra-Riviera C, Gude-Sampedro F, Rey JM, Garcia-García A. Relationships between surgical difficulty and postoperative pain in lower third molar extractions. J Oral Maxillofac Surg 2007;65:979-983. 6- Knutsson K, Lysell L, Rohlin M. Dentists' decisions on prophylactic removal of mandibular third molars: A 10-year follow-up study. Community Dent Oral Epidemiol 2001;29:308-314. 7- Knutsson K, Lysell L, Rohlin M. Dentists' decisions on prophylactic removal of mandibular third molars: A 10-year follow-up study. Community Dent Oral Epidemiol 2001;29:308-314. 8- Karasawa LH, Rossi AC, Groppo F, Prado FB, Caria P. Cross-sectional study of correlation between mandibular incisor crowding and third molars in young Brazilians. Med Oral Patol Oral Cir Bucal 2013;18:505-509. 9-Oenning A, Mello S, Groppo F, Haiter-Neto F. Mesial inclination of impacted third molars and its propensity to stimulate external root resorption in second molars - A cone-beam computed tomographic evaluation. J Oral Maxillofac Surg 2015;73:379-386. 10-McArdle LW, McDonald F, Jones J. Distal cervical caries in the mandibular second molar: An indication for the prophylactic removal of third molar teeth? Update. Br J Oral and Maxillofac Surg 2014;52:185-189. 11-Cutilli T, Bourelaki T, Scarsella S, Di Fabio D, Pontecorvi E, Cargini P, Junquera L. Pathological (late) fractures of the mandibular angle after lower third molar removal: a case series. J Med Case Rep 2013;7:121. 12- Bhat P, Cariappa KM. Inferior alveolar nerve deficits and recovery following surgical removal of impacted mandibular third molars. J Maxillofac Oral Surg 2015;11:304-308.