

Amorim A. <sup>\*†</sup> DDS, Amorim T. <sup>†</sup> DDS, Lavado J. <sup>\*\*</sup> TPD, Amoroso J. <sup>\*\*</sup> TPD, Tocantins E. <sup>\*\*</sup> DDS  
<sup>\*</sup> Autor <sup>†</sup>Instituto Superior de Ciências da Saúde - Egas Moniz <sup>\*\*</sup> Faculdade de Medicina Dentária Universidade de Lisboa

# BIMAXILARY FULL-ARCH REHABILITATION

## OF EDENTULOUS PATIENT: CLINICAL CASE

**CASE DESCRIPTION:** Male, patient, 78 years old, healthy, attended the clinic unhappy with the aesthetics of his smile. After a complete clinical and radiographic examination, there were all the parameters needed to perform a complete implant-supported rehabilitation.

6 implants were performed in the upper jaw and 4 implants in the lower jaw with immediate load (all of them Branemark System MkIV 4X15mm). The upper posteriors implants, due to poor primary stability, were loaded after the osseointegration period.

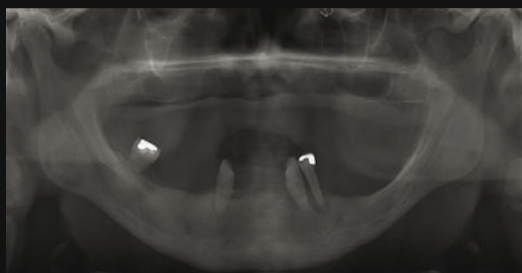
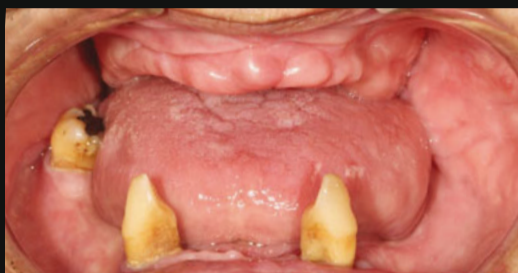
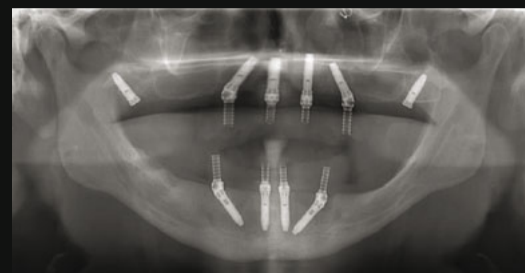Fig. 1 - Inicial photos a) Inicial panoramic X-ray



b) Intra-oral without prostheses



c) Immediate function X-ray

**DISCUSSION:** The loss of teeth promotes bone resorption at the level of the jaw. A implant-supported full rehabilitation allows the placement of implants and respective immediate loading. Because of being a simple surgical technique and prosthetic, and have a high success rate, the complete implant rehabilitation is increasingly used.

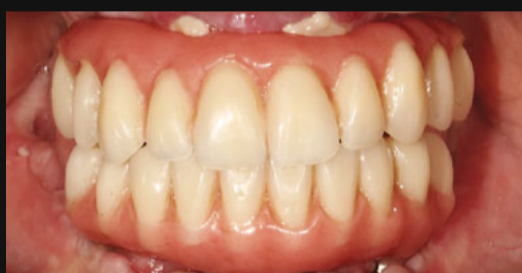

Fig. 2 - Provisional prostheses 10 days after surgery

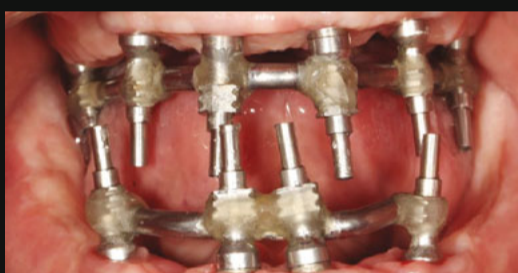

Fig. 3 - Final impression

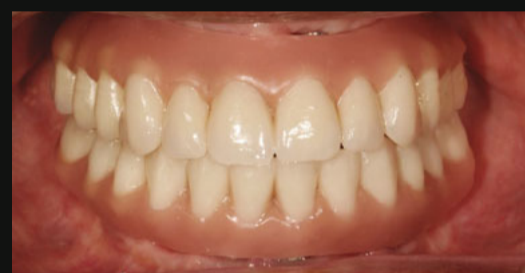

Fig. 4 - Esthetic try-in

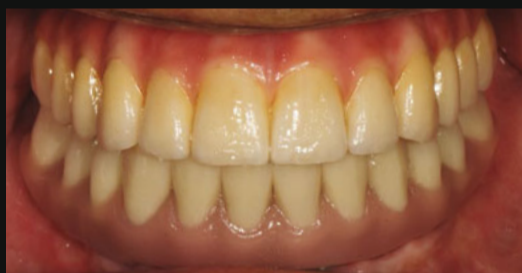

Fig. 5 - Ceramic try-in

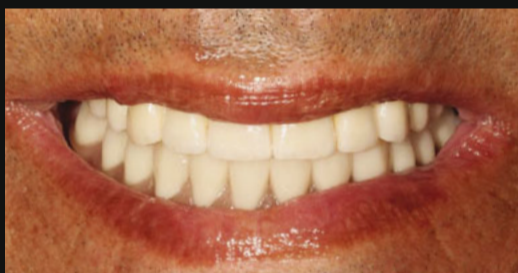

Fig. 6 - Ceramic try-in (smile)

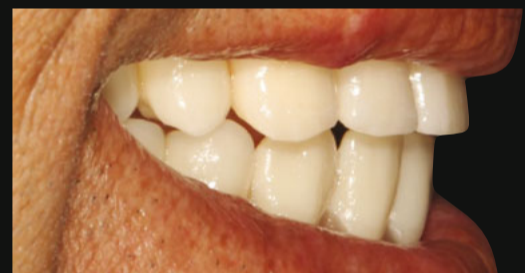

Fig. 7 - Ceramic try-in profile photo

**CONCLUSION:** The total rehabilitation on implants shown to be effective in surgical, prosthetic and biomechanical terms, bringing comfort, aesthetics and function to the patient.

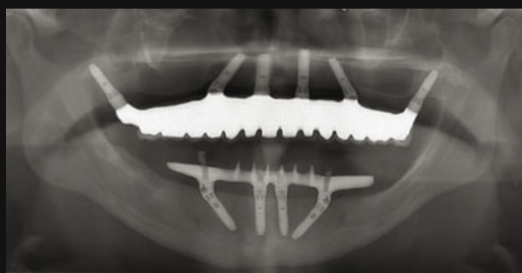


Fig. 8 - Definitive prostheses X-ray

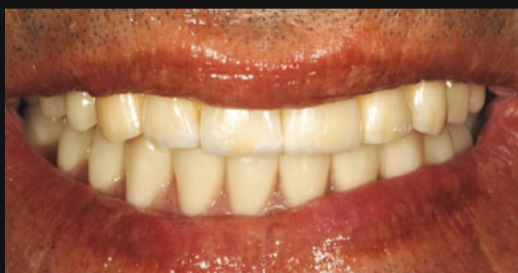

Fig. 9 - Smile with definitive prostheses

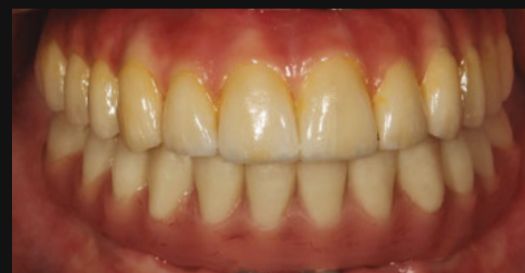

Fig. 10- Definitive prostheses (intra-oral)

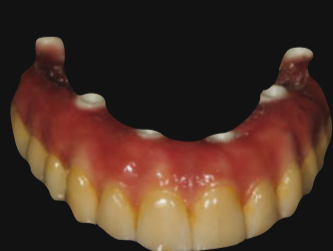

Fig. 11- Upper prostheses

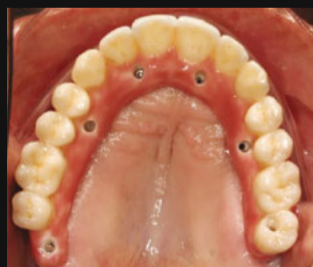

Fig. 12- Upper prostheses (occlusal)

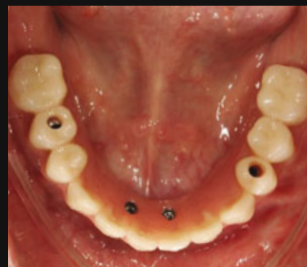

Fig. 13- Lower prostheses (occlusal)

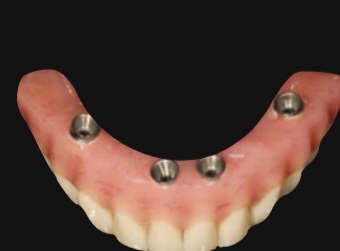

Fig. 14- Lower prostheses

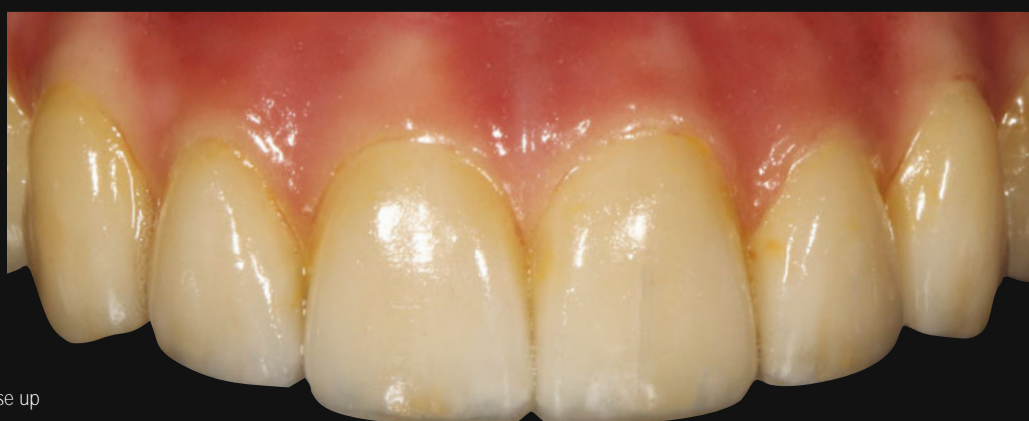

Fig. 15- Final close up