

Sarah Sonnenschein, Christopher J. Lux, Sebastian Zingler, Christian Freudlsperger

Interdisciplinary treatment approach in a class III patient with severe periodontitis: challenges and solutions in an University Dental Clinic

Introduction: The orthodontic treatment of adult patients with interdisciplinary treatment needs often presents a challenge and it requires good cooperation between dental specialists in order to achieve an optimal result. The case report describes the joint interdisciplinary treatment of a 40-year-old patient with Angle class III occlusion, progenic forced bite, severely malpositioned teeth and periodontitis. Conservative dental treatment was also necessary due to insufficient restorations and carious lesions.

Treatment method: The therapy encompassed orthognathic surgery as well as orthodontic, periodontal and conservative treatments together with tooth recontouring at the end. Following thorough treatment planning, the first step involved systematic periodontal treatment. Once stable periodontal conditions were achieved and maintained, the position of the maxillary front teeth was corrected by means of a multibracket appliance, followed by bimaxillary orthognathic surgery. Finally, direct tooth recontouring using composite resins was performed in order to improve the esthetic appearance of the maxillary front teeth.

Result: Thanks to good interdisciplinary cooperation between specialists in various dental disciplines including maxillofacial surgery, periodontology, orthodontics and conservative dentistry, the healthy and painless functioning of the jaws could be restored under healthy periodontal conditions and an esthetically appealing appearance of the teeth could be achieved.

Conclusion: Shared objectives and treatment planning between dental specialists should be aimed for in patients requiring interdisciplinary treatment. In order to achieve optimal treatment outcomes, the individual treatment steps should always be planned and, if necessary, adjusted in terms of time and interim results.

Keywords: dysgnathia; periodontal treatment; preoperative and postoperative orthodontic treatment; orthognathic surgery; tooth recontouring

Section of Periodontology, Department of Conservative Dentistry, Clinic for Oral, Dental and Maxillofacial Diseases, University Hospital Heidelberg, Im Neuenheimer Feld 400, 69120 Heidelberg, Germany: Dr. med. dent. Sarah Sonnenschein, functional senior physician
Department of Orthodontics and Dentofacial Orthopaedics, Clinic for Oral-, Dental- and Maxillofacial Diseases, University Hospital Heidelberg, Im Neuenheimer Feld 400, 69120 Heidelberg, Germany: Univ.-Prof. Dr. med. dent. Christopher J. Lux, medical director, Prof. (apl.) Dr. med. dent. Sebastian Zingler, leading chief physician
Department of Oral and Maxillofacial Surgery, Clinic for Oral-, Dental- and Maxillofacial Diseases, University Hospital Heidelberg, Im Neuenheimer Feld 400, 69120 Heidelberg, Germany: Prof. (apl.) Dr. med. Dr. med. dent. Christian Freudlsperger, leading chief physician and representative medical director
Citation: Sonnenschein S, Lux CJ, Zingler S, Freudlsperger C: Interdisciplinary treatment approach in a class III patient with severe periodontitis: challenges and solutions in an University Dental Clinic. Dtsch Zahnärztl Z Int 2022; 4: 49–57
Peer-reviewed article: submitted: 04.02.2021, revised version accepted: 15.07.2021
DOI.org/10.53180/dzz-int.2022.0006

Introduction

Dental treatment of patients with interdisciplinary treatment needs is often challenging and it requires good cooperation between specialists in order to achieve an optimal result. The following case report presents the surgical, orthodontic, periodontal and conservative treatments of a patient with Angle class III occlusion, prognathic forced bite, dental crowding and periodontitis. The patient also required conservative treatment due to various insufficient restorations and carious lesions.

Case presentation and choice of treatment

General medical history

In March 2013, the 40-year-old patient presented herself to the Department of Orthodontics and Dentofacial Orthopaedics of the Clinic for Oral, Dental and Maxillofacial Diseases at the Heidelberg University because she experienced severe temporomandibular pain. The general medical history was inconspicuous and the patient was a non-smoker. At that time, she had been living in Germany for 4 years and she worked as a saleswoman in retail. She had been married for 5 years.

Dental anamnesis

The patient reported that she had been experiencing temporomandibular pain for several years and that she had been suffering psychologically due to the esthetic appearance of her teeth. In her native country, she had previously undergone various tooth extractions due to caries and some of her teeth had been "filled". No further dental treatments had been performed to date. The patient stated that she brushed her teeth twice a day with an electric toothbrush and fluoride toothpaste and used toothpicks to clean her interdental spaces after each meal.

Main concerns of the patient

The patient's primary concerns were the desire for "straight" teeth and pain relief. Moreover, it was important for her to be able to practice more effective oral hygiene after treatment.

After her initial consultation, the patient was referred to the Depart-

ment of Oral and Maxillofacial Surgery as well as to the Section of Periodontology of the Department of Conservative Dentistry for continued examination by dental specialists and interdisciplinary treatment planning.

Extraoral findings

A marked mandibular midline deviation to the left (left masticatory plane approximately 2 mm further cranially, Figure 1) and a positive lip overjet were particularly evident.

Intraoral findings

Dental health status

Intraorally, a partially edentulous dentition that had been partially restored by means of conservative treatment was present, together with severely malpositioned teeth. The maxillary and mandibular front teeth displayed severe abrasion. A total of 23 teeth were present. The inspection of the tooth hard tissues revealed numerous insufficient restorations and wedge-shaped defects. Moreover, a number of open carious lesions were diagnosed (Figure 2). Vitality testing using cold spray revealed that all teeth were vital. Sensitivity on palpation and percussion of each individual tooth was not detected.

Periodontal findings

Localized gingival redness as well as hard and soft plaque were present. Pus discharged from the period-

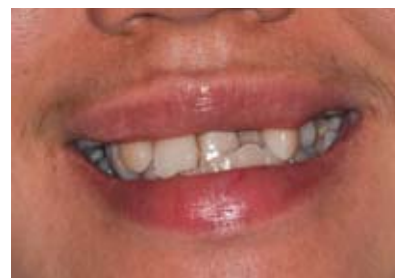

Fig. 1: S. K. Sonnenschein

Figure 1 Extraoral appearance at the time of the patient's initial consultation

ontium of the maxillary front teeth. The clinical attachment level (CAL) was between 3 and 7 mm in the maxilla and between 3 and 5 mm in the mandible (mean CAL: 3.5 mm). The general probing depths ranged between 3 and 4 mm, and at some sites in the maxilla, they were between 5 and 6 mm (mean probing depth: 2.5 mm). There was generalized bleeding on probing (BOP: 44%). Generalized recessions were also particularly evident in the maxillary anterior region. No furcation involvement or pathological tooth mobility was diagnosed. The detailed periodontal findings together with the complete general dental findings are shown in Figure 3.

Orthodontic findings

Clinical functional examination: Sigmatism addentalis, crenated tongue, bruxism (mainly awake bruxism), occlusal plane shift with a cranial incli-

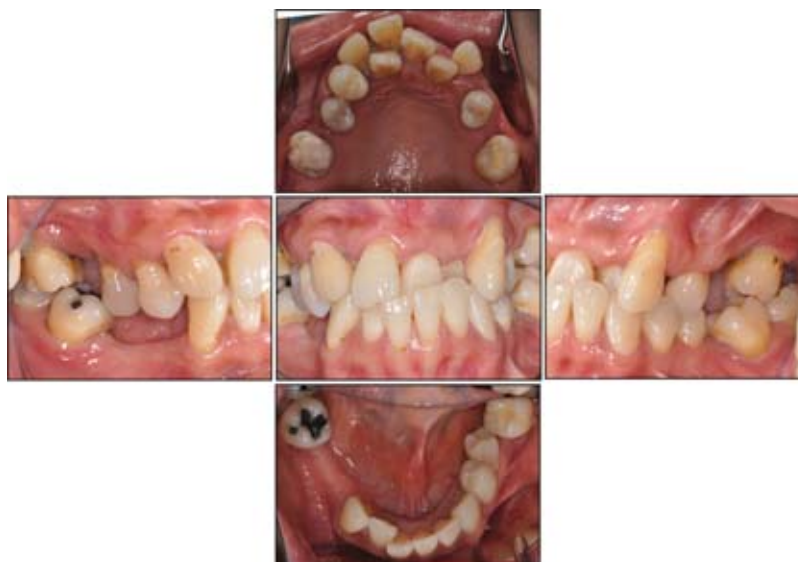

Fig. 2: S. K. Sonnenschein

Figure 2 Intraoral appearance at the time of the patient's initial consultation

nation of 2 mm on the left side, mandibular prognathic forced bite with protrusive mandibular excursion of 2 mm over tooth 24, mandibular deviation to left side during maximal mouth opening, intermediary clicking of the left temporomandibular joint during mouth opening, pain in the left temporomandibular joint during mouth opening, positive lip profile, straight “ante”-profile according to A. M. Schwartz.

Study model findings: upper jaw: overall arch length discrepancy: -22.4 mm, discrepancy posteriorly right: -3.8 mm, discrepancy posteriorly left: -5.6 mm, discrepancy anteriorly: -13 mm, anterior Tonn ratio: 0.78, palatally displaced lateral incisors 12 and 22, mesial rotation of teeth 15, 12, 22, and 25, distal rotation of tooth 21, mesial tipping inclination of teeth 17, 13, 23, 25 and 27, mesial drift of posterior teeth in the first and second quadrants, alveolar midline deviation of 2 mm to the right, labially displaced teeth 13, 11 and 23, supraposition of teeth 15, 14, 12 and 22; lower jaw: overall arch length discrepancy: -4.4 mm, discrepancy posteriorly right: -1.1 mm, discrepancy posteriorly left: -0.8 mm, discrepancy anteriorly: -2.5 mm, mesial rotation of teeth 35, 41 and 42, mesial inclination of teeth 38, 37, 47 and 48, lingual tipping of teeth 35, 42, 43, supraposition of teeth 32 and 42; occlusion: (modified) molar Angle Classification: on the right side 3/4 cusp Class III and on the left side full cusp Class III, mandibular midline deviation 2 mm to the left.

Radiological findings

Figure 4 shows the initial panoramic radiograph. Teeth 18, 16, 24, 26, 28, 36 and 44 to 46 are missing. Radiopaque areas indicating restorative restorations can be seen in the area of the dental crowns on teeth 17, 14, 13, 22, 26, 38, 37, 46 and 47. There is a generalized loss of alveolar bone up to the middle root third in the maxilla and up to the coronal root third in the mandible. Tooth 15 appears to show an apical radiolucency. The hard substance of tooth 22 shows a mesial radiolucency representing a secondary carious lesion.

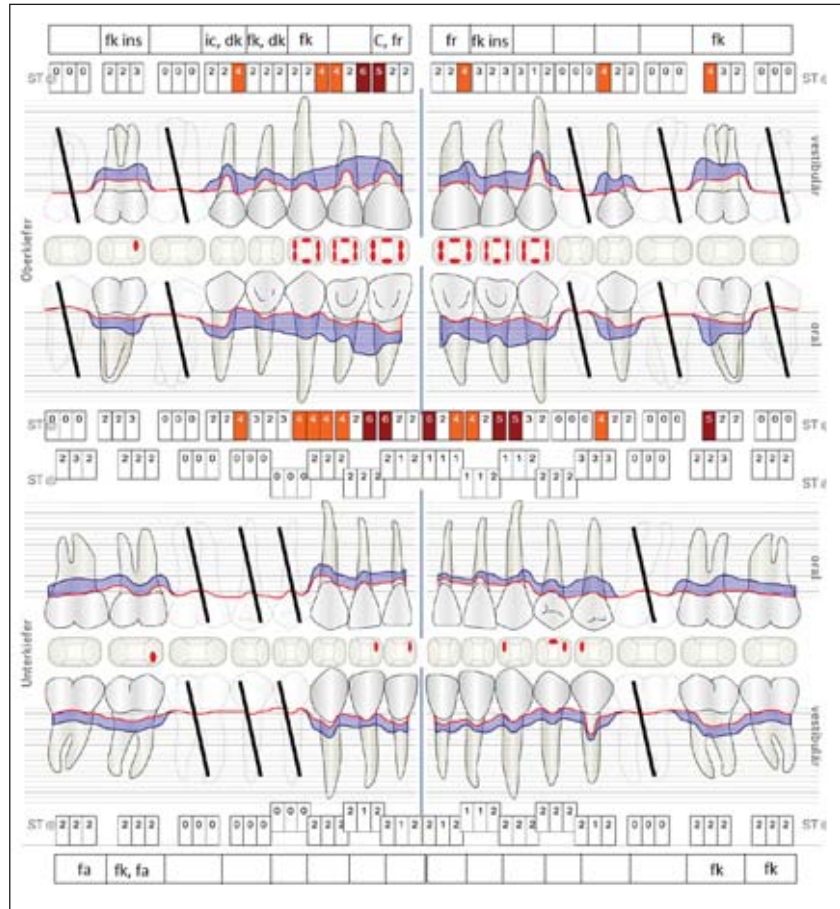


Figure 3 Detailed periodontal and dental findings. fk, composite restoration; C, caries; ic, initial caries; dk, wedge-shaped defect; fr, abfraction/heavy abrasion; fa, amalgam restoration; ins, insufficient

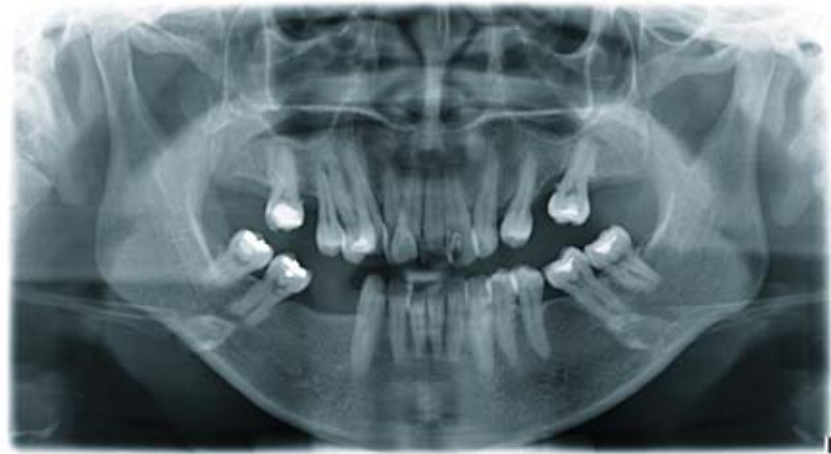

Figure 4 Panoramic radiograph from February 2013 (created on site)

Fig. 4: C. Lux, S. Zingler

The heads of the maxillary branch appear asymmetrical. The maxillary sinus and other bony structures show no evidence of pathological changes. In order to better assess the apical situation of tooth 15, an additional periapical X-ray was made; it

did not confirm an apical radiolucency at this tooth. Angular bone defects extending into the middle third of the root can be seen at teeth 25, 26 and 47. Hard deposits on the root surfaces which indicate subgingival tartar can be seen mesially at

Fig. 5: C. Lux, S. Zingler

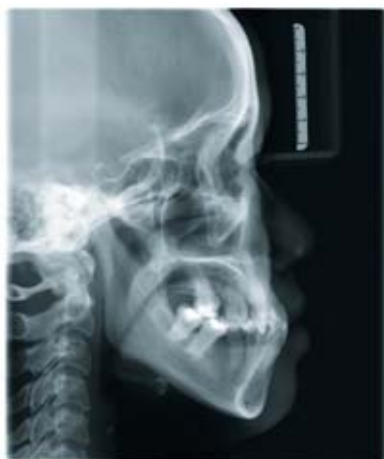

Figure 5 Cephalometric X-ray from January 2014 (initial findings)

teeth 17, 27 and 37 and distally at tooth 38.

The lateral cephalogram (Figure 5) reveals a mesial basal relation and a neutral, vertically tending facial skull structure. The upper and lower jaws have a prognathic position. The maxillary front teeth are axis-aligned and in orthoposition. The mandibular front teeth are axis-aligned and in anteposition. The maxillary and mandibular bases are relatively oversized.

Diagnoses

- skeletal class III, occlusal plane canting (2 mm further cranially on the left side), mandibular midline deviation of 2 mm to the left, prognathic forced bite, lack of space in the upper and lower jaw, severe teeth malalignment
- periodontitis (generalized stage III grade B [7]; according to the classification valid at the start of treatment: severe, generalized chronic periodontitis [1])
- caries at tooth 11
- initial carious lesion at tooth 15

Preliminary prognostic assessment

The patient was very open to the treatment suggestions and the anamnestic information regarding oral hygiene behavior indicated that good compliance could be expected. As there was also no general medical health risk, the patient-related factors were categorized as “favorable”. From

a periodontal perspective, except for tooth 12, the prognosis of all existing teeth was assessed as being “favorable” (prognosis system according to Kwok & Caton [6]). This assessment was mainly founded on the fact that no furcation involvement was present and good cleaning of the subgingival root surfaces appeared possible. In the case of tooth 12, due to its distal position and close proximity to the neighboring teeth, it would not be possible to perform sufficient subgingival cleaning. Consequently, it was assumed that home-based supra- and subgingival plaque removal at this tooth would not lead to satisfactory results in spite of the patient’s strong determination. Thus, the initial prognosis of the tooth was considered questionable from a periodontal standpoint.

By extracting tooth 12 and retracting tooth 23 in order to create space, the resolution of the frontal crowding in the maxilla appeared to be possible. Similarly, it was expected that the frontal crowding could be corrected after the distalization of tooth 43 in the mandible. Given the fact that the extent of distalization of tooth 23 would be insufficient to completely correct the maxillary alveolar midline deviation preoperatively, the remaining correction of the maxillary dental midline would have to be taken into account as part of the surgical planning.

In relation to maxillofacial surgery, no contraindications for orthognathic surgery existed due to the patient’s good general health status, the available bone supply and her compliance. The patient was very open to the treatment suggestion after being informed about the prospective repositioning of both jaws (bignathic repositioning osteotomy) as part of the interdisciplinary treatment, and the resulting effect on function and esthetics.

Treatment plan

The primary therapeutic goal was to establish a stable occlusion under healthy periodontal conditions. The treatment plan was based on the close consultation between all specialists of the dental disciplines involved.

1. Treatment with a bite splint for managing the temporomandibular pain
2. Systematic periodontal treatment: Anti-infective treatment including full mouth disinfection (FMD) according to the “Heidelberg Concept” (described in Sonnenschein et al. 2021 [9]); re-evaluation of the periodontal status 3 months after FMD; this was to be followed by closely scheduled supportive periodontal therapy (SPT) (every 6 to 8 weeks).
3. Composite restorations on teeth 17, 47 and 11 (if possible, during the hygiene phase of systematic periodontal treatment)
4. Based on the results of the ongoing periodontal treatment, the definitive extraction planning would need to be decided from an orthodontic standpoint.
5. After stable periodontal conditions were established, the decision was made to extract tooth 12 in order to create space and perform preoperative orthodontic treatment using a multibracket appliance.
6. After preoperative shaping of the dental arches and the transversal/sagittal adjustment of both jaws, the the bimaxillary orthognathic was performed in both jaws.
7. After postoperative orthodontic precision adjustments and the removal of the bands, shape corrections of the teeth in the anterior region and prosthetic rehabilitation of the interdental gap in quadrant 4 were to be performed at the beginning of the orthodontic retention phase.

Course of treatment

After the patient received a bite splint to alleviate her TMJ problems, systematic periodontal treatment began in February 2014. After 2 cleaning appointments, FMD (modified according to Quirynen [8]) was performed on 2 consecutive days in mid-March 2014. The insufficient fillings on teeth 11, 22, 17 and 47 were replaced with direct composite restorations as part of the supportive periodontal treatment (SPT) in August 2018. Furthermore, the wedge-shaped defect on tooth 14 was filled with a composite restora-

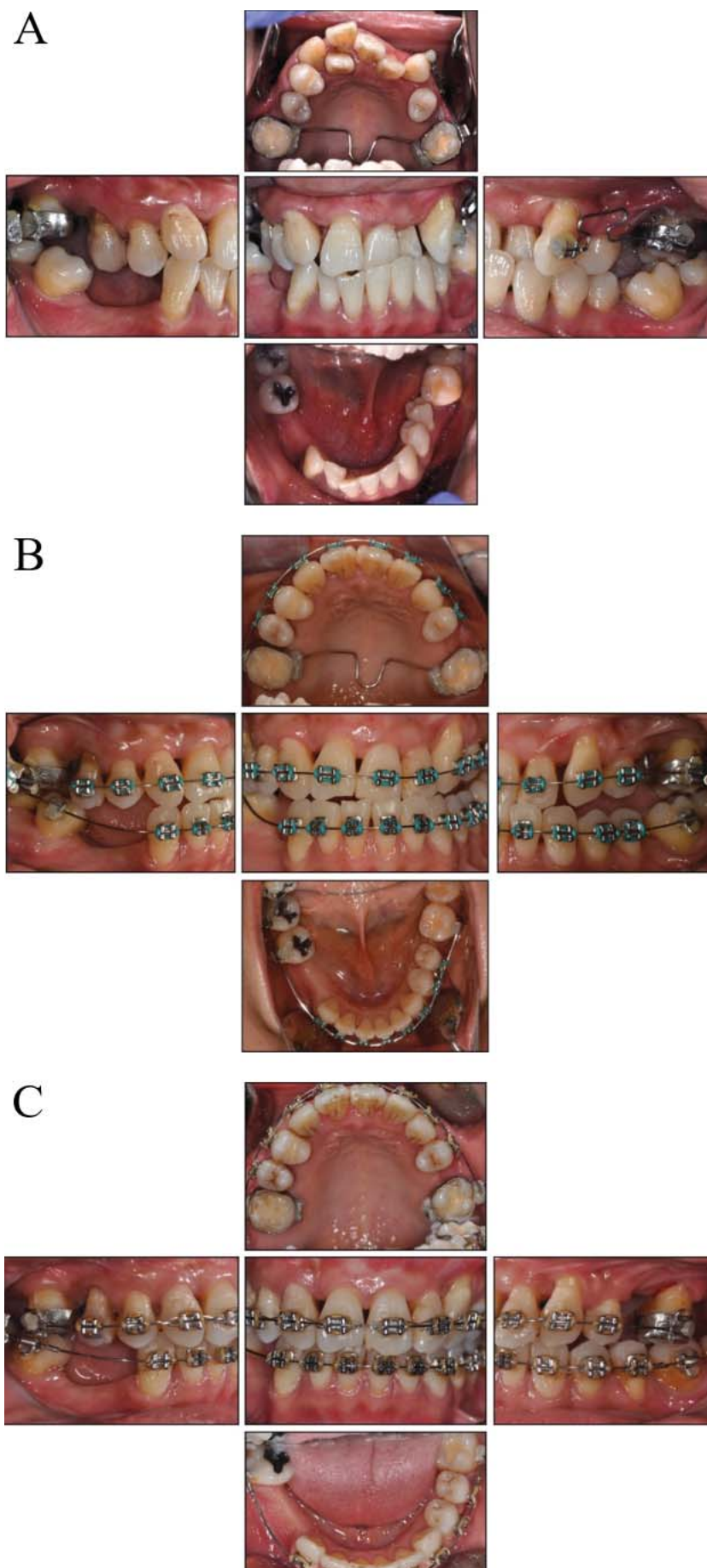


Figure 6 (A) Intraoral photos presenting the clinical condition in February 2015, (B) December 2015, and (C) after bimaxillary orthognathic surgery in January 2017

tion in the course of SPT. After the re-evaluation of the periodontal status 3 months after FMD and final orthodontic planning, tooth 12 was ready for extraction. It was finally extracted using a minimally invasive procedure in April 2015. The re-evaluation of the periodontal status showed a reduction of all probing sites to 3 mm, with the exception of tooth 11 at the distolingual site. Tooth 11 displayed a probing pocket depth of 4 mm and no bleeding. Overall, BOP decreased to 10%. The mean probing depth at the time of re-evaluation was 2.1 mm and the average CAL was 2.7 mm. Due to the remaining tooth malpositions, and the consequent inability to effectively maintain oral hygiene at home, as well as the additional difficulty in performing oral hygiene due to the planned multiband appliance, a SPT interval of 6–8 weeks was scheduled. After stable periodontal conditions were achieved just 6 months consecutive to FMD, the definitive orthodontic treatment planning began.

Orthodontic treatment

Orthodontic treatment began in December 2014 with partial fixed appliance in the upper jaw in order to achieve the isolated retraction of tooth 23. At the same time a transpalatal arch for maximal anchorage was inserted. A partial arch (23–26) with a T-loop was used in order to align and retract tooth 23 and to create space prior to the maxillary anterior alignment. Due to the mesial tipping of tooth 27, a partial space closure was carried out in region 025. In April 2015, tooth 12 was extracted (using a minimally invasive technique by the periodontist). In May 2015, a fully fixed multibracket appliance in both jaws was inserted. Regular check-ups and arch changes were made until the surgical planning began in October 2015. The intraoral clinical condition during the course of treatment is shown in Figure 6 A–C.

Maxillofacial surgery

In order to plan the bimaxillary orthognathic surgery, the documents (DVT, initial study models with the

Fig. 6: S. K. Sonnenschein

Month or date	Orthodontics	Conservative treatment/ periodontal treatment	Maxillofacial surgery
March 2013	Initial consultation and planning of further interdisciplinary evaluation of TMD complaints, PA pretreatment		
December 2013	Orthodontic diagnosis and treatment plan; presentation in an interdisciplinary dysgnathia consultation, information about multibracket appliance + surgery, systematic prophylaxis program		
05.02.2014		Oral hygiene phase – appointment I (GBI: 10%; PCR: 47%; BOP: 41%)	
27.02.2014		Oral hygiene phase – appointment II (GBI: 4%; PCR: 20%)	
20./21.03.2014		FMD with subsequent controls after 1 and 2 weeks	
25.06.2014		Re-evaluation PA-Status (GBI: 0%; PCR: 24%; BOP: 11%)	
28.08.2014		Supportive periodontal therapy, composite resin restorations on teeth 11, 22, 17, 47	
August 2014	Re-evaluation, final orthodontic diagnostic and treatment plan		
October 2014	Presentation in the orthognathic multidisciplinary consultation and discussion of the final treatment plan with patient		
December 2014	Maxillary partial banding left (bands on 16, 26, bracket on 23; transpalatal arch and partial arch with T-loop for retraction 23).		
07.01.2015	Follow-up appointment, activation of the T-Loop, local fluoridation	SPT (GBI: 3%; PCR: 33%)	
18.02.2015	Follow-up appointment, T-Loop activation	SPT (GBI: 9%; PCR: 26%)	
20.04.2015	Follow-up appointment, T-Loop activation	SPT (GBI: 3%; PCR: 29%)	
30.04.2015	Clinical re-evaluation and referral to extraction of tooth 12	Minimally invasive extraction of tooth 12	
May 2015	Maxillary/mandibular full banding, followed by further check-ups and wire changes		
08.06.2015	Follow-up check	SPT (GBI: 3%; PCR: 27%)	
08.07.2015	Follow-up check and maxillary/mandibular wire change		
10.08.2015	Follow-up check	SPT (GBI: 1%; PCR: 39%)	
21.09.2015	Follow-up and maxillary/mandibular wire change	SPT (GBI: 0%; PCR: 15%)	
October 2015	Orthodontic interim diagnosis		
06.11.2015	Follow-up check	Composite resin restorations of the wedge-shaped defects on teeth 14 and 15	
December 2015	Presentation in a dysgnathia consultation with planning of surgery appointments		

Table 1 Overview of the treatment process and the corresponding therapeutic procedures. BOP, bleeding on probing; TMD, temporomandibular dysfunction; FMD, full mouth disinfection; GBI, gingival bleeding index; PCR, plaque control record; PA, periodontal treatment; SPT, supportive periodontal therapy; Orth, orthodontics.

Month or date	Orthodontics	Conservative treatment/ periodontal treatment	Maxillofacial surgery
24.02.2016	Follow-up check		Preparation of planning documents for the surgery (DVT, study models with facebow registration, cephalometric evaluation)
08.03.2016	Follow-up check	SPT (GBI: 1 %; PCR: 18 %)	Inpatient admission
09.03.2016	Follow-up check		Bimaxillary repositioning osteotomy
11.03.2016	Further postoperative check-ups and postoperative orthodontic fine adjustments (setting)		
27.01.2017		SPT (GBI: 3 %; PCR: 27 %)	
21.02.2017	Debonding, temporary insertion of vacuum formed retainers (Essix retainers) for the duration of the scheduled tooth reshaping	Direct tooth recontouring using various composite resins, Part I	
28.02.2017	Insertion of maxillary/mandibular fixed retainer and removable retention appliance	Direct tooth recontouring using various composite resins, Part II	
28.03.2017	Check-up of retention		Removal of the osteosynthesis plates

Table 1 Overview of the treatment process and the corresponding therapeutic procedures. BOP, bleeding on probing; TMD, temporomandibular dysfunction; FMD, full mouth disinfection; GBI, gingival bleeding index; PCR, plaque control record; PA, periodontal treatment; SPT, supportive periodontal therapy; Orth, orthodontics.

facebow registration, cephalometric evaluation) were prepared on 24.02.2016. On 08.03.2016, the patient was admitted as an inpatient and the surgical preparations were completed. On 09.03.2016, the bimaxillary orthognathic surgery was performed under general anesthesia without complications. The maxilla was impacted by 2 mm on the left side to correct the canted occlusal plane after a Le Fort I osteotomy was performed in the usual manner. In order to correct the dental midline deviation and the maxilla's retrograde position, the maxilla was displaced 3 mm to the left in the transverse and 3 mm in the anterior direction, respectively. Four L-shaped miniplates (Medartis Modus 2.0) were used for osteosynthesis. The bilateral sagittal split osteotomy (BSSO) was performed according to Obwegeser-Dal Pont using the Hunsuck-Epker modification (Figure 7) in the mandible. Semi-rigid orthognathic plates (Medartis Modus 2.0) were used for osteosynthesis in the mandible. Postoperatively, the intended occlusion was secured with

tight elastics in the splint. The postoperative X-ray confirmed that the osteosynthesis material was properly inserted (Figure 8). No complications occurred during the course of inpatient care. The patient was instructed about how to change the elastics by herself and she was discharged from the inpatient care unit on March 16, 2020. After good bone consolidation in the area of the osteotomies, the

osteosynthesis material was removed 12 months postoperatively on March 28, 2017, under general anesthesia without complications. The change in the facial profile resulting from the surgery can be seen in Figure 9.

Tooth recontouring

The additive tooth recontouring of the maxillary front teeth (teeth 13 to

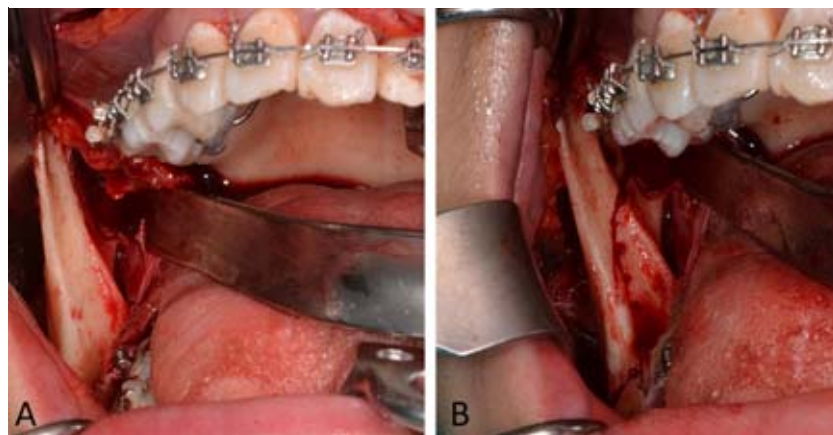


Figure 7 Intraoperative X-ray images. (A) An illustration of the right ascending mandibular ramus (B) Sagittal split osteotomy (BSSO) according to Obwegeser-Dal Pont with modification according to Hunsuck-Epker

Fig. 7: C. Freudsperger

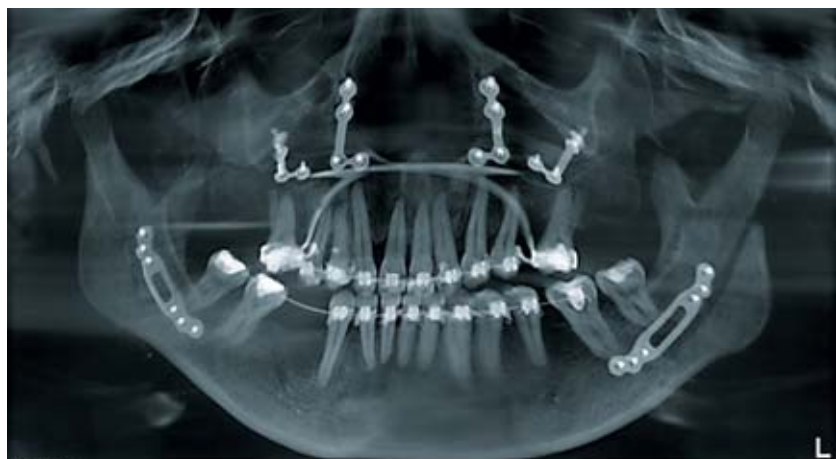


Figure 8 Postoperative orthopantomogram in March 2016

23) using the direct composite layering technique (materials: OptiBond FL Primer and Adhesive, Kerr; Tetric Evo Ceram and Tetric Evo Flow, Ivoclar Vivadent) was performed in 2 steps in February 2017 (Figure 10). The detailed course of treatment is shown in Table 1. The diagnoses in February 2017 were:

- Angle class I after orthodontic treatment and maxillary/mandibular repositioning osteotomy of an Angle class III with a frontal prognathic forced bite.
- Stable periodontal conditions after anti-infective treatment of periodontitis (generalized stage III grade B) with localized recurrence at the buccal site of tooth 23.

The chronological sequence of the treatment protocol and the specific procedures of each respective specialist discipline are summarized in Table 1.

Epicrisis

Studies have shown that in the presence of good plaque control, orthodontic treatment of patients with stabilized periodontitis, who have clinically healthy gingival conditions along with reduced periodontium, is possible without worsening the periodontal conditions or increasing the recurrence risk of periodontitis [11]. On the other hand, there also exist animal studies demonstrating that orthodontic forces on teeth with periodontal inflammation can lead to gingival recession and bone loss [4, 10]. For this reason, it is important to establish healthy and stable periodontal conditions prior to any orthodontic tooth movement [2, 3, 5]. In the case presented, the narrow and crowded position of the maxillary front teeth posed a particular challenge for anti-infective treatment. In

addition to the difficulties of home-based oral hygiene, it was technically very challenging for the periodontist to access the entire subgingival surfaces in this area. Besides special curettes and airscalers, smaller, specially sharpened Mini-Five curettes were also used for subgingival debridement during FMD, as the teeth were sometimes so close together that the instruments did not fit between the teeth. Given the fact that the regeneration, or rather, repair of bony periodontal defects should largely be completed, and both the practitioner and patient should be confident about effective home-based plaque removal, orthodontic movements were not started until periodontal conditions were stable 6 months after anti-infective treatment. The orthodontic treatment of periodontally damaged adult dentitions presents a special challenge. This is because the involutive ageing processes of the desmodont and alveolar bone, as well as the type and extent of periodontal damage, create altered tissue responsiveness to orthodontic interventions [8, 9]. In the presence of attachment loss after periodontal treatment, it is important to note that the root surface which can absorb the orthodontic force is reduced and that the center of resistance is shifted apically, resulting in a longer lever arm; reduced forces must then be applied to account for these circumstances [2, 3, 5]. In order to correct a skeletal class III, orthodontic treatment and maxillofacial surgery is an established procedure; its aim is to achieve a class I dentition with stable



Figure 9 Preoperative profile views: (A) frontal and (B) lateral as well as postoperative profile views: (C) frontal and (D) lateral

Fig. 10: S. K. Sonnenschein

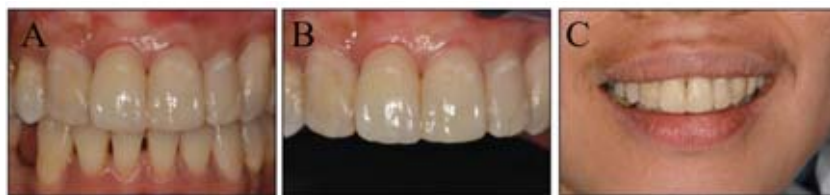

Figure 10 Appearance after direct tooth recontouring using various composite resins in March 2017

occlusion and the simultaneous correction of the maxillary and mandibular positions based on cephalometric and facial landmarks which are esthetic. The patient in this case underwent bimaxillary orthognathic surgery after preoperative orthodontic treatment without any complications. Moreover, throughout the course of treatment, the patient showed a stable occlusion without any signs of relapse of the original class III occlusion. A good consolidation of the bone in the former areas of osteotomy was seen when the osteosynthesis material was removed, indicating that a good long-term outcome can be assumed from a surgical standpoint.

From a periodontal perspective, the continued prognosis is likewise considered to be good. The patient was able to establish a satisfactory home-based oral hygiene regime and the periodontal condition has remained stable over the entire period ensuing FMD. The patient claims to remain motivated.

For personal reasons, the patient changed her residence to a more distant location at the end of 2016. Although the treatment that had been started was completed, she searched for a new dentist in her new location from March 2017 in order to continue with the SPT appointments, for which an interval of 6 months was recommended. Further treatment planning includes, in addition to SPT, the closure of the dental gap in region 44–46 using implants or a bridge and orthodontic retention.

The case presented illustrates how a treatment goal can be achieved by the close interdisciplinary cooperation between specialists in the disciplines of orthodontics, oral and maxillofacial

surgery, and periodontics/restorative dentistry. Following collective case analysis by all the specialists involved, a joint treatment strategy was planned and implemented in a coordinated sequence. The treatment aim which consisted of establishing a stable occlusion in a normal occlusal position, with the best possible pain-free function and good conditions for maintaining periodontal stability, as well as an esthetically pleasing appearance of the teeth could be achieved by this procedure through interdisciplinary cooperation.

Conflict of interest

The authors declare that there is no conflict of interest according to the guidelines of the International Committee of Medical Journal Editors.

References

1. Armitage GC: Development of a classification system for periodontal diseases and conditions. *Ann Periodontol* 1999; 4: 1–6
2. Diedrich P: Biomechanische Prinzipien für orthodontische Bewegungen bei reduziertem Attachment. *Dtsch Zahnärztl Z* 1990; 45: 78–81
3. Diedrich P, Fritz U: Wechselwirkungen zwischen Parodontologie und der kieferorthopädischen Behandlung Erwachsener. *Inf Orthod Kieferorthop* 2006; 38: 189–199
4. Ericsson I, Thilander B, Lindhe J, Okamoto H: The effect of orthodontic tilting movements on the periodontal tissues of infected and non-infected dentitions in dogs. *J Clin Periodontol* 1977; 4: 278–293
5. Gkantidis NCP, Topouzelis N: The orthodontic-periodontic interrelationship in

integrated treatment challenges: a systematic review. *J Oral Rehabil* 2010; 37: 377–390

6. Kwok V, Caton JG: Commentary: prognosis revisited: a system for assigning periodontal prognosis. *J Periodontol* 2007; 78: 2063–2071

7. Papapanou PN, Sanz M, Buduneli N et al.: Periodontitis: consensus report of workgroup 2 of the 2017 World Workshop on the Classification of Periodontal and Peri-Implant Diseases and Conditions. *J Periodontol* 2018; 89 Suppl 1: S173–S182

8. Quirynen M, Bollen CM, Vandekerckhove BN, Dekeyser C, Papaioannou W, Eysen H: Full- vs. partial-mouth disinfection in the treatment of periodontal infections: short-term clinical and microbiological observations. *J Dent Res* 1995; 74: 1459–1467

9. Sonnenschein SK, Ziegler P, Ciardo A, Ruetters M, Krisam J, Kim TS: The impact of splinting mobile mandibular incisors on oral health-related quality of life – preliminary observations from a randomized clinical trial. *J Clin Periodontol* 2021; 48(6): 816–825

10. Wennstrom JL, Lindhe J, Sinclair F, Thilander B: Some periodontal tissue reactions to orthodontic tooth movement in monkeys. *J Clin Periodontol* 1987; 14: 121–129

11. Zasciurinskiene E, Lindsten R, Slotte C, Bjerklind K: Orthodontic treatment in periodontitis-susceptible subjects: a systematic literature review. *Clin Exp Dent Res* 2016; 2: 162–173



Photo: S. Sonnenschein

DR. MED. DENT.

SARAH SONNENSCHN

Functional senior physician
Section of Periodontology, Department of Conservative Dentistry, Clinic for Oral, Dental and Maxillofacial Diseases, University Hospital Heidelberg
Im Neuenheimer Feld 400
69120 Heidelberg
sarah.sonnenschein@med.uni-heidelberg.de