

Coronectomy with Subsequent Implant-Prosthetic Rehabilitation of a Patient: A Case Report

Christoph Polly¹, Tristan Hampe¹, Fouad Khoury^{1,2}

1: Private Clinic Schloss Schellenstein, Olsberg, Germany
 2: Department of Oral and Maxillofacial Surgery, University of Münster, Münster, Germany
 Contact: prof.khoury@t-online.de

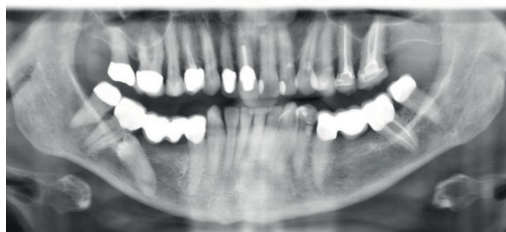


INTRODUCTION

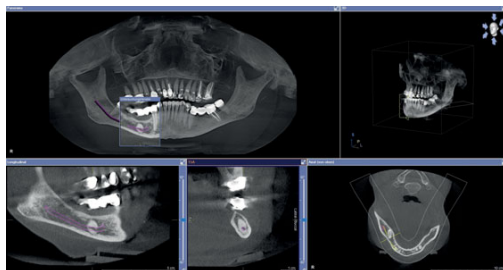
If there is a close anatomical relationship between impacted teeth and the inferior alveolar nerve, the surgical removal of these teeth poses an increased risk of nerve damage. In some cases, this risk can be reduced by performing a coronectomy, leaving the root in place. In the literature, this was mainly described for wisdom teeth [1], [2]. The presented case demonstrates the treatment option of a coronectomy of an impacted premolar while preserving the surrounding bone for subsequent implant-prosthetic rehabilitation.

MATERIAL AND METHODS

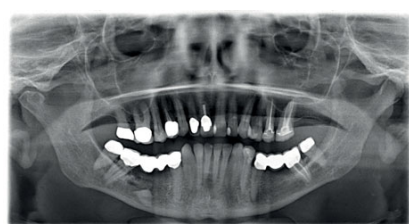The patient presented with a distally angulated and impacted tooth 45 and secondary caries on the mesial crown margin of tooth 47. Teeth 45 and 46 had been replaced by pontics for decades, with teeth 44 and 47 serving as the abutments. On the panoramic X-ray, the inferior alveolar nerve projected onto the root of tooth 45, and the CBCT showed that the inferior alveolar nerve was enclosed by the root of tooth 45. The patient was recommended a coronectomy on tooth 45. The coronectomy was performed under intravenous sedation with peri-operative antibiotics. A bony lid was prepared using the MicroSaw (DENTSPLY Implants, Mannheim, Germany). After the removal of the tooth crown and the coronal third of the tooth root, the remaining portion was left in place due to the close anatomical relationship to the inferior alveolar nerve, and the bony lid was repositioned. After proper healing, tooth 47 had to be removed following the failure of a preservation attempt. Two months postoperatively, implantation was carried out in regions 45 and 47, and bone augmentation was performed using the split bone block technique and bone core technique. Autologous bone for augmentation was harvested both locally at the implantation site and from the ipsilateral retromolar area. After implant exposure, prosthetic restoration was performed without any sensory impairment in this area.



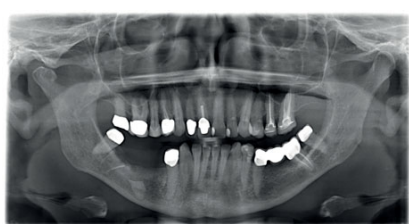Preoperative panoramic X-ray presenting the distally-angulated and impacted premolar (FDI: 45).



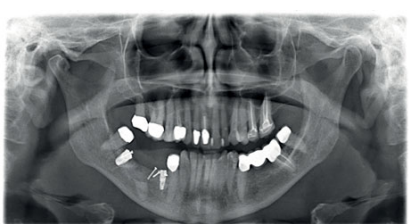Preoperative cone beam tomography presents the close relationship of the premolar to the inferior alveolar nerve with enclosure of it within the root.



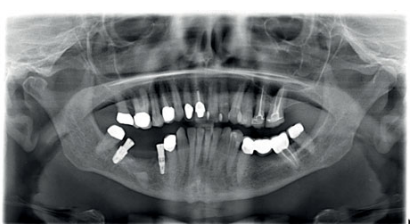Postoperative panoramic X-ray after the coronectomy.



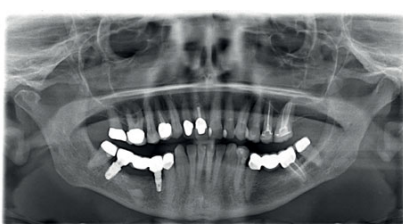Panoramic X-ray after extraction of tooth 47.



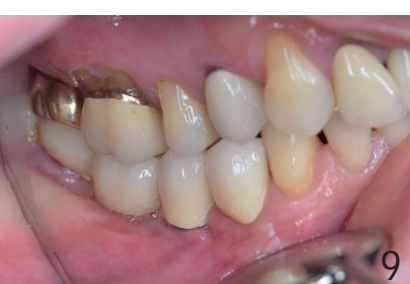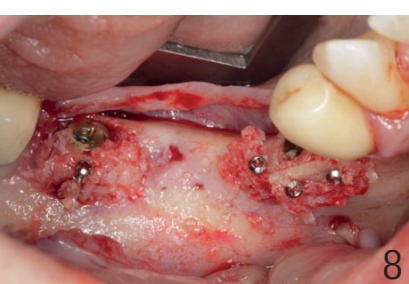
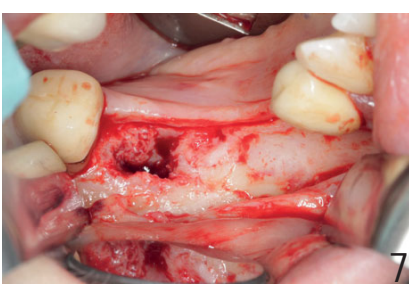
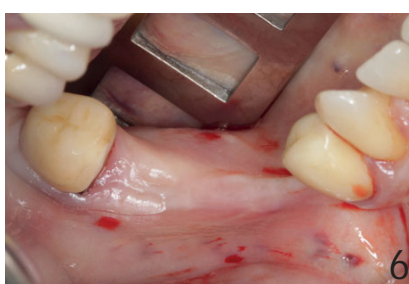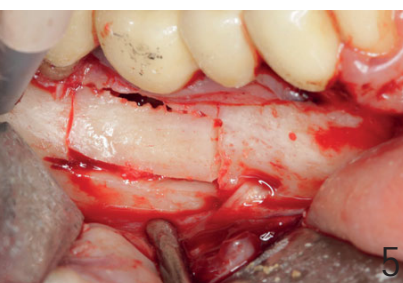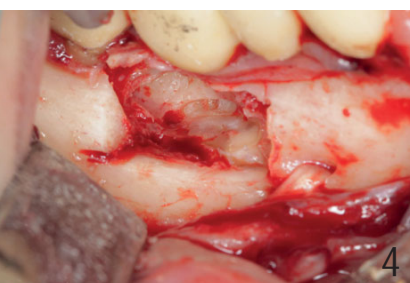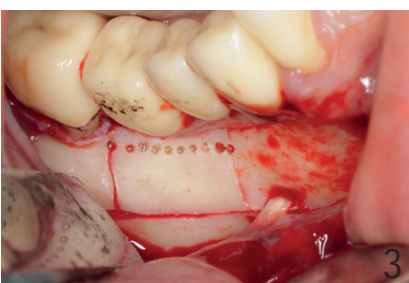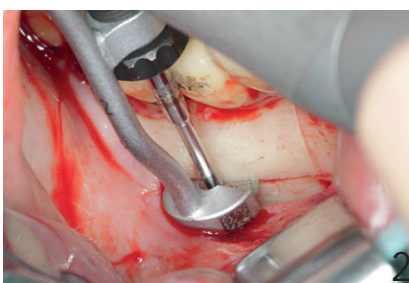
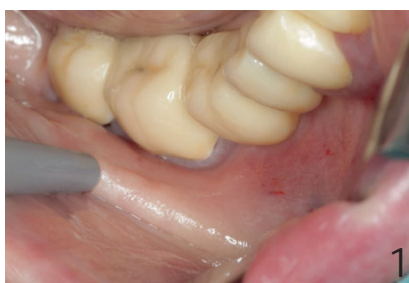Panoramic X-ray after augmentation and implantation in regions 45 and 47.



Panoramic X-ray after exposure of the implants in regions 45 and 47.



Panoramic X-ray after insertion of the final prosthetic restoration.



CONCLUSION

A coronectomy can be performed as an alternative to complete tooth removal if there is a close relationship to the inferior alveolar nerve. The exposure of the crown using a bony lid preserves the surrounding bone and enables subsequent implant placement.

Caption:

1. Preoperative situation
2. Preparation of a bony lid with the MicroSaw (horizontal osteotomy)
3. Prepared bony lid while preserving the inferior alveolar nerve
4. Tooth 45 after the coronectomy
5. Repositioned bony lid
6. Clinical situation: 8 weeks after the extraction of tooth 47
7. Situation before implant placement with good regeneration of the bony lid
8. Inserted implants with the autologous augmentation in regions 45 and 47
9. Clinical situation after insertion of the prosthetic restoration by the referring dentist

Literature:

- [1] Dolanmaz D, Yildirim G, Isik K, Kucuk K, Ozturk A. A preferable technique for protecting the inferior alveolar nerve: coronectomy. J Oral Maxillofac Surg. 2009 Jun;67(6):1234-8.
- [2] Hatano Y, Kurita K, Kuroiwa Y, Yuasa H, Arijji E. Clinical evaluations of coronectomy (intentional partial odontectomy) for mandibular third molars using dental computed tomography: a case-control study. J Oral Maxillofac Surg. 2009 Sep;67(9):1806-14.
- [3] Khoury F. The bony lid approach in pre-implant and implant surgery: a prospective study. Eur J Oral Implantol. 2013 Winter;6(4):375-84.
- [4] Fouad Khoury (Hrsg.): Bone and Soft Tissue Augmentation in Implantology. 1. edition, Quintessence Publishing, Deutschland 2022