

Int Poster J Dent Oral Med 2007, Vol 9 No 03, Poster 369

## Sinus Augmentation with Periosteum derived Tissue Engineered Bone

**Language:** English

**Authors:**

Dr. med. Sebastian Sauerbier, Dr. med. Pit Voss, Dr. med. Nils Weyer, r. med. Dr. med. dent. Jens Kuschnierz, Dr. med. dent. Christoph Zizelmann, PD Dr. med. Dr. med. dent. Ralf Schön, Prof. Dr. med. Dr. med. dent. Ralf Gutwald, Prof. Dr. med. Dr. med. dent. Rainer Schmelzeisen,

Department of Maxillofacial Surgery, University Hospital Freiburg

**Date/Event/Venue:**

19th to 21th of Oktober 2006  
 AO-Biotechnology-Symposium, From basic research to clinical applications using biotechnology and bioengineering  
 Lausanne, Switzerland



DGZMK-Poster-Award 2008 für das beste Poster 2007

### Introduction

Tumors in the oral cavity cause loss of bone and soft tissue (Sauerbier et al., 2006). More often than the reconstruction of soft tissue the improvement of the hard tissue bearing of dentures and dental implants is required. For the reconstruction of bone defects the gold standard is still the autologous bone harvested from the iliac crest, the mandible or the maxilla. Tissue-engineering procedures for hard tissue augmentations of the maxilla offer significant advantages compared with conventional grafts, as there is minimal or no donor site morbidity, limited availability of bone and the necessity of an additional surgical procedure. Periosteum has been demonstrated to have cell populations, which include chondroprogenitor and osteoprogenitor cells, that can be isolated in tissue culture and form both cartilage and bone. The aim of this prospective study was to evaluate the feasibility of the clinical application of periosteum derived tissue engineered bone.

### Material and Methods

Periosteal cells were isolated from a biopsy of periosteum of the mandibular angle carried out as an outpatient protocol under local anaesthesia (Fig. 1). The transplants were prepared as described by Perka et al. (2000). After four passages the periosteal cells were trypsinized and subsequently resuspended in DMEM/Ham's F12 (1:1) medium and mixed with human fibrinogen (3:1, TissueColl, Baxter, Vienna, Austria). The cell suspension was soaked into polymer fleeces (Ethicon, Norderstedt, Germany) and by adding bovine thrombin polymerized (TissueColl, Baxter, Vienna, Austria) diluted in PBS (1:10). Subsequently, cell polymer transplants were cultivated for 1 week in DMEM/Ham's F12 (1:1) medium, supplemented with 5% autologous patient serum, ascorbic acid (50 mg/l), dexamethasone ( $10^{-7}$ M) and  $\beta$ -glycerolphosphate (10 mM). Eight weeks after harvesting the periosteal grafts, the transplantation was performed in combination with a sinus lift as described by Boyne and James (1980). The tissue-engineered autologous bone was placed and condensed into the depth of the sinus cavity (Fig. 2). The control group underwent the same procedure except that autologous cancellous bone from the iliac crest was used instead of tissue engineered bone substitute. Turkey's Studentized Range Test and the Mann-Whitney-Test were used for statistical evaluation.

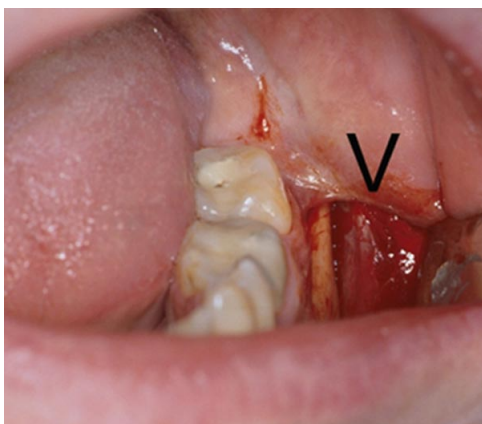


Fig. 1: Harvesting the specimen of periosteum (below V).

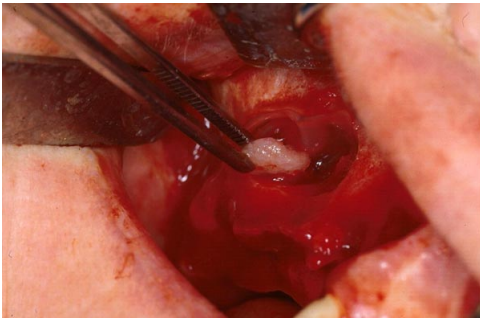


Fig. 2: Insertion of a cell-polymer construct into the maxillary sinus.

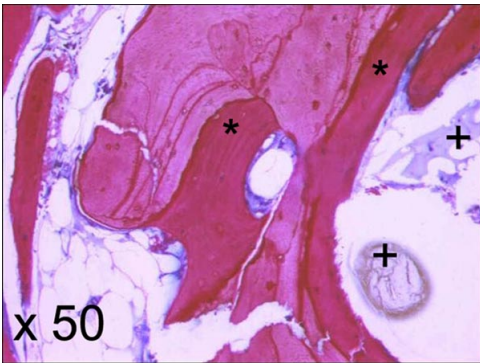


Fig. 3: The x 50 magnification reveals mineralized trabecular bone (\*) with remnants of biomaterial (+).

## Results

Periosteal harvesting from the mandibular angle via an intraoral approach under local anaesthesia was tolerated well by the patients, and throughout the complete procedure no complications occurred. The wounds resulting from replantation of the engineered tissue healed without complications. The implants were inserted into the grafted areas. When the implant was inserted primary stability was tested and proven clinically. Radiographs demonstrated a tight implant-bone interface (Fig. 3A-C). A total number of 118 (TE) and 183 (control group, see Stricker et al. 2003) ITI implants (Straumann AG, Waldenburg, Switzerland) were inserted into the grafted areas (Table 1).

	simultaneous lift and implantation	first lift, later implant	total number of implants
Oral Bone	54	64	118
autologous bone	48	135	183

Table 1: Number of inserted dental Implants

All patients could be provided with fixed prosthetic rehabilitation like either crowns and bridges or dentures. The biopsies taken during the two-way protocol revealed mineralized trabecular bone with remnants of biomaterial (Fig. 3). Osteocytes were apparent within the bone lacunae. In seven patients of the two-stage protocol group and in 17 patients if the one-stage procedure, an excellent clinical, radiological, and histological result could be proved 3 months after augmentation. In comparison to the initial situation, the clinical inspection showed a good formation of new bone without signs of resorption. This was confirmed by radiological imaging (Fig. 4)(Zizelmann et al., 2007). In 10 patients (16 Sinus) of the two-stage protocol group the biopsies showed that the grafts had turned into a clinically appearing connective tissue-like consistency. In seven of these patients the situation was complicated by infection (Table 2).

	simultaneous lift and implantation	first lift, later implant	total number of implants
Total	18	17	35
2nd lift necessary	1	10	11

Table 2: Comparison of two different techniques of application of tissue engineered bone

The relation of augmentation procedures with BioSeed® -Oral Bone to infections as for example sinusitis and abscess is highly significant ( $p=0,000$ ). All these cases required an additional augmentation procedure with autologous bone and bone substitutes. Only one patient of the control group which had been operated on just with autologous bone required secondary surgery (Fig. 5). Also no infection was seen in this group. The loss of augmented material is significantly higher in the group in which the tissue engineered material was applied ( $p=0,000$ ) (Fig. 6AB).

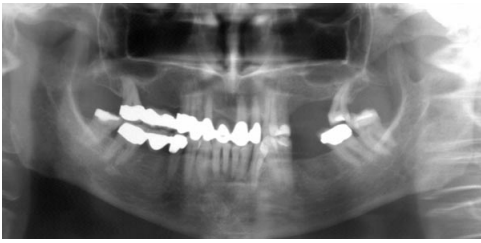


Fig. 4a: Orthopantomogram of a 56-year-old patient with an atrophy of the left maxilla

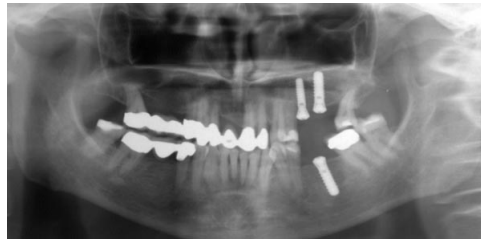


Fig. 4b: Postoperative radiograph after simultaneous augmentation and implantation

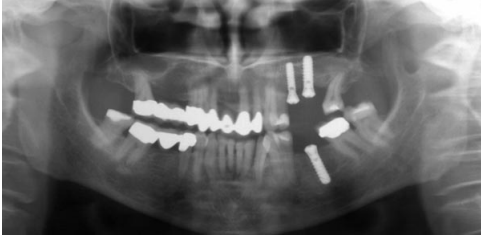


Fig. 4c: 3 months later, the augmented material demonstrates beginning mineralization

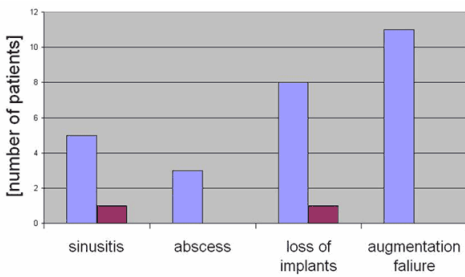


Fig. 5: Box-plot showing the complication in sinus-elevation procedures in absolute numbers of patients. The blue bars indicate the oral bone. The pink bars symbolize autologous bone.

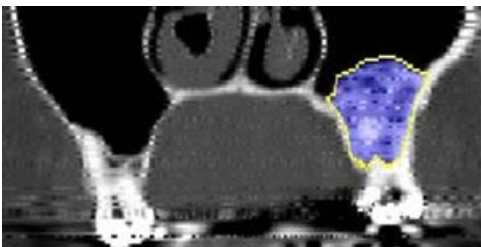


Fig. 6a: Sinus floor augmentation after three months. CT-scan of a patient from the control group which was treated with autologous cancellous bone from the iliac crest

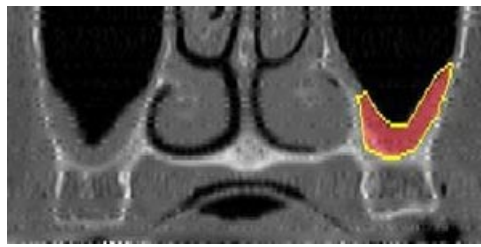


Fig. 6b: CT-image of a patient treated with periosteum derived tissue engineered bone

## Conclusions

Our experiences from this pilot study with tissue engineered bone transplants reveal the necessity to limit the indications for tissue engineered bone. Its application is restricted to the sinus augmentation with simultaneous implant insertion at sites providing a sufficient bone bearing. These techniques are a new approach in hard tissue-impairment therapy and were applied in the region of the jaw and the face for the first time. To improve long term results modifications in the field of cell cultivation and carrier materials and a better understanding of the physiological part of the healing process are necessary.

## Literature

1. Boyne, P.J., James, R.A. (1980) Grafting of the maxillary sinus floor with autogenous marrow and bone. *Journal of Oral Surgery*. 38: 613-616.
2. Perka, C., Schultz, O., Spitzer, R.S., Lindenhayn, K., Burmester, G.R., Sittinger, M. (2000) Segmental bone repair by tissue-engineered periosteal cell transplants with bioresorbable fleece and fibrin scaffolds in rabbits. *Biomaterials* 21: 1145-1153.

- Sauerbier, S., Gutwald, R., Wiedmann-Al-Ahmad, M., Lauer, G., Schmelzeisen, R. (2006) Clinical Application of tissue engineered Transplants - Part I: Mucosa. Clin Oral Implants Res. 17: In press.
- Stricker, A., Voss, P.J., Gutwald, R., Schramm, A., Schmelzeisen, R. (2003) Maxillary sinus floor augmentation with autogenous bone grafts to enable placement of SLA-surfaced implants: preliminary results after 15-40 months. Clin Oral Implants Res. 14(2): 2007-12
- Zizelmann, C., Schoen, R., Metzger, M.C., Schmelzeisen, R., Schramm, A., Gellrich, N.C. (2007) Bone formation after sinus augmentation with engineered bone. Clin Oral Implants Res. accepted for publication

This Poster was submitted by Dr. med. Sebastian Sauerbier.

**Correspondence address:**  
 Dr. med. Sebastian Sauerbier  
 Department of Maxillofacial Surgery  
 University Hospital Freiburg  
 Hugstetter Str. 55  
 79106 Freiburg

**Poster Faksimile:**



## Sinus Augmentation with Periosteum derived Tissue Engineered Bone

S. Sauerbier<sup>1</sup>, P. Voss<sup>1</sup>, N. Weyer<sup>1</sup>, J. Kuschnierz<sup>1</sup>, C. Zizelmann<sup>1</sup>, R. Schön<sup>1</sup>, R. Gutwald<sup>1</sup>, R. Schmelzeisen<sup>1</sup>

<sup>1</sup> Department of Oral and Craniomaxillofacial Surgery, University Hospital Freiburg, Freiburg, Germany



**Introduction**

Tumors in the oral cavity cause loss of bone and soft tissue (Sauerbier et al., 2006). More often than the reconstruction of soft tissue the improvement of the hard tissue bearing of dentures and dental implants is required. For the reconstruction of bone defects the gold standard is still the autologous bone harvested from the iliac crest, the mandible or the maxilla. Tissue-engineering procedures for hard tissue augmentations of the maxilla offer significant advantages compared with conventional grafts, as there is minimal or no donor site morbidity, limited availability of bone and the necessity of an additional surgical procedure. Periosteum has been demonstrated to have cell populations, which include chondrogenic and osteogenic cells, that can be isolated in tissue culture and form both cartilage and bone. The aim of this prospective study was to evaluate the feasibility of the clinical application of periosteum derived tissue engineered bone.

**Materials and Methods**

Periosteal cells were isolated from a biopsy of periosteum of the mandibular angle carried out as an outpatient protocol under local anaesthesia (Fig. 1). The transplants were prepared as described by Perka et al. (2000). After four passages the periosteal cells were trypsinized and subsequently resuspended in DMEM/Ham's F12 (1:1) medium and mixed with human fibrinogen (3.1, TissueCoil, Baxter, Vienna, Austria). The cell suspension was soaked into polymer fleeces (Ethicon, Norderstedt, Germany) and by adding bovine thrombin polymerized (TissueCoil, Baxter, Vienna, Austria) diluted in PBS (1:10). Subsequently, cell polymer transplants were cultivated for 1 week in DMEM/Ham's F12 (1:1) medium, supplemented with 5% autologous patient serum, ascorbic acid (50 mg/l), dexamethasone (10<sup>-8</sup> M) and β-glycerolphosphate (10 mM). Eight weeks after harvesting the periosteal grafts, the transplantation was performed in combination with a sinus lift as described by Boyne and James (1980). The tissue-engineered autologous bone was placed and condensed into the depth of the sinus cavity (Fig. 2). The control group underwent the same procedure except that autologous cancellous bone from the iliac crest was used instead of tissue engineered bone substitute. Turkey's Canceled Range Test and the Mann-Whitney-Test were used for statistical evaluation.

**Results**

Periosteal harvesting from the mandibular angle via an intraoral approach under local anaesthesia was tolerated well by the patients, and throughout the complete procedure no complications occurred. The wounds resulting from replantation of the engineered tissue healed without complications. The implants were inserted into the grafted areas. When the implant was inserted primary stability was tested and proven clinically. Radiographs demonstrated a tight implant-bone interface (Fig. 3A-C). A total number of 118 (TE) and 183 (control group, see Stricker et al. 2003) ITI implants (Straumann AG, Waldenburg, Switzerland) were inserted into the grafted areas (Table 1). All patients could be provided with fixed prosthetic rehabilitation like either crowns and bridges or dentures.

The biopsies taken during the two-way protocol revealed mineralized trabecular bone with remnants of biomaterial (Fig. 3). Osteocytosis were apparent within the bone lacunae. In seven patients of the two-stage protocol group and in 17 patients if the one-stage procedure, an excellent clinical, radiological, and histological result could be proved 3 months after augmentation. In comparison to the initial situation, the clinical inspection showed a good formation of new bone without signs of resorption. This was confirmed by radiological imaging (Fig. 4)(Zizelmann et al., 2007). In 10 patients (16 Sinus) of the two-stage protocol group the biopsies showed that the grafts had turned into a clinically appearing connective tissue-like consistency. In seven of these patients the situation was complicated by infection (Table 2). The relation of augmentation procedures with BioSeed®-Oral Bone to infections as for example sinusitis and abscess is highly significant (p=0,000). All these cases required an additional augmentation procedure with autologous bone and bone substitutes. Only one patient of the control group which had been operated on just with autologous bone required secondary surgery (Fig. 5). Also no infection was seen in this group. The loss of augmented material is significantly higher in the group in which the tissue engineered material was applied (p=0,000) (Fig. 6A).







**Fig. 5:** Bar chart showing the comparison of sinus elevation procedures in diverse numbers of patients. The bar chart indicates the one bone. The pink bars represent autologous bone.

Procedure	Autologous Bone	TE Bone
Autologous Bone	50	50
TE Bone	45	10

**Table 1:** Number of inserted dental implants

Procedure	ITI Implants	Total Number of Implants
Autologous Bone	183	183
TE Bone	118	118
Total	291	291

**Table 2:** Comparison of two different techniques of application of tissue engineered bone

Procedure	ITI Implants	Total Number of Implants
Autologous Bone	183	183
TE Bone	118	118
Total	291	291

**Discussion**

Our experiences from this pilot study with tissue engineered bone transplants reveal the necessity to limit the indications for tissue engineered bone. Its application is restricted to the sinus augmentation with simultaneous implant insertion at sites providing a sufficient bone bearing. These techniques are a new approach in hard tissue-impairment therapy and were applied in the region of the jaw and the face for the first time. To improve long term results modifications in the field of cell cultivation and carrier materials and a better understanding of the physiological part of the healing process are necessary.

**References:**

Boyne, P.J., James, R.A. (1980) Grafting of the maxillary sinus floor with autogenous marrow and bone. *Journal of Oral Surgery*, 38: 613-616

Perka, C., Schulz, D., Spatz, R.S., Lindnerhayn, K., Bunnmeister, G.R., Sillinger, M. (2000) Segmental bone repair by tissue-engineered periosteal cell transplants with bioresorbable fleece and fibrin scaffolds in rabbits. *Biomaterials* 21: 1165-1173

Sauerbier, S., Gutwald, R., Wiedmann-Al-Ahmad, M., Lauer, G., Schmelzeisen, R. (2006) Clinical Application of tissue engineered Transplants - Part I: Mucosa. *Clin Oral Implants Res.* 17: In press.

Stricker, A., Voss, P.J., Gutwald, R., Schramm, A., Schmelzeisen, R. (2003) Maxillary sinus floor augmentation with autologous bone grafts to enable placement of SLA-surfaced implants: preliminary results after 15-40 months. *Clin Oral Implants Res.* 14(2): 2007-12

Zizelmann, C., Schoen, R., Metzger, M.C., Schmelzeisen, R., Schramm, A., Gellrich, N.C. (2007) Bone formation after sinus augmentation with engineered bone. *Clin Oral Implants Res.* accepted for publication

contact: sebastian.sauerbier@uniklinik-freiburg.de

