

## Lymphangioma - An Advanced Imaging Study

**Language:** English

**Authors:**

Prof Dr. Mahima V. G., Prof. Dr Karthikeya Patil, Dr Anudeep Raina, PG Student, Dr Ekta Pai, PG Student, J.S.S University, Mysore Department of Oral Medicine and Radiology, J.S.S Dental College and Hospital, Karnataka, India

**Date/Event/Venue:**

July 9th-10th, 2010

National OOO Symposium 2010

Vokkaligara Sangha Dental College and Hospital, Bangalore, India

Poster Award

Best Poster Award

### Introduction

Lymphangioma is the most common cervicothoracic mass in children; however such lesions have seldom been reported in adults. These tumors when massive, tend to surround and invade normal anatomic structures leading to bizarre complications. Several imaging modalities are used to study lymphangiomas including plain radiography, Ultrasonography, Computed Tomography (CT), Magnetic Resonance Imaging (MRI) and Nuclear Medicine. In addition to these, Computed Tomography Angiography (CTA) is a practical alternative for the assessment of vascular involvement.

### Case report

A 50 year old female reported with a chief complaint of a gradually progressive swelling in the right submandibular and submental region extending to the neck bilaterally of 7 years duration. Clinical examination revealed a massive cervicomandibular mass that was non tender and soft in consistency. Fragment mobility of the right mandible distal to the canine tooth was noted on palpation intraorally. A provisional diagnosis of a lymphangioma was considered. An orthopantomograph showed extensive resorption of the inferior border of the mandible predominantly affecting the right side. Ultrasonography revealed extensive thin walled cervicomandibular hypochoeic mass lesions. Computed tomography angiography divulged an irregular hypodense cystic non enhancing lesion involving soft tissues of the neck with no evident feeding arteries and/or draining veins. Magnetic resonance imaging study of the neck depicted hyperintense T2 weighted and isointense T1 weighted lesions. Fine needle aspiration cytology and biopsy from the submandibular mass was suggestive of lymphangioma. Treatment comprised of hemimandibulectomy and surgical excision of the entire submandibular mass. No surgical intervention for the cervical masses was instituted due to their proximity to adjacent vital structures. The patient has been kept under observation for the same.

### Conclusion

An adult lymphangioma of such an extensive nature is a very rare entity and may give rise to a multitude of complications. Advanced imaging modalities are vital tools in delineating the nature and extent of the lesion thereby facilitating diagnosis and treatment planning of lymphangiomas as illustrated.

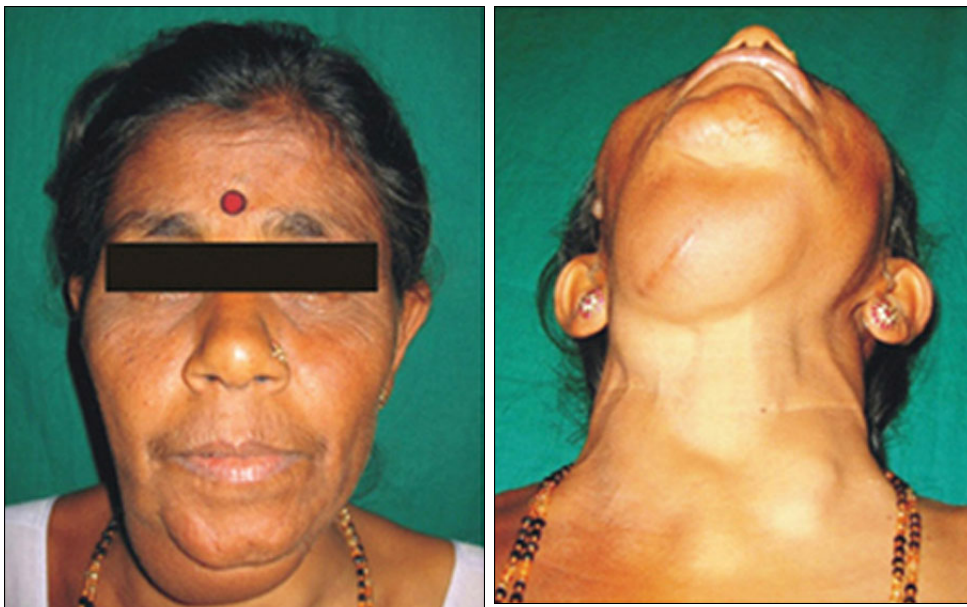

Fig. 1-2: Extraoral massive cervico - mandibular swelling

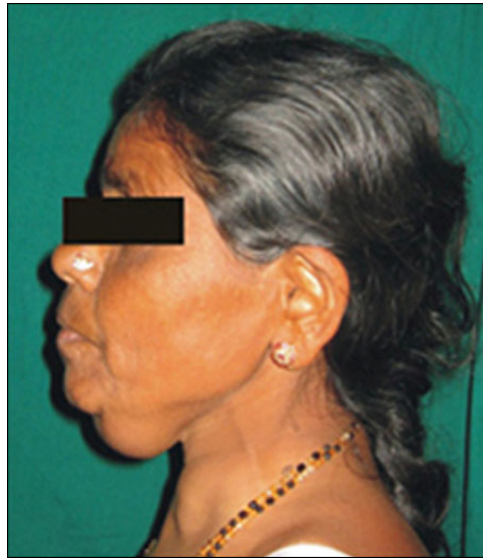
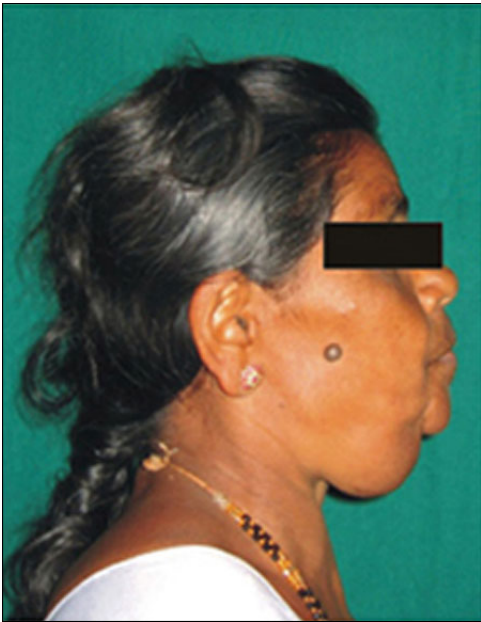
Fig. 3-4: Extraoral massive cervico - mandibular swelling

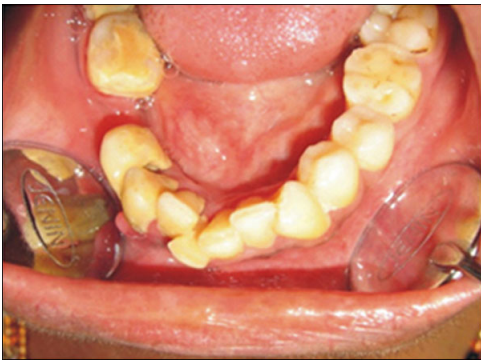

Fig. 5: Intraoral - No evident pathology

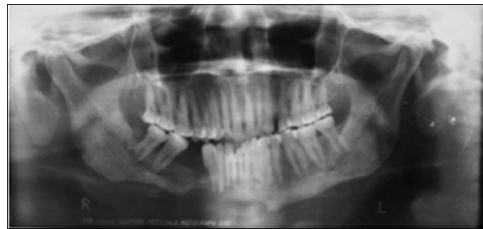

Fig. 6: OPG - Extensive resorption inferior border mandible

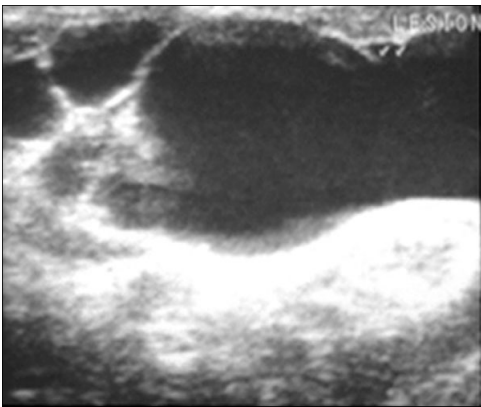


Fig. 7: Ultrasound - Extensive cystic lesion

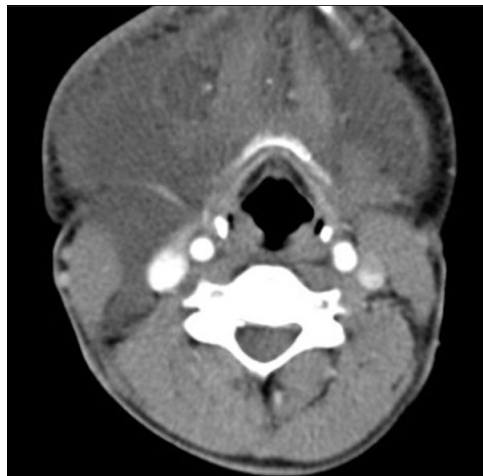

Fig. 8: CT angiogram - Large ill defined hypodense areas without enhancement

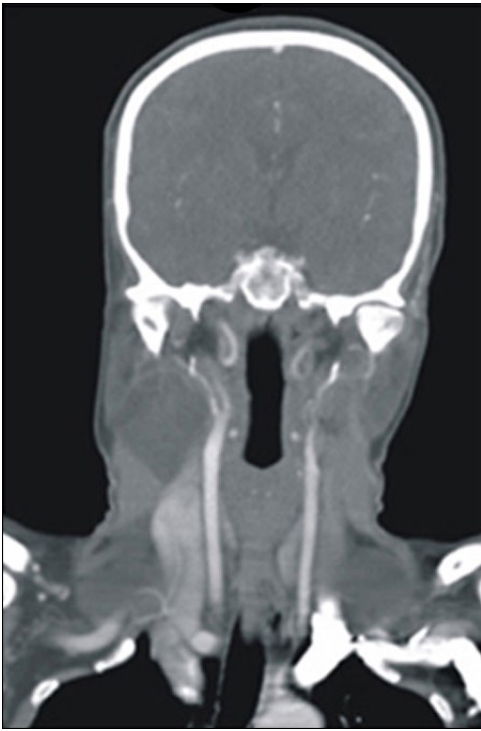


Fig. 9: CT angiogram - Large ill defined hypodense areas without enhancement

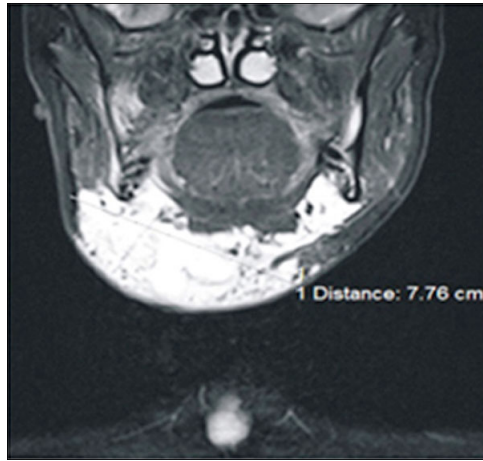


Fig. 10: MRI - Lobulated T2 hyperintense areas, thin septae

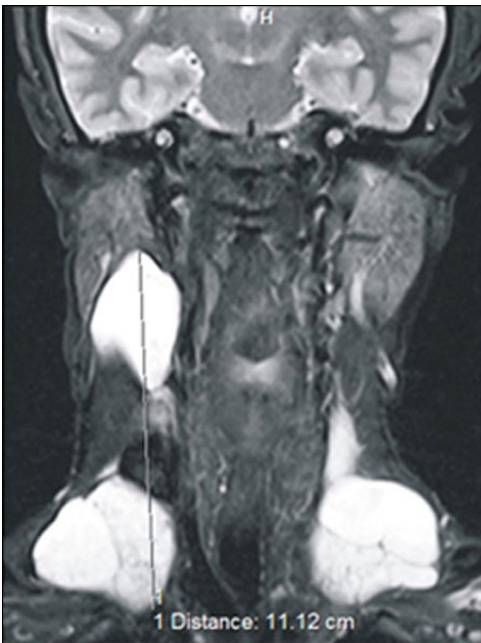


Fig. 11: MRI - Lobulated T2 hyperintense areas, thin septae

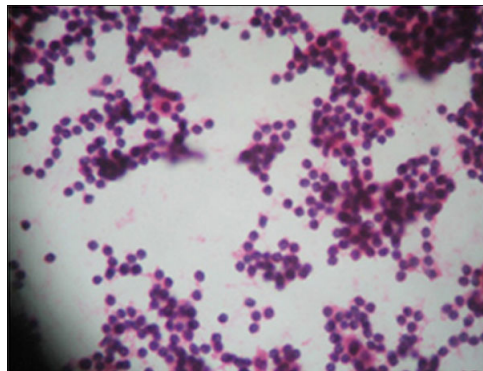


Fig. 12: FNAC - clusters of small lymphocytes

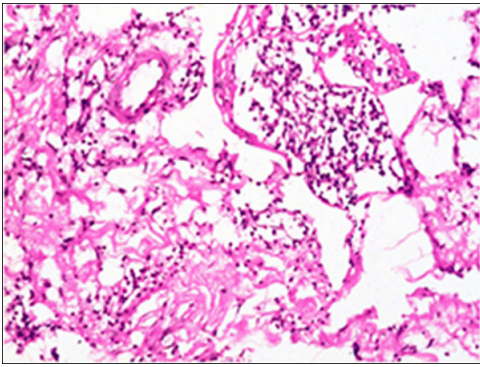


Fig. 13: Biopsy - Numerous thin walled vascular channels and aggregates of lymphocytes

This Poster was submitted by Prof Dr. Mahima V. G..


**Correspondence address:**

Prof Dr. Mahima V. G.  
 JSS Dental College and Hospital  
 J.S.S University, Department of Oral Medicine and Radiology  
 SS Nagar, Mysore - 570 015, Karnataka  
 India


**Poster Faksimile:**

## LYMPHANGIOMA – ADVANCED IMAGING STUDY


Lymphangiomas are benign congenital malformations of the lymphatic system resulting from sequestration or obstruction of developing lymphatic vessels that tend to surround and invade normal anatomic structures. They occur most commonly in children and are rare in adults. Advanced imaging is an essential aid in establishing an accurate diagnosis in order to facilitate appropriate management strategies.



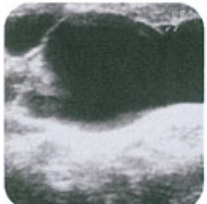
EXTRAORAL MASSIVE CERVICO-MANDIBULAR SWELLING



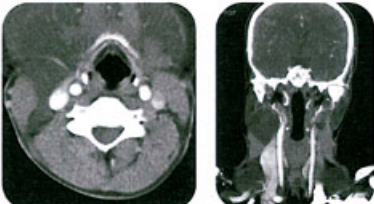
INTRAORAL – NO EVIDENT PATHOLOGY



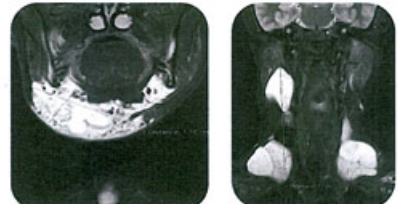
OPG - EXTENSIVE RESORPTION INFERIOR BORDER MANDIBLE



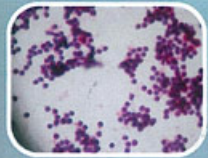
ULTRASOUND-EXTENSIVE CYSTIC LESION



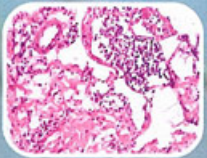
MRI-LOBULATED T2 HYPERINTENSE AREAS, THIN SEPTAE



CT ANGIOGRAM - LARGE ILL DEFINED HYPODENSE AREAS WITHOUT ENHANCEMENT



FNAC - CLUSTERS OF SMALL LYMPHOCYTES



BIOPSY - NUMEROUS THIN WALLED VASCULAR CHANNELS AND AGGREGATES OF LYMPHOCYTES