

USE OF CAD-CAM IN DENTISTRY TO RESTORE BADLY DECAYED TOOTH

Dr. Satheesh B Haralur, Ali Hassan AL-Faifi,
College of Dentistry, King Khalid University

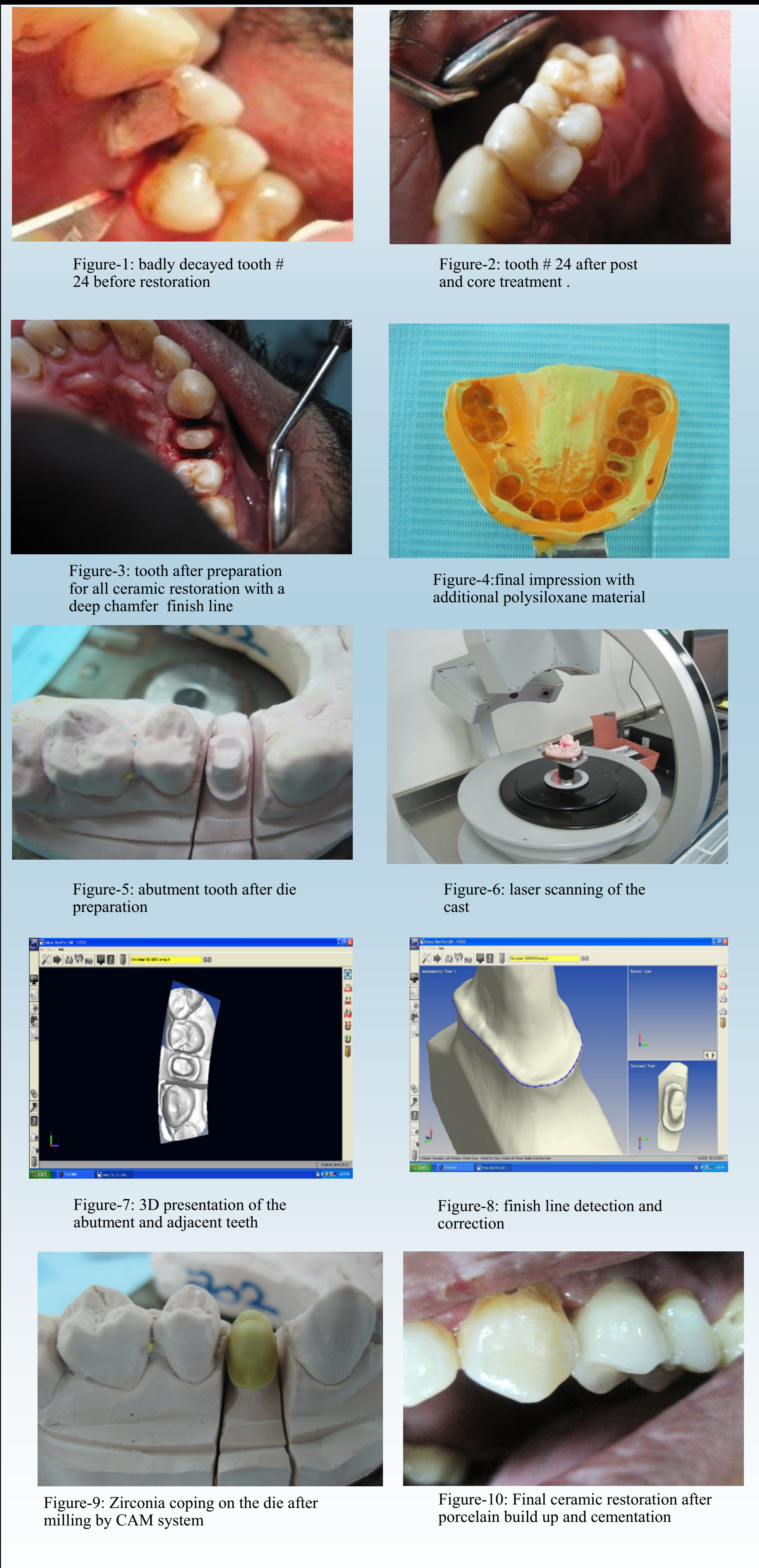
INTRODUCTION :

Computer aided design-computer aided manufacturer (CAD-CAM) is used widely in manufacturing industry for faster and precise production of components. Even though CAD-CAM was introduced to dentistry in mid-1980, only recently it has gained its popularity and widely accepted as important restorative alternative. CAD-CAM technology is successfully utilized in dentistry for the fabrication of inlays, onlays, crowns and bridges¹. This technology helps in manufacturing the restorations with high precision and accuracy. This results in better adaptation and esthetics of restorations.

Preservation of natural teeth is of paramount importance for many reasons including, integrity of arch, masticatory efficiency, esthetics, phonetics and most importantly for psychological well-being of the individual. For any restoration to be categorized as successful, it should not only satisfy the biomechanical needs but also esthetic need of patient²

CASE SUMMARY :

32year old male patients presented to our dental clinic with badly decayed upper left first premolar tooth. The caries involvement of pulp was confirmed with intraoral radiograph, which also confirmed the chronic apical periodontitis. Remaining anatomic crown structure was less than 40%.



Yttrium-stabilized zirconium dioxide coping instead of metal for all ceramic crowns in high stress areas is used successfully in recent years³. CAD-CAM is used for the fabrication of Zirconia copings.

This alternative provides the patient with strong, better adapted, highly esthetic restoration for the patients

This case provided two challenges for all ceramic restoration; it had insufficient tooth structure and also was in high stress area. To overcome these shortcomings, tooth was reinforced to improve its retention and support of post-endodontic crown. This was provided with glass reinforced fiber post and core build up. Zirconia coping was selected instead of alumina coping to help in sustaining the expected high stresses in premolar region.

CONCLUSION :

Proper, intelligent use of materials and technology should be utilized for the benefit of the patient. Use of zirconia and CAD-CAM will help in saving many compromised tooth. This provides the patient a chance to have restorations, which are bio mechanically superior as well as with pleasing esthetics.

REFERENCES :

- 1.Fernando Zarone,Simona Russo,Roberto Sorrentino :From porcelain-fused-to-metal to zirconia: Clinical and experimental considerations.Dent Mater 2010 Nov:26
- 2.Wassell RW, Walls AW, Steele JG. :Crowns and extra-coronal restorations: materials selection..Br Dent J. 2002 Feb 23;192