

Clinical Efficiency and Patient Preference of Immediate Digital Impression after Implant Placement for Single Implant-Supported Crown

Dan Ni GUO¹, Yu Shu LIU¹, Shao Xia PAN¹, Peng Fei WANG², Bing WANG², Jian Zhang LIU¹, Wen Hui GAO², Yong Sheng ZHOU¹

Objective: To evaluate the time efficiency and patient preference of three impression techniques by comparing immediate digital impression performed directly after implantation with regular digital impression and conventional implant impression performed 3 months after implantation.

Methods: Twenty consecutive patients with a missing single molar or premolar who received implant treatment were recruited into this prospective self-controlled clinical trial. Three different impression techniques were performed after implant surgery on all the participants: An intraoral scanning (IOS) impression performed immediately after implant placement (immediate digital impression) was compared with a regular digital impression and a classic polyether impression (conventional implant impression) performed 3 months after implant surgery. The operating time of each impression technique was recorded. Patients were asked to complete a visual analogue scale (VAS) questionnaire on their perception of the three techniques to describe their satisfaction and preference. Statistical analyses were performed with the Wilcoxon signed rank test.

Results: The clinical time of the immediate digital impression (10.97 ± 2.1 min) was significantly shorter than that of the conventional implant impression (14.45 ± 3.0 min) ($P < 0.05$). The mean time of the immediate digital impression (10.97 ± 2.1 min) was statistically the same as that of the regular digital impression (10.23 ± 2.7 min) ($P > 0.05$). Participants' subjective evaluation indicated higher satisfaction with the immediate digital impression than with the regular digital impression and the conventional implant impression.

Conclusion: The immediate digital impression was more efficient than the conventional implant impression and had the same efficiency as the regular digital impression. Among the three impression techniques, the participants showed higher satisfaction with the immediate digital impression.

Key words: impression, digital, dental implant, computer-aided design/computer-aided manufacturing (CAD/CAM)

Chin J Dent Res 2019;22(1):21–28; doi: 10.3290/j.cjdr.a41771

1 Department of Prosthodontics, Peking University School and Hospital of Stomatology, National Clinical Research Center for Oral Diseases, National Engineering Laboratory for Digital and Material Technology of Stomatology, Beijing Key Laboratory of Digital Stomatology, Beijing, P.R. China.

2 Dental Laboratory, Peking University School and Hospital of Stomatology, National Clinical Research Center for Oral Diseases, National Engineering Laboratory for Digital and Material Technology of Stomatology, Beijing Key Laboratory of Digital Stomatology, Beijing, P.R. China.

Corresponding author: Dr Shao Xia PAN, Department of Prosthodontics, 22# Zhongguancun South Avenue, HaiDian District, Beijing 100081, P.R. China. Tel: 86 13011110951; Fax: 86 10 62173402. Email: panshaoxia@vip.163.com

Implant therapy has been accepted as a regular treatment option for restoring a single posterior missing tooth¹. Nowadays, the advancement of computer-aided design/computer-aided manufacturing (CAD/CAM) technology has made it possible to provide patients with implant prostheses of a similar or even superior precision through a more comfortable full digital workflow compared with a conventional workflow². Joda and Bragger³ conducted a study to analyse the full digital workflow for single-implant crowns. It was found that a digital technique minimized the need for the clinical adjustment of restorations compared with an analogue technique. A full

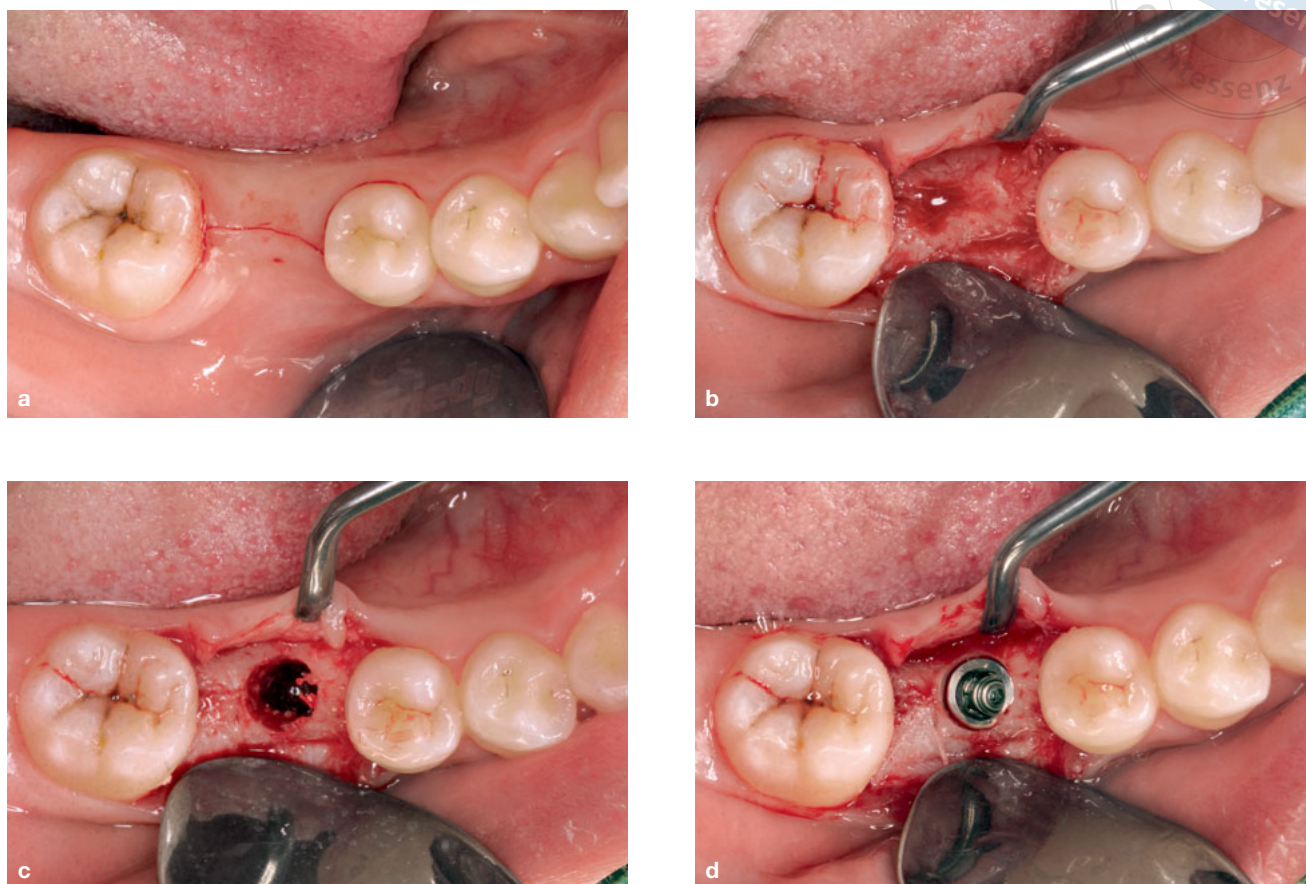


Fig 1 Implant placement. (a) Oral situation before surgery; (b) Raising a mucosal flap; (c) Preparing the implant site; (d) Implantation.

digital workflow without a physical model reduces errors, integrating and assuring a comparable or even higher precision of restoration manufacturing⁴. With a digital technique, patients can avoid being exposed to uncomfortable procedures such as direct contact with impression materials; this tends to affect patient preference^{2,5}.

As the first step in a full digital workflow for implant prostheses, a digital impression taken with an intraoral scanner and scan body plays an important role. The implant position and oral condition can be recorded using an intraoral scanning (IOS) technique. Several studies have shown the advantages of direct digital impression technology accomplished by IOS; namely, less chair time, a more stress-free procedure, and higher patient satisfaction^{2,6}. In addition, the data from IOS impressions can be easily stored, transmitted and reused. Nevertheless, IOS techniques depend on expensive IOS devices, the fit of the scan body⁷ and the dentist's skill⁸. Another disadvantage of IOS is that the digital impression accuracy and fit are clinically acceptable for single crowns and short fixed dental prostheses (FDPs) but not for full-arch FDPs⁹.

Most current studies have focussed on the efficacy and efficiency of IOS digital impressions in the conventional implant prosthetic procedure, i.e. a regular IOS impression procedure conducted 3 months after implantation. Several studies have compared the efficiency and patient preference of conventional as opposed to digital impressions. Wismeijer et al¹⁰, Schepke et al¹¹ and Joda et al¹² all showed that digital impressions had a shorter operating time and higher patient satisfaction.

For single posterior implants with enough primary stability, an immediate digital impression taken right after implant surgery can further simplify the treatment procedure and take advantage of the precise mechanical structure of the implant system and the convenience of the digital workflow. Tian et al¹³ concluded that it was feasible to fabricate interim crowns after immediate implantation in one single visit with an immediate IOS impression and a full digital workflow. Beuer et al¹⁴ reported a case in which a single molar was restored successfully using immediate digital impression. However, these authors did not compare the efficiency of the immediate IOS impression with that of a

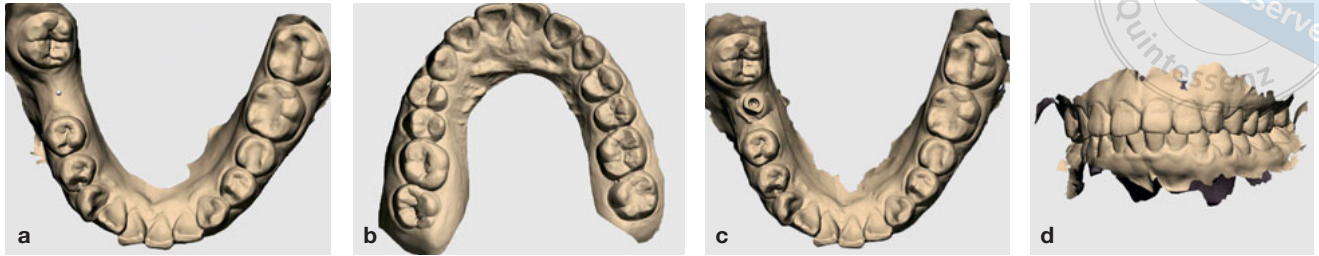


Fig 2 First IOS digital impression. (a) Mandible; (b) Maxilla; (c) Implant scan; (d) Occlusion.

conventional implant impression. There are few studies in the literature regarding immediate IOS right after implantation. The surgery procedure and fluid exposure may increase the difficulty of IOS and prolong chair time. Therefore, the clinical feasibility, efficiency and patient satisfaction of the immediate digital impression need to be evaluated.

The objective of this *in vivo* clinical trial was to evaluate the efficiency and patient preference of immediate digital impression compared with regular digital impression and conventional implant impression 3 months after implantation.

Materials and methods

Participants

A prospective, self-controlled clinical study was conducted in the Department of Prosthodontics, Peking University School and Hospital of Stomatology, for which 20 patients (45% males) with a mean age of 41.4 years with a missing molar or premolar were recruited.

The inclusion criteria included:

- older than 18 years of age at the time of implant surgery;
- single tooth missing at least 3 months before date of implant surgery;
- sufficient bone height and width at implantation site;
- enough prosthetic space;
- adequate oral hygiene;
- willingness to participate in the clinical trial.

The exclusion criteria included:

- patients with local and/or systemic contraindication for implantation (uncontrolled diabetes, haemophilia, metabolic bone disorder, history of renal failure, radiation treatment to the head or neck region, current chemotherapy and pregnancy);
- smoking more than 10 cigarettes per day;
- severe bruxism.

This study was approved by the Institutional Review Board of Peking University School and Hospital of Stomatology (Ethical approval No. PKUSSIRB-201630094) and was registered in the Chinese Clinical Trial Registry (ChiCTR) (ChiCT No. INR-17014092). All participants signed an informed consent form.

Study design

Each participant received a single implant restoration (Straumann Bone Level, Institut Straumann AG, Basel, Switzerland). For each patient, three impression techniques were performed, as follows: an immediate IOS impression taken directly after implant placement (1st IOS), a regular IOS digital impression (2nd IOS) and a conventional implant impression taken 3 months after implant placement. The working time and patient preference for each impression technique were recorded.

Implant surgery procedure

Before implant surgery, an oral examination and a cone beam computed tomography (CBCT) scan (NewTom VGi, NewTom, Italy) were performed. Under local anaesthesia, a full-thickness flap was raised with a crestal incision and a sulcular incision on the neighbouring tooth. An implant was placed at the planned position (Fig 1) with enough primary stability (torque ≥ 35 Ncm). The guided bone regeneration (GBR) technique was not used for any of the patients.

Immediate IOS digital impression

For the immediate digital impression, the intraoral situations including the adjacent teeth, opposite arch and occlusal registration were digitized with an intraoral scanner (Trios 1, 3Shape Trios Standard-P11, 3Shape A/S, Copenhagen, Denmark) before surgery (Fig 2). The software version 2014-1 (release 1.3.4.7) was used. Complete-arch scans were taken without any contrast powder for each patient. Before IOS, the scanner was

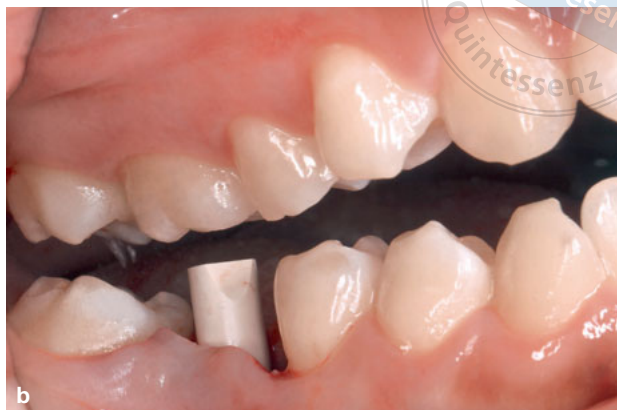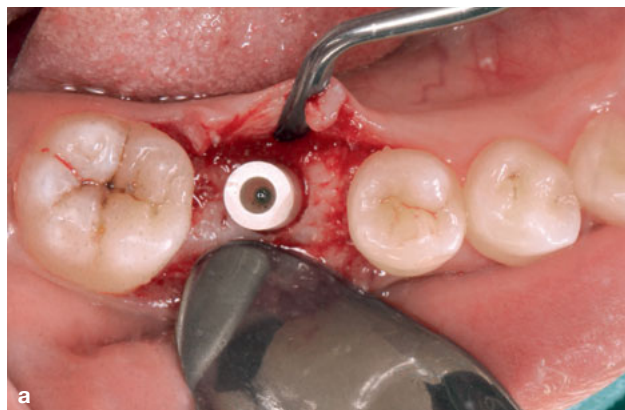


Fig 3 Scan body placement. **(a)** Occlusal; **(b)** Buccal.

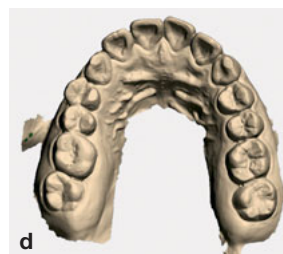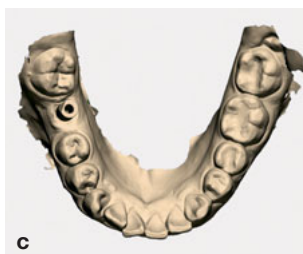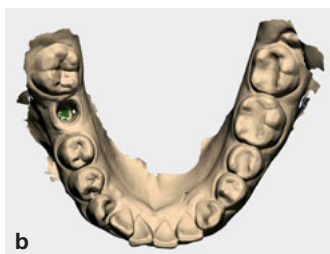


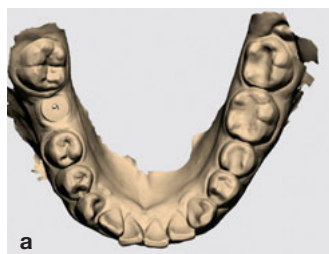Fig 4 Second IOS digital impression. **(a)** Mandible; **(b)** Emergency profile; **(c)** Scan body; **(d)** Maxilla.

calibrated following the manufacturer’s instructions. After implantation, a scan body (Straumann BL RC, Institut Straumann AG) was screwed into the implant. The flap was then sutured with 5-0 Prolene (Johnson & Johnson, New Brunswick, New Jersey, US). Direct digitalization of the implant position was scanned with and IOS technique (1st IOS) (Fig 3). The scan body was removed after scanning and a healing cap was screwed back into the implant.

The regular IOS and conventional implant impression

After 3 months, a second digital impression (2nd IOS) was taken, after the completion of implant osseointegration. The healing abutment was removed and the scan body (Straumann BL RC) was screwed into place. A complete-arch digital impression, including the arch with implant, antagonistic dentition and interocclusal record, was performed by the same dentist (Fig 4). Then, at the same appointment, a conventional implant impression was also taken with the close-tray approach using polyether material (Impregum Penta, 3M ESPE GmbH, Neuss, Germany) and an implant transfer post (Strau-

mann BL RC). In addition, a high-viscosity alginate impression was taken for the opposite arch (Fig 5).

Outcome variables

Impression operating time was measured with a regular stopwatch (Loease, Zhongshan, China) in minutes and seconds for all the procedures (Table 1), respectively. After each impression, the healing cap was screwed back and the colour of the crown was determined. The time of all the clinical procedures was recorded on a time sheet.

Patients were asked to complete a visual analogue scale (VAS) questionnaire regarding their perception of the three techniques in order to describe their satisfaction and rate their preference¹⁵. A self-developed, eight-item questionnaire that referred to the relevant literature¹² was designed to evaluate patient satisfaction regarding the three impression methods. The first seven questions focussed on treatment time and the patients’ perception of the impression protocols with regard to overall convenience, anxiety, taste, nausea, difficulty breathing and the possible sensation of pain. To respond to the eighth question – “Which impression technique is

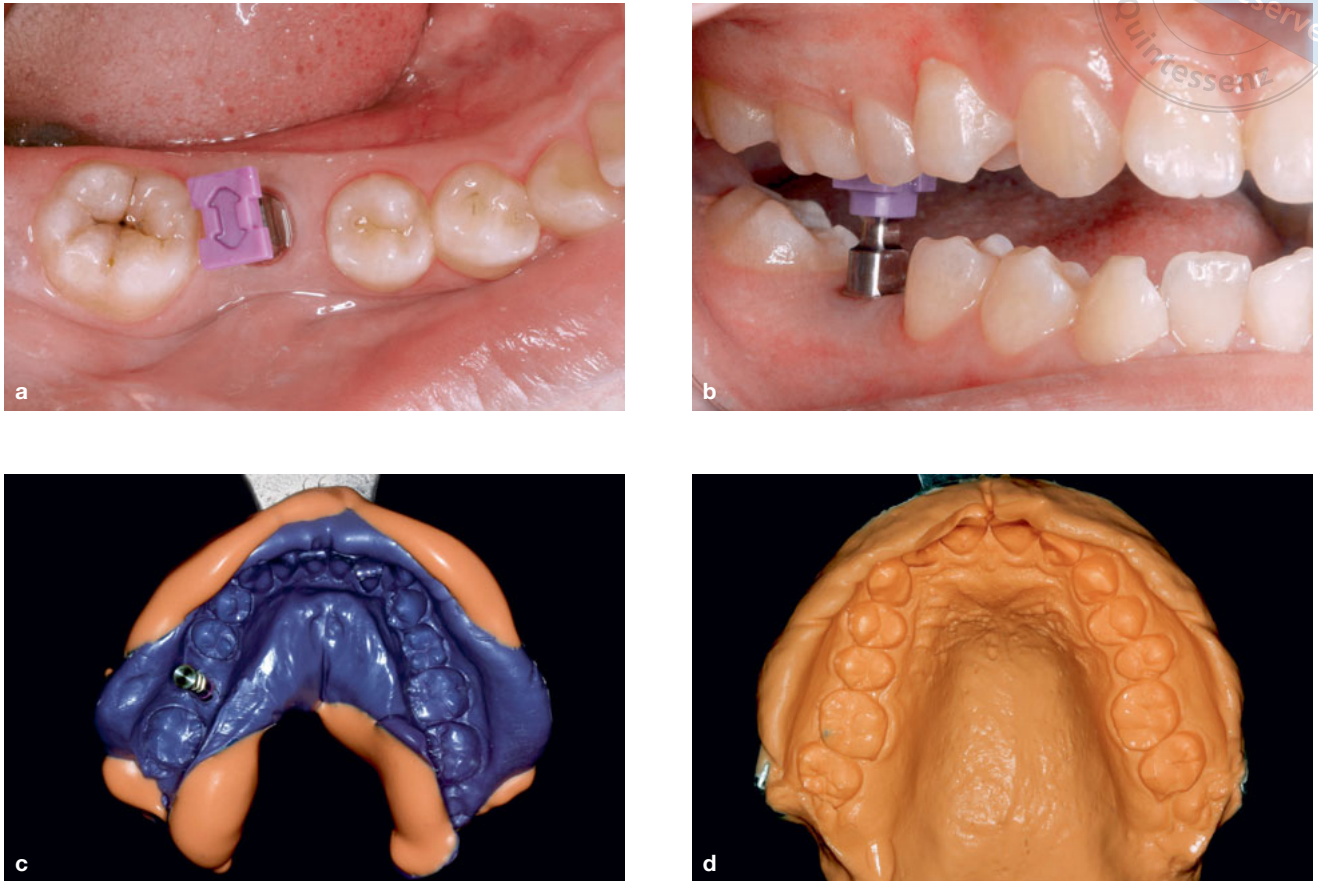


Fig 5 Conventional implant impression. (a) Occlusal; (b) Buccal; (c) Mandible; (d) Maxilla.

Table 1 Procedures of three impression techniques.

	1st IOS	2nd IOS	Conventional implant impression
Implant impression procedures	1. Insertion of scan body	1. Removal of healing cap	1. Tray selection
	2. IOS process*	2. Insertion of scan body	2. Removal of healing cap
	3. Removal of scan body	3. IOS process*	3. Insertion transfer post
	4. Insertion of healing cap	4. Removal of scan body	4. Impression taking#
	5. Colour determination	5. Insertion of healing cap	5. Removal of transfer post
		6. Colour determination	6. Insertion of healing cap
			7. Colour determination

* Intraoral scan process: adjacent teeth, implant site, opposite arch, occlusal registration.

Impression taking: implant site, adjacent teeth, opposite arch, occlusal registration.

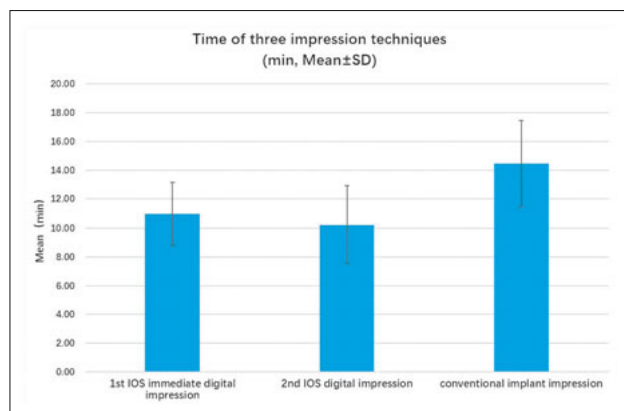


Fig 6 Mean time of three impression techniques. Immediate digital impression of 1st IOS (10.97 ± 2.1 min), regular digital impression of 2nd IOS (10.23 ± 2.7 min) and conventional implant impression (14.45 ± 3.0 min).

your favorite one?” – patients had to choose one of the three impression techniques or express an indifference towards them.

Each patient was asked to rate their satisfaction with each impression technique using a linear scale with two endpoints (ranging from “Very satisfied = 0” to “Not satisfied at all = 100”). For each impression technique, VAS ratings of the seven questions were expressed in a numerical format (ranging from 0 to 100). The total score was then calculated by adding up the seven scores.

The statistical analyses for ‘time’ and ‘patient satisfaction’ were analyzed using the Wilcoxon signed rank test. This nonparametric analysis was applied because the data were not normally distributed for all items. Paired sample *t* tests were used to compare the two groups after verification of normality. All data were statistically analyzed using the SPSS system (IBM SPSS Statistics v22; IBM Corp, Chicago, USA). A *P* value of < 0.05 was considered statistically significant.

Results

The mean time taken for the immediate digital impression (1st IOS) (10.97 ± 2.1 min) was statistically the same as that of the 2nd IOS (10.23 ± 2.7 min) ($P > 0.05$) and both were significantly shorter than that of the conventional implant impression (14.45 ± 3.0 min) ($P < 0.05$) (Fig 6).

The VAS scores of the first seven questions were independently compared among the three groups (Fig 7). Participants’ subjective evaluation indicated higher satisfaction with the 1st IOS (immediate digital impression) than with the 2nd IOS and the conventional implant impression in terms of convenience, working time,

anxiety, bad taste, nausea sensation, difficulty breathing, possible pain sensation and total. The scores of the 1st IOS and 2nd IOS reached a significantly higher level ($P < 0.05$) compared with the conventional implant impression, especially the score for nausea sensation.

Among the 20 patients, 17 showed a preference for the immediate digital impression technique (85%), and three expressed indifference regarding the impression methods.

Discussion

The results of this research showed that the chair time of the 1st IOS and 2nd IOS digital impressions was statistically shorter than that of the conventional implant impression.

The IOS technique is easier to carry out with only a scan body and an IOS device. It reduces the preparation time and workflow compared with a conventional implant impression procedure in terms of selecting and adjusting the impression tray, removing the healing abutment, inserting the transfer post, and waiting for the impression material to be mixed. Moreover, when the conventional implant impression has to be retaken, all the clinical procedures must be performed all over again. For a digital impression, a step-by-step scanning process is convenient for modifying and rescanning part of the dentition. The *in vitro* study by Lee and Gallucci¹⁶ showed that the time for a full-arch digital impression was 12 min 29 s on average, and that of a traditional impression was 24 min 42 s. Joda and Brägger¹² showed that the quadrant-like IOS time of a single implant and conventional implant impression was 14 min 8 s and 17 min 9 s, respectively. Similar research conducted by Schepke et al¹¹ reported that the time for a quadrant-like digital impression was 6 min 39 s on average, and that for a traditional impression was 12 min 13 s. Despite the fact that due to different timing standards there were differences in the results of the different clinical trials, all conclusions were the same, ie, that digital impressions were more efficient.

Compared with the total time of the 2nd IOS that took place 3 months after implantation, the 1st IOS took a bit longer on average. However, the difference is not significant. Reasons for this could be as follows: Firstly, a lower ambient temperature in the operating room resulted in an insufficient temperature of the scanning head, which may have influenced the IOS speed. A patient’s warm breath can result in foggy condensation on the reflection lens. The heating device automatically senses room temperature in order to heat the lens, and a lower room temperature will influence the drying

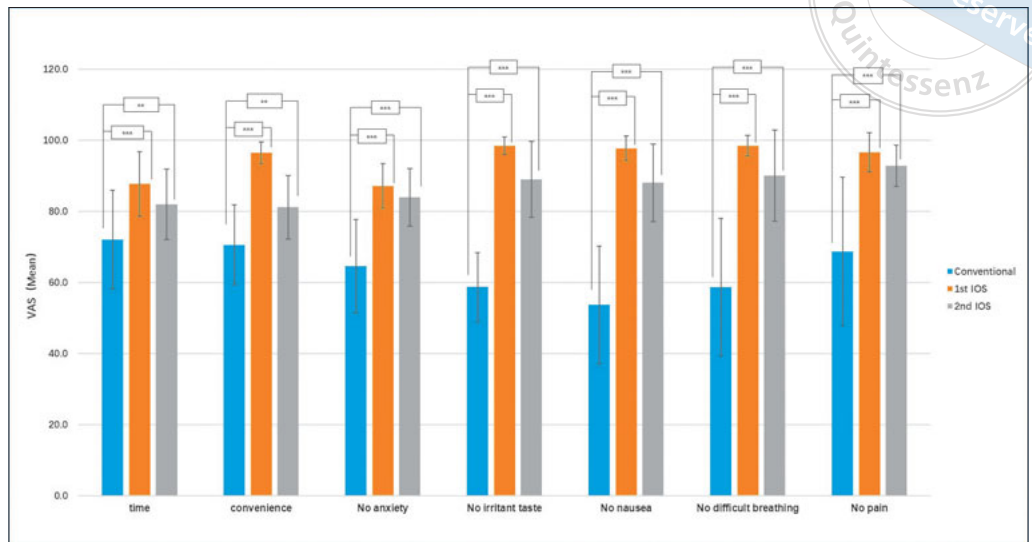


Fig 7 Patient-reported outcome (VAS) for the three impression techniques. Ratings of the first seven questions are shown (* $P < 0.05$, ** $P < 0.01$, *** $P < 0.001$).

process. Secondly, due to the large amount of saline for rinsing during the operation, as well as blood, there will be some liquid left on the surface of the adjacent teeth and mucosa in the surgical area. This liquid will result in refraction and reflection, which can influence the scanning speed. Thirdly, the graph stitching speed may also be influenced by the suture thread and morphology variation of the soft tissue, which may result in a longer IOS time. All these factors can contribute to the time taken to perform immediate IOS.


As the most important device during IOS, intraoral scanners may affect operating time and patient satisfaction. In recent years, many intraoral scanners have been introduced onto the market. Trios 1, which works on the principle of confocal microscopy and ultrafast optical scanning, is a powerful and fast¹⁷ structured light scanner. It does not require contrast powder¹⁸, so the patient's comfort is not affected. Trios 1 has a wand, which helps to push away unwanted soft tissue such as tongue, cheeks or lips¹⁹. As an open system, the data in Trios 1 can be exported to common stereolithography (.stl) files through the 3Shape CAD system. Furthermore, the Trios system has been used in many studies investigating the accuracy of different intraoral scanners^{18,19}. For these reasons, the Trios 1 was used as the scanner for the present study.

There have been an increasing number of research studies focussing on integrating a digital workflow into the implant restoration procedure to simplify the entire process and benefit both the patient and the clinician. Schnitman and Han²⁰ demonstrated that it was feasible to complete a maxillary anterior single-tooth implant restoration in two visits. Tian et al¹³ evaluated the viability of an immediate digital impression after

implantation for maxillary anterior single teeth. The present study on immediate digital impression provided some prerequisites for further research on final restoration design and manufacture. The results can provide reference points for clinical practice regarding the improvement of the complete digital workflow.

Digital technology not only changes treatment processes but also influences treatment experience and patient attitudes¹⁰. The results of the VAS questionnaire showed that patients prefer the digital impression technique²¹. Another advantage of the digital impression process is that it is easy to pause and resume it at any time. Also, the impression and digital model can be double-checked in one visit, reducing the risk of possible impression/model failure and saving time by eliminating the need for another clinical visit for impression retaking. Furthermore, there is no need to use a tray and a physical model, which eliminates workflow steps such as model pouring and disinfecting. Digital impressions mitigate patient discomfort such as unpleasant taste or nausea resulting from the impression material; the treatment experience is very comfortable. It is for these reasons that the participants in this study indicated greater satisfaction with the 1st IOS than the 2nd IOS.

Another potential benefit of an IOS digital impression is the possibility of the intervention occurring at the same time as the implant surgery. This shortens overall treatment time and reduces the number of necessary appointments. Also, the adjacent teeth and the implant site can be scanned separately, which improves patient satisfaction by minimizing the IOS difficulty and reducing the risk of pain or fatigue. Less difficulty means less scanning time, less discomfort and less irritation. Therefore, it is not surprising that 17 patients in the present study preferred



the immediate digital impression technique. With higher patient satisfaction and cooperation, IOS also becomes simpler and more efficient.

This study did not discuss the accuracy of the three impression techniques. Some *in vitro* investigations have demonstrated that the accuracy of an IOS digital impression can satisfy the clinical requirement of a single implant restoration. Lee et al²² reported that the accuracy of a digital milling model was acceptable for manufacturing clinical restorations. Koch et al⁴ found that the direct IOS digital impression had the lowest rate of error, while the milling model introduced a larger accumulated error. Moreira et al²³ pointed out that the accuracy of an IOS impression was up to 12.7 μm , reducing the accumulative errors of the complex procedure of conventional implant impressions.

Conclusion

The results of this study suggested that an immediate digital impression after implantation is feasible for clinical application and more efficient than a conventional implant impression. The clinical efficiency of an immediate digital impression is statistically the same as that of a regular digital impression. Patients show higher satisfaction with immediate digital impressions among three different impression techniques.

Conflicts of interest

The authors report no conflicts of interest related to this study.

Author contribution

Drs Dan Ni GUO and Shao Xia PAN conceived and designed the clinical trial, contributed to the data collection and analysis and prepared the manuscript. Drs Yu Shu LIU, Peng Fei WANG, Bing WANG, Jian Zhang LIU, Wen Hui GAO and Yong Sheng ZHOU contributed to the data collection and analysis. All the authors reviewed the manuscript.

(Received Jan 30, 2018; accepted Mar 20, 2018)

References

- Goodacre CJ, Naylor WP. Single implant and crown versus fixed partial denture: A cost-benefit, patient-centred analysis. *Eur J Oral Implantol* 2016;9(suppl 1):S59–S68.
- Joda T, Ferrari M, Gallucci GO, Wittneben JG, Bragger U. Digital technology in fixed implant prosthodontics. *Periodontol* 2000 2017;73:178–192.
- Joda T, Bragger U. Time-efficiency analysis of the treatment with monolithic implant crowns in a digital workflow: a randomized controlled trial. *Clin Oral Implants Res* 2016;27:1401–1406.
- Koch GK, Gallucci GO, Lee SJ. Accuracy in the digital workflow: From data acquisition to the digitally milled cast. *J Prosthet Dent* 2016;115:749–754.
- Joda T, Zarone F, Ferrari M. The complete digital workflow in fixed prosthodontics: a systematic review. *BMC Oral Health* 2017;17:124.
- Patel N. Integrating three-dimensional digital technologies for comprehensive implant dentistry. *J Am Dent Assoc* 2010;141(suppl 2):20S–24S.
- Stimmelmayer M, Guth JF, Erdelt K, Edelhoff D, Beuer F. Digital evaluation of the reproducibility of implant scanbody fit – an *in vitro* study. *Clin Oral Investig* 2012;16:851–856.
- Gimenez B, Ozcan M, Martınez-Rus F, Pradies G. Accuracy of a digital impression system based on parallel confocal laser technology for implants with consideration of operator experience and implant angulation and depth. *Int J Oral Maxillofac Implants* 2014;29:853–862.
- Ahlholm P, Sipila K, Vallittu P, Jakonen M, Kotiranta U. Digital Versus Conventional Impressions in Fixed Prosthodontics: A Review. *J Prosthodont* 2018;27:35–41.
- Wismeijer D, Mans R, van Genuchten M, Reijers HA. Patients' preferences when comparing analogue implant impressions using a poly-ether impression material versus digital impressions (Intraoral Scan) of dental implants. *Clin Oral Implants Res* 2014;25:1113–1118.
- Schepke U, Meijer HJ, Kerdijk W, Cune MS. Digital versus analog complete-arch impressions for single-unit premolar implant crowns: Operating time and patient preference. *J Prosthet Dent* 2015;114:403–406.
- Joda T, Bragger U. Patient-centered outcomes comparing digital and conventional implant impression procedures: a randomized crossover trial. *Clin Oral Implants Res* 2016;27:e185–e189.
- Tian JH, Di P, Lin Y, Zhang Y, Wei DH, Cui HY. A pilot clinical study of immediate provisionalization with a chairside computer aided design and computer aided manufacture monolithic crown for single tooth immediate implant placement [In Chinese]. *Zhonghua Kou Qiang Yi Xue Za Zhi*, 2017;52:3–9.
- Beuer F, Groesser J, Schweiger J, Hey J, Guth JF, Stimmelmayer M. The Digital One-Abutment/One-Time Concept. A Clinical Report. *J Prosthodont* 2015;24:580–585.
- Price DD, McGrath PA, Rafii A, Buckingham B. The validation of visual analogue scales as ratio scale measures for chronic and experimental pain. *Pain* 1983;17:45–56.
- Lee SJ, Gallucci GO. Digital vs. conventional implant impressions: efficiency outcomes. *Clin Oral Implants Res* 2013;24:111–115.
- van der Meer WJ, Andriessen FS, Wismeijer D, Ren Y. Application of intra-oral dental scanners in the digital workflow of implantology. *PLoS One* 2012;7:e43312.
- Mangano FG, Veronesi G, Hauschild U, Mijiritsky E, Mangano C. Trueness and Precision of Four Intraoral Scanners in Oral Implantology: A Comparative *In Vitro* Study. *PLoS One* 2016;11:e0163107.
- Imburgia M, Logozzo S, Hauschild U, Veronesi G, Mangano C, Mangano FG. Accuracy of four intraoral scanners in oral implantology: a comparative *in vitro* study. *BMC Oral Health* 2017;17:92.
- Schnitman PA, Han RK. Completely Digital Two-Visit Immediately Loaded Implants: Proof of Concept. *J Oral Implantol* 2015;41:429–436.
- Persson AS, Oden A, Andersson M, Sandborgh-Englund G. Digitization of simulated clinical dental impressions: virtual three-dimensional analysis of exactness. *Dent Mater* 2009;25:929–936.
- Lee SJ, Betensky RA, Gianneschi GE, Gallucci GO. Accuracy of digital versus conventional implant impressions. *Clin Oral Implants Res* 2015;26:715–719.
- Moreira AH, Rodrigues NF, Pinho AC, Fonseca JC, Vilaca JL. Accuracy Comparison of Implant Impression Techniques: A Systematic Review. *Clin Implant Dent Relat Res* 2015;17(suppl 2):e751–e764.