

Correction of Hypertelorism: Surgical Results Related to Three Dimensional Planning Assessments in Various Orbital Dystopias

Language: English

Authors: PD Dr. Dr. Johannes Kleinheinz¹, Koord Smolka¹, Univ.-Prof. Dr. Dr. Dr. h.c. Ulrich Joos¹, Dr. Thomas Stamm²
University of Münster, Germany

¹Department of Cranio-Maxillofacial Surgery

²Department of Orthodontics

Date/Event/Venue:

March 13-16, 2001

3rd International Interdisciplinary Congress on Skull base and Craniofacial Surgery
Interlaken, Switzerland

Introduction

Dystopias of the bony orbit are caused by craniosynostosis, facial clefts, hamartomas and encephaloceles. Increased interorbital distance is casually and pathogenically heterogeneous. The etiology and type of hypertelorism influence the selection of the operative procedure. Therefore three dimensional computed tomographic scans are standard in planning assessments for craniofacial surgery.

Purpose of the Study

The aim of this study about correction of hypertelorism was to test the hypothesis whether there is a predictable relationship between a three dimensional planning assessment for soft tissue changes as well as for movements of the osseous orbits or the ocular globes and the surgical outcome.

Material and Methods

From 1996 to 1999 five patients (mean age 11 years, ranging from 5 to 35) underwent hypertelorism surgery in our clinic. Three patients were female, two male. In four patients midline clefts were associated with hamartomas. One patient showed unilateral orbital dystopia combined with Goldenhar syndrome, another appeared with de Myer syndrome and anophthalmia on one side. Reduction of the increased interorbital distance was the main aspect of the surgery in three patients, whereas correction of a vertical displacement of one orbit was necessary in the other two patients.

Surgical correction of hypertelorism was performed in all patients by combined intra- and extracranial approach. All patients received reattachment of the canthal ligaments. Scheme for surgery was calculated by a digital three dimensional computed tomographic (CT) scan model. Simulation of the surgical procedure was separately done for the movements of the osseous orbits, the ocular globes and soft tissue changes. Soft tissue distances were measured clinically as well preoperatively as postoperatively. Bony conditions were evaluated pre- and postoperatively by three dimensional CT scans. CT digital distances were compared similar to clinical distances when possible.

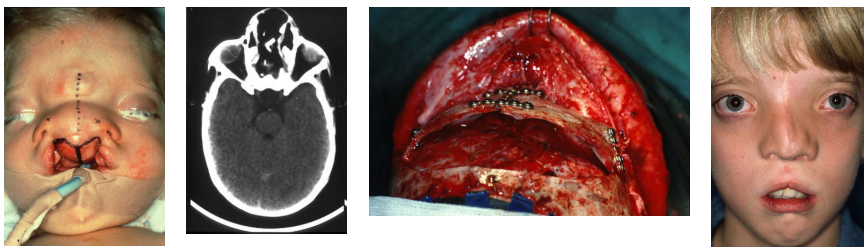


Fig. 1: Pre- and postoperative view of a patient with midline cleft. The horizontal CT-scan shows dislocation of the orbits. Operative view with reattachment after medial rotation.

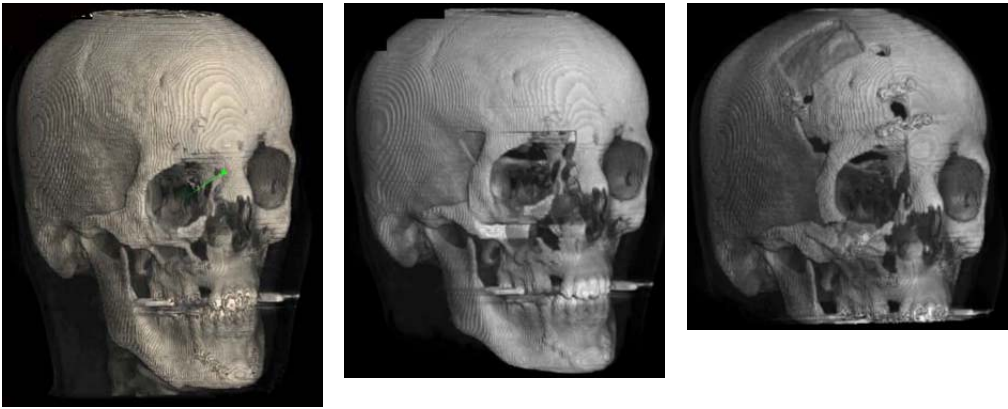


Fig. 2: Pre- and postoperative 3-D-CT-scan in a patient with unilateral orbital dystopia. The picture in the middle shows computer assisted planning assessment.

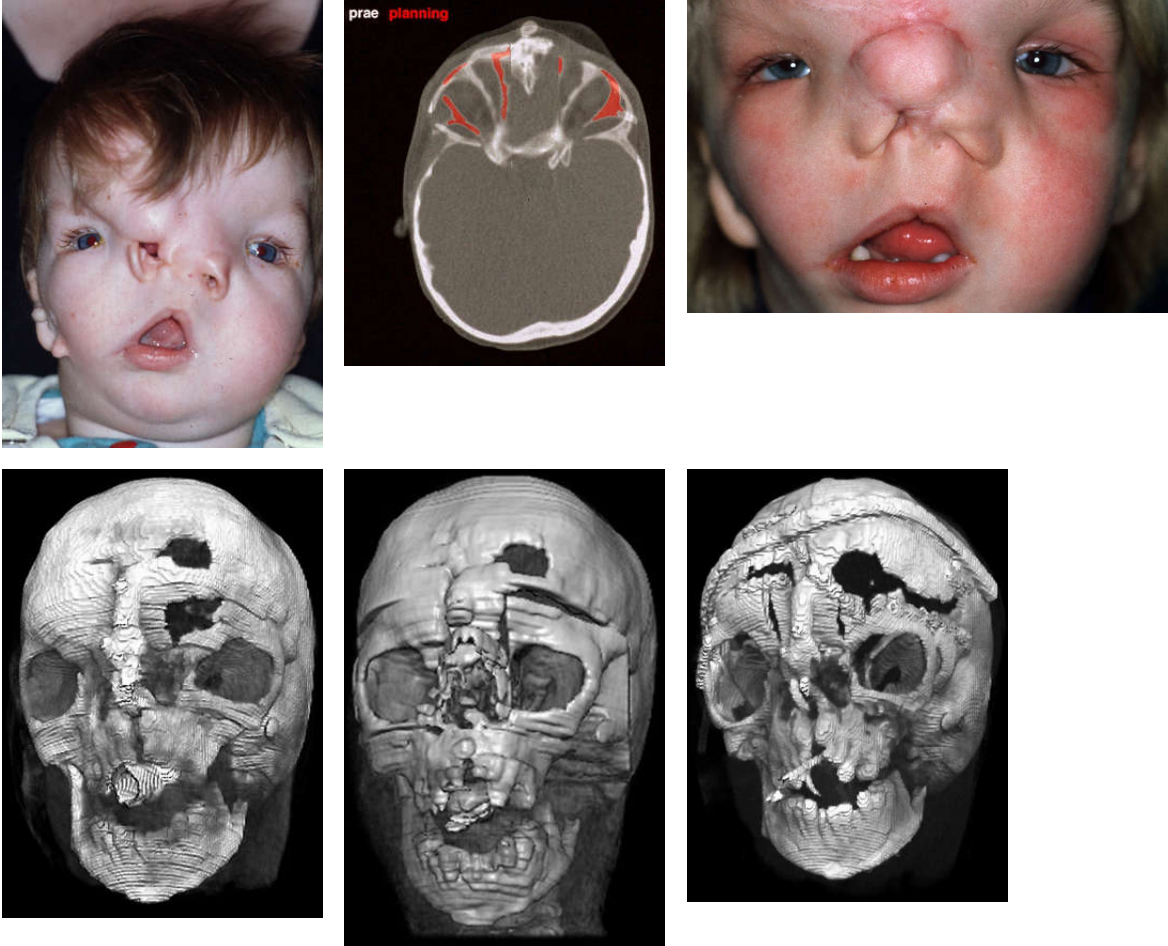


Fig. 3: Pre- and postoperative view and 3-D-CT-scan in a patient with hypertelorism caused by midline cleft in association with hamartoma. Pictures in the middle show planning assessment in a horizontal scan and in our computer assisted 3-D-CT-scan prediction model after medial rotation of both orbits.

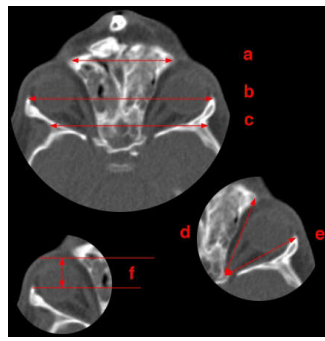
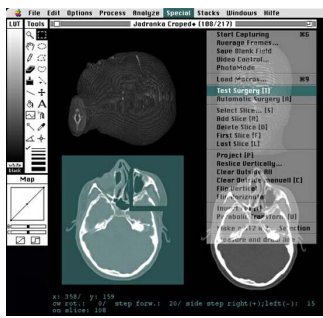


Fig. 4: Work station for our computer assisted assessment

Fig. 5: Preoperative analysis of the bony orbital skeleton

Results

The bony interorbital distance decreased by an average of 25.2 mm in the three hypertelorism cases. The intercanthal distance decreased by an average of 18.2 mm. There was a strong correlation between the bony structures in the digital prediction model and postoperative CT scans (deviation less than 2 mm). With reference to the bony reduction of the interorbital distance we found only a moderate correlation between the predicted reduction of the intercanthal distance in the digital model and surgical outcome in postoperative CT scans or in postoperative clinical measurement. Also medial movement of the ocular globes was less than predicted. Correlations between the digital model and postoperative CT scans were stronger in vertical than in transversal movements of the orbit.

Discussion

The goal in hypertelorism surgery is the reduction of the interocular and intercanthal distance to improve the functional result and aesthetic appearance. Our model has been proved as exact predictor for the bony outcome. Although exactly predicted medial bony translocation of the orbits does not produce equivalent movement of the ocular globes and equivalent reduction of the intercanthal distance, exact prediction of the bony outcome is fundamental for the development of more precise prediction criteria for the movement of the ocular globes and changes in intercanthal distances in hypertelorism surgery.

Conclusion

We conclude that our digital three dimensional planning assessment is a useful predictor in hypertelorism surgery especially for the bony outcome.

References

- Mühling J, Zöller J, Saffar M, Reinhart E, Reuther J: Results of operative therapy of bony orbit dystopies. *Mund Kiefer Gesichtschir* 2:94-97, 1998
- Tan ST, Mulliken JB: Hypertelorism: nosologic analysis of 90 patients. *Plast Reconstr Surg* 99:317-27, 1997
- Joos U, Anatssov E: Treatment of craniofacial midline clefts in association with hamartomas: report of three cases. *J Oral Maxillofac Surg* 56; 383-392, 1998
- Panchal J, Kim YO, Stelnicki E, Pilgram T, Marsh JL: Quantitative assessment of osseous, ocular and periocular changes after hypertelorism surgery. *Plast Reconstr Surg* 104: 16-28, 1999
- Ortiz Monasterio F, Medina O, Musolas A: Geometrical planning for the correction of orbital hypertelorism. *Plast Reconstr Surg* 86: 650-7, 1990

This Poster was submitted by PD Dr. Dr. Johannes Kleinheinz.

Correspondence address:

PD Dr. Dr. Johannes Kleinheinz
University of Münster
Waldeyerstr. 30
D-48149 Münster
Germany

P
18

Correction of Hypertelorism: Surgical Results Related to Three Dimensional Planning Assessments in Various Orbital Dystopias



Smolka K¹, Kleinheinz J¹, Stamm T², Joos U¹

¹ Department of Craniomaxillofacial Surgery, University of Muenster, Germany
Head: Prof. Dr. Dr. Dr.h.c.U.Joos



² Department of Orthodontics, University of Muenster, Germany
Head: Prof. Dr. U. Ehmer

1 Introduction

Dystopias of the bony orbit are caused mainly by craniosynostosis, facial clefts, hamartomas and encephaloceles.¹ Increased interorbital distance is causally and pathogenetically heterogeneous.² The etiology and type of hypertelorism influence the selection of the operative procedure.³ Therefore three dimensional computed tomographic scans are standard in planning assessments for craniofacial surgery.

2 Purpose of the Study

The aim of this study about correction of hypertelorism was to test the hypothesis whether there is a predictable relationship between a three dimensional planning assessment for soft tissue changes as well as for movements of the osseous orbits or the ocular globes and the surgical outcome.

3 Material and Methods

From 1996 to 1999 five patients (mean age 11 years, ranging from 5 to 35) underwent hypertelorism surgery in our clinic. Three patients were female, two male. In four patients midline clefts were associated with hamartomas. One patient showed unilateral orbital dystopia combined with Goldenhar syndrome, another appeared with de Myer syndrome and anophthalmia on one side. Reduction of the increased interorbital distance was the main aspect of surgery in three patients, whereas correction of a vertical displacement of one orbit was necessary in the other two patients. Surgical correction of hypertelorism was performed in all patients by combined intra- and extracranial approach. All patients received reattachment of the canthal ligaments. Scheme for surgery was calculated by a digital three dimensional computed tomographic (CT) scan model. Simulation of the surgical procedure was separately done for the movements of the osseous orbits, the ocular globes and soft tissue changes. Soft tissue distances were measured clinically as well prospectively as postoperatively. Bony conditions were evaluated pre- and postoperatively by three dimensional CT scans. CT digital distances were compared similar to clinical distances when possible.

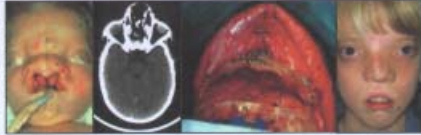


Fig. 1: Pre- and postoperative view of a patient with midline cleft. The horizontal CT-scan shows dislocation of the orbits. Operative view with reflexion after medial rotation.

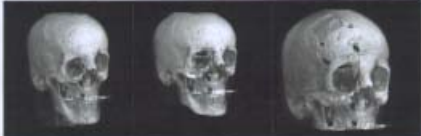

Fig. 2: Pre- and postoperative 3-D-CT-scan in a patient with unilateral orbital dystopia. The picture in the middle shows computer assisted planning assessment.

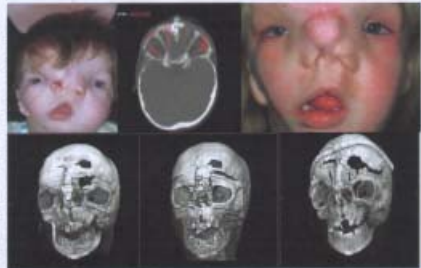

Fig. 3: Pre- and postoperative view and 3-D-CT-scan in a patient with hypertelorism caused by midline cleft in association with hamartoma. Pictures in the middle show planning assessment in a horizontal scan and in our computer assisted 3-D-CT-scan prediction model after medial rotation of both orbits.

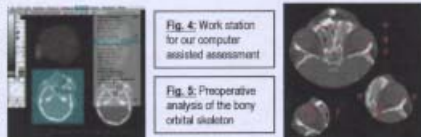


Fig. 4: Work station for our computer assisted assessment

Fig. 5: Preoperative analysis of the bony orbital skeleton

4 Results

The bony interorbital distance decreased by an average of 25.2 mm in the three hypertelorism cases. The intercanthal distance decreased by an average of 18.2 mm. There was a strong correlation between the bony structures in the digital prediction model and postoperative CT scans (deviation less than 2 mm). With reference to the bony reduction of the interorbital distance we found only a moderate correlation between the predicted reduction of the intercanthal distance in the digital model and surgical outcome in postoperative CT scans or in postoperative clinical measurement. Also medial movement of the ocular globes was less than predicted. Correlations between the digital model and postoperative CT scans were stronger in vertical than in transversal movements of the orbits.

5 Discussion

The goal in hypertelorism surgery is the reduction of the interocular and intercanthal distances to improve the functional result and aesthetic appearance.⁴ Our model has been proved as exact predictor for the bony outcome. Although exactly predicted medial bony translocation of the orbits does not produce equivalent movement of the ocular globes and equivalent reduction of the intercanthal distance, exact prediction of the bony outcome is fundamental for the development of more precise prediction criteria for the movement of the ocular globes and changes in intercanthal distances in hypertelorism surgery.⁵

6 Conclusion

We conclude that our digital three dimensional planning assessment is a useful predictor in hypertelorism surgery especially for the bony outcome.

References

1. Wilentz J, Silber J, Silber H, Frenkel C, Frenkel J: Results of maxillary surgery in the cleft lip and palate team (University of Muenster). 1997; 1:108
2. Lee J: Analysis of hypertelorism: etiology, analysis of 20 patients. Plast Reconstr Surg 1971; 47: 207
3. Lee J, Frenkel C: Treatment of hypertelorism with the orbit in association with hamartomas. Arch of Plast Surg 1974; 10: 200-204
4. Frenkel C, Lee JH, Silber H, Frenkel J, Silber J, Guedes A: Guidelines treatment of hypertelorism with computer-aided three-dimensional analysis. Plast Reconstr Surg 1991; 87: 398
5. Lee JH, Frenkel C, Silber H, Frenkel J: Interorbital spacing by the movement of the orbit. Plast Reconstr Surg 1991; 87: 100