

Int Poster J Dent Oral Med 2012, Vol 14 No 3, Poster 609

Recurrence and complications of ranula

A series of 35 cases

Language: English

Authors:

Dr. Eva Lakiere, Prof. Serge Schepers, Dr. Luc Vrielinck,
St. John's Hospital, Department of Oral and Maxillofacial Surgery, Genk, Belgium
Prof Ivo Lambrichts, Prof Constantinus Politis,
Hasselt University, Faculty of Medicine, Diepenbeek, Belgium

Date/Event/Venue:

19/03/2012
Spring Meeting, OMFS Belgium
Dolce, La Hulpe

Introduction

Definition

- Most ranulas are pseudocysts, originating from ductal injury with subsequent extravasation and accumulation of saliva in the surrounding tissue.
- Sometimes it can be a true cyst with epithelial lining, arising from ductal obstruction.

Clinical presentation

- Oral ranula
 - Blue translucent swelling in the floor of the mouth
- Plunging ranula
 - Cervical swelling
 - Herniates through or at posterior border of the m. mylohyoideus.

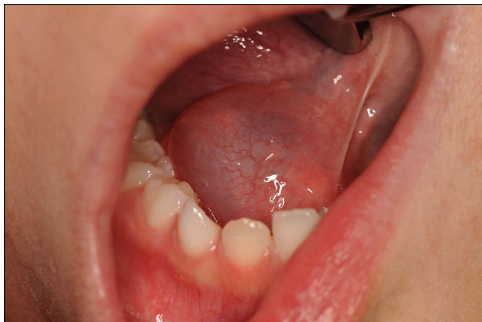

Fig. 1: Clinical presentation

Management

Management of the ranula is controversial. There are several different options, each with advantages and disadvantages.

Treatment options

- Aspiration
- Sclerotherapy
- Carbon dioxide laser
- Surgery
 - Marsupialization
 - Ranula excision
 - Sublingual gland + ranula excision
 - Sublingual gland + ranula evacuation

Objectives

Recurrence and complications of ranula treatment in 35 patients.

Material and Methods

Retrospective patient file analysis of treated cases between 1993 and 2010.

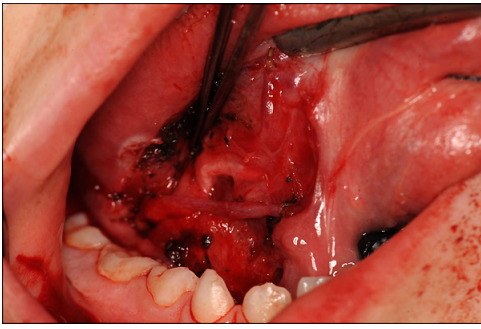


Fig. 2: Peroperative image

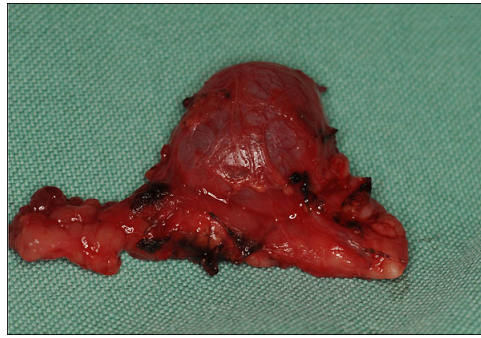

Fig. 3: Resection specimen

Results

- 35 patients
- 1993-2010
- Age:
 - Mean: 19
 - Range: 4 - 64
- Male-female ratio: 2 to 3

| Treatment | Number | recurrence | Other complications |
|--------------------------------------|--------|------------|--|
| Expectatio | 2 | 0% | 0% |
| Marsupialization | 6 | 50% | 50% Infection (1), plunging ranula (1), tongue hypesthesia (1) |
| Excision ranula | 18 | 28% | 6% cicatrization of Wharton's duct: excision of gl. submandibularis (1) |
| Excision ranula and gl. sublingualis | 7 | 0% | 14% postoperative bleeding (1) |
| Excision gl. submandibularis | 1 | 100% | 0% |
| Referral | 1 | | |

Tab. 1: Treatment of Ranula

Conclusions

Excision of the ipsilateral sublingual gland with ranula excision (true cyst) or with evacuation of the ranula (pseudocyst) is first choice treatment for oral and plunging ranula

Marsupialization only in infants or patients in poor general condition

No additional excision of submandibular gland

- No causal relationship between submandibular gland and ranula

- Higher risk of injury of ramus marginalis and hypoglossal nerve with transcervical approach

This Poster was submitted by [Dr Eva Lakiere](#).

Correspondence address:

[Dr Eva Lakiere](#)

St. John's Hospital, Oral and Maxillofacial Surgery

Schiepse Bos 6

3600 Genk

Belgium

RECURRENCE AND COMPLICATIONS OF RANULA

A series of 35 cases

E. Lakiere¹, S. Schepers^{1, 3}, L. Vrielinck¹, I. Lambrichts², C. Politis^{1, 2*}



¹Oral and Maxillofacial Surgery, St. John's Hospital, Gent, Belgium.
²Faculty of Medicine, Hasselt University, Diepenbeek, Belgium.
³Oral and Maxillofacial Surgery, Faculty of Medicine, Ghent University, Belgium.
^{*}Corresponding author



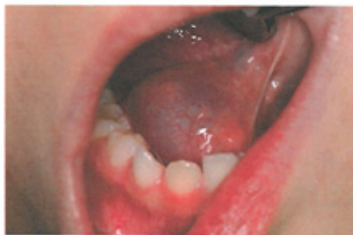INTRODUCTION

Definition

- Most ranulas are pseudocysts, originating from ductal injury with subsequent extravasation and accumulation of saliva in the surrounding tissue.
- Sometimes it can be a true cyst with epithelial lining, arising from ductal obstruction.

CLINICAL PRESENTATION

- Oral ranula
 - Blue translucent swelling in the floor of the mouth
- Plunging ranula
 - Cervical swelling
 - Herniates through or at posterior border of the m. mylohyoideus.



MANAGEMENT

Management of the ranula is controversial. There are several different options, each with advantages and disadvantages.

TREATMENT OPTIONS

- Aspiration
- Sclerotherapy
- Carbon dioxide laser
- Surgery
 - Marsupialization
 - Ranula excision
 - Sublingual gland + ranula excision
 - Sublingual gland + ranula evacuation

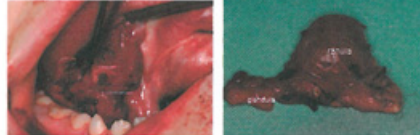OBJECTIVES

Recurrence and complications of ranula treatment in 35 patients.

MATERIALS AND METHODS

Retrospective patient file analysis of treated cases between 1993 and 2010.

Original ranula excised together with ipsilateral sublingual gland



RESULTS

- 35 patients
- 1993-2010
- Age:
 - Mean: 19
 - Range: 4 - 64
- Male-female ratio: 2 to 3

RESULTS

| Treatment | Number | Recurrence | Other complications |
|--------------------------------------|--------|------------|---|
| Expectato | 2 | 0% | 0% |
| Marsupialization | 6 | 50% | 50% (3x) infection (1) plunging ranula (1) tongue hyposthenia (1) |
| Excision ranula | 18 | 28% | 6% (1/18) cicatrization of Wharton's duct: excision of submandibular gland |
| Excision ranula and sublingual gland | 7 | 0% | 14% (1/7) postoperative bleeding (1) |
| Excision submandibular gland | 1 | 100% | 0% |
| Referral to other centre | 1 | | |

DISCUSSION AND CONCLUSION

- Excision of the ipsilateral sublingual gland with ranula excision (true cyst) or with evacuation of the ranula (pseudocyst) is first choice treatment for oral and plunging ranula
- Marsupialization only in infants or patients in poor general condition
- No additional excision of submandibular gland
 - No causal relationship between submandibular gland and ranula
 - Higher risk of injury of ramus marginalis and hypoglossal nerve with transcervical approach