



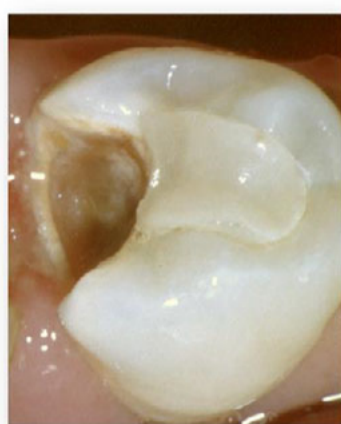Disinfection of Carious Dentin With Sodium Hypochlorite-Supported Incomplete Excavation

M.J. Noack, N. Peyrade, K. Höfer, M.J. Wicht

Department of Operative Dentistry and Periodontology,
Center of Dental Medicine, University of Cologne, Germany

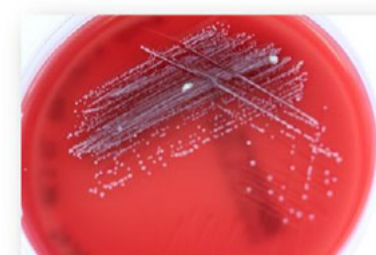Introduction

- Complete excavation is not supported by evidence
- Incomplete excavation has a risk of failure for restoration
- An advantageous strategy could be the disinfection of carious-infected dentin
- Disinfection of root canal walls: NaOCl (gold standard)



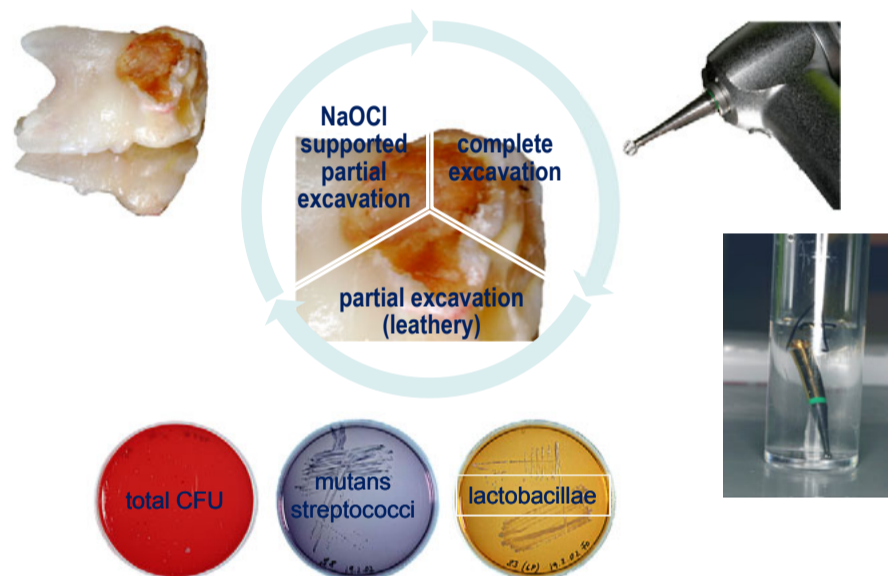
Objectives

- To evaluate the disinfecting effect of sodium hypochlorite during partial caries excavation of deciduous teeth in vitro
 - Primary endpoint: Counts of microorganisms in dentin samples

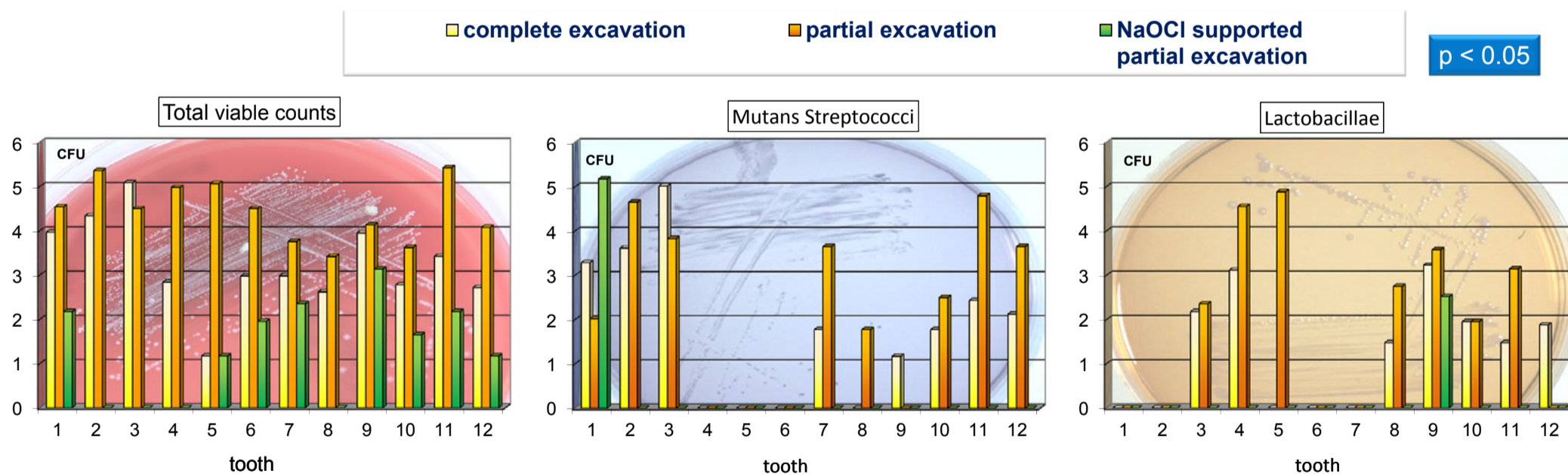


Materials and Methods

- 12 freshly extracted primary teeth from children with early childhood caries (ECC)
- Sectioned into three parts through the center of the defect
 - Treated within 2 h after extraction:
 - complete caries excavation
 - partial caries excavation
 - partial caries excavation with 1% NaOCl
 - Excavation procedures: round bur in a torque-controlled handpiece, simulated clinical conditions, 37 °C
 - Rinse: 65 ml ringer lactate, dentinal debris samples
 - Vortexed dentin samples: anaerobically grown on blood, MSB and Rogosa agars

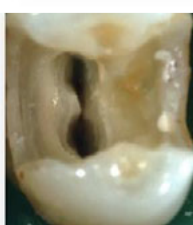
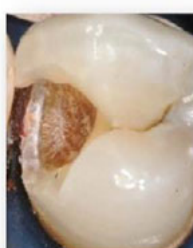
Results



Discussion

- Complete excavation: even so, microorganisms are left behind
- Partial excavation: pulp protection
- NaOCl:
 - effective against caries pathogens
 - no side-effects on pulp (< 15 min)
- Partially excavated adhesive restorations
 - sealing of carious dentin
 - clinically successful
- Adhesive procedure has to be adapted



Conclusions

- Application of sodium hypochlorite during partial caries excavation will disinfect the remaining dentin more effectively than complete caries excavation
- Sodium hypochlorite-supported incomplete excavation should be considered a clinical standard, as it is for root canal treatment

