



# Bruxism Diagnosis: A Clinical Case Report



CASTRO, MAURA<sup>1</sup>; DELGADO, ANTÓNIO HS<sup>2</sup>; ALMEIDA, ANDRÉ MARIZ<sup>3</sup>; RUA, JOÃO<sup>4</sup>; FÉLIX, SÉRGIO<sup>5</sup>  
<sup>1</sup>14th Year Dentistry student at ISCSEM

<sup>2</sup>Teaching assistant of Oral Rehabilitation at ISCSEM; <sup>3</sup>Assistant Professor of Oral Rehabilitation and Orofacial Pain and TMJ at ISCSEM; <sup>4</sup>Assistant Professor of Clinical Oral Rehabilitation at ISCSEM.

<sup>5</sup>Head Professor of Oral Rehabilitation and Orofacial Pain and TMJ at ISCSEM. Member of the CiiEM

**Clinical case description:** 27 year old female patient, presented to the dentist referring muscular pain regarding the masseter and dental sensitivity. Clinically there was tooth wear on the occlusal surfaces of the inferior molars and bicuspid. Oclusally the patient displayed bilateral group guidance, class I molar relationship on the right side and class II division I on the left. In order to diagnose, firstly a questionnaire was performed, where the patient showed history of grinding, pain on the palpation of the masseter, mandibular pain and discomfort in the morning and sleeping pattern alterations. Given the clinical history and oral observation sleeping bruxism was suspected. With the purpose of confirming the preliminary diagnosis the patient was submitted to a polysomnography exam, an intra-oral splint (Bruxchecker®) and to portable electromyography (Grindcare®).

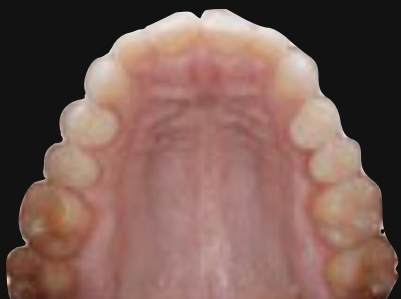

Figure 1. Occlusal view of the maxillary arch

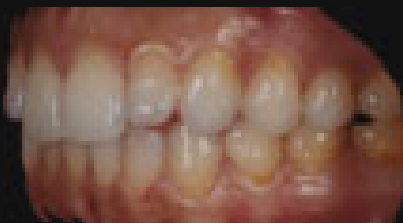


Figure 2. Lateral view in occlusion

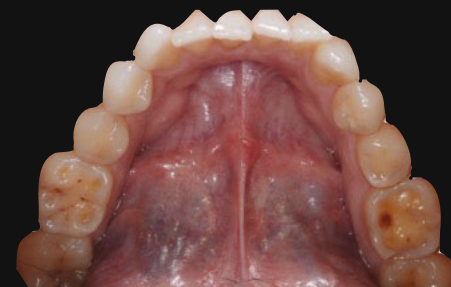

Figura 3. Lateral view of the mandibular arch

**Discussion:** Sleeping bruxism is considered the third most common sleeping disorder<sup>1</sup>. For its diagnosis to be considered definite, according to the literature<sup>2</sup>, it requires a combination of self-reports, clinical observation and full polysomnography - current gold standard<sup>2,3</sup>. The following table shows the different diagnostic methods employed in this individual case.

Diagnostic Method	Diagnosis	Reading	Limitations
Questionnaire	Positive	History of night grinding, headaches over the last six months, temple pain, ear ache over the last month, and referral of jaw pain and discomfort in the morning (Fig. 4)	Although questionnaires represent a good source of information they often lack reliability and are subjective. They're insufficient in the diagnosis of bruxism <sup>2</sup>
Clinical Observation	Positive	Score 3 of tooth wear on tooth 3.6 (occlusal - fig.5), score 2 on tooth 4.6 (occlusal) and score 1 on the cusp tips of the bicuspid according to Smith and Knight's index (1984) <sup>4</sup> .	It is clinically difficult to diagnose the etiology of the attrition and toothwear relying only on the clinical exam due to the fact that there are a number of possible differential diagnosis <sup>5</sup>
Polysomnography	Positive	Aumento da atividade eletromiográfica submentoniana durante a fase N2 do sono (e durante algumas transições de fase). Revelou 16 microdespertares ao longo da noite.	Although its considered the gold standard it depends on the variability of the sleeping bruxism and the device conditions the person's sleeping pattern over the night, leading to changes <sup>6</sup>
Bruxchecker®	Positive	Grinding contacts dominated by group guidance in mediotrusive movements (fig. 6)	Even though the splint is thin (0,1mm) it is hard to rule out its responsibility in generating the bruxism episode, leaving it less reliable as a diagnostic method <sup>7</sup>
Grindcare®	Positive	Based on the electromyographic activity of the masseter and anterior portion of the temporalis the grinding frequencies were obtained (fig. 9 e 10) and treatment was initiated by biofeedback stimulation	This method is merely an electromyographic reading, and depends solely on the activity of the masseter and temporalis <sup>8</sup>




Figure 4. Orofacial Pain Questionnaire

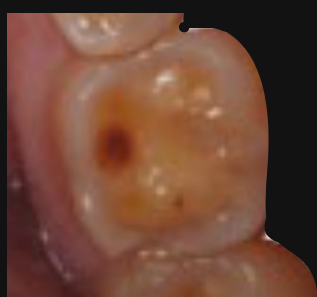

Figure 5. Score 3 on molar 3.6



Figure 7. Polysomnography exam



Figure 6. Bruxchecker®




Figure 8. Grindcare® on the temporalis

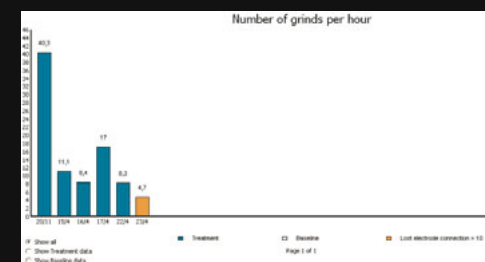
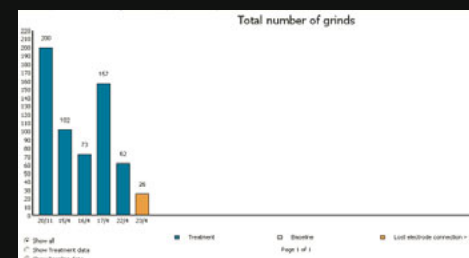


Figure 9 & 10. Grinding frequencies

**Conclusion:** Despite the existence of different diagnostic methods for bruxism, this remains controversial, due to the fact that a stand-alone method for its definite diagnosis is still lacking. In this clinical case, the combination of these methods allowed a holistic approach given the diversity of methods employed.

1. Murall RV, Rangarajan P, Mounessamy A. Bruxism: Conceptual discussion and review. Journal of pharmacy & biomedical sciences. 2015;7(Suppl 1):S265-70.  
 2. Castrillon EE, Du XL, Wang K, Zhang J, Zhou X, Swenson P. Sleep bruxism: an updated review of an old problem. Acta odontologica Scandinavica. 2016;1:7.  
 3. Lavigne GJ, Rompre PH, Montplaisir JY. Sleep bruxism: validity of clinical research diagnostic criteria. In a controlled polysomnographic study. Journal of dental research. 1996;75(1):546-5. B. Sugiuchi T, Hoshino J, Fujiwara M, Cui Y, Saito M, Saito M, Saito M. Diagnostic validity of the use of a portable single-channel electromyography device for sleep bruxism. Sleep & Breathing. 2016;20(2):693-702.  
 4. Lopez-Frias FJ, Castellanos-Cosano L, Martín-González J, Llamas-Carreras JM, Segura-Egea JJ. Clinical measurement of tooth wear: Tooth wear indices. Journal of clinical and experimental dentistry. 2012;4(1):48-53.  
 5. Yadav S. A Study on Prevalence of Dental Attrition and its Relation to Factors of Age, Gender and to the Signs of TMJ Dysfunction. Journal of Indian Prosthodontic Society. 2011;11(2):98-105.  
 6. Ferraz O, de Moura Guimarães T, Maluly Filho M, Del Fabro C, Abramo-Crossara Cunha T, Cristina Lotaf A, et al. Assessment of interobserver concordance in polysomnography scoring of sleep bruxism. Sleep Science. 2015;8(3):121-3.  
 7. Onodera K, Kanagae T, Sasaguri K, Protasio Oquendo C, Sato S. The use of a bruxchecker in the evaluation of different grinding patterns during sleep bruxism. O-rano: the journal of craniomandibular practice. 2006;24(4):292-9.