



Bilateral palatal inclusion canines in a patient with skeletal class III



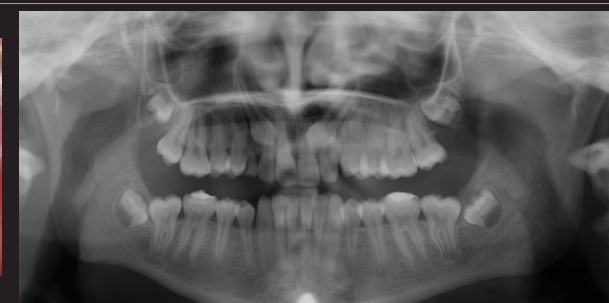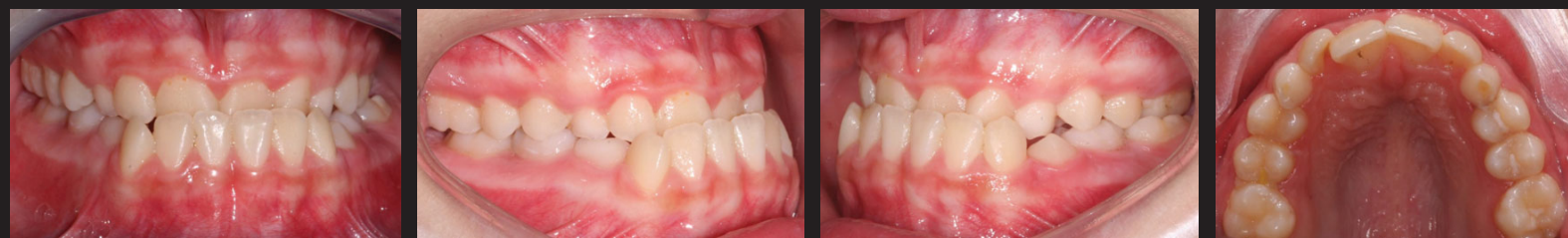LAVALL A. ^{1,2,3}, PIRES L. * ^{1,2}, USTRELL JM. ^{3,4}, ALFAIATE D. ^{1,2,3,5}

1. Núcleo CIRO; 2. IUCS/CESPU; 3. FMUP; 4. Universidade de Barcelona; 5. ICBAS

Clinical case description: A female patient, 11 years and 8 months old, due to esthetic reasons came to an orthodontic appointment. There were no general pathologies and in her family history we notice that the father had mandibular protrusion. With the orthodontic study (clinical evaluation, radiographic, models and cephalometric analysis) we detected that the patient had skeletal class III malocclusion with anterior crossbite and maxillary bilateral canines inclusion. The treatment plan was divided in 2 phases: In the interceptive phase was used the Mcnamara appliance associated with a Delaire facial mask and in the second one the patient put a fixed orthodontic appliance. Was also held a surgery for the exposure of the canines and their traction. The prognosis was good, the interceptive phase was before the maximum growth, the patient was cooperative and the canines were in a favorable position to traction. All these factors were important to the final result.

Clinical Case

INITIAL



TREATMENT

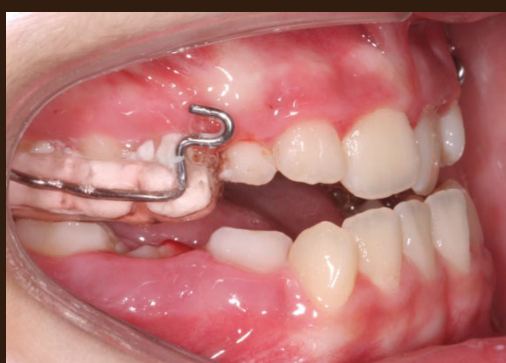

Figure. 1 Mcnamara appliance

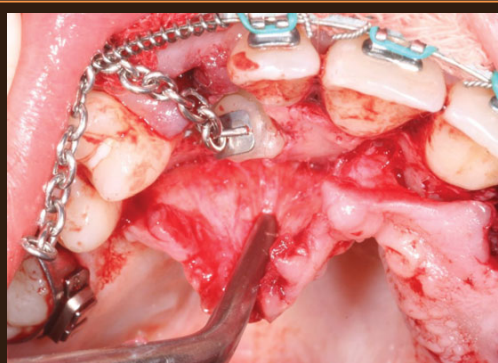


Figure.3 Surgical exposition with closed technic eruption

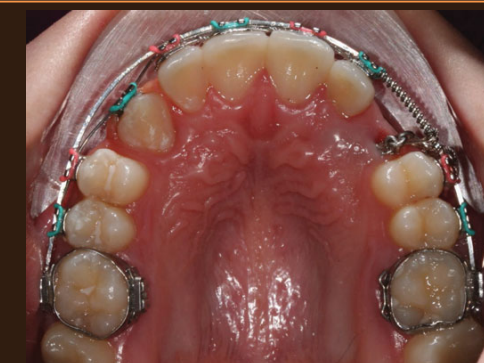


Figure. 4 Traction 13 and 23

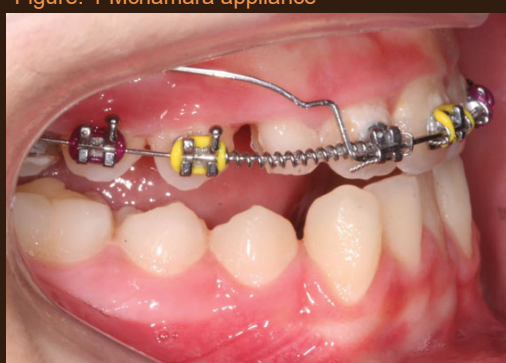
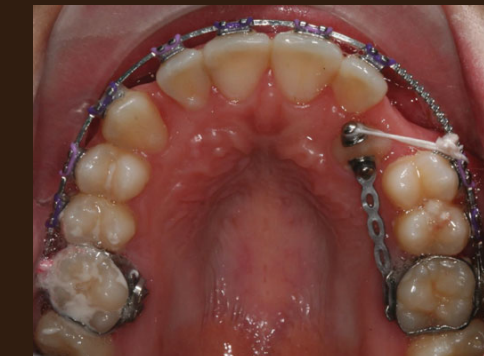
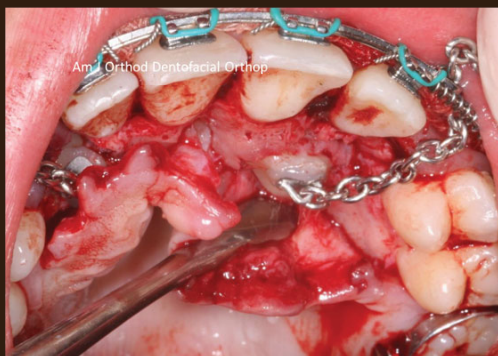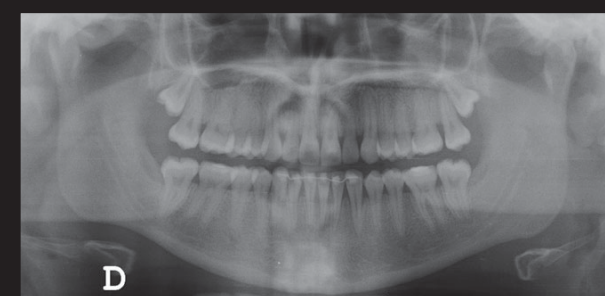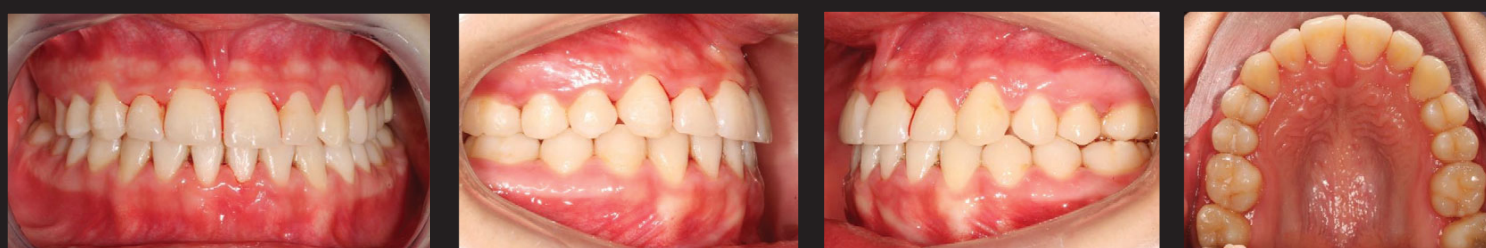Figure. 2 Protrusion utility arch



FINAL



Surgery – Dr. David Alfaiate
Orthodontic treatment - Dra. Asela Lavall

Discussion: The maxillary canines inclusion is the second one most frequent. According to the literature, unlike the buccal inclusions, in which cause is well explained (is the result of inadequate space in the arch), in the case of the canines that are included by the palatine, exact etiology is unknown. There are two theories well accepted as possible explanations for this phenomenon: the genetic theory and the guidance theory.¹⁻⁴ There are several therapeutic approaches, since interceptive treatment, canines traction, until the extraction in latter case. The choice of the treatment to be carried out depends of several factors – canine position; cooperation and age of the patient, among others. ² In this case we decided to go with the close surgery approach due to the high position of the canines. According to several authors, this technic has as benefits the patient comfort during the healing process, less bleeding, an easier placement of the attaching device and a good periodontal tooth health after the treatment.⁵

Conclusion: The correction of the position of this canines entails a greater improvement in the function, aesthetics and general oral health.² These treatments are complex and should be the subject of a multidisciplinary detailed study. In this case we extracted the 63. This treatment is recommended as interceptive/prevented measure when the maxillary canine is not palpable in the normal position and the rx confirms the palatal position. Professionals should aim to place the canines in the arcade whenever is possible and the patient should be informed of the whole process including the inherent risks of this treatment.⁶

Bibliography:
1- Chalakkal P, Thomas A, Chopra S. Displacement, location, and angulation of unerupted permanent maxillary canines and absence of canine bulge in children. *AJO-DO*. 2011; 139(3): 345-350.
2- Fleming P, Sharma P, Dibiase A. How to... mechanically erupt a palatal canine. *J Orthod*. 2011; 37:262-271
3- Schubert M, Baumert U. Alignment of impacted maxillary canines: Critical analysis of eruption path and treatment time. *J Orofac Orthop*. 2009;70(3):200-212
4- Becker A, Chaushu S. Etiology of maxillary canine impaction: A review. *Am J Orthod Dentofacial Orthop*. 2015;148(4): 557-567
5- Smailiene D et al. Palatally impacted maxillary canines: choice of surgical-orthodontic treatment method does not influence post-treatment periodontal status. A controlled prospective study. *Eur J Orthod*. 2013; 35(6): 803-810.
6- Becker A, Chaushu G, Chaushu S. Analysis of failure in the treatment of impacted maxillary canines. *Am J Orthod Dentofacial Orthop*. 2010;137(6): 744-754.