

# Rapid Maxillary Expansion in the Obstructive Sleep Apnea Syndrome - Meta-Analysis

## Introduction

The obstructive sleep apnea syndrome (OSAS) is a breathing disorder caused by repeated partial or complete upper airway obstruction (Fig. 1). This condition causes the cessation of breathing for 10 seconds or more, with changes in the normal pulmonary ventilation, resulting in a deficit of oxygenation. In prolonged episodes can lead to a progressive increase in the partial pressure of carbon dioxide in blood and consequent decrease in arterial pH (1,2,3).

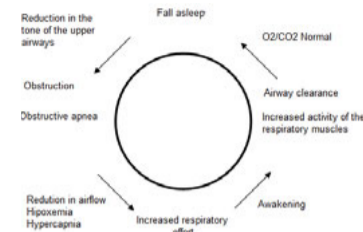


Figure 1 - Pathophysiological stages of OSAS

The orthodontic treatment has been considered an important option in the treatment of mild OSAS, representing also a viable alternative to the use of other therapeutic procedures like the continuous positive airway pressure (CPAP)(4).

Some intra-oral appliances, particularly the rapid maxillary expander (RME), may be used in cases of severe OSAS if the other therapeutic modalities are not indicated(5).

The aim of this systematic review with meta-analysis was to answer the following clinical question according to the PICO model (P, population; I, intervention; C, comparative intervention; O, outcome): "Considering children and adolescents under 18 years with OSAS, does RME treatment result in AHI normalization?"

## Methods

The research was conducted in compliance with the criteria described in the following table:

Type of studies	Systematic reviews, meta-analysis, randomized controlled trials, cohort studies, with the aim of assessing the effectiveness of RME
Type of participants	Children and adolescents, under 18 years old, with OSAS and subjected to maxillary expansion
Type of intervention	A comparison was made between the intervention (application of rapid maxillary expander) or lack of it
Type of results	Improvement in the condition of OSA was considered as corresponding to the normalization of apnea-hypopnea index (AHI)
Research strategy	Research on the following databases: Pubmed, Web of Science, LILACS, Cochrane Library e Embase data with the keywords: "Palatal Expansion Technique" [MeSH] AND "Sleep Apnea, Obstructive" [MeSH]. Articles in Portuguese and English with publication date between January 1st 2000 and December 2016 were accepted

## Results

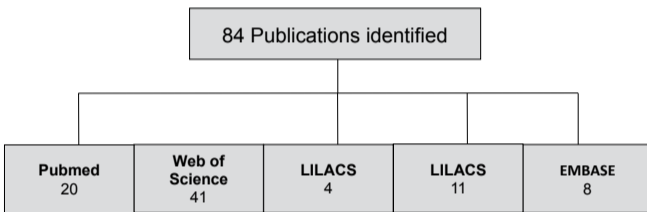


Figure 2 - Diagram of the results of the electronic search by database.




Figure 3 - Diagram of the methodology used for selecting the studies.

Author, Year	Aim	Study design	Participants	Age mean at baseline (range)	Appliance Used	Methods	Follow-up	AHI (nº/h)					Conclusions
								Baseline	4 mo	6 mo	12 mo	36 mo	
Villa, 2007	To assess at 12-mo follow-up the effectiveness of a RME as an early orthodontic treatment for OSAS in young children with dental malocclusion	Nonrandomized controlled clinical trial	16 (9 males and 7 females)	6,9 ± 2,2 (4,5 - 10,5)	Fixed 2-band RME appliance with an expansion screw	Anchorage: Second deciduous molars of the upper jaw Activation: 2 turns a day for the first 10 days	12	5,8 ± 6,8	--	2,7 ± 3,5	1,5 ± 1,6	--	AHI diminished significantly (P 5 .05) from Baseline
Villa, 2011	To evaluate the long-term outcome in the same group of young children (aged 4-10 y) with dental malocclusion successfully treated with RME by assessing sleep respiratory parameters and the clinical sign and symptoms of OSAS	Nonrandomized controlled clinical trial	10 (5 males and 5 females)	6,4 ± 1,97 (4 - 8)	Fixed 2-band RME appliance with an expansion screw	Anchorage: Second deciduous molars of the upper jaw Activation: 2 turns a day for the first 10 days	36	6,3 ± 4,7	--	--	2,4 ± 2,0	2,3 ± 1,7	AHI decreased significantly (P 5 .05) from baseline to 12 mo
Miano, 2009	To assess the outcome on cardiorespiratory parameters. To analyze the NREM sleep microstructure before and after RME treatment	Nonrandomized controlled clinical trial	9 (6 males and 3 females)	6,4 ± 1,97 (4 - 8)	Fixed 2-band RME appliance with an expansion screw	Anchorage: Second deciduous molars of the upper jaw Activation: 2 turns a day for the first 10 days	12	17,4 ± 21,0	--	--	5,4 ± 6,3	--	AHI decreased significantly (P 5 .05)
Pirelli, 2010	To describe how rapid maxillary expansion may improve the patency of the nasal airway and to what extent it may improve pediatric OSAS	Nonrandomized controlled clinical trial	60 (38 males and 22 females)	7,3 (6 - 13)	Fixed 2-band RME appliance with an expansion screw	Anchorage: First molars and premolars or second deciduous molars Activation: First day: 6 turns; after: 2 turns a day	4	16,3 ± 2,5	0,8 ± 1,3	--	--	--	Most of the patients present a normalization of recording with AHI
Pirelli, 2005	To study whether RME therapy in the upper jaw could improve both the patency of the nasal airways and OSAS	Nonrandomized controlled clinical trial	42 (26 males and 16 females)	7,1 ± 2,6 (4-10)	Fixed band RME appliance with an expansion screw	Anchorage: First molars and premolars or second deciduous molars Activation: First day: 6 turns; after: 2 turns a day	12	12,2 ± 2,5	--	--	0,5 ± 1,2	--	Most of the patients present a normalization of recording with AHI

Table 1 - Characteristics of the selected studies. AHI, Apnea-Hypopnea Index; Mo, month

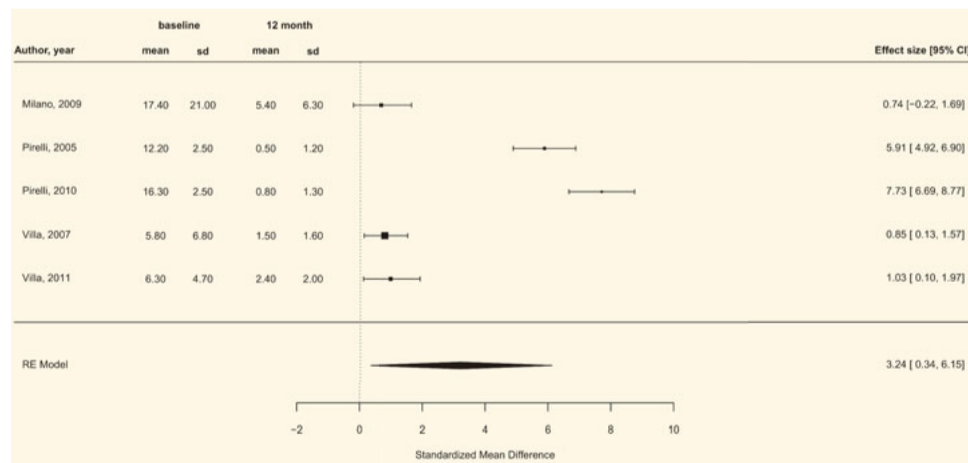


Figure 4 - Forest plot of the comparison between the AHI values before and after RME therapy. AHI, Apnea-Hypopnea Index; CI, confidence interval; RME, rapid maxillary expansion; SD, standard deviation.

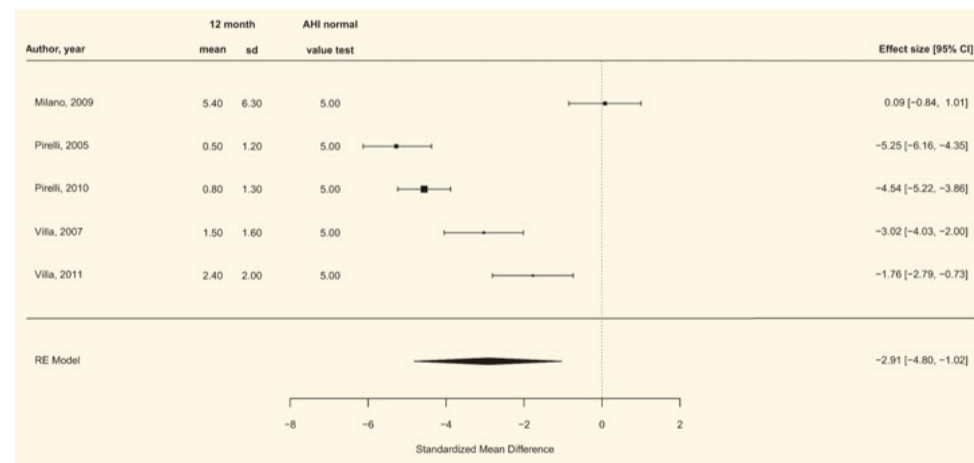


Figure 5 - Forest plot of AHI normalization after RME therapy. AHI, Apnea-Hypopnea Index; CI, confidence interval; RME, rapid maxillary expansion; SD, standard deviation.

## Conclusion

Despite the limitations related to the heterogeneity found in the reviewed studies, the meta-analysis results suggest that RME has a significant effect on OSAS and improves the AHI in children. Thus, this therapeutic approach may be considered as an auxiliary method in the treatment of children with risk factors for OSAS such as craniofacial abnormalities.

## Reference

- Choi JH, Kim EJ, Choi J, Kwon SY, Kim TH, Lee SH, Lee HM, Shin C, Lee SH. Obstructive sleep apnea syndrome: a child is not just a small adult. *Ann Otol Rhinol Laryngol.* 2010;119:656-61.
- Katyal V, Pamula Y, Martin AJ, Daynes CN, Kennedy JD, Sampson WJ. Craniofacial and upper airway morphology in pediatric sleep-disordered breathing: Systematic review and meta-analysis. *Am J Orthod Dentof Orthop.* 2013;143:20-30.
- Martins AB, Tufik S, Moura SMGPT. Síndrome da apnéia-hipopnéia obstrutiva do sono. *Fisiopatologia. J Bras Pneumol.* 2007;33:93-100.
- Ogawa T, Ito T, Cardoso MV, Kawata T, Sasaki K. Oral appliance treatment for obstructive sleep apnea patients with severe dental condition. *J Oral Rehabil.* 2001;38:202-7.
- Ito FA, Ito RT, Moraes NM, Sakima T, Bazzera MLS, Meirelles RC. Condutas terapêuticas para tratamento da Síndrome da Apnéia e Hipopnéia Obstrutiva do Sono (SAHOS) e da Síndrome da Resistência das Vias Aéreas Superiores (SRVAS) com enfoque no Aparelho Anti-Ronco (AAR-ITO). *R Dental Press Ortodon Orthop Facial.* 2005;4:143-56.
- Villa M, Malagola C, Pagani J, Montesano M, Rizzoli A, Guilleminault C, Ronchetti R. Rapid maxillary expansion in children with obstructive sleep apnea syndrome: 12-month follow-up. *Sleep Med.* 2007;8:128-34.
- Miano S, Rizzoli A, Evangelisti M, Bruni O, Ferri R, Pagani J, Villa M. P. "NREM sleep instability changes following rapid maxillary expansion in children with obstructive apnea sleep syndrome" *Sleep Medicine* 10. 2009. ; 471-478;
- Pirelli P, Saponara M, Rosa C, Fanucci E. "Orthodontics and obstructive sleep apnea in children", *Med Clin N Am* 94. 2010;517-529;
- Pirelli P, Saponara M, Attanasio G. Obstructive sleep apnoea syndrome (OSAS) and rhino-tubular dysfunction in children: therapeutic effects of RME therapy. *Prog Orthod* 2005;6(1): 48-61.
- Illa MP, Rizzoli A, Miano S, Malagola C. Efficacy of rapid maxillary expansion in children with obstructive sleep apnea syndrome: 36 months of follow-up. *Sleep Breath* 2011;15:179-84.