

# Non-dental incidental findings in cone-beam computed tomography

Patricia Quaresma<sup>1</sup>, Mariana Rodrigues<sup>1</sup>, Adriana Armas Sobral<sup>1</sup>, Inês Francisco<sup>2</sup>, Francisco do Vale<sup>3</sup>

1. DDS, MSc, Postgraduate Student, Institute of Orthodontics, Faculty of Medicine of the University of Coimbra, Portugal  
2. DDS, MSc, Assistant, Institute of Orthodontics, Faculty of Medicine of the University of Coimbra, Portugal

3. DDS, MSc, Specialist in Orthodontics, PhD, Program Director and Head of Department, Institute of Orthodontics, Faculty of Medicine of the University of Coimbra, Portugal



## Introduction

Diagnostic imaging of the maxillofacial region substantially improved with the development of cone-beam computed tomography (CBCT).<sup>1-3</sup> CBCT use has generally been justified when 2-dimensional radiography has not been able to provide the necessary information required to a proper management and treatment planning.<sup>2</sup> Nowadays, most dental practices use CBCT to image nearly every area of the maxillofacial region.<sup>3</sup> The improvement of imaging techniques can increase the identification of incidental findings (IFs). An IF detected on a radiographic image can be defined as any abnormal or pathological

finding that is unrelated to the original purpose of the imaging test or tests being performed.<sup>4</sup> A dental practitioner should be able to interpret a complete image, additional to the region of primary interest, because there could be other important findings that potentially concern the patient's health.<sup>3</sup>

The aim of this study was a review of the literature to determine the nature of non-dental IFs in the head and neck region that were found in CBCT scans.

## Material

A conducted computerized search on databases Cochrane and Pubmed was performed with the following terms: "cone beam computed tomography" [Mesh] AND "incidental findings"[Mesh]. A total of 74 publications were found, and after full read of title and abstract 47 were selected to read. The inclusion

criteria were articles in Portuguese or English; articles reporting incidental findings using CBCT and articles published between January 2000 to May 2019. The exclusion criteria were case reports, opinion articles. After application of the criteria 17 articles were selected.

## Results

The frequency of incidental findings in CBCT imaging varies widely, among studies in the literature, ranging from 1.1 to 2.9 per CBCT scan. This is due to differences in age groups, demographics of patient studies, and categories of findings that were reported.<sup>3,4</sup>

### GENERAL CATEGORIES OF THE MOST COMMON INCIDENTAL FINDINGS

#### PARANASAL SINUSES

- Sinusitis/Mucosal thickening
- Mucous retention cyst
- Aplastic/hypoplastic sinuses
- Pansinusitis
- Sinus pneumatization
- Antrolith

The paranasal sinuses include the frontal, sphenoidal, and maxillary sinuses, as well as the ethmoid air cell complex. Common inflammatory changes include mucosal thickening, mucus retention phenomenon, and less commonly, the antrolith. If the inflammatory changes seen in the maxillary sinus are extensive, the other paranasal sinus spaces may be involved.<sup>6</sup> The most common situation is the mucosal thickening and mucous retention cyst.<sup>3,7-11</sup>

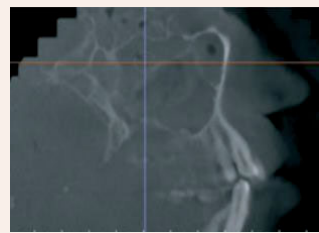


Fig. 1 Pansinusitis: mucosal thickening of sphenoid, ethmoid, and maxillary sinuses.<sup>5</sup>

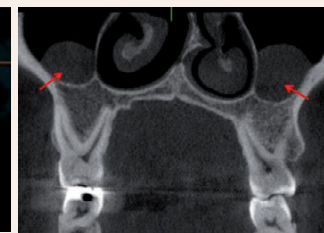

Fig. 2 Bilateral mucous retention cyst.<sup>7</sup>

It is suggested that in the absence of associated complications, conservative monitoring is the appropriate management strategy.<sup>11</sup> In case of antrolith referral may be recommended depending on location, size, and symptoms present.<sup>5</sup>

#### NASO-OROPHARYNGEA AIRWAY

- Adenoidal Hypertrophy
- Tonsillolith
- Concha bullosa
- Nasal septum deviation
- Narrowing of pharyngeal airway
- Asymmetry of pharyngeal airway
- Nasal/Antral polyp
- Nasal mucosal thickening

Enlarged tonsils or adenoid tissues are frequently seen. Commonly, there can be calcifications that are single or multiple, which represent tonsilloliths. These are secretions of mucus, bacteria, or fungi that reside in the tonsillar crypts. It has been clinically related to halitosis.<sup>1,6,11</sup> Other frequent findings are nasal septum deviation and concha bullosa, a common anatomical variation characterized by pneumatization of the nasal turbinates.<sup>6,11</sup>

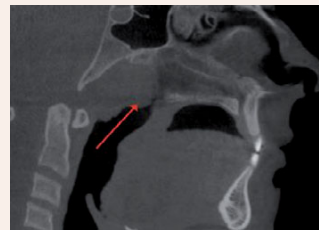

Fig. 3 Severe adenoidal hypertrophy.<sup>11</sup>

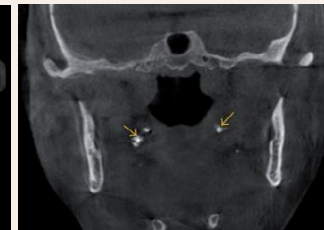

Fig. 4 Tonsilloliths.<sup>1</sup>

No treatment is required for most tonsillar calcifications.<sup>11</sup> Narrowing or asymmetry of the pharyngeal airway may be associated with obstructive sleep apnea or tumors. Physician referral is essential, following correlation with patient history and clinical findings.<sup>1</sup>

#### CERVICAL VERTEBRAE

- Degenerative changes:
- Osteoarthritis
- Lytic lesion
- Vertebral misalignment
- Fusion
- Prior surgery
- Ponticulus posticus

The degenerative changes represents the main finding in the cervical area. Other findings includes lytic areas, vertebral misalignment, clefts and fusion and the cervical spine is a common site for cancer metastasis.<sup>1,6,8,10,11,14</sup> *Ponticulus posticus* (PP) is a bony anomaly of the atlas that consists of a complete or partial calcified bridge over the vertebral groove of the posterior arch.<sup>12,13,14</sup>

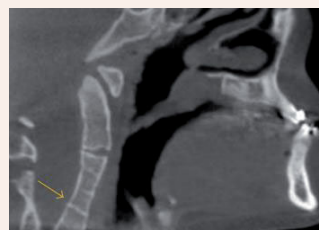


Fig. 5 Fusion of C3-C4.<sup>1</sup>

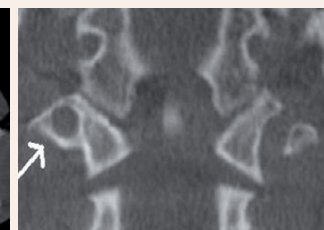

Fig. 6 Ponticulus posticus.<sup>14</sup>

Recognition of PP is important, because they have been implicated in neck pain, headaches, visual disturbances, vertigo and vascular problems, and is not a rare finding in childhood and adolescence.<sup>12,13,14</sup> Any changes in the cervical vertebrae region, that looks unusual, must be referral.<sup>6</sup>

#### SURROUNDING SOFT/HARD TISSUES

- Pineal gland calcification
- Stylohyoid ligament calcification
- Sialolith
- Stafne bone defect
- Thyroid cartilages calcification
- Exostoses
- Osteoma
- Enlarged sella turcica

Soft tissue calcifications in the head and neck areas can be pathological, age-related or idiopathic and correct identification is based on anatomic location, distribution, and morphology.<sup>1,5,6</sup> Calcification of the pineal gland is seen in two-thirds of the adult population and increases with age.<sup>1</sup> Another common finding is the calcification of stylohyoid ligament and sialolithiasis.<sup>1</sup> Sialolithiasis can appear at any age, with rare cases being reported in children and can be observed in parotid and submandibular gland.<sup>3</sup>

Incidental hard tissues can also be found and the most common are exostoses.<sup>10</sup> In clinical practice, most of them are asymptomatic and usually discovered incidentally during routine examinations.<sup>5,15</sup>

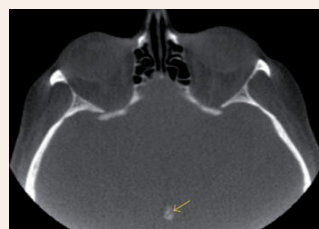

Fig. 7 Pineal gland calcification.<sup>1</sup>

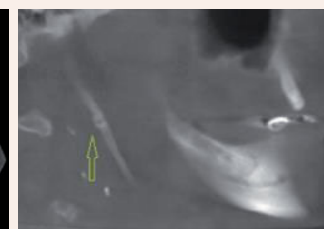


Fig. 8 Stylohyoid ligament calcification.<sup>15</sup>

The pineal gland calcification often does not lead to any clinical concern, but the possibility of tumor should be considered when calcification is found in children younger than 9 years or when it is greater than 1cm in diameter.<sup>1</sup> In the calcification of stylohyoid ligament, no follow-up or intervention is required unless symptoms associated with Eagle's syndrome are present. No treatment or referral is required in hard tissues IFs except for osteoma, which requires periodic monitoring for potential changes in size.<sup>5,15</sup>

#### TEMPOROMANDIBULAR JOINT

- Physiologic remodelling
- Degenerative changes
- Osteophytes
- erosions
- Bifid condyle

The main findings are physiologic remodeling and degenerative changes.<sup>8,11</sup> Remodeling is a physiological process that adapts the TMJ structure as a result of the mechanical forces, and flattening is a signal of this remodeling. An osteophyte on the condyle appears in the later stage of degenerative changes.<sup>5,10</sup>

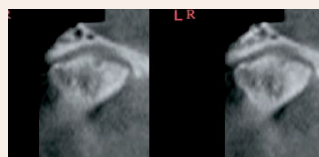


Fig. 9 Flattening and osteophyte formation on anterior surface.<sup>16</sup>

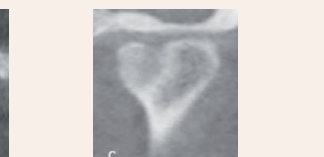


Fig. 10 Bifid condyle.<sup>10</sup>

If signs of degenerative changes are noted, and the patient is clinically asymptomatic, only monitoring the may be sufficient.<sup>5,10</sup>

#### VASCULAR

- Intracranial calcification of the internal carotid artery
- Carotid artery calcification

The common incidental vascular findings are calcification of the carotid and internal carotid arteries, especially in older population.<sup>17</sup> The calcification of the carotid artery is a radiographic evidence of atherosclerosis and could be an indicator of potential stroke or metabolic disease. The presence of internal carotid artery calcification does not always imply stenosis.<sup>1,17</sup>

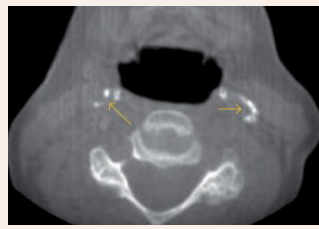


Fig. 11 Carotid artery calcifications.<sup>1</sup>

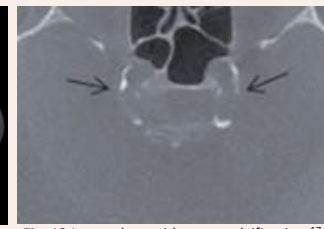


Fig. 12 Internal carotid artery calcification.<sup>17</sup>

It is important to differentiate between carotid calcifications and other soft tissue calcifications found in the same region. Physician referral is recommended in vascular calcifications for evaluation of risk factors for stroke.<sup>1,5,10,17</sup>

## Conclusions

General practitioners should be aware that incidental findings in the head and neck region, in CBCT scans, are frequent and that their identification is essential for a correct medical documentation. The most common IFs identified were vertebral degenerative changes, sinusitis or mucosal thickening, pineal gland calcification, mucous retention cysts, TMJ condylar degenerative changes and concha bullosa.<sup>4</sup> The effect of these IFs requires additional research in terms of follow-up care, treatment and costs.

**Bibliography:** 1. Barghan, S., Tahmasbi Arashlow, M., & Nair, M. K. Incidental Findings on Cone Beam Computed Tomography Studies outside of the Maxillofacial Skeleton. *International Journal of Dentistry*, 2016, 1-9. 2. Doğramacı, E. J., Rossi-Fedele, G., & McDonald, F. Clinical importance of incidental findings reported on small-volume dental cone beam computed tomography scans focused on impacted maxillary canine teeth. *Oral Surgery, Oral Medicine, Oral Pathology and Oral Radiology*, 118(6), e205-e209. 2016. 3. Togan, B., Gander, T., Lanzer, M., Martin, R., & Lübbers, H.-T. Incidence and frequency of non-dental incidental findings on cone-beam computed tomography. *Journal of Cranio-Maxillofacial Surgery*, 44(9), 1373-1380. 2016. 4. Edwards, R., Altalibi, M., & Flores-Mir, C. The frequency and nature of incidental findings in cone-beam computed tomographic scans of the head and neck region. *The Journal of the American Dental Association*, 144(2), 161-170. 2013. 5. Price, J.B., Thaw, K., Tyndall, D.A., Ludlow, J.B., Padilla, R.J. Incidental findings from cone beam computed tomography of the maxillofacial region: a descriptive retrospective study. *Clin. Oral Implants Res.* 00, 2011, 1-8. 6. Niles, D. A., & Danforth, R. A. Reporting Findings in the Cone Beam Computed Tomography Volume. *Dental Clinics of North America*, 68(3), 687-709. 2014. 7. Aysever, H., Gunduz, K., Karakoc, O., Akyol, M., & Orhan, K. Incidental findings on cone-beam computed tomographic images: paranasal sinus findings and nasal septum variations. *Oral Radiology*, 34(1), 40-48. 2017. 8. Allareddy, V., Vincent, S. D., Hellestein, J. W., Qian, F., Smoker, W. R. K., & Rupprecht, A. Incidental Findings on Cone Beam Computed Tomography Images. *International Journal of Dentistry*, 2012, 1-9. 9. Raghav, M., Karjodkar, F., Sontakke, S., & Sansare, P. Prevalence of incidental maxillary sinus pathologies in dental patients on cone-beam computed tomographic images. *Contemporary Clinical Dentistry*, 5(3), 361. (2014). 10. Lopes, I. A., Tucunduva, R. M. A., Handem, R. H., & Capelozza, A. L. A. Study of the frequency and location of incidental findings of the maxillofacial region in different fields of view in CBCT scans. *Dentomaxillofacial Radiology*, 46(1), 2017. 11. Edwards, R., Alsufyani, N., Heo, G., & Flores-Mir, C. The frequency and nature of incidental findings in large-field cone beam computed tomography scans of an orthodontic sample. *Progress in Orthodontics*, 15(1), 2014. 12. Geist, J. R., Geist, S.-M. R. Y., & Lin, L.-M. A cone beam CT investigation of ponticulus posticus and lateralis in children and adolescents. *Dentomaxillofacial Radiology*, 43(5), 2014. 13. Chen, C.-H., Chen, Y.-K., & Wang, C.-K. Prevalence of ponticulus posticus among patients referred for dental examinations by cone-beam CT. *The Spine Journal*, 2015, 1270-1276. 14. Alsufyani, N. A. Cone beam computed tomography incidental findings of the cervical spine and clavus: retrospective analysis and review of the literature. *Oral Surgery, Oral Medicine, Oral Pathology and Oral Radiology*, 122(6), e197-e217. 2017. 15. Togan, B., et al. Incidence and frequency of non-dental incidental findings on cone-beam computed tomography. *Journal of Cranio-Maxillofacial Surgery* (2016). 16. Cha, J.-Y., Mah, J., & Sinclair, P. Incidental findings in the maxillofacial area with 3-dimensional cone-beam imaging. *American Journal of Orthodontics and Dentofacial Orthopedics*, 132(1), 7-14. 17. Damskos, S., Tsiklakis, K., Syriopoulos, K., & der Steit, P. van. (2014). Extra- and intra-cranial arterial calcifications in adults depicted as incidental findings on cone beam CT images. *Acta Odontologica Scandinavica*, 2007, 73(3), 202-209.