

ESTHETIC TREATMENT GUIDE

ESTHETIC IMPLANT SURGERY



JAIME A. GIL | ROBERT A. SADER | ALFONSO L. GIL



ESTHETIC TREATMENT GUIDE

VOLUME 1

ESTHETIC IMPLANT SURGERY

CO-EDITORS: ROBERT A. SADER, HOMAYOUN H. ZADEH

 QUINTESSENCE PUBLISHING

Berlin | Chicago | Tokyo
Barcelona | London | Milan | Paris | Prague | Seoul | Warsaw
Beijing | Istanbul | Sao Paulo | Sydney | Zagreb


INTERNATIONAL FEDERATION
OF ESTHETIC DENTISTRY



One book, one tree: In support of reforestation worldwide and to address the climate crisis, for every book sold Quintessence Publishing will plant a tree (<https://onetreepanted.org/>).



A CIP record for this book is available from the British Library.
ISBN: 978-1-78698-119-6

 **QUINTESSENCE PUBLISHING
DEUTSCHLAND**

Quintessenz Verlags-GmbH
Ifenpfad 2-4, 12107 Berlin,
Germany
www.quintessence-publishing.com

Quintessence Publishing Co Ltd
Grafton Road, New Malden, Surrey KT3 3AB
United Kingdom
www.quintessence-publishing.com

© 2025 Quintessenz Verlags-GmbH
All rights reserved. This book or any part thereof may not be reproduced, stored in a retrieval system, or transmitted in any form or by any means, whether electronic, mechanical, photocopying, or otherwise, without prior written permission of the publisher.

Editing, layout, production, and reproduction:
Quintessenz Verlags-GmbH, Berlin, Germany

ISBN: 978-1-78698-119-6

Printed and bound in Croatia

Editorial

ESTHETIC TREATMENT GUIDE

Dental specialties, each distinct in their planning, execution, and technical complexity, share a unified goal: the unwavering pursuit of oral esthetics. The smile, long the focal point of dentistry, has gained unprecedented importance in the era of social media, becoming a primary driver of our profession and a critical desire of patients.

Patients present with diverse problems that vary in complexity and involve the teeth, periodontium, maxillary and mandibular bone, and lips, and their functional dynamics. Achieving durable, functional, and esthetic restorations in a healthy periodontium demands the orchestrated efforts of several specialties working in unison to fulfill the expectations of patients.

Integrating specialties such as prosthodontics, periodontology, orthodontics, and implantology results in a multidisciplinary and interdisciplinary team approach. This fosters clear, coordinated communication, thereby improving clinical outcomes and enhancing patient care. Despite the longstanding focus of dental education on such integration, clinicians often encounter challenges in merging these fields into a cohesive treatment plan, which can lead to suboptimal esthetic results.

Currently, there is a notable gap in the literature. Thus, a comprehensive, detailed multispecialty treatment guideline that offers valuable planning insights and solutions for managing everyday clinical challenges and complications is required.


Quintessence, in collaboration with the International Federation of Esthetic Dentistry, is proud to announce the publication of a series titled *Esthetic Treatment Guide*. This series has been meticulously crafted to detail treatment protocols across every dental and oral specialty. It consists of seven volumes:

- Esthetic Implant Surgery
- Esthetic Implant Restorations
- Esthetic Periodontal Plastic Surgery
- Esthetic Direct Restorations
- Esthetic Indirect Restorations
- Esthetic Orthodontic Treatments
- Esthetic Orofacial Treatments

Each volume consists of 6–7 chapters and is structured to cover the spectrum of its specialty, with chapters outlining treatment concepts, esthetic principles, decision-making processes, clinical case resolutions, and summaries. Importantly, all protocols are grounded in recent and relevant scientific evidence and are written by a curated list of world-renowned authors and clinicians.

The objective of the *Esthetic Treatment Guide* is to provide clinicians with stepwise interdisciplinary protocols for treatment planning and to manage esthetic cases predictably and satisfactorily.

Jaime A. Gil
Robert A. Sader
Alfonso L. Gil



Jaime A. Gil, MD, DDS, PhD

Chairman of Prosthodontics, University of The Basque County, Bilbao, Spain

Robert A. Sader, MD, DMD, PhD

University Professor and Professor h.c. mult.
Department of Oral, Cranio-Maxillofacial and Facial Plastic Surgery, Medical Center, University Hospital, Goethe University, Frankfurt, Germany

Alfonso L. Gil, DDS, MSc, PhD

Assistant Professor, International University of Catalonia, Barcelona, Spain
Associate Faculty, University of Southern California, Los Angeles, CA, USA
Private Practice, Bilbao, Spain



Preface

VOLUME 1: ESTHETIC IMPLANT SURGERY

The surgical phase of implant therapy is critical to the final outcome, particularly the esthetic result. Significant progress has been made in refining the techniques, protocols, and materials used in dental implant therapy, as well as related procedures. Despite these advancements, biologic, technical, and esthetic complications still occur. These complications can often be avoided through a better understanding of the biologic responses, the adoption of evidence-based techniques and materials, and adherence to the protocols established by experienced experts in the field.

This volume of the IFED *Esthetic Treatment Guide*, titled *Esthetic Implant Surgery*, represents the convergence of the science and art of surgical implant therapy. This volume features contributions from some of the world's leading experts in implant surgical dentistry. The content draws from cutting-edge clinical and basic research, and the extensive clinical experience of these contributors. Each chapter explores key aspects of implant surgical therapy, providing readers with a comprehensive resource beneficial for clinical practice.

This volume emphasizes the surgical phase of interdisciplinary care and complements other volumes in this series, which focus on additional facets of esthetic treatment. By fostering an interdisciplinary approach, this volume promotes integrated patient care, aiming to optimize esthetic and functional outcomes.

We extend our sincere gratitude to the contributors of this volume for their valuable expertise and insights. We believe that the material included in this volume will serve as a valuable resource for clinicians, enhancing their ability to navigate the esthetic challenges of dental implant surgery with confidence and skill.

Thank you for embarking on this journey with us. We trust that the knowledge and strategies presented within these pages will not only improve your clinical practice but also contribute to the overall advancement of this evolving field.

Sincerely,
Robert A. Sader
Homayoun H. Zadeh





Table of Contents

Chapter 1: Esthetic implant site development 1

Ronald Jung, Alfonso L. Gil

Consequences of tooth extraction	2
Difficulty of implant placement	2
Alveolar ridge preservation	3
Conclusions	29
Acknowledgments	29
References	29

Chapter 2: Esthetic ridge augmentation with simultaneous implant placement 31

Ueli Grunder, David Schneider

Treatment concept	33
Treatment concept	34
Post-extraction healing period	35
Flap design	35
Implant placement	40
Conclusions	57
References	62

Chapter 3: Augmentation of anterior maxillary ridge defects 63

Istvan Urban, Isabella Rocchietta

Flap design	65
Conclusions	88
References	88
Bibliography	88

Chapter 4: Clinical concepts to enhance peri-implant soft tissue esthetics and peri-implant health 89

Markus Schlee, Daniel Thoma

Procedures	90
Conclusions	104
References	104

Chapter 5: Implant-related sinus augmentation procedures 105

Tiziano Testori, Behnam Shakibaie, Riccardo Scaini

Treatment and guidelines	106
Novel antrostomy design	110
Minimally invasive techniques in sinus floor elevation and augmentation	119
Microscope-guided external sinus floor elevation	120
Conclusions	128
References	128

Chapter 6: Immediate single-tooth replacement in the anterior maxilla 131

Stephen J. Chu, Stephanie M. Chu, Dennis P. Tarnow

Periodontal phenotype	132
Blood supply to the labial plate	132
Flapless tooth extraction and alveolar ridge preservation	133
Tooth extraction of single-rooted anterior teeth	134
Three-dimensional spatial implant placement in the anterior extraction socket	134
Gap distance and wound healing	134
Wound healing via secondary intention in the extraction socket	136
Hard tissue grafting of the gap	139
Bone thickness and ridge dimensional change	139
Peri-implant soft tissue thickness	141
Dual-zone socket management	141
Prosthetic socket sealing	145
Provisional crown restoration	145
Cement-versus screw-retained provisional and definitive restorations	154
Abutment selection: material and color considerations	155
Implant design for immediate tooth placement	156
Uniaxial versus biaxial implants	157
Implant design for immediate tooth placement	157
Conclusions	160
References	160

Table of Contents

Chapter 7: Esthetics and peri-implantitis 163

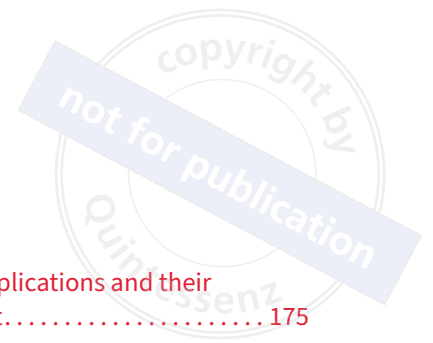*Ausra Ramanauskaite, Anton Sculean, Robert Sader,
Frank Schwarz*

Supracrestal soft tissue complex	164
Horizontal soft tissue dimensions	164
Vertical soft tissue dimensions	164
Factors associated with midfacial peri-implant mucosa height	164
Treatment of peri-implant soft tissue recession	166
Interproximal papilla fill	167
Esthetic compromise after secondary surgery	168
Relevance of soft tissue dimensions in maintaining peri-implant tissue health	170
Conclusions	171
References	171

Chapter 8: Esthetic complications and their management 175

Homa H. Zadeh, Luca Cordaro

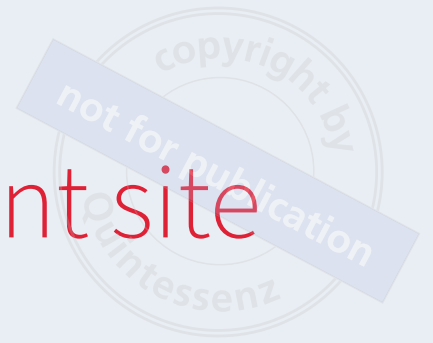Inflammatory complications	176
Mucosal dehiscence	178
Mucosal complications	178
Papillary discrepancies	179
Complications attributed to growth or remodeling	179
Alveolar ridge deficiencies	179
Clinical case reports	180
Conclusions	190
References	190



CHAPTER 1:

Esthetic implant site development

Ronald Jung, Alfonso L. Gil



Consequences of tooth extraction

After tooth extraction, the socket undergoes both physiologic and morphometric alterations at the level of the soft and hard tissues.¹ These typically include bone resorption in a horizontal direction (a 3.87-mm reduction in buccolingual ridge thickness) and a vertical direction (a 1.67-mm reduction in a vertical mid-buccal direction).²

Difficulty of implant placement

These bone volume alterations may hamper the feasibility of subsequent implant therapy,³ especially in the esthetic zone. In the anterior maxilla, the thickness of the buccal bone plate is less than 1 mm in most cases,⁴ making the extraction site very susceptible to accentuated bone volume loss if the socket is left to heal unassisted. The consequence of this resorption if an implant restoration is planned is the need for primary bone augmentation or simultaneous bone augmentation and implant placement.⁵ Such procedures are associated with prolonged healing times and increased morbidity for patients and might make the placement of dental implants in an ideal prosthetic position more difficult.

The decision-making process for selecting the optimal treatment solution should always start before tooth extraction and should be based on two relevant factors: (1) the anticipated morphologic alterations based on the patient's

presenting anatomy, and (2) the timing of implant placement after tooth extraction.

The decision tree in **Figure 1-1** starts with the question of whether implant placement is indicated and possible for the patient within 2 months of tooth extraction. If it is indeed possible to place the implant within 2 months after tooth extraction, then alveolar ridge preservation is not indicated. In this scenario, a second question is warranted: Is there a soft tissue deficiency and is soft tissue augmentation needed? If no soft tissue augmentation is necessary, the socket is left to heal spontaneously, either with immediate implant placement or with early (6–8 weeks later) implant placement. The choice of performing immediate or early implant placement is based on patient-related factors (lip line, esthetic expectations), clinical observations (soft tissue volume, periodontal phenotype, gingival margin, periodontal health, interproximal attachment) and radiographic evaluation (thickness of the buccal bone plate, bone deficiency).

If a soft tissue deficiency (buccal volume deficiency) or gingival recession in relation to the adjacent teeth exist, soft tissue augmentation is indicated to improve the deficient clinical situation. Such a procedure typically includes placing an autogenous graft, either a connective tissue graft (CTG) or a free gingival punch graft from the palate. Bone graft material may also be used. The timing of implant placement is usually 6 to 8 weeks later (early placement), once the soft tissue healing is completed and no more deficiency exists.

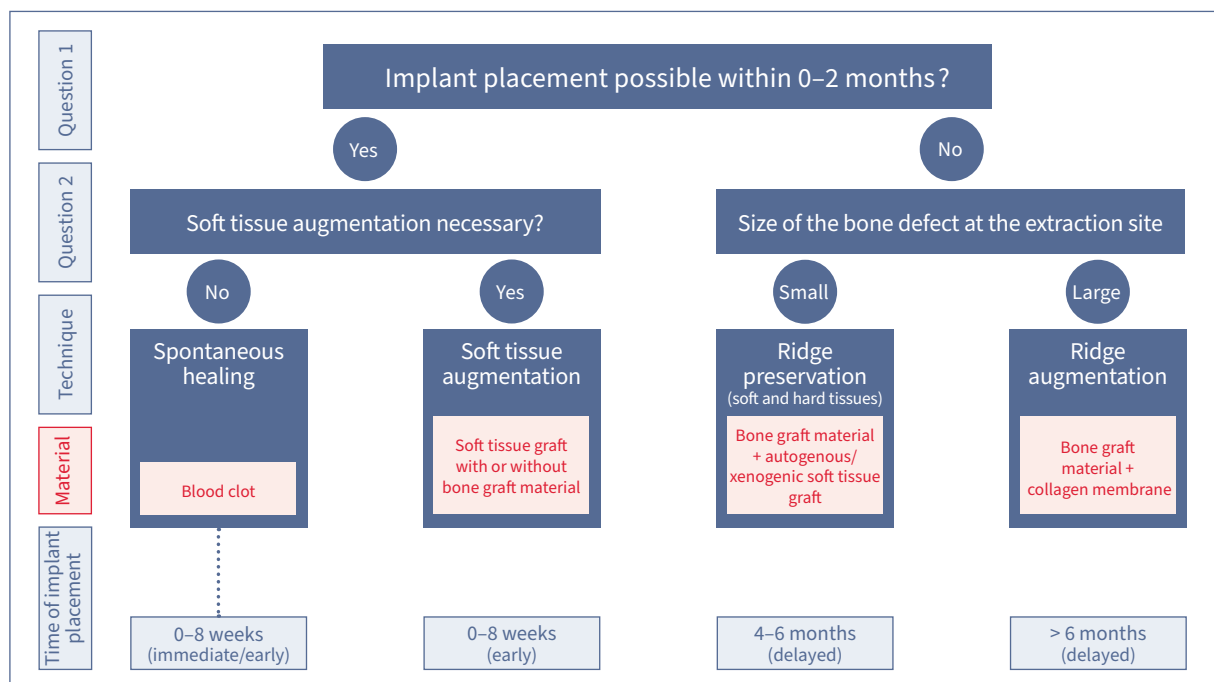


Figure 1-1 Tooth extraction decision tree.

Alveolar ridge preservation

If it is not possible to place the implant within 2 months from the time of extraction, alveolar ridge preservation is the recommended therapy. Depending on the characteristics of the bone deficiency, one of two procedures is indicated.

1. If the bone defect on the buccal side is small (less than 50% loss of buccal bone height), an alveolar ridge preservation technique with hard and soft tissue preservation should be performed with subsequent implant placement 4 to 6 months after. Hard tissue preservation consists of adapting a bone substitute material inside the socket and placing a soft tissue graft, with either an autogenous graft or a soft tissue substitute sealing the socket.
2. If the bone defect is advanced (more than 50% loss of buccal bone height), a guided bone regeneration (GBR) procedure with the objective of augmenting the deficient ridge is indicated with subsequent implant placement more than 6 months after. This bone augmentation procedure is typically performed with a bone substitute material that can be mixed with autogenous bone and placed both inside and outside the socket. The bone graft is then stabilized with a resorbable or nonresorbable membrane and left to heal for longer.

Recent evidence suggests that even in the presence of large buccal bone defects, the first type of ridge preservation can suffice to counteract the resorption processes and allow for subsequent implant placement within 4 to 6 months.⁶ This approach, however, requires long-term clinical evidence for validation.

Aim

The purpose of this chapter is to explain the different techniques available for ridge preservation after tooth extraction in relation to the following relevant clinical factors: invasiveness, technical complexity, clinical evidence, and soft tissue thickness.

Treatment and guidelines for alveolar ridge preservation

Alveolar ridge preservation is usually carried out with soft and hard tissue preservation performed using a minimally invasive flapless approach.^{7,8} Healing requires 4 to 6 months depending on the size of the socket; however, earlier implant placement is also possible and has been described in the literature.⁶

The evidence suggests that alveolar ridge preservation can attenuate the dimensional alterations of the socket that occur after tooth extraction. This therapy is most effective for reducing horizontal bone resorption, followed by vertical mid-buccal and vertical mid-lingual bone alterations.⁹

There is no preferred technique in terms of hard and soft tissue augmentation for ridge preservation, but there may be

some clinical advantages in choosing certain techniques or materials over others. In this section, we discuss the different approaches in terms of soft and hard tissue material selection and the healing period before implantation.^{9,10}

Hard tissue preservation


The bundle bone (cribriform plate) of the socket is a periodontal ligament-dependent structure. After the tooth is extracted, this thin plate undergoes osteoclastic activity and bone resorption. If the alveolar buccal bone plate is thin, most of this buccal bone plate is part of the bundle bone and will subsequently be lost.¹¹ The overlying soft tissue, devoid of its three-dimensional supporting scaffold, collapses within the socket, causing a 30% to 60% horizontal reduction and 10% to 20% vertical reduction of the alveolar ridge.¹² Bone grafts can be used to try to counteract this morphometric alteration by serving as a scaffold to support the outer soft tissue. The main advantage of this procedure is that it allows for subsequent implant placement without the need for further bone augmentation.^{13,14}

Four graft options exist for reducing volumetric changes in the socket after tooth extraction. Autogenous bone, allografts, xenografts, and alloplastic materials have all been described alone or in combination with blood derivatives or growth factors for bone regeneration.⁹ The sealing of the socket with different soft tissues is described next.

Most of the existing literature focuses on the use of bovine or porcine xenografts, as well as particulate allografts, which may help reduce the horizontal and vertical bone volumetric alterations in the socket after tooth extraction. Alloplastic materials have shown greater variability, more bone resorption, and less predictable results than xenografts or allografts.⁹ Autogenous bone grafts suffer an earlier resorption process, are associated with increased patient morbidity due to the need for a second surgical donor site, and are used less often for ridge preservation.

The bone graft material can be applied to the socket either in particulate form and compacted or as part of a block graft that is held together with collagen, trimmed, and adapted into the socket.

The reason why both xenografts and allografts show predictable results may be related to their osteoconductivity and biocompatibility.¹⁴ Both bone graft materials serve as a scaffold to preserve the structural integrity of the ridge and allow new vital bone formation to occur. Their rate of resorption may differ depending on the crystalline content of hydroxyapatite affecting the relationship between remaining bone substitute material and new vital bone formation. Allografts typically have a faster bone turnover than xenografts. They also present potential osteoinductive properties depending on their demineralization treatment processes.¹⁵ Xenografts, on the other hand, show a slower resorption process than allografts; although they lack the osteoinductive properties of allografts, they still undergo physiologic remodeling and become incorporated into bone over time.



Figures 1-2 to 1-5 Invasiveness (A), technical complexity (B), clinical evidence (C), and soft tissue volume (D) (+ = low; ++ = medium; +++ = high).

Soft tissue preservation

After the bone graft material is placed inside the socket, there are different ways to seal the socket with a soft tissue graft. The available options consist of using either an autogenous subepithelial connective tissue graft (SCTG) harvested from the tuberosity area or the palate, a free gingival punch graft from the palate, a soft tissue substitute, or resorbable or nonresorbable membranes. These sealing procedures are typically carried out using a flapless approach, focusing on preserving keratinized tissue and adapting the graft to the dimensions of the socket.

The soft tissue graft protects the bone graft material and stabilizes it, enhancing the closure of the alveolar wound. It also prevents the bone substitute biomaterial from becoming exposed or encapsulated in the overlying soft tissue.³

No specific graft or material for sealing the socket has been shown to provide superior outcomes in alveolar ridge preservation,⁹ suggesting that no single technique can be used for all indications. Finding the appropriate graft or material for each individual clinical situation is therefore necessary.

An autogenous soft tissue graft, either in punch or CTG form, seems to be the most suitable method for optimizing the ridge profile at the soft tissue level,¹⁶ as measured by soft tissue thickness. An autogenous graft, however, results in more morbidity and postoperative pain because it requires a second surgical site. This is the reason why soft tissue substitutes have been suggested as alternatives to autogenous grafts. They offer decreased morbidity for patients and increased ease of use for the dentist.¹⁷ The results are promising and show similar clinical outcomes as autogenous soft tissue grafts.¹⁸

The most commonly used combinations of soft and hard tissue grafts for alveolar ridge preservation are bovine bone substitute particulate material in conjunction with a collagen matrix or a punch graft from the palate. In addition, porcine xenografts and particulate allografts in combination with a resorbable collagen membrane or sponge have also been used extensively with favorable outcomes.⁹

Healing period

The postoperative healing time after alveolar ridge preservation is usually 4 to 6 months. The greater the dimensions of the socket and the greater the buccal bone dehiscence,


the longer the socket takes to heal. The healing process of a socket is centripetal, with new bone formation starting from the bony walls and extending toward the center of the alveolus.¹¹ This is why molars and premolars normally need more time for bone regeneration than incisors. The percentage of new vital bone and the turnover of the bone substitute material is higher the later the surgical reentry for implant placement takes place.¹⁹ The importance of new vital bone formation for implant survival is not yet clear. Intuitively, more new vital bone formation seems desirable because it might increase the rate at which the implant achieves stability and bone-to-implant contact. Nevertheless, there is a lack of literature clearly showing that the percentage of vital bone at implant sites directly affects implant survival, bone-to-implant contact, and esthetic parameters.

Studies have been performed to analyze shorter healing times after ridge preservation, with as little as 2 months for implant placement showing favorable results.^{20,21} In these scenarios, one should not remove the unincorporated bone graft that is still mineralizing while placing the implant. Shorter healing times before implant placement require further investigation for validation.

Clinical concepts for alveolar ridge preservation

Each therapeutic procedure for ridge preservation is explained in the following sections in the context of the following four factors: invasiveness (Figure 1-2), technical complexity (Figure 1-3), clinical evidence (Figure 1-4), and soft tissue volume (Figure 1-5). For every case, each of these factors is ranked as low (+), medium (++), or high (+++).

Clinical concept for hard and soft tissue Hard and soft tissue preservation using a soft tissue substitute (socket seal technique)



Patient

The patient was a healthy 45-year-old woman.

Chief complaint and esthetic expectations

The restorations on the maxillary central incisors had been placed 12 years ago, but the patient was unhappy with their esthetic appearance and wanted them replaced. The patient had low-to-moderate esthetic expectations due to her low lip line.

Clinical and radiographic findings

Clinical and radiographic evaluation revealed open margins on restorations 11 and 21, gingival recession, and deep subgingival caries on 11.

Diagnosis

Two insufficient maxillary anterior crowns on the central incisors, caries on 11, acquired gingival deformity on 11 (Figures 1-6 to 1-8).

Treatment plan

Extraction of tooth 11 with ridge preservation and subsequent implant placement. Placement of an implant-supported crown on tooth 11 and a tooth-supported crown on tooth 21.

Expected time for implant placement

The patient was in no hurry to receive the implant and accepted a long postoperative extraction healing time as long as she received a fixed provisional.

Tooth 11 was extracted in the least traumatic manner possible. After curetting and irrigating the socket, a block bovine bone substitute material was placed inside (Bio-Oss Collagen, Geistlich) (Figures 1-9 and 1-10). The soft tissue margins of the socket were de-epithelialized with a round bur. After adapting the bone graft to the dimensions of the socket, an 8-mm diameter resorbable collagen matrix (Mucograft Seal, Geistlich) was placed in the socket (Figure 1-11) and stabilized with 6-0 polyamide sutures (Figure 1-12). The collagen matrix was carefully adapted to the underlying bone and in contact with the sulcular margin. A fixed provisional was placed on tooth 21 with a mesial cantilever on missing tooth 11 (Figure 1-13). The socket was left to heal for 4 months.

After 4 months of healing, a CBCT scan of site 11 was taken (Figure 1-14). The scan showed preserved bone volume in the socket in both horizontal and vertical dimensions with well-integrated bone graft material. The clinical situation corroborated the radiographic findings (Figure 1-15), showing a healed ridge with similar volumetric dimensions to the adjacent central and lateral incisors. An implant was planned for site 11.

A crestal incision was performed, and a full-thickness flap was raised in site 11 (Figure 1-16). The horizontal bone width

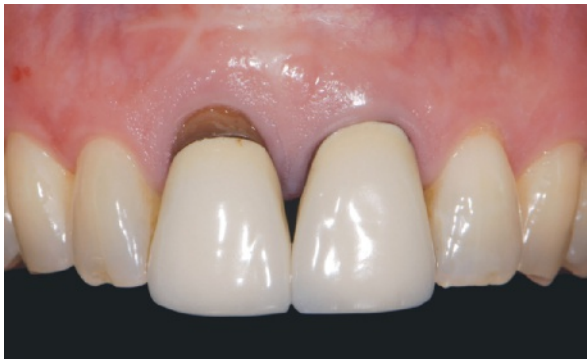

Figure 1-6 Buccal view of the initial clinical situation with two insufficient crowns.

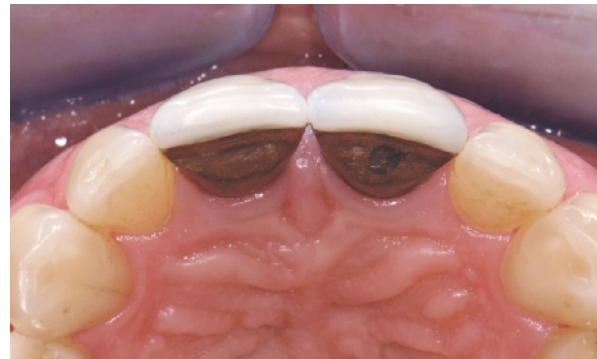

Figure 1-7 Occlusal view of the initial clinical situation.

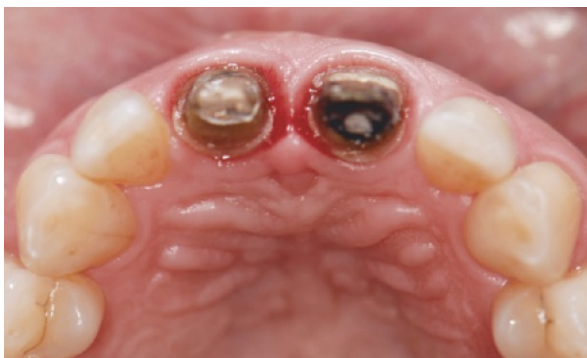

Figure 1-8 Abutment teeth after removing the crowns.

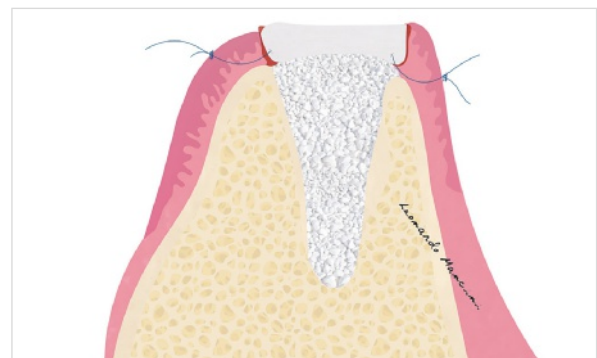


Figure 1-9 Ridge preservation. Hard tissue preservation with a bovine bone substitute material in block form. Soft tissue preservation with a collagen matrix. The healing time was 4 months.

copyright by
not for publication

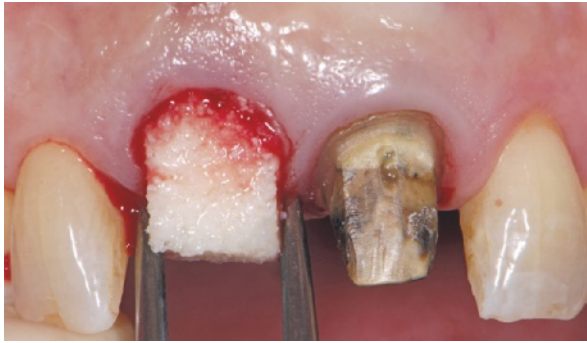

Figure 1-10 Placement of bone substitute material into the socket.

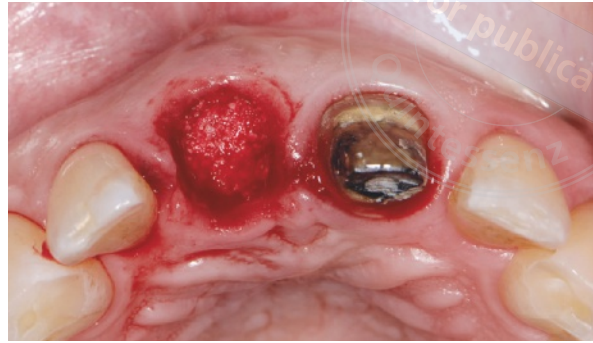


Figure 1-11 The bone graft is compacted inside the socket.

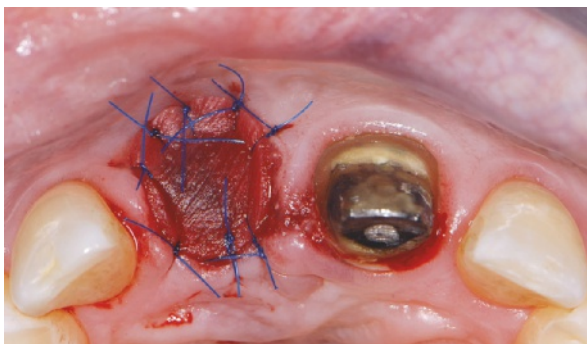


Figure 1-12 A collagen matrix is sutured and stabilized, sealing the socket.

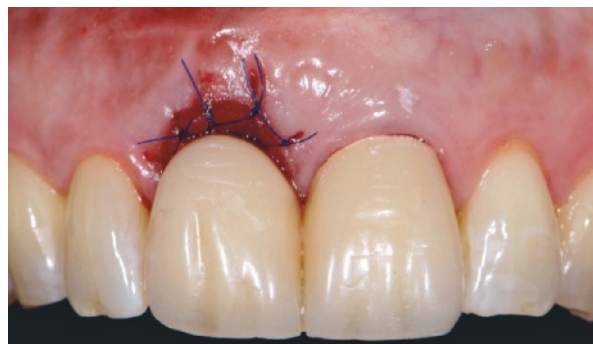


Figure 1-13 A provisional cantilever restoration is cemented on tooth 21.

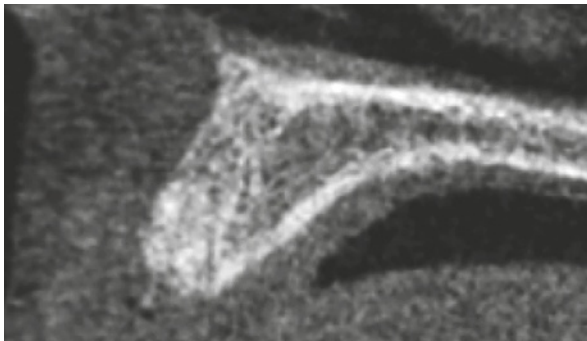


Figure 1-14 CBCT at 4 months of healing with integrated bone graft.

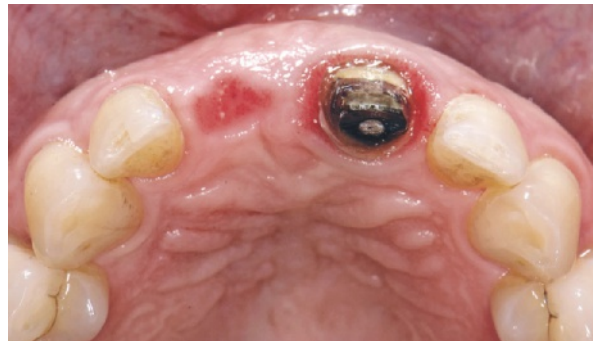

Figure 1-15 The ridge at 4 months of healing with adequate volume maintenance.

was preserved so that the implant could be placed at an ideal prosthetic position with sufficient bone surrounding the implant (Figure 1-17). There was no need for GBR. The implant was left submerged for 3 months to heal after which abutment connection was performed and an impression was taken.

An implant-supported provisional restoration was provided to the patient for 3 months to develop the emergence profile (Figure 1-18). After this provisional phase, a definitive conventional impression was taken of the right central

incisor implant and the left central incisor to manufacture single all-ceramic restorations. The implant received a porcelain-fused-to-metal screw-retained restoration, and tooth 21 also received a porcelain-fused-to-metal restoration (Figure 1-19). The implant- and tooth-supported restorations possessed similar optical properties in relation to the patient's existing dentition, and the patient was satisfied with their esthetics and functionality (Figures 1-20 and 1-21). The periapical radiograph taken at the 5-year follow-up showed stable marginal bone levels (Figures 1-22 and 1-23).

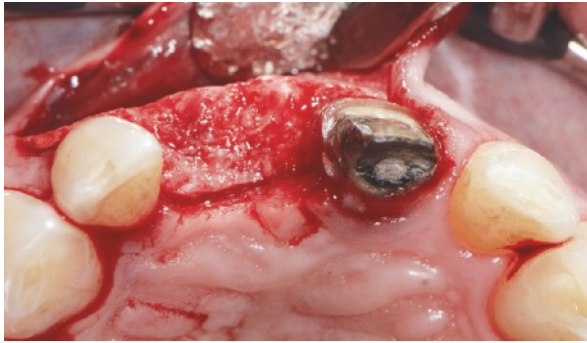
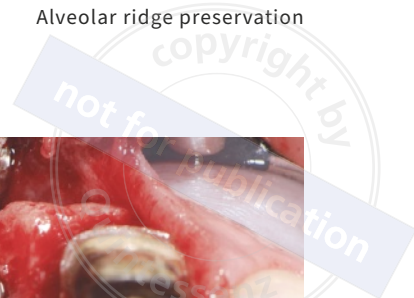

Figure 1-16 After flap elevation, the ridge appears well maintained and the bone graft is well integrated.

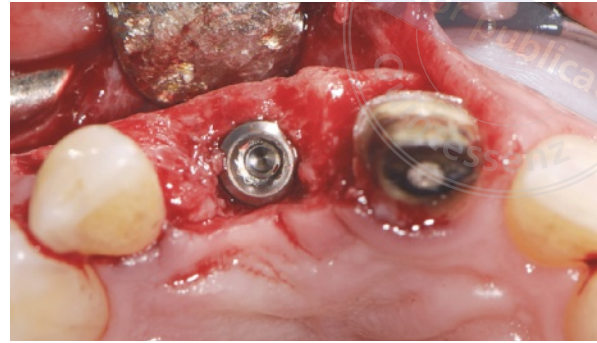

Figure 1-17 Implant placement with adequate bone surrounding the implant.

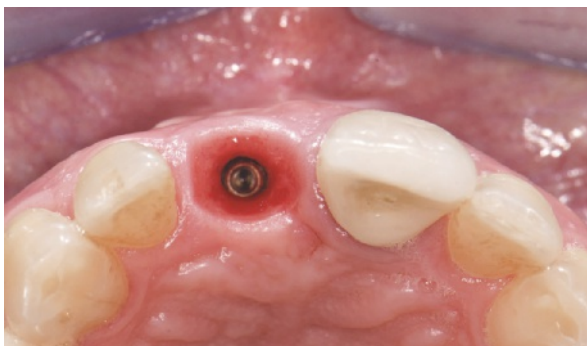


Figure 1-18 Emergence profile after the provisional phase.

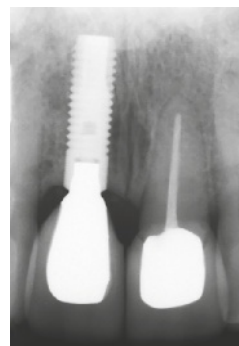


Figure 1-19 Periapical radiograph showing adequate fit and stable bone margins.

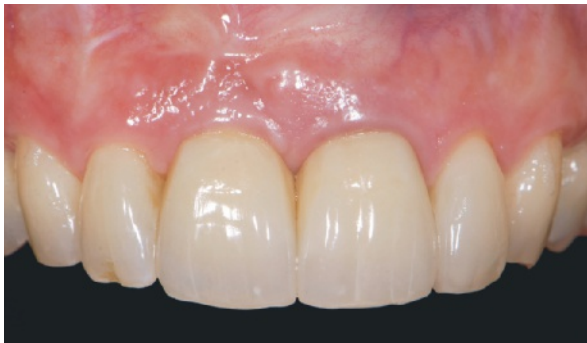

Figure 1-20 Implant-supported crown in the site of the right central incisor and tooth-supported crown on the left central incisor.

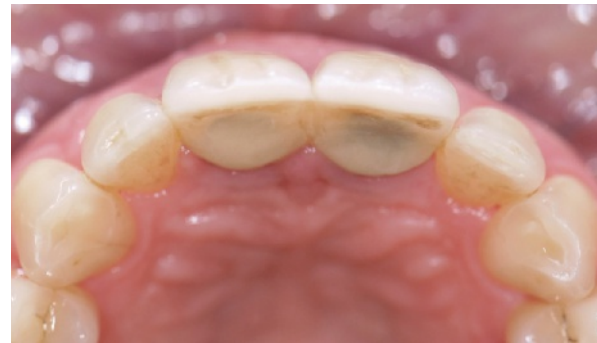

Figure 1-21 Screw-retained restoration in site 11 and cemented crown on tooth 21.

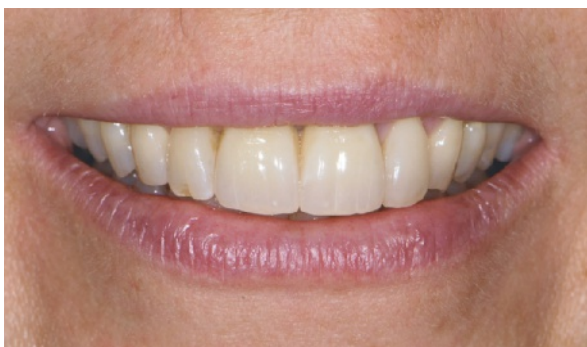

Figure 1-22 The restorations blend in with the patient's smile.

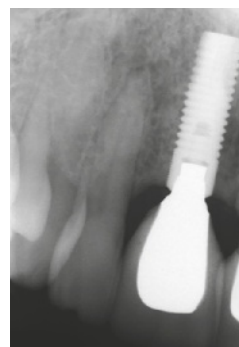

Figure 1-23 The periapical radiograph shows stable marginal bone levels after 5 years.

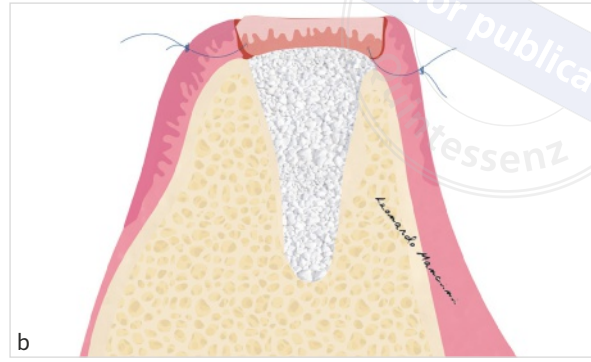
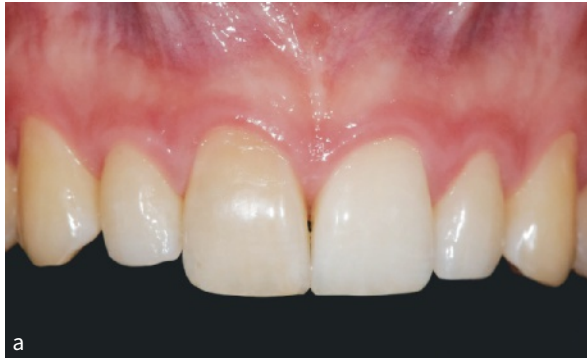

Figure 1-24a, b View of the initial clinical situation. Ridge preservation. Hard tissue preservation with a bovine bone substitute material in block form. Soft tissue preservation with a free gingival punch graft from the palate.

Rationale for performing ridge preservation

Invasiveness

Combining a xenograft for hard tissue preservation with a xenogeneic collagen matrix for sealing the socket entails minimal invasiveness and morbidity for the patient because there is no need for a second surgical site.

Technical complexity

The grafting procedure does not require advanced technical skills because the biomaterial is easy to handle and place.


Clinical evidence

There is plenty of clinical evidence to support the use of a collagen matrix and a bone substitute for ridge preservation.⁹ Studies showed high implant survival rates, stable marginal bone levels, and preservation of the bone volume.^{13,22}

Soft tissue volume

Given the patient's low expectations, low lip line, and thick phenotype, there was no need to harvest an autogenous graft to develop the soft tissue profile. The expected volume gain for the soft tissue surrounding the implant with a collagen matrix was acceptable.

Clinical concept for hard and soft tissue Hard and soft tissue preservation using an autogenous free gingival punch graft



Patient

The patient was a healthy 20-year-old man.

Chief complaint and esthetic expectations

The patient had been involved in an accident 5 years before that caused trauma to tooth 11, which was treated with a

root canal. Tooth 11 was still sensitive and exhibited recurrent infection at the time of the consultation. The patient came from a family of dentists and had very high esthetic expectations.

Clinical and radiographic findings

Clinical evaluation revealed deep isolated probing (9 mm), gingival recession, recurrent abscess, and sensitivity to percussion (Figure 1-24). The radiograph showed a periapical lesion around tooth 11 extending to the buccal side and the periapical region of tooth 12, with partial obliteration of the buccal bone wall (Figure 1-25).

Diagnosis

Vertical root fracture of tooth 11.

Treatment plan

Extraction of tooth 11 with ridge preservation, subsequent implant placement, and placement of an implant-supported crown (Figures 1-26 to 1-29).

Expected time for implant placement

Because of the patient's exam schedule at university, he could not receive an immediate or early implant after extraction and gladly accepted a long postoperative extraction healing time.

Hard tissue preservation

A bovine bone substitute material in block form.

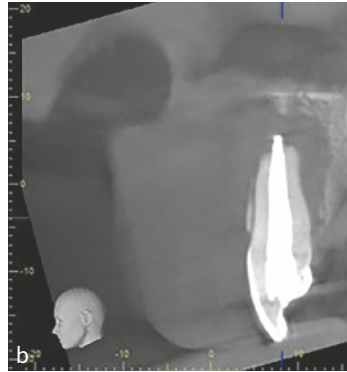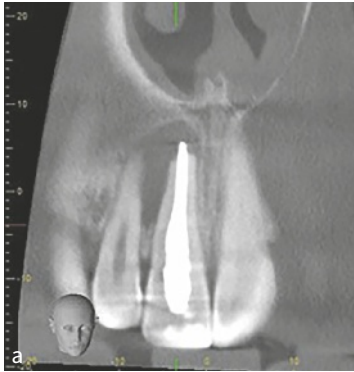
Soft tissue preservation

Palatal punch graft with 2-mm thickness.

Healing time

Six months.

After 6 months of healing, the clinical situation showed preservation of the ridge volume (Figures 1-30 and 1-31), and an implant was placed in the site of the right central incisor. A crestal incision was connected to a vertical releasing incision on tooth 12. A full-thickness flap was raised, showing an adequately healed socket with new bone forma-



Figures 1-25a, b CBCT showing advanced bone loss around tooth 11.

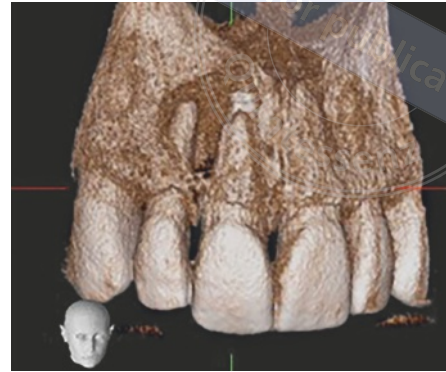

Figure 1-26 Ridge preservation. Hard tissue preservation with a bovine bone substitute material in block form. Soft tissue preservation with a free gingival punch graft.

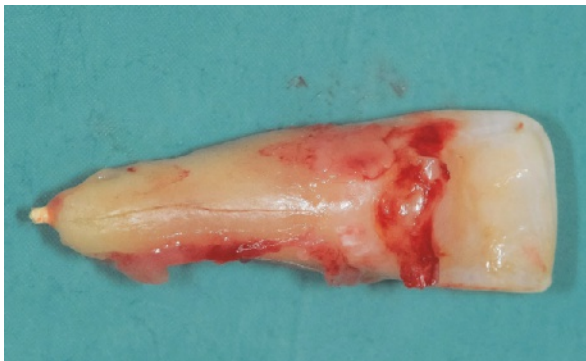

Figure 1-27 Tooth 11 was carefully luxated and extracted. The socket was curetted and irrigated profusely to eliminate the inflammatory granulation tissue.

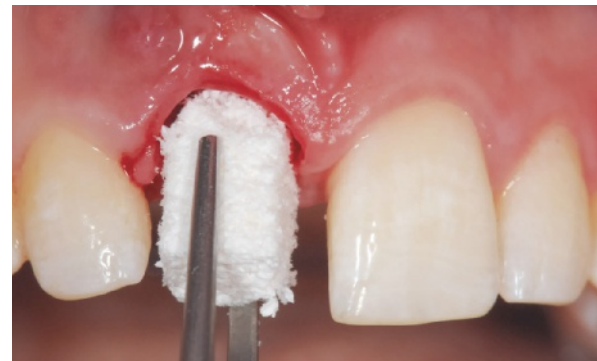

Figure 1-28 Once the infectious granulation tissue had been completely removed, a block of bovine bone substitute material (Bio-Oss Collagen) was stabilized in the socket.

tion (Figures 1-32 and 1-33). An implant was placed in a prosthetically ideal position for a screw-retained restoration (Figure 1-34). Because of a small bone dehiscence on the buccal side of the implant (Figure 1-35), a GBR procedure was carried out simultaneously with implant placement. GBR was performed with a bovine bone substitute with collagen in a block shape (Bio-Oss Collagen), covered with a resorbable collagen membrane (Bio-Gide, Geistlich), fixed with resorbable pins (LeadFIX Pins, Karr Dental) (Figures 1-36 and 1-37). After stabilizing the bone graft, a periosteal releasing incision was performed to allow proper flap closure. A short healing abutment was placed on the implant (Figure 1-38). The flap was sutured with 5-0 polyamide sutures with horizontal mattress sutures and single interrupted sutures (Figures 1-39 and 1-40). Primary closure was achieved with no existing tension.

After 3 months of healing, a provisional was placed on the implant (Figures 1-41 and 1-42) with enough pressure applied on the buccal side to shape the emergence profile to mimic the form of the adjacent teeth. After the provisional phase, the emergence profile showed adequate soft tissue quantity and quality (Figures 1-43 and 1-44). The definitive restoration was a screw-retained veneered zirconia restor-

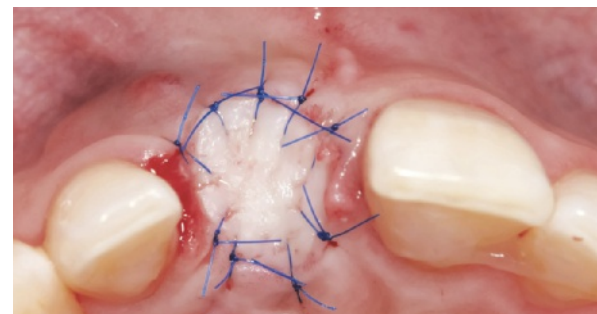
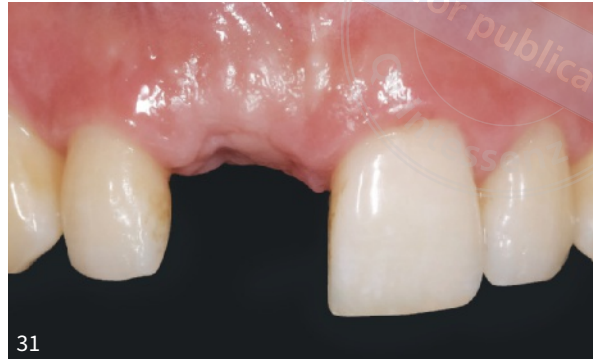
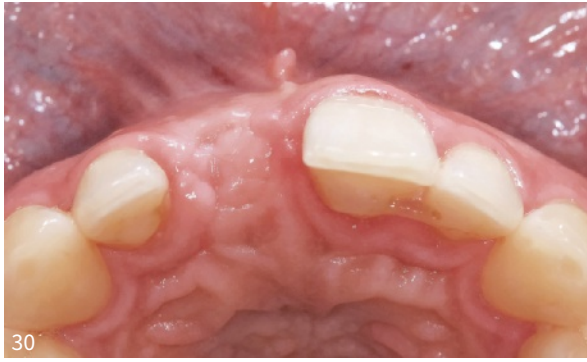
Figure 1-29 De-epithelialization of the sulcular margins was carried out with a straight preparation diamond bur. An autogenous free gingival punch graft with 2-mm thickness was harvested from the palate and sutured in close contact with the de-epithelialized sulcular margin, thus covering the bone graft.

ation (Figures 1-45 and 1-46). The esthetic outcome of the treatment fulfilled the patient's expectations (Figure 1-47) and remained stable at 3 and 8 years of follow-up (Figures 1-48 and 1-49).

copyright by
not for publication



Figures 1-30 and 1-31 Clinical situation after 6 months of healing.

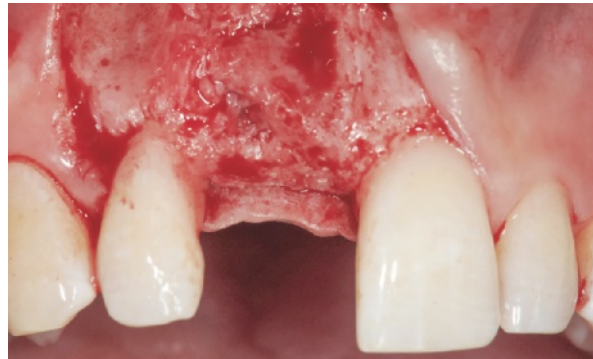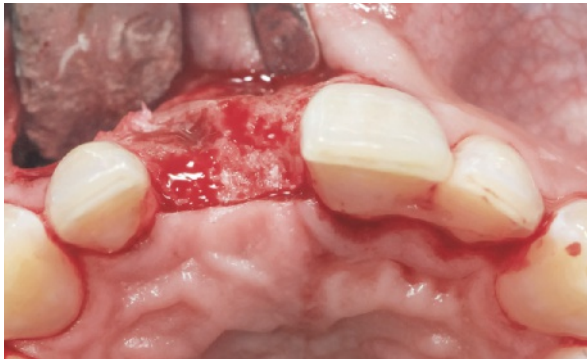


Figure 1-32 Bone crest with enough width.

Figure 1-33 Buccal flap with a distal vertical incision.

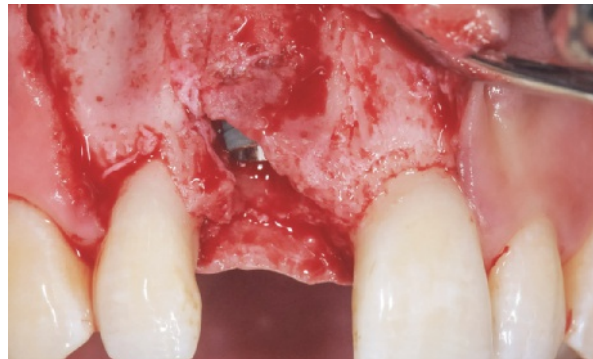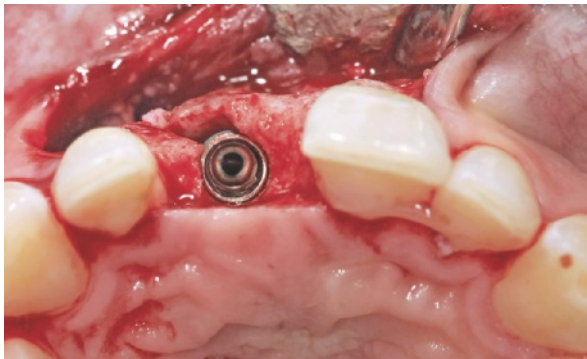
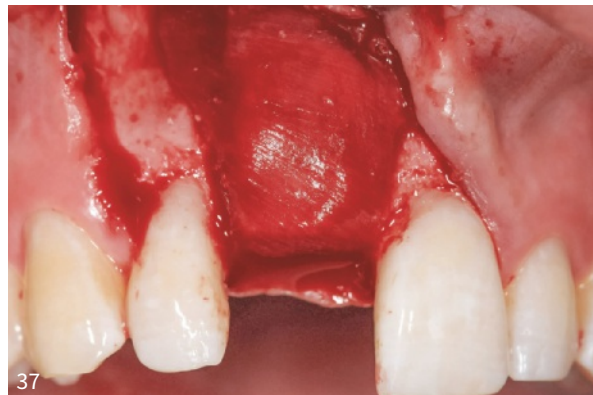

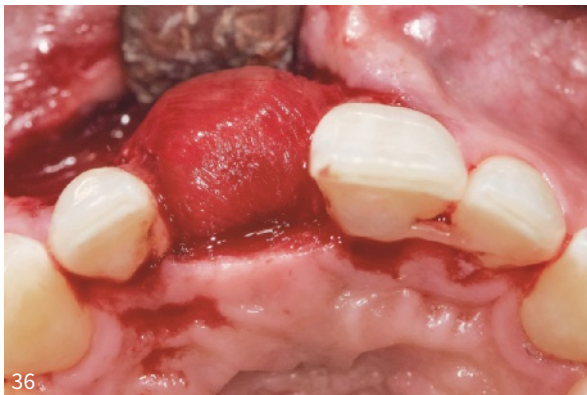
Figure 1-34 Implant placed for a screw-retained restoration.

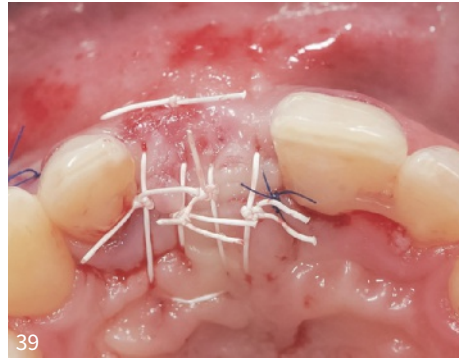
Figure 1-35 Implant placed with a small buccal bone dehiscence.



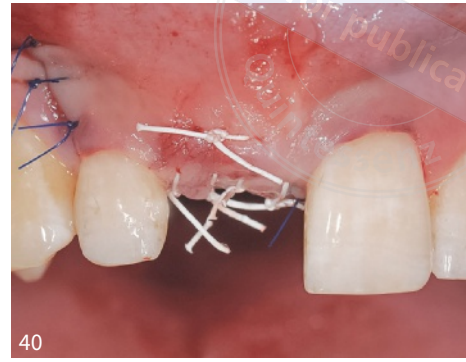
Figures 1-36 and 1-37 GBR with bone graft and a resorbable collagen membrane.

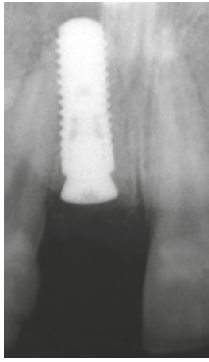

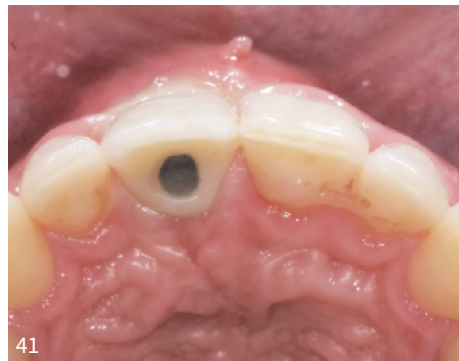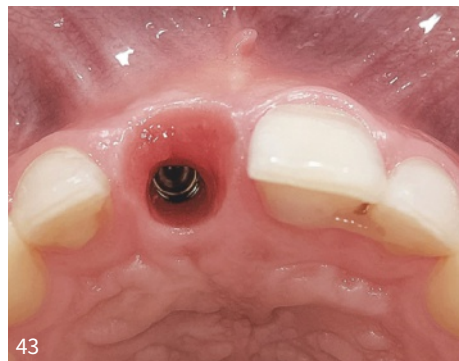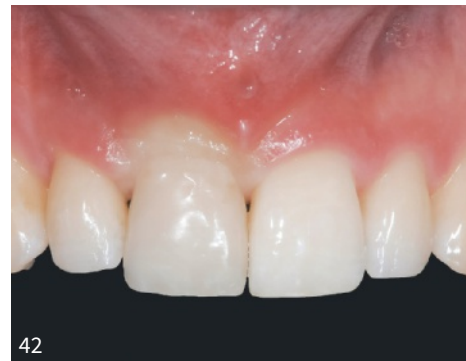Figure 1-38 Implant placed in site 11.



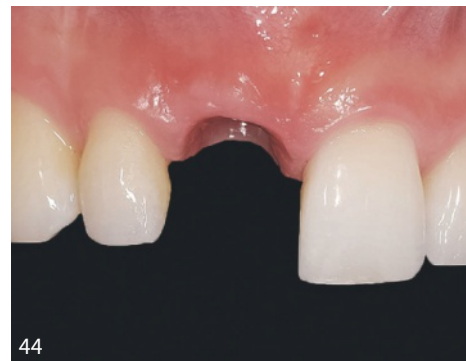Figures 1-39 and 1-40 Primary closure with nonresorbable sutures.



Figures 1-41 and 1-42 Provisional restoration on the implant in the site of the right central incisor.



Figures 1-43 and 1-44 Emergence profile with adequate soft tissue volume.



Rationale for performing ridge preservation

Invasiveness

A punch graft from the palate entails medium invasiveness as it requires an additional surgical harvesting site in the palate, albeit a minimally invasive one.

Technical complexity

The surgical skills required to harvest a palatal punch graft are low to medium. It is more difficult than using a synthetic soft tissue graft because the punch graft needs to be trimmed and carefully adapted to the socket dimensions using sutures.

Clinical evidence

There is plenty of literature supporting the use of this combined approach with high implant survival rates and stable soft and hard tissue preservation.^{7,13,22}

Soft tissue volume

Punch grafts may improve the soft tissue situation, especially in cases where there is an existing soft tissue deficit. The patient in this case presented with an existing recession on the maxillary right central incisor and was provided with an esthetically pleasing restoration thanks to the combination of different procedures.

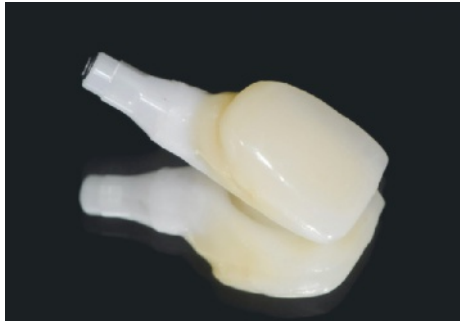
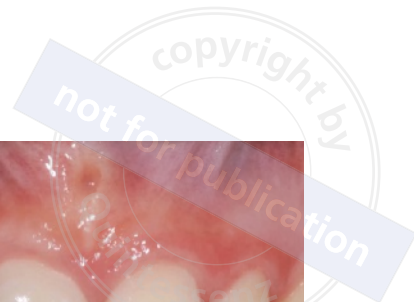

Figure 1-45 Milled zirconia crown with buccal veneering ceramic.

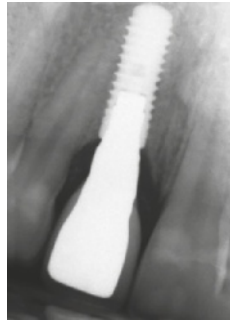

Figure 1-46 Periapical radiograph showing adequate fit.

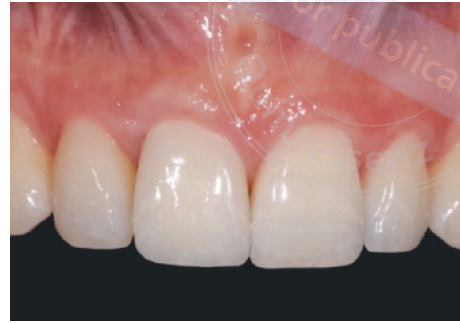

Figure 1-47 Adequate integration of the implant-supported ceramic restoration.

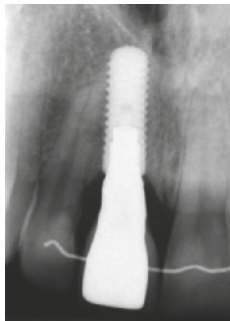


Figure 1-48 Radiograph at the 3-year follow-up.

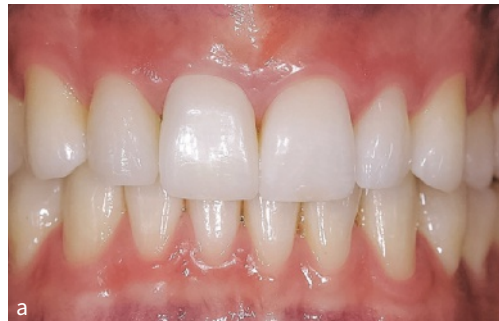


Figure 1-49a Stable implant restoration and soft tissue contour at the 8-year follow-up.

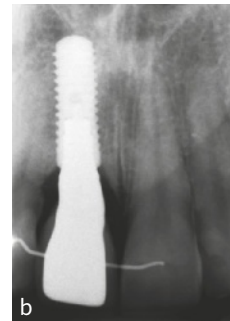

Figure 1-49b Radiograph at the 8-year follow-up showing stable marginal bone levels.

Hard and soft tissue preservation using a rotated connective tissue pedicle graft



Patient

The patient was a healthy 35-year-old woman.

Chief complaint and esthetic expectations

The patient was referred to the clinic with a chronic infection on tooth 11 and high esthetic expectations (Figure 1-50). Tooth 11 had suffered trauma 10 years ago and was treated with multiple root canals that did not resolve the persisting periapical radiolucency.

Clinical and radiographic findings

Clinical and radiographic findings included a buccal abscess (Figure 1-51), a deep (11 mm) isolated pocket, and absence of the buccal bone revealed via radiograph (Figure 1-52).

Diagnosis

Vertical root fracture of tooth 11.

Treatment plan

Extraction of tooth 11 with ridge preservation, delayed implant placement, and placement of an all-ceramic implant-supported single crown along with placement of a new ceramic veneer on tooth 21.

Expected time for implant placement

The patient wanted to wait at least 6 months for implant placement due to financial reasons.

Ridge preservation

Hard tissue preservation: bovine bone substitute material in block form. Soft tissue preservation: split-thickness pedicle palatal graft.

Healing time

Six months (Figure 1-53).

Treatment

Tooth 11 was luxated and carefully extracted (Figure 1-54). The ridge preservation procedure entailed using a block bovine bone substitute material (Bio-Oss Collagen) covered with a resorbable collagen membrane (Bio-Gide) to cover the missing buccal bone in conjunction with a rotated pedicle graft from the palate (Figure 1-55). The socket was then sealed with cyanoacrylate glue (Figure 1-56) and provisionalized with a resin-bonded bridge.

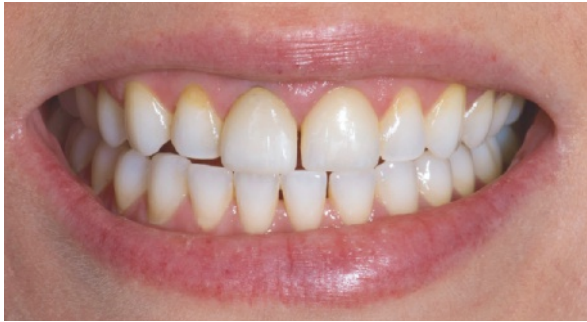

Figure 1-50 Initial clinical situation and smile line.

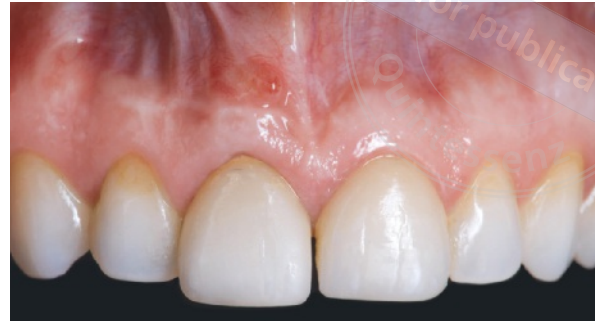

Figure 1-51 Initial clinical situation with a diastema between the maxillary central incisors and a buccal fistula on tooth 11.

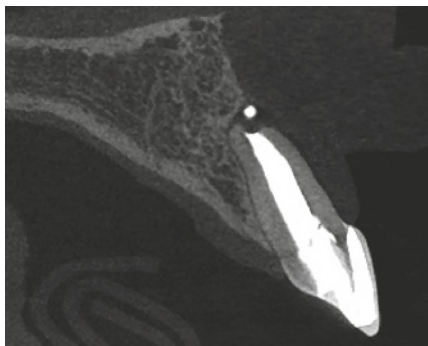


Figure 1-52 CBCT showing obliteration of the buccal bone wall of tooth 11.

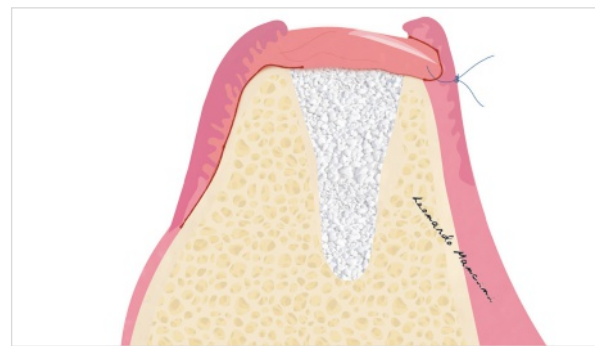


Figure 1-53 Ridge preservation. Hard tissue preservation: bovine bone substitute material in block form. Soft tissue preservation: split-thickness pedicle graft.

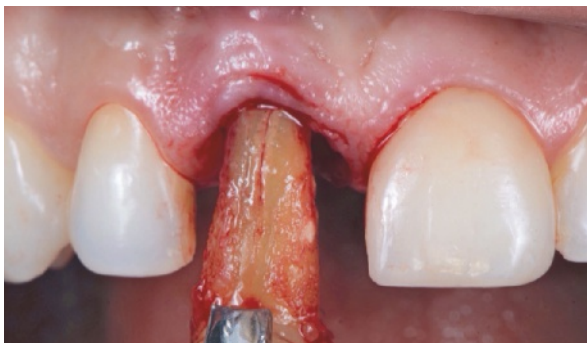

Figure 1-54 Tooth 11 with a vertical root fracture is extracted.

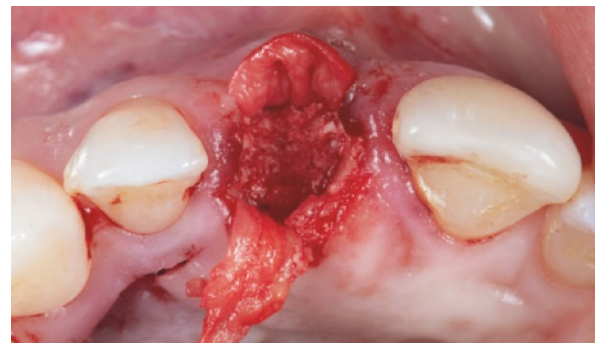


Figure 1-55 Ridge preservation with a bone graft with a collagen membrane on the buccal side and with a pedicle graft.

The ridge was left to heal for 6 months, after which a digital impression and a CBCT scan were taken. Both files were superimposed with digital software to allow for guided implant planning at a prosthetically ideal position. Implant placement in the site of the right central incisor was performed via a fully guided procedure through an open surgical guide (Figures 1-57 to 1-59). The ridge dimensions were ideal for the placement of a screw-retained implant, as was the quality of the grafted bone (Figure 1-60). No GBR was necessary. The subepithelial connective tissue was stabilized occlusally and buccally to the implant (Figure 1-61), and the implant was left to heal for 3 months (Figure 1-62). After healing, a provisional was used for 4 months to adequately condition the shape of the emergence profile. Once

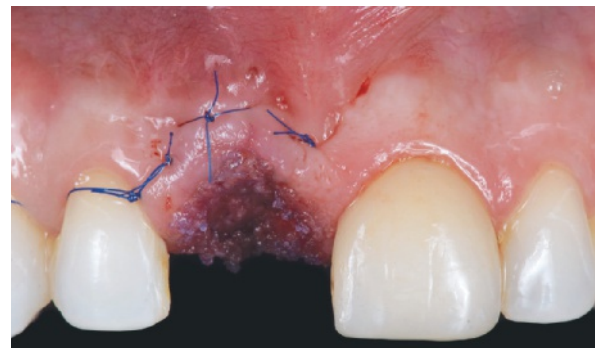


Figure 1-56 Alveolar ridge preservation performed and finalized with cyanoacrylate glue on the socket surface.

copyright by
not for publication

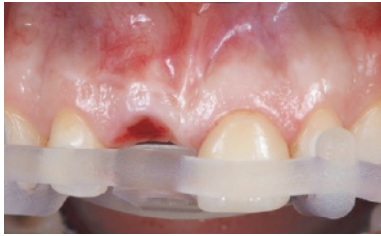

Figure 1-57 Guided implant placement.

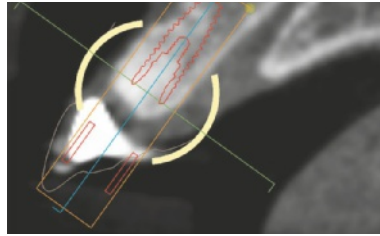


Figure 1-58 CBCT shows the implant planning with an adequately healed ridge and a screw-retained implant.

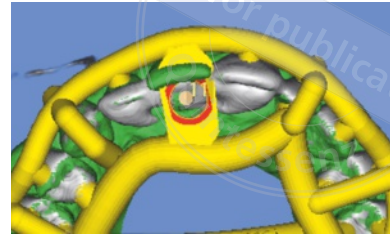


Figure 1-59 Digital planning of the implant guide.

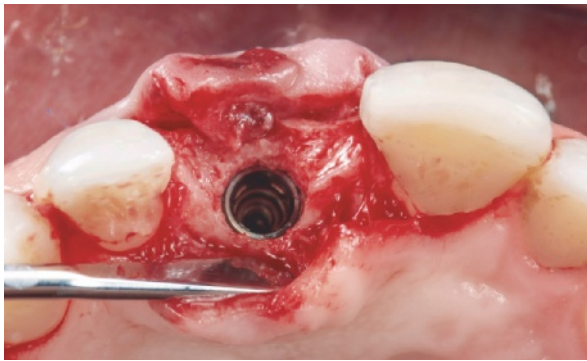


Figure 1-60 Sufficient bone for implant placement.

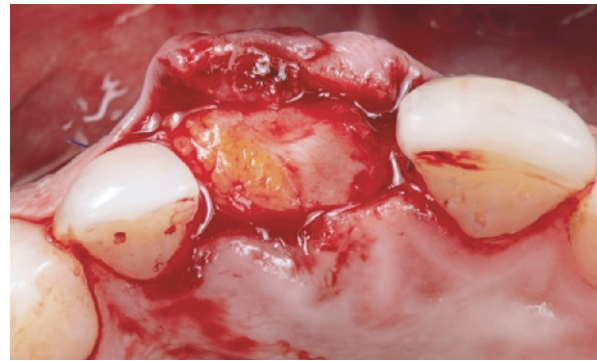


Figure 1-61 Occlusal view of the SCTG.

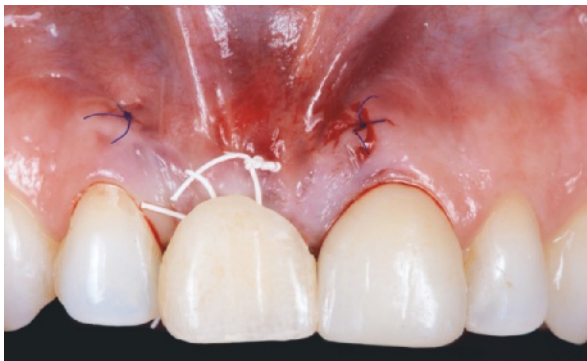


Figure 1-62 Primary closure with sutures and the placement of a provisional resin-bonded partial denture.

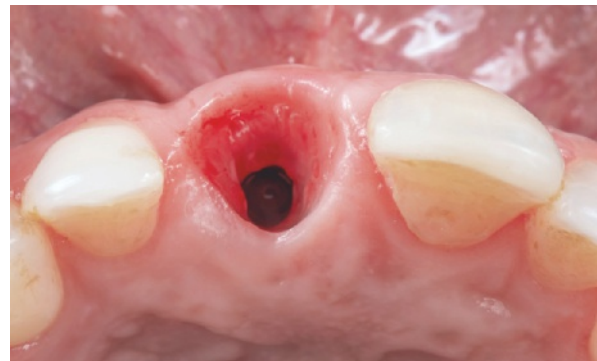


Figure 1-63 Emergence profile after 4 months of provisionalization.

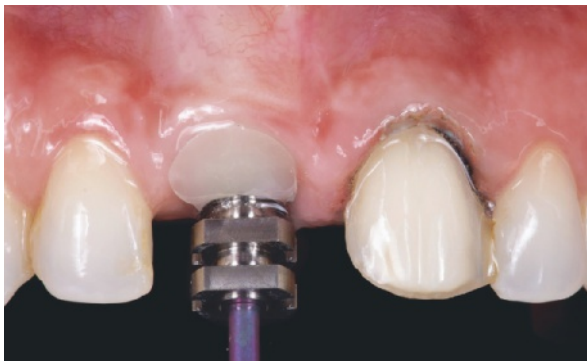


Figure 1-64 Individualized impression coping.

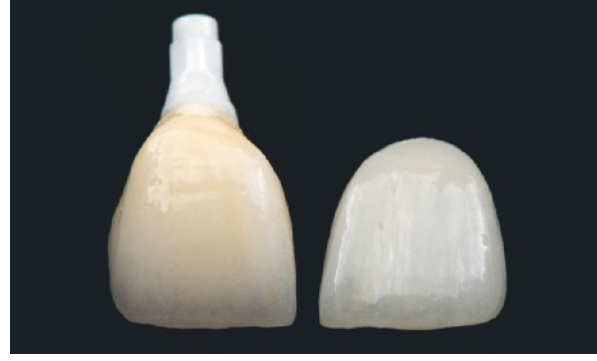
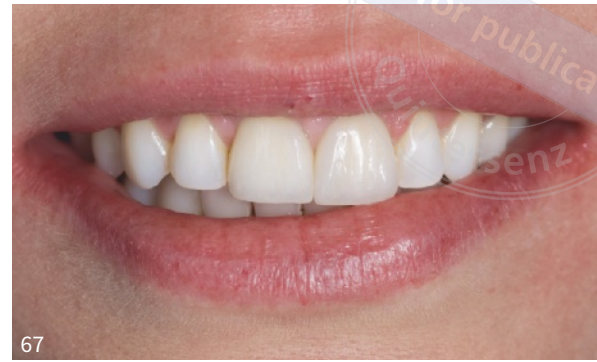
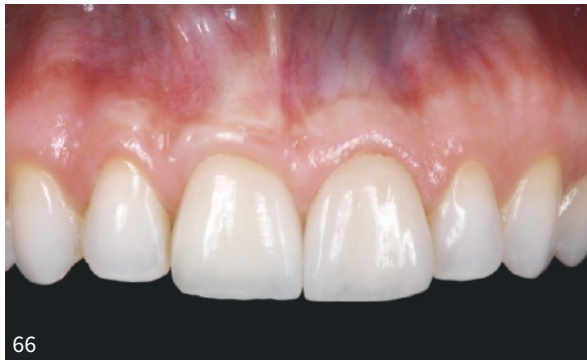Figure 1-65 Implant-supported zirconia crown with veneering ceramic and the feldspathic veneer.



Figures 1-66 and 1-67 The implant-supported restoration and ceramic veneer blend in with the patient's dentition.

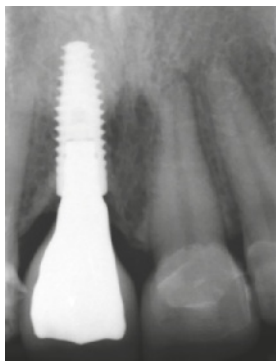

Figure 1-68 Adequate fit shown on the periapical radiograph.

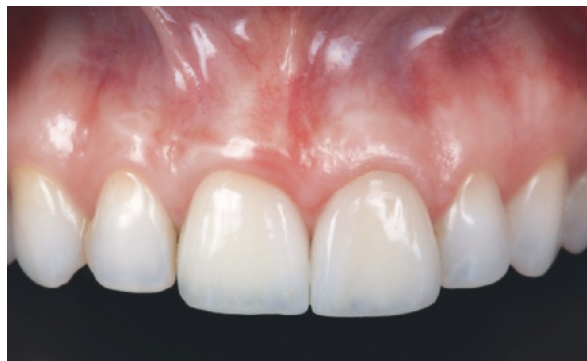

Figure 1-69 Adequate soft tissue at the 2-year follow-up.

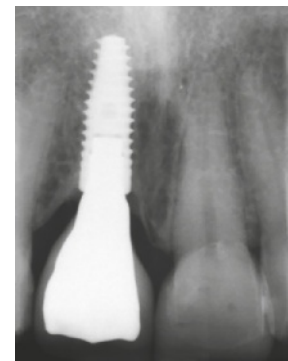


Figure 1-70 Periapical radiograph showing stable marginal bone levels.

the emergence profile resembled that of the adjacent central incisor (Figure 1-63), an individualized impression of the central incisors was taken (Figure 1-64).

A screw-retained zirconia implant restoration with buccal veneering for the site of the right central incisor and a feldspathic veneer for tooth 21 were manufactured (Figure 1-65). The implant-supported restoration was delivered, and the ceramic veneer was cemented to tooth 21 (Figures 1-66 to 1-68). Both restorations were followed for 2 years. The patient was very pleased with the esthetic appearance of the restorations. After 2 years, the implant remained healthy with stable marginal bone levels and peri-implant mucosa (Figures 1-69 and 1-70).

Rationale for performing ridge preservation

Invasiveness

The use of a rotated pedicle graft from the palate entails medium-to-high invasiveness because it requires an addi-

tional split-thickness flap with increased intraoperative bleeding and postoperative swelling.

Technical complexity

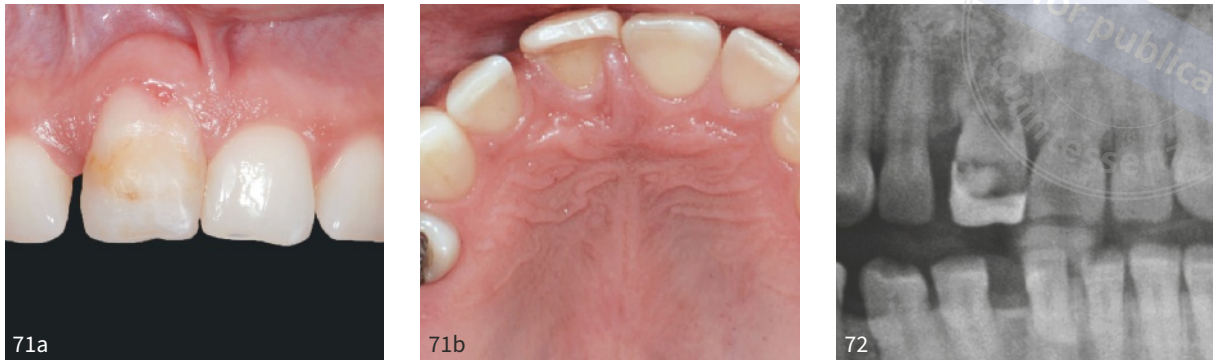The technical skills required are very high because of the need to perform a partial-thickness flap on the palate and on the buccal side to insert the resorbable collagen membrane and secure the pedicle flap.

Clinical evidence

The evidence to support this approach is very limited, with few case reports in the literature.²³

Soft tissue volume

The interventions in this complex case led to harmonious soft and hard tissue integration. The use of a pedicle graft had the advantage of maintaining vascularization of the graft from the end attached to the palate, which may reduce shrinkage.



Figures 1-71 and 1-72 Initial clinical situation with deficient tooth 11. The panoramic radiograph shows root resorption and ankylosis of tooth 11.

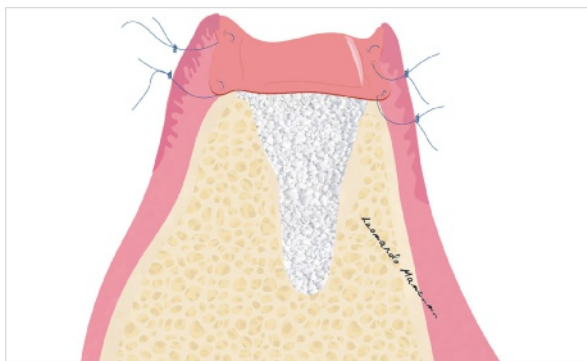


Figure 1-73 Ridge preservation. Hard tissue preservation: bovine bone material in particulate form. Soft tissue preservation: SCTG.

Hard and soft tissue preservation using an autogenous SCTG



Patient

The patient was a healthy 39-year-old woman.

Chief complaint and esthetic expectations

The patient had an ankylosed maxillary right central incisor with asymmetric gingival margins and crown forms. Tooth 11 had suffered trauma 20 years ago, had a coronal fracture, and was treated with a composite restoration that was asymmetric and unsatisfying. The patient had suffered from esthetic concerns since childhood and from referred pain and strong bleeding on the buccal margin of tooth 11. In addition, she had high esthetic expectations.

Clinical and radiographic findings

Evaluation revealed gingival recession, external root resorption with associated bleeding, distal diastema, and asymmetric clinical crowns (Figures 1-71 and 1-72).

Diagnosis

Ankylosed tooth 11 with associated root resorption.

Treatment plan

Extraction of tooth 11 combined with ridge preservation (Figure 1-73), tooth alignment with orthodontic treatment, delayed implant placement, and placement of an all-ceramic single-crown implant-supported restoration on tooth 11 and new ceramic veneers for teeth 12 and 21.

Expected time for implant placement

The patient accepted the planned implant restoration on tooth 11 after orthodontic treatment. She expressed no time concerns for receiving the implant.

Ridge preservation

Hard tissue preservation: bovine bone substitute material in particulate form. Soft tissue preservation: SCTG from the palate.

Healing time

Four months.

Treatment performed

The coronal part of tooth 11 was extracted (Figure 1-74). The apical part of the root was fused to the alveolar bone. Clinicians should make every effort to remove the ankylosed tooth remnants. However, special attention should be given to avoid removing any vital bone structure. A tunnel approach was performed on the papilla between teeth 11 and 12 and between teeth 11 and 21 to coronally advance both interproximal soft tissue areas (Figures 1-75 and 76-1). Ridge preservation was carried out with a particulate bovine bone substitute material (Bio-Oss granulate, Geistlich) (Figure 1-77). An SCTG was harvested from the posterior palate (Figure 1-78) and was adapted through a buccal and palatal split-thickness flap (Figure 1-79). The need for a CTG was based on the existing severe soft tissue deficiency around tooth 11 at the time of extraction; 5-0 polyamide sutures were placed in a single interrupted manner to stabilize the graft (Figure 1-80). A removable provisional restoration was provided to the patient for the healing phase (Figure 1-81).

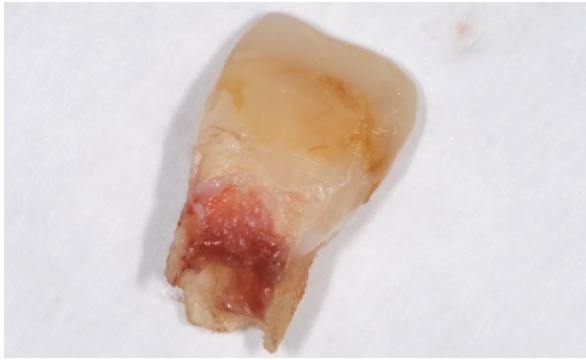


Figure 1-74 Tooth 11 extracted and with a resorbed root.

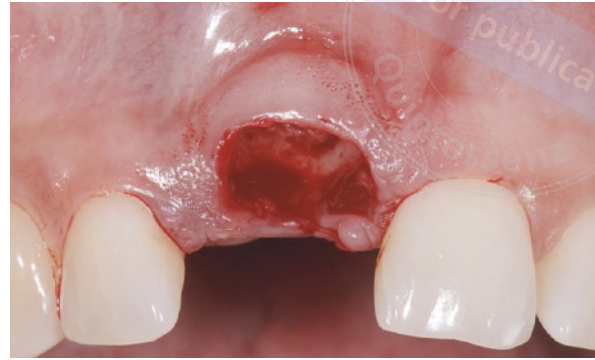


Figure 1-75 A tunnel is elevated around the soft tissue walls of tooth 11.

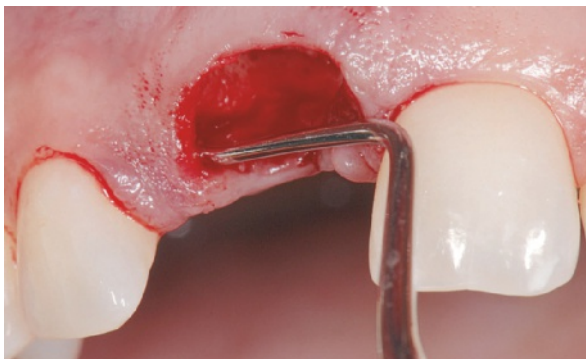

Figure 1-76 A tunnel is elevated around the soft tissue walls of tooth 11.

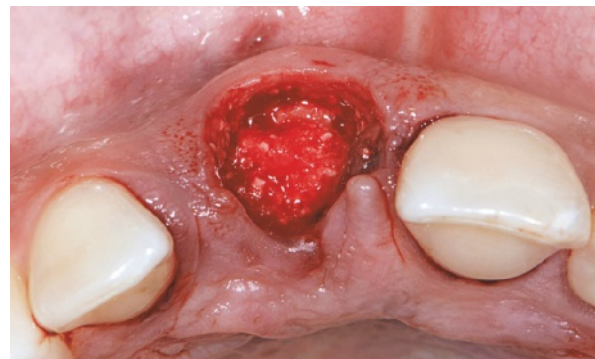

Figure 1-77 A bone substitute material in particulate form is placed in the socket.

After 4 months of healing, an implant was planned for site 11 (**Figure 1-82**). A crestal incision was performed with a distal releasing incision on tooth 12. A full-thickness flap was elevated in site 11, exposing a healed extraction socket with new bone formation and remaining bone substitute material (**Figure 1-83**). A surgical prosthetic guide was used to place the implant in an ideal position for a screw-retained prosthesis (**Figure 1-84**). The implant was placed with sufficient primary stability, and a GBR procedure was carried out for contour augmentation (**Figure 1-85**). Bone regeneration was performed with a particulate bovine bone substitute (Bio-Oss granulate) (**Figure 1-86**) covered by a resorbable collagen membrane (Bio-Gide) fixed apically with resorbable pins (LeadFIX Pins) (**Figure 1-87**). The membrane was tucked under the palatal flap, a periosteal releasing incision was performed, and the surgical site was sutured with a combination of horizontal mattress and single interrupted polyamide and expanded polytetrafluoroethylene (ePTFE) 5-0 sutures (**Figure 1-88**). Passive closure was achieved with uneventful healing by primary intention.

After 3 months (**Figure 1-89**), abutment connection was performed. The healing abutment was left in place for 4 weeks, at which time an impression was taken to manufacture a provisional restoration (**Figure 1-90**). The purpose of the provisional restoration was twofold: first to shape the emergence profile and second for anchorage for limited orthodontic treatment to close the existing diastema between tooth 12 and provisional 11 (**Figure 1-91**). After orthodontic treatment an individualized open-tray impression was taken of teeth 12 and 21 and implant 11 (**Figure 1-92**). Three all-ceramic restorations were manufactured: two feldspathic veneers for teeth 12 and 21 and one veneered zirconia screw-retained single crown for site 11 (**Figure 1-93**). The final esthetic situation after delivery of the restorations was very pleasing for the patient and met her expectations (**Figures 1-94 and 1-95**). The restorations were followed for 2 years, showing stable bone levels and a stable soft tissue situation (**Figures 1-96 and 1-97**).

copyright by
not for publication

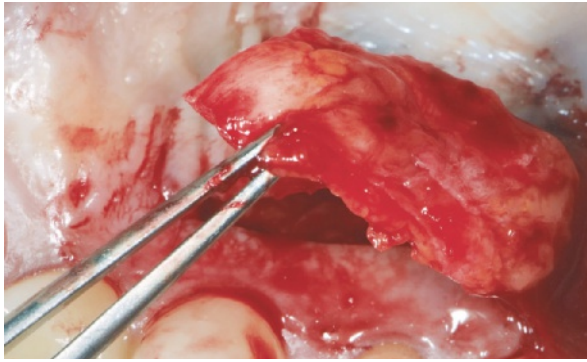


Figure 1-78 A CTG is harvested from the palate.

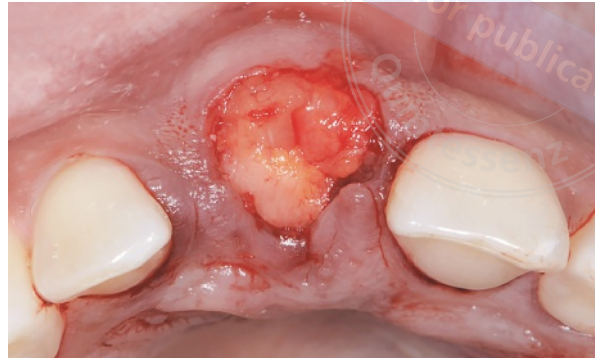


Figure 1-79 The soft tissue graft is placed within the tunnel.

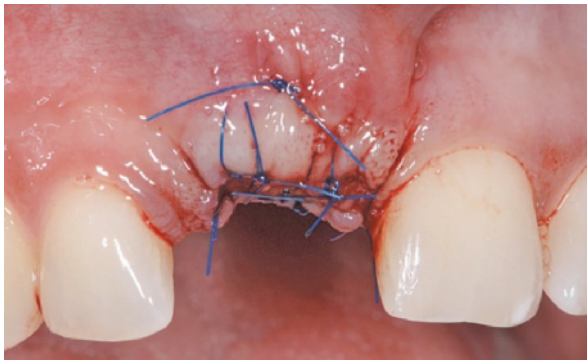


Figure 1-80 Stabilization of the graft with sutures.

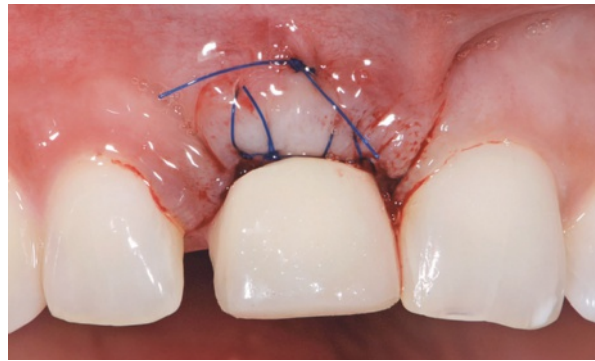


Figure 1-81 Removable provisional restoration.

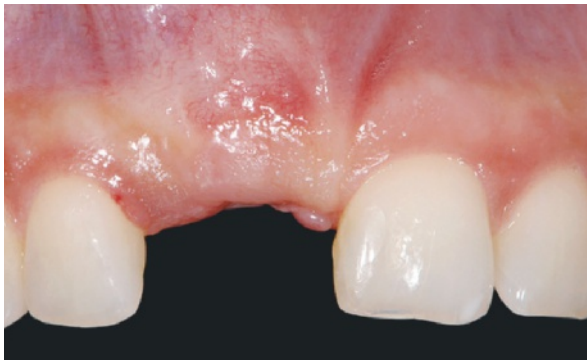

Figure 1-82 Healing after 4 months.

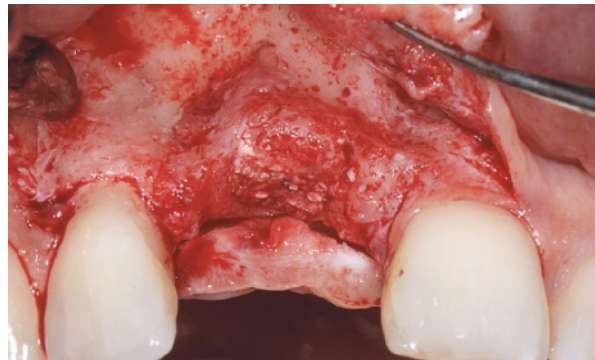

Figure 1-83 Full-thickness flap with vertical releasing incision.

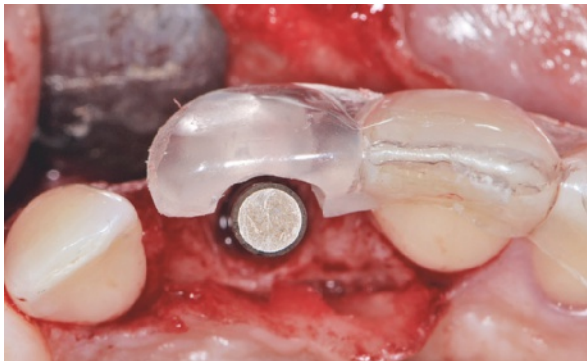


Figure 1-84 Implant osteotomy preparation with a guide.

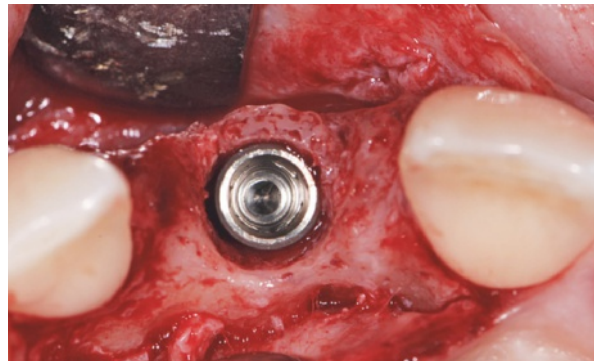


Figure 1-85 Implant placement with an existing bone defect.

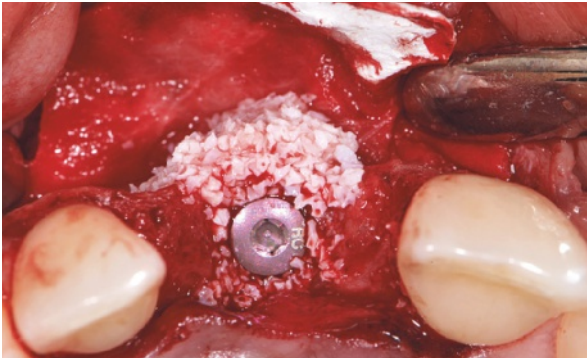
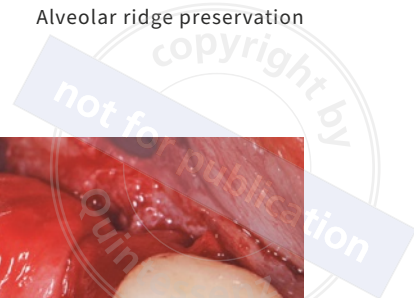


Figure 1-86 Bone graft placed around the implant with a collagen membrane.

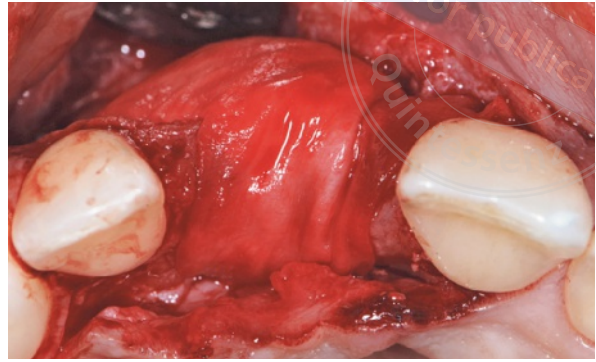


Figure 1-87 GBR for contour augmentation.

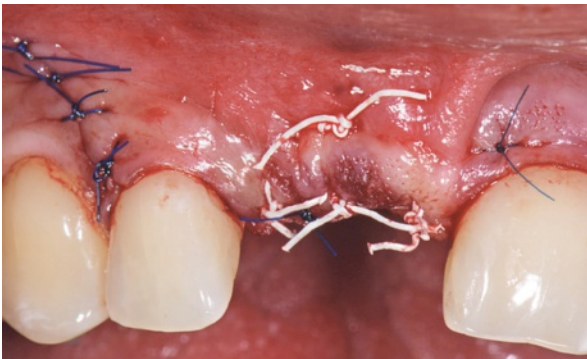


Figure 1-88 Primary closure with sutures.

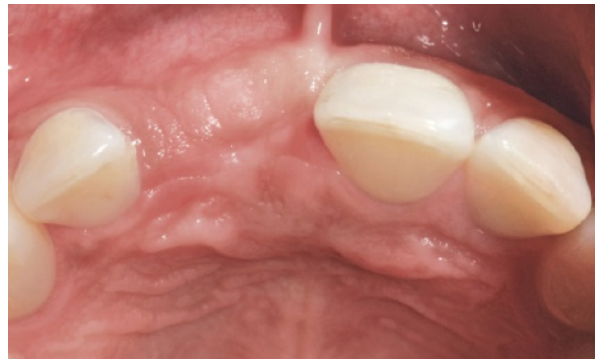

Figure 1-89 Healing after 3 months.

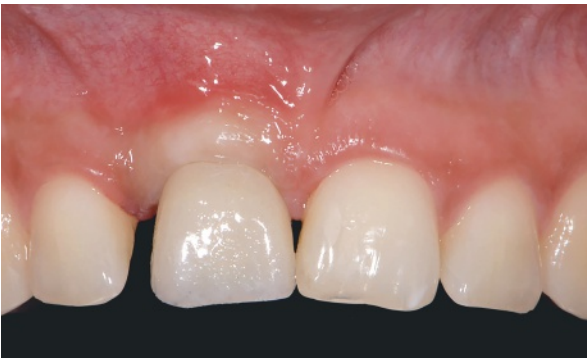

Figure 1-90 Implant-supported provisional restoration in the site of tooth 11.

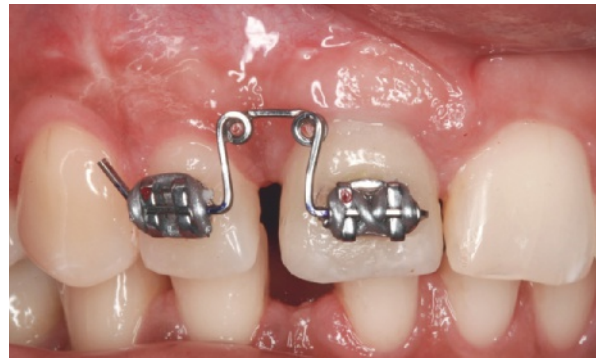

Figure 1-91 Orthodontic treatment to close the diastema between teeth 11 and 12.

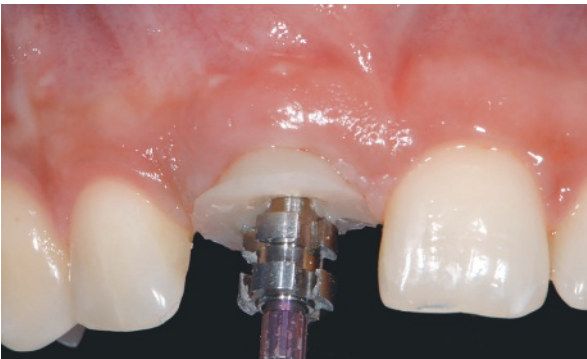


Figure 1-92 Individualized impression coping.

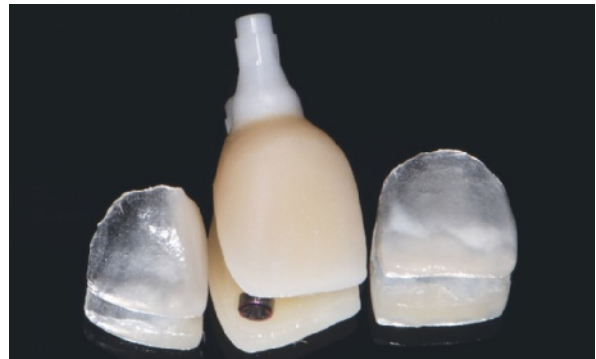
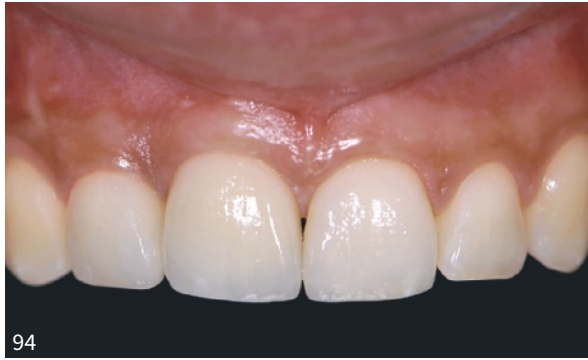
Figure 1-93 Zirconia implant restoration for site 11 and feldspathic veneers for teeth 12 and 21.



Figures 1-94 and 1-95 The restorations are esthetically pleasing.

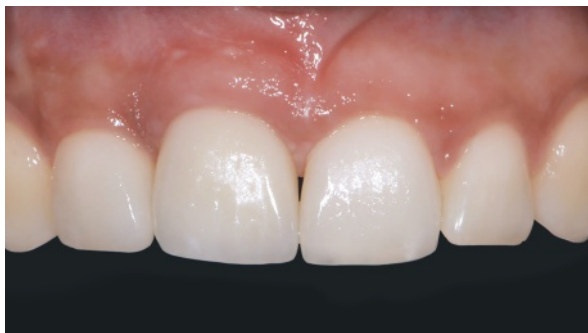
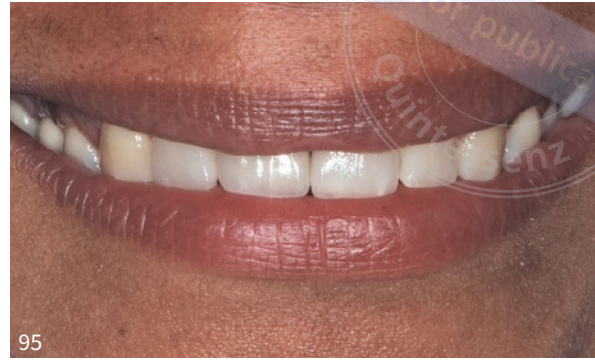
Figure 1-96 Stable soft tissues at the 2-year follow-up.

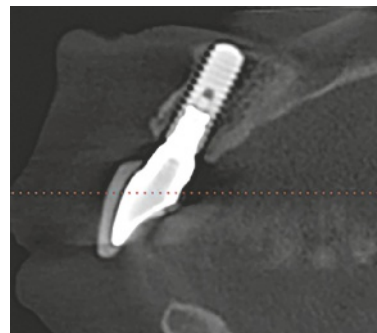

Figure 1-97 CBCT showing stable marginal bone levels and buccal bone.

Rationale for performing ridge preservation

Invasiveness

Medium to high because of the need to harvest a CTG, which increases morbidity and is associated with postoperative bleeding and pain. In addition, there is a need for split-thickness incisions on the buccal and palatal sides of the alveolus to stabilize the CTG. Depending on the choice of harvesting technique with or without vertical releasing incisions and the location of the graft in the palate, invasiveness may vary. Vertical incisions make harvesting easier to visualize but increase invasiveness and morbidity. Tuberosity grafts offer less morbidity and are less invasive. In this case, no vertical releasing incisions were performed for the harvesting and graft location was the posterior palate because of an insufficient tuberosity.

Technical complexity

Medium because of the use of a CTG from the posterior palate with a single horizontal incision. The required surgical skills may differ depending on the use of releasing vertical incisions for harvesting and the donor site. Vertical incisions require less technical skill as they increase visibility.


Clinical evidence

Limited to case reports with good clinical outcomes and increases in soft tissue thickness.²⁴

Soft tissue volume

The CTG facilitates an increase in the quality and quantity of soft tissue of the socket, enabling the proper management of a preexisting gingival deficiency with a satisfying esthetic result.

Hard and soft tissue augmentation using primary bone augmentation and an SCTG



Patient

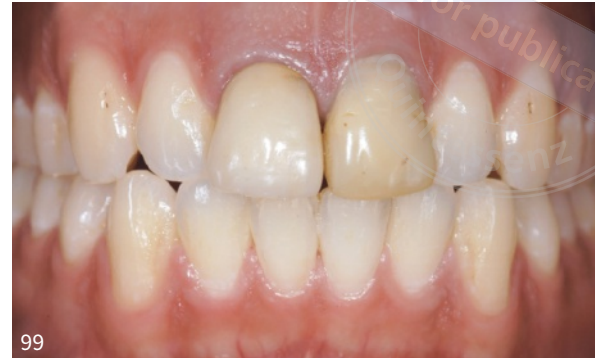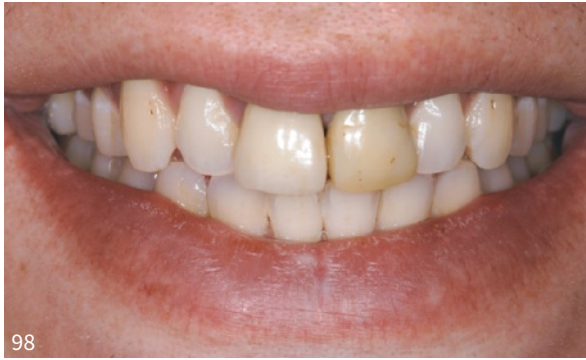The patient was a healthy 28-year-old man.

Chief complaint and esthetic expectations

The patient presented with two failing maxillary central incisors with sensitivity after an accident in the military 15 years ago (Figures 1-98 to 1-100). He wanted to replace the two failing central incisors with fixed restorations. Given his low lip line, the esthetic expectations were moderate.

Clinical and radiographic findings

Evaluation revealed discolored crowns and secondary caries on teeth 11 and 21 (Figure 1-101), and apical radiolucency on teeth 11 and 21 (Figure 1-102).



Figures 1-98 to 1-100 Initial clinical situation with discolored crowns.

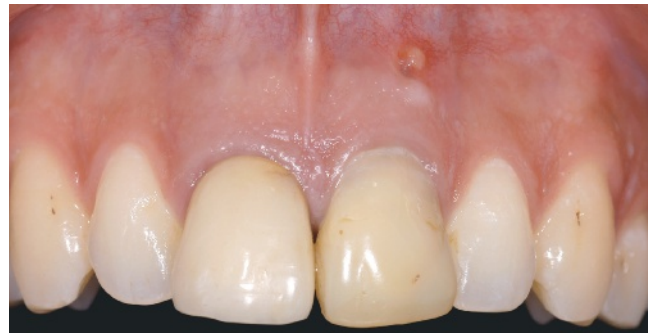
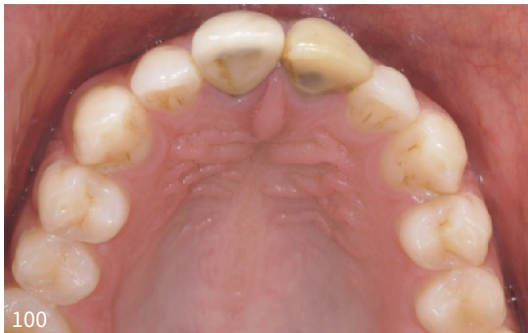
Figure 1-101 Diastema between crowns 11 and 21.

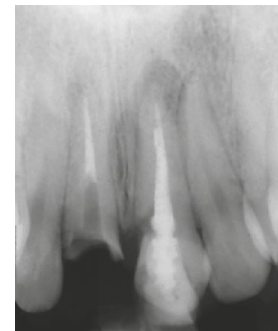


Figure 1-102 The radiograph shows periapical lesions around teeth 11 and 21.

Diagnosis

Caries and periapical pathology on teeth 11 and 21, root resorption on tooth 21.

Treatment plan

Extraction of both central incisors, early implant placement in the sites of teeth 11 and 21 with simultaneous bone augmentation, and delayed placement of two implant-supported all-ceramic restorations.

Expected time for implant placement

The patient wanted to avoid prolonged healing times and receive the fixed restorations as soon as possible.

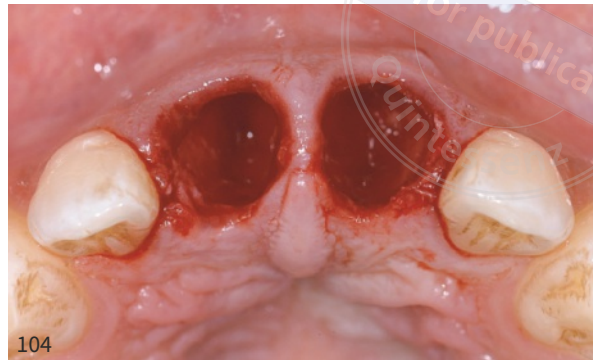
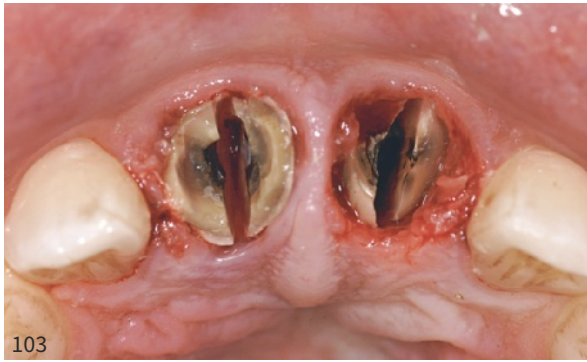
Ridge preservation

Ridge preservation was not carried out because of the decision to perform early implant placement with simultaneous bone augmentation 6 weeks after tooth extraction.

Healing time

Six weeks.

The existing restorations on teeth 11 and 21 were removed. The teeth were sectioned buccopalatally to be luxated and extracted in two pieces (Figure 1-103). The sockets were curetted and irrigated to eliminate the chronic granulation tissue (Figure 1-104). An immediate removable provisional restoration replacing both central incisors was provided to the patient (Figure 1-105). After 2 weeks (Figure 1-106), an impression was taken to manufacture a fixed resin-bonded provisional partial denture with double metal wings to the lateral incisors and canines (Figures 1-107 and 1-108). After 6 weeks of healing, early implant placement with ridge augmentation was indicated (Figures 1-109 and 1-110).



Figures 1-103 and 104 Extraction of teeth 11 and 21 by sectioning the roots buccopalatally.

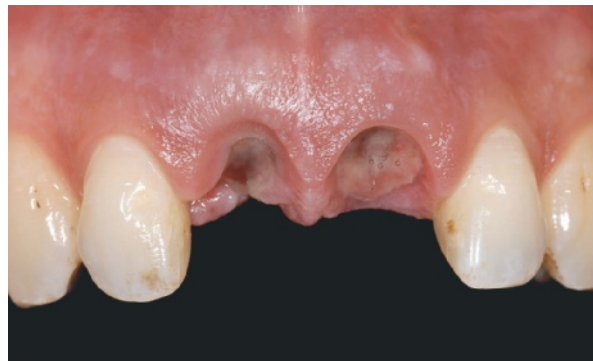
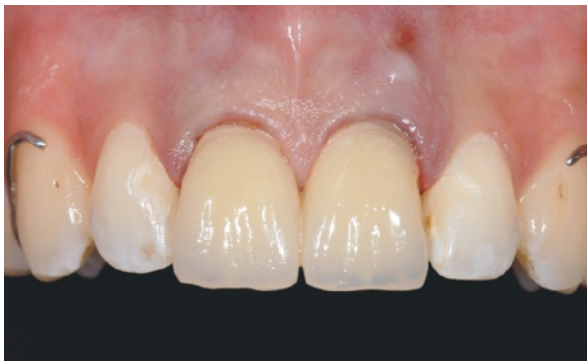
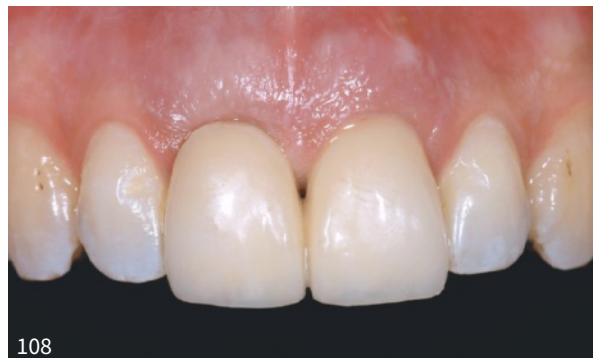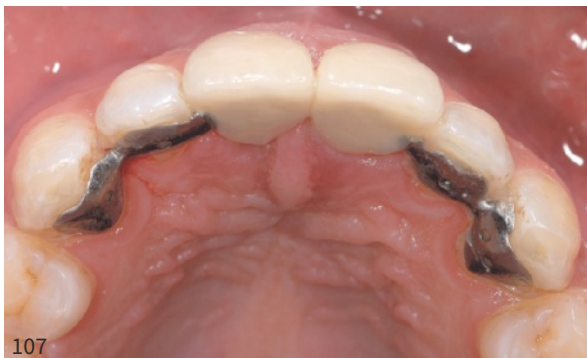Figure 1-105 Placement of a removable provisional with ovate pontics.

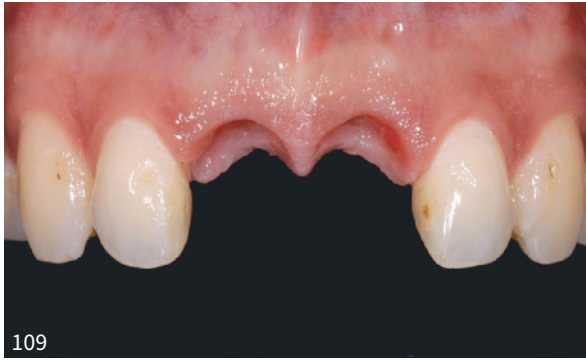Figure 1-106 Soft tissue adapted to the ovate pontics.



Figures 1-107 and 1-108 Provisional resin-bonded fixed partial denture.

A crestal incision was performed toward the palatal side of sites 11 and 21, leaving the papilla intact and inside the flap. A full-thickness flap was elevated with one distal releasing incision on the lateral tooth (Figure 1-111). A surgical guide was manufactured based on the wax-up of both central incisors. The guide was used to position the implants in prosthetically ideal locations (Figure 1-112). Implants were placed with primary stability for placement of a screw-retained prosthesis. The hard tissue deficit was apparent, with a 2-mm dehiscence around implant 11 and an 11-mm dehiscence around implant 21 (Figures 1-113

and 1-114). GBR was performed with two stable block bovine bone substitutes (Bio-Oss Collagen) (Figures 1-115 to 1-117) covered with a resorbable collagen membrane (Bio-Gide) fixed apically with resorbable pins (LeadFIX Pins) on the buccal side (Figure 1-118). The membrane was adapted on the palatal side. To achieve tension-free flap closure, a periosteal releasing incision was performed deep in the vestibule. The flap was sutured with 5-0 ePTFE sutures in the form of two horizontal mattress sutures as well as single interrupted sutures. Additional 5-0 polyamide suturing was carried out to approximate the wound margins (Figure



Figures 1-109 and 1-110 Healing after 6 weeks.

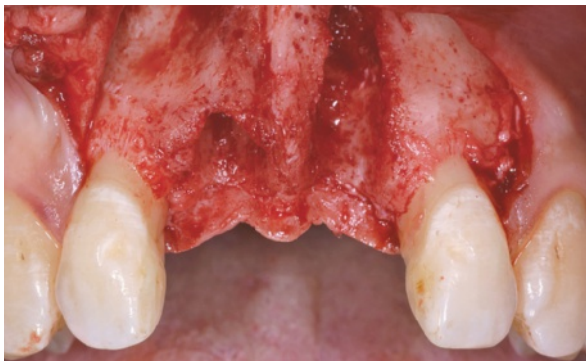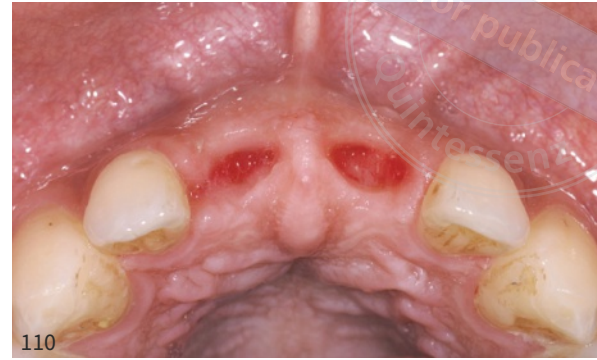


Figure 1-111 Early implant placement after 6 weeks.

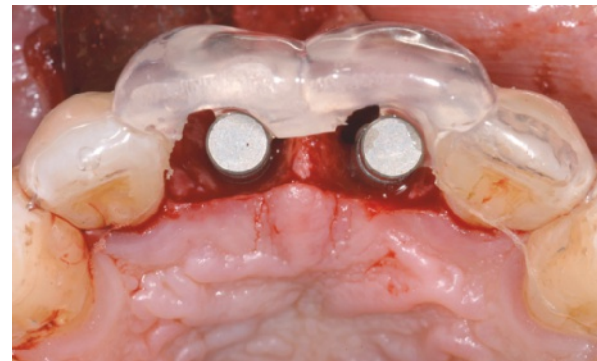
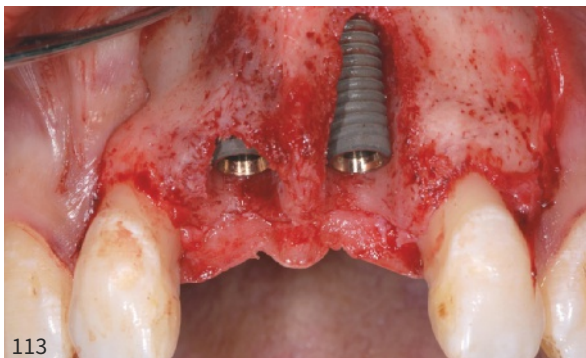
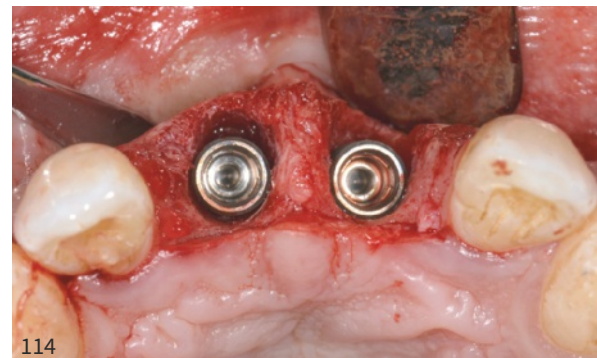

Figure 1-112 Implant osteotomy using a guide.



Figures 1-113 and 1-114 Implants placed with existing bone defects.



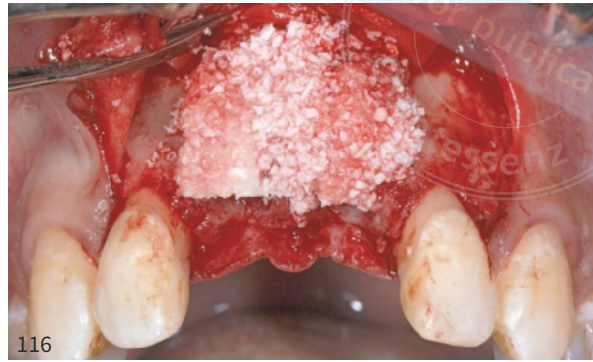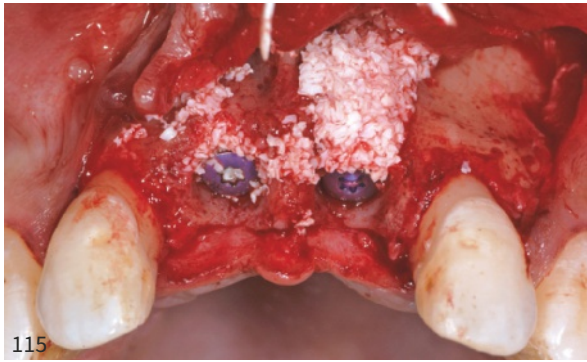1-119), and primary wound closure was achieved (Figure 1-120).

After 3 months of healing (Figures 1-121 and 1-122), soft tissue augmentation was performed. A full-thickness flap was elevated at the crestal level from teeth 12 to 22 without any releasing incisions. After full-thickness elevation, a split-thickness flap was carried out apically on the buccal side to allow the graft to be sutured to the buccal periosteum and to provide tension-free flap closure. A CTG was harvested from the posterior palate (Figure 1-123) and

positioned near the implants (Figure 1-124). Polyamide sutures were used to stabilize the graft on the palatal side, and a combination of polyamide and ePTFE sutures were used to close the flap with horizontal mattress and single interrupted sutures (Figures 1-125 and 1-126).

Abutment connection was performed 2 months after soft tissue augmentation with two rolled flaps (Figure 1-127). The overlying soft tissue above the implants was deepithelialized with a round bur, and two U-flaps were performed and rolled toward the buccal side to gain buccal volume.

copyright by
not for publication
essenz



Figures 1-115 to 1-117 GBR performed with a collagen membrane and bone substitute material.

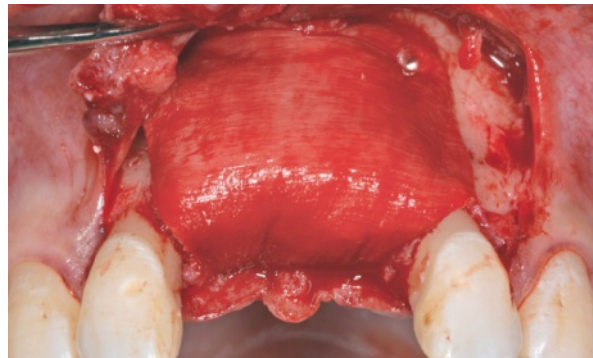
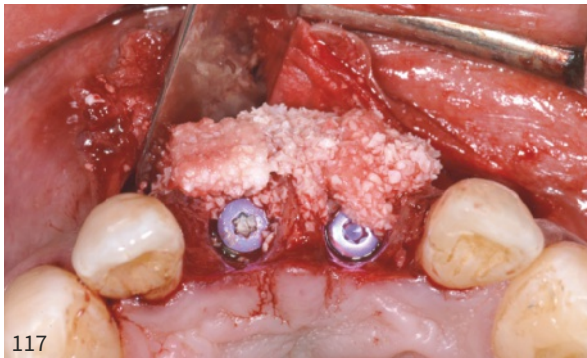
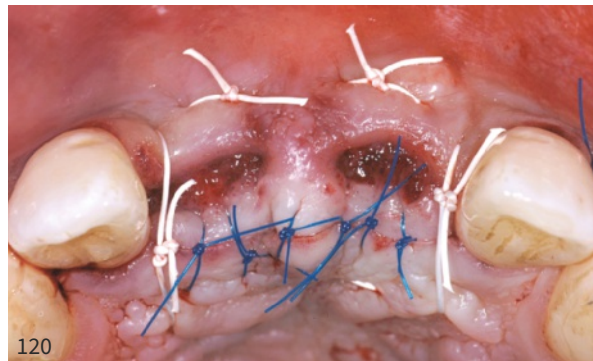
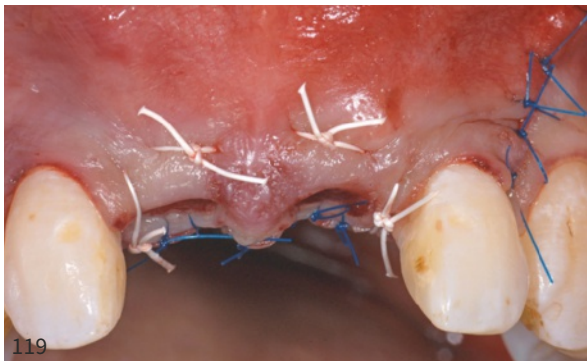
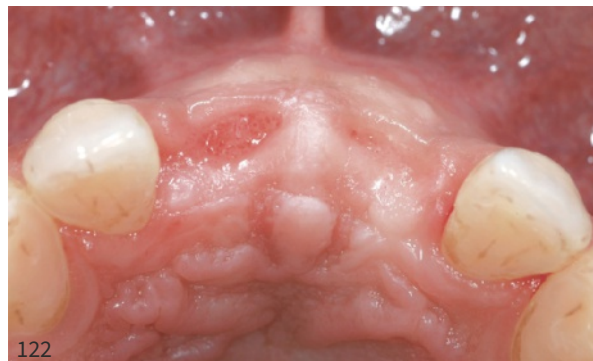
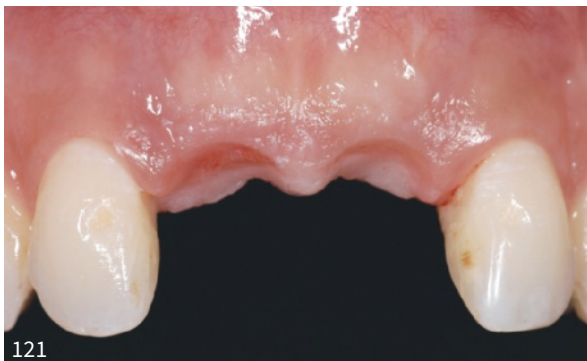
Figure 1-118 Fixation of the collagen membrane with apical pins.



Figures 1-119 and 1-120 Primary closure with sutures.



Figures 1-121 and 1-122 Healing after 3 months.

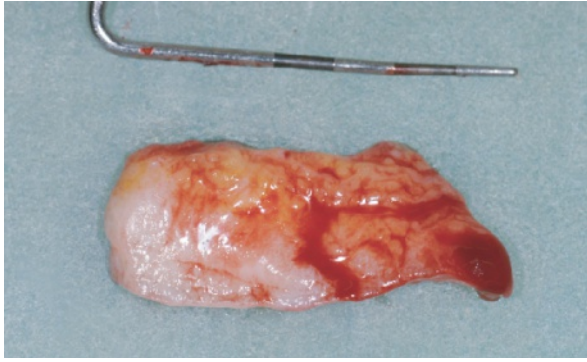
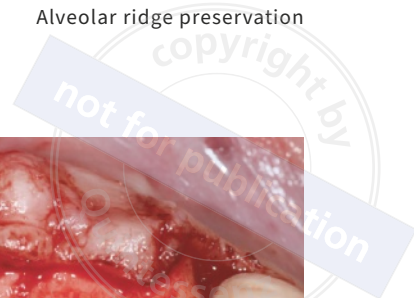


Figure 1-123 CTG harvested from the palate.

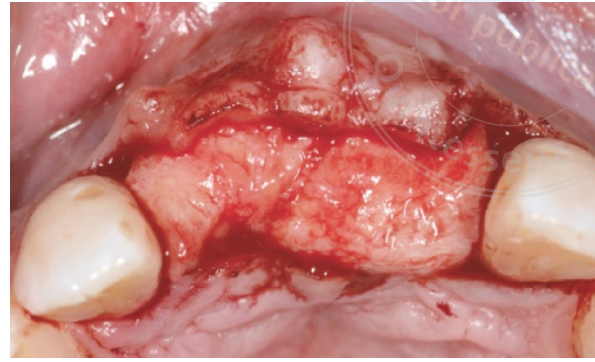
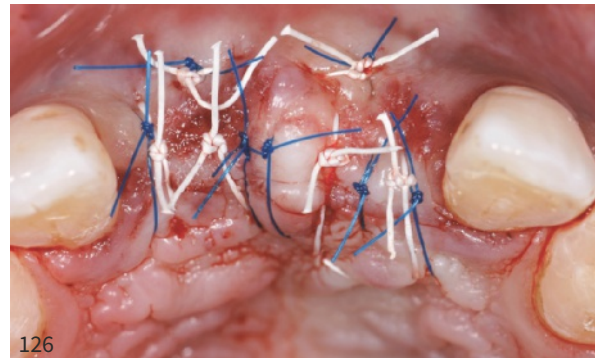
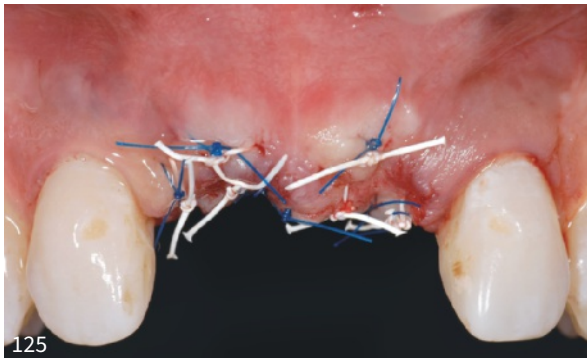

Figure 1-124 Graft placed occlusal and buccal to the implants.



Figures 1-125 and 1-126 Stabilization of the graft with sutures for primary closure.

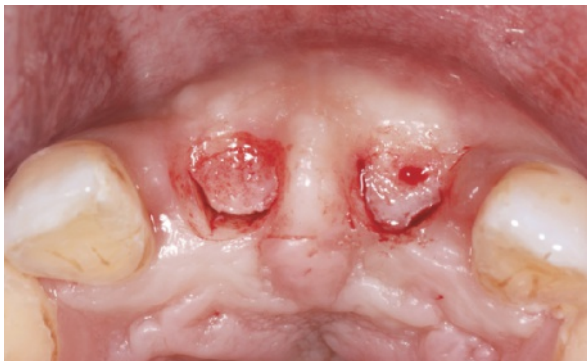

Figure 1-127 Minimal flaps for stage-two surgery.

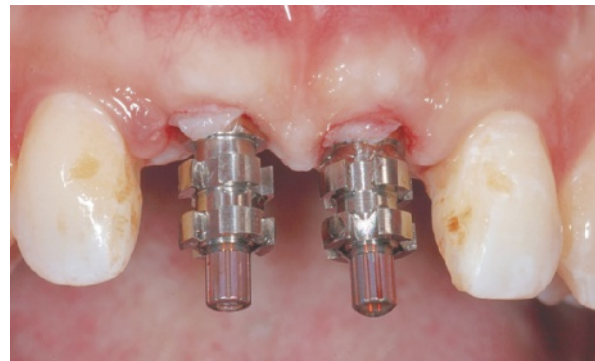

Figure 1-128 Conventional impression with impression posts.

Two impression posts were placed, and a polyether impression of both implants was taken (Figure 1-128). Two healing abutments were screwed to the implants for transmucosal healing (Figure 1-129).

Two provisional implant restorations were delivered to the patient to shape the emergence profile (Figures 1-130 to 1-132). These provisional restorations were initially under-

contoured in the transmucosal side and were successively built up submucosally with flowable composite to develop the shape of the emergence profile (Figures 1-133 and 1-134).

An impression was taken of both implants with open-tray impression posts filled with flowable composite capturing the shape of the emergence profile (Figures 1-135 to 1-138). Two CAD/CAM zirconia abutments were manufactured and

copyright by Quintessenz
not for publication

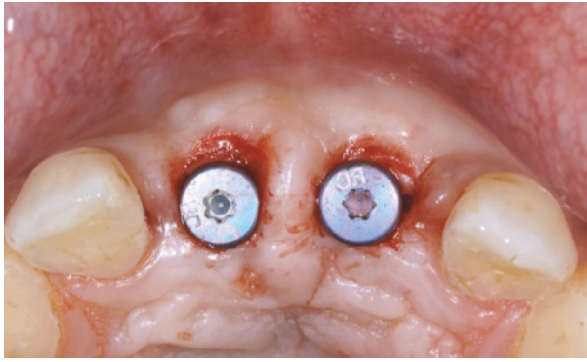
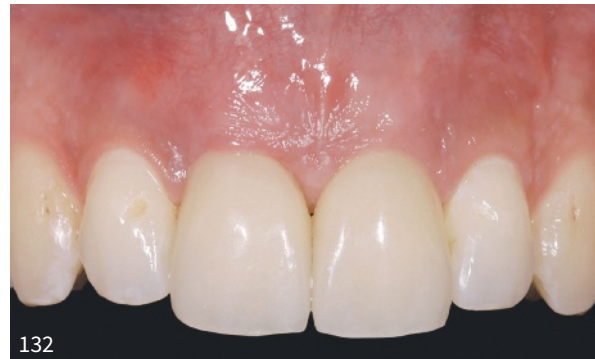
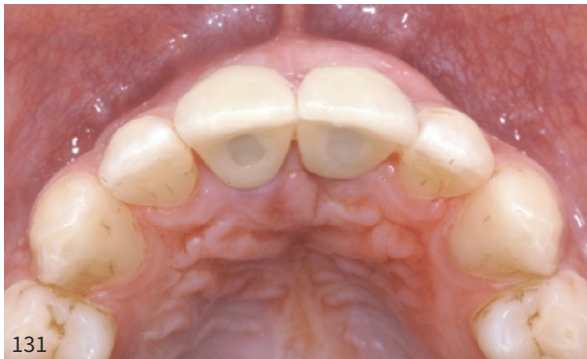
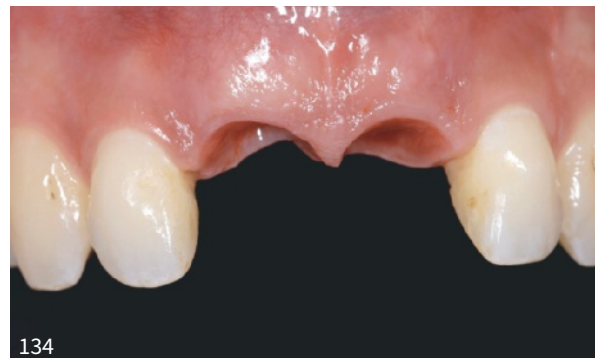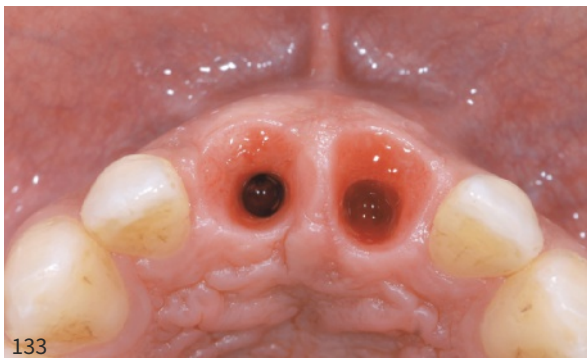
Figure 1-129 Healing abutments.



Figure 1-130 Two implant-supported provisional restorations.



Figures 1-131 and 1-132 Delivery of the provisional restorations.



Figures 1-133 and 1-134 Emergence profile after provisional phase.

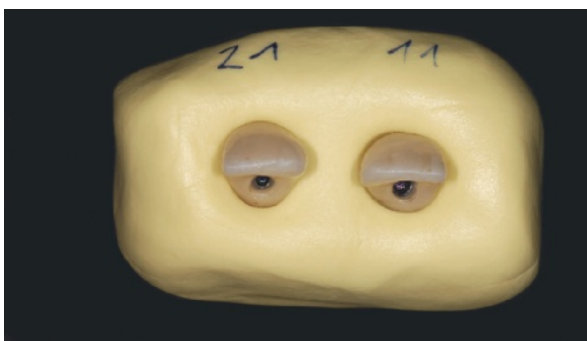
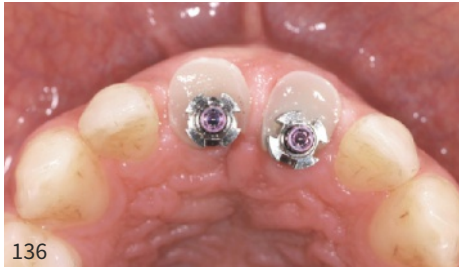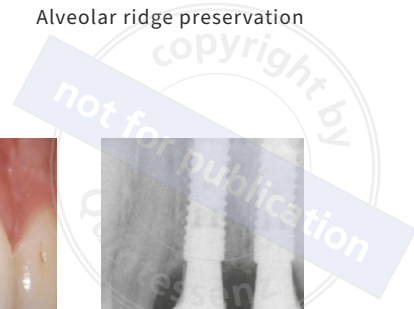

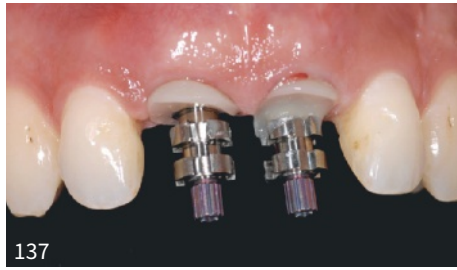
Figure 1-135 Individualized impression silicone with implant provisionals.

tried on the implants (Figures 1-139 and 1-140). The fit was adequate. Then the bisque try-in with the veneering ceramic on the zirconia abutments was performed. The shape and color were verified (Figure 1-141). The emergence profile was ideal in both the horizontal and vertical dimensions (Figure 1-142). The screw-retained all-ceramic restorations were finalized and inserted at 35 Ncm (Figure 1-143). The



136



137

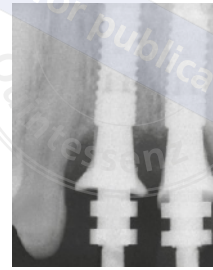
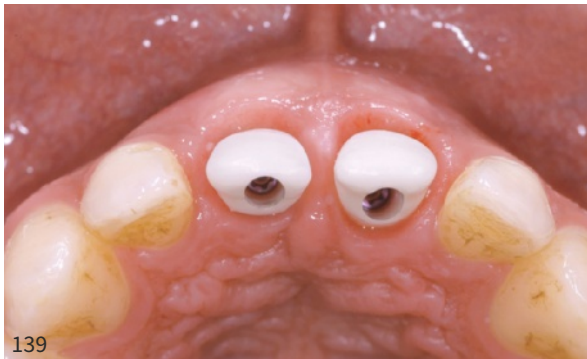
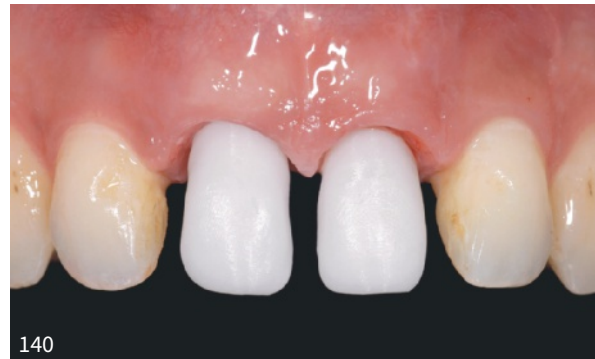
Figure 1-138 Correct seating of the impression copings.



139



140

Figures 1-139 and 1-140 Zirconia CAD/CAM implant abutments.

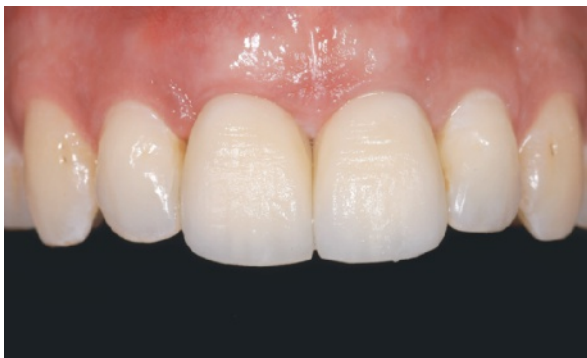

Figure 1-141 Bisque try-in of the implant restorations.

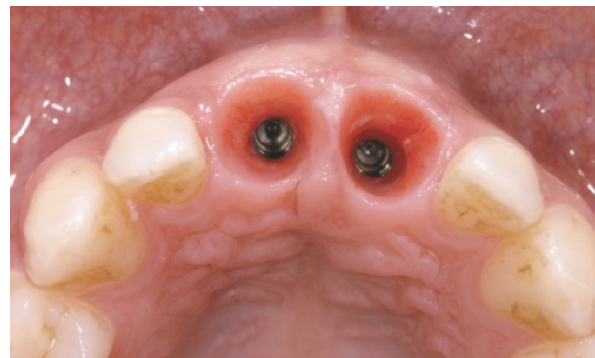


Figure 1-142 Emergence profile during restoration delivery.

patient was extremely satisfied with the implant restorations (Figures 1-144 and 1-145).

The follow-up at 2 years showed stable volume clinically (Figures 1-146 and 1-147) and healthy marginal levels on the radiograph (Figure 1-148), without any mechanical or biologic complications.

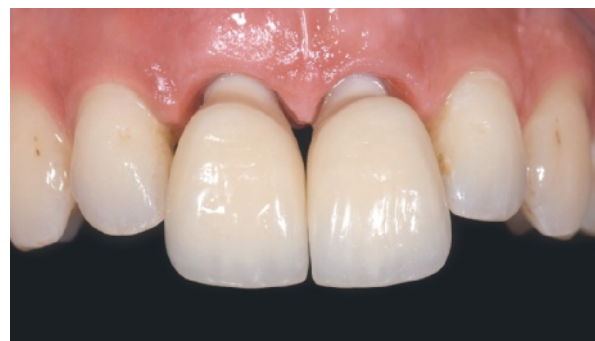
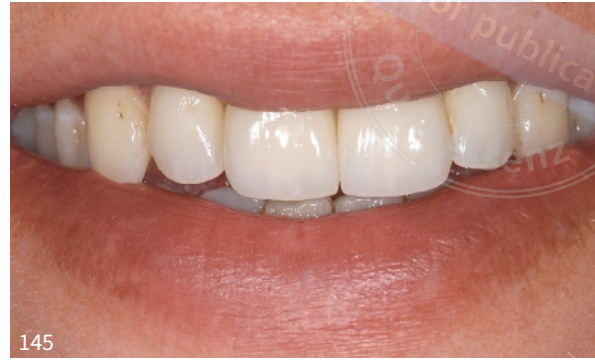
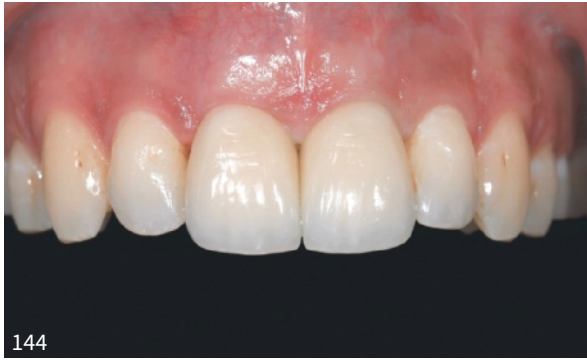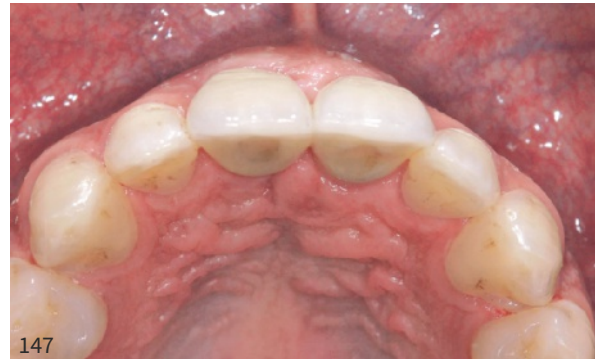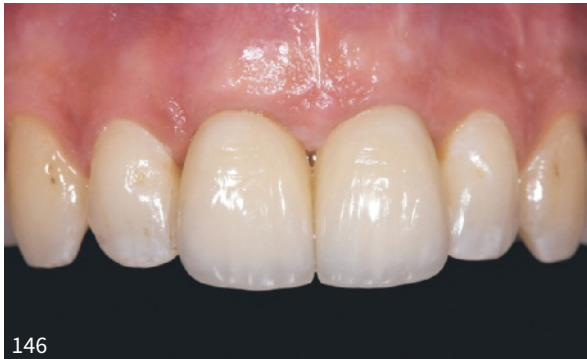Figure 1-143 Placement of screw-retained implant restorations.



Figures 1-144 and 1-145 Veneered zirconia implant restorations.



Figures 1-146 and 1-147 Clinical follow-up at 2 years.

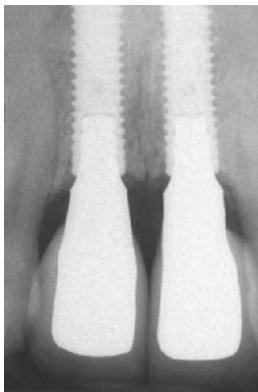


Figure 1-148 Radiograph showing stable marginal bone levels.

Rationale for early implant placement with Rationale for performing early implant placement with GBR

Invasiveness

Because of the long-lasting chronic infection and the fact that both central incisors had to be extracted, bone augmentation was indicated in this case. This is the reason why ridge preservation was not performed and ridge augmentation was done instead at the time of early implant place-

ment. Invasiveness is high because of the need to raise an extensive flap with a deep vertical incision in addition to the bone graft needed. Swelling and the risk of biologic complications is higher for this type of procedure.

Technical complexity

The need to raise a large mucoperiosteal flap and the handling of the bone biomaterial, membrane, and pins, in addition to the periosteal releasing incision for flap closure, make this procedure more technique sensitive than

ridge preservation alone. The required surgical skills and experience are must be developed through training and expertise.

Clinical evidence

A few studies have documented the success of this combination of early implant placement and GBR.^{25,26} The rationale behind it is to prevent the 10% to 20% volume collapse that still occurs at a horizontal level after ridge preservation is performed. By performing grafting at the time of implant placement, resorption can be counteracted more predictably and large bone deficiencies can be addressed.

Soft tissue volume

The combination of hard and soft tissue augmentation in a patient with two failing central incisors provided enough tissue volume to place the implants and develop a healthy and harmonious emergence profile on adjacent implants for the central incisors. When a lot of tissue volume is required, implant placement with simultaneous bone augmentation is a feasible treatment option with predictable results if the surgeon has enough clinical experience and the patient accepts the higher risk of morbidity and complications.

Conclusions

Ridge preservation reduces the alveolar alterations that occur after tooth extraction. It results in less bone resorption in the horizontal and vertical dimensions of the alveolar process, and it reduces the need for additional bone augmentation during implant placement.

The decision-making process for alveolar ridge preservation in the esthetic zone should always start before tooth extraction. When an extracted tooth can be replaced with an implant within 2 months, ridge preservation procedures are not indicated.

In cases where implant placement is not recommended within 2 months of tooth extraction because of alveolar volumetric deficiencies or patient-related factors, ridge preservation procedures should be carried out.

The decision of which technique to use for ridge preservation should be based on four factors: invasiveness, technical complexity, clinical evidence, and soft tissue volume.

Choosing the right therapeutic procedure for every patient is key to achieving predictable esthetic, functional, and biologic results.

Acknowledgments

We thank Leonardo Mancini for the illustrations of the different ridge preservation techniques and the decisive factors.

References

- Sculean A, Stavropoulos A, Bosshardt DD. Self-regenerative capacity of intra-oral bone defects. *J Clin Periodontol* 2019;46(suppl 21):705–81S.
- Van der Weijden F, Dell'Acqua F, Slot DE. Alveolar bone dimensional changes of post-extraction sockets in humans: a systematic review. *J Clin Periodontol* 2009;36(12):1048–1058.
- Jung RE, Ioannidis A, Hämmerle CHF, Thoma DS. Alveolar ridge preservation in the esthetic zone. *Periodontology* 2000 2018;77(1):165–175.
- Januário AL, Duarte WR, Barriviera M, Mesti JC, Araújo MG, Lindhe J. Dimension of the facial bone wall in the anterior maxilla: a cone-beam computed tomography study. *Clin Oral Implants Res* 2011;22(10):1168–1171.
- Avila-Ortiz G, Gubler M, Romero-Bustillos M, Nicholas CL, Zimmerman MB, Barwacz CA. Efficacy of alveolar ridge preservation: a randomized controlled trial. *J Dent Res* 2020;99(4):402–409.
- Thoma DS, Naenni N, Benic GI, Muñoz F, Hämmerle CHF, Jung RE. Effect of ridge preservation for early implant placement—Is there a need to remove the biomaterial? *J Clin Periodontol* 2017;44(5):556–565.
- Jung RE, Philipp A, Annen BM, et al. Radiographic evaluation of different techniques for ridge preservation after tooth extraction: a randomized controlled clinical trial. *J Clin Periodontol* 2013;40(1):90–98.
- Lindhe J, Cecchinato D, Donati M, Tomasi C, Liljenberg B. Ridge preservation with the use of deproteinized bovine bone mineral. *Clin Oral Implants Res* 2014;25(7):786–790.
- Avila-Ortiz G, Chambrone L, Vignoletti F. Effect of alveolar ridge preservation interventions following tooth extraction: a systematic review and meta-analysis. *J Clin Periodontol* 2019;46(suppl 21):195S–223S.
- Atieh MA, Alsabeeha NH, Payne AG, Ali S, Faggion CM Jr, Esposito M. Interventions for replacing missing teeth: alveolar ridge preservation techniques for dental implant site development. *Cochrane Database Syst Rev* 2021;(4):CD010176.
- Araújo MG, Lindhe J. Dimensional ridge alterations following tooth extraction. An experimental study in the dog. *J Clin Periodontol* 2005;32(2):212–218.
- Mardas N, Trullenque-Eriksson A, MacBeth N, Petrie A, Donos N. Does ridge preservation following tooth extraction improve implant treatment outcomes: a systematic review: Group 4: Therapeutic concepts and methods. *Clin Oral Implants Res* 2015;26:180–201.
- Jonker BP, Gil A, Naenni N, Jung RE, Wolvius EB, Pijpe J. Soft tissue contour and radiographic evaluation of ridge preservation in early implant placement: a randomized controlled clinical trial. *Clin Oral Implants Res* 2021;32(1):123–133.
- Jensen SS, Terheyden H. Bone augmentation procedures in localized defects in the alveolar ridge: clinical results with different bone grafts and bone-substitute materials. *Int J Oral Maxillofac Implants* 2009;24(suppl):218S–236S.
- Noumbissi SS, Lozada JL, Boyne PJ, et al. Clinical, histologic, and histomorphometric evaluation of mineralized solvent-dehydrated bone allograft (Puros) in human maxillary sinus grafts. *J Oral Implantol* 2005;31(4):171–179.
- Thoma DS, Buranawat B, Hämmerle CH, Held U, Jung RE. Efficacy of soft tissue augmentation around dental implants and in partially edentulous areas: a systematic review. *J Clin Periodontol* 2014;41(suppl 15):77S–91S.
- Thoma DS, Sancho-Puchades M, Ettlin DA, Hämmerle CHF, Jung RE. Impact of a collagen matrix on early healing, aesthetics and patient morbidity in oral mucosal wounds—A randomized study in humans. *J Clin Periodontol* 2012;39(2):157–165.
- Thoma DS, Zeltner M, Hilbe M, Hämmerle CHF, Hüsler J, Jung RE. Randomized controlled clinical study evaluating effectiveness and safety of a volume-stable collagen matrix compared to autogenous connective tissue grafts for soft tissue augmentation at implant sites. *J Clin Periodontol* 2016;43(10):874–885.
- Barone A, Aldini NN, Fini M, Giardino R, Calvo Guirado JL, Covani U. Xenograft versus extraction alone for ridge preservation after tooth removal: a clinical and histomorphometric study. *J Periodontol* 2008;79(8):1370–1377.
- Thoma DS, Bienz SP, Lim H-C, Lee WZ, Hämmerle CHF, Jung RE. Explorative randomized controlled study comparing soft tissue thickness, contour changes, and soft tissue handling of two ridge preservation techniques and spontaneous healing two months after tooth extraction. *Clin Oral Implants Res* 2020;31(6):565–574.

20. Chen ST, Darby I. Alveolar ridge preservation and early implant placement at maxillary central incisor sites: a prospective case series study. *Clin Oral Implants Res* 2020;31(9):803–813.
21. Jonker BP, Strauss FJ, Naenni N, Jung RE, Wolvius EB, Pijpe J. Early implant placement with or without alveolar ridge preservation in single tooth gaps renders similar esthetic, clinical and patient-reported outcome measures: one-year results of a randomized clinical trial. *Clin Oral Implants Res* 2021;32(9):1041–1051.
22. Peñarrocha M, García-Mira B, Martínez O. Localized vertical maxillary ridge preservation using bone cores and a rotated palatal flap. *Int J Oral Maxillofac Implants*. 2005;20(1):131–14.
23. Stimmelmayer M, Allen EP, Reichert TE, Iglhaut G. Use of a combination epithelized-subepithelial connective tissue graft for closure and soft tissue augmentation of an extraction site following ridge preservation or implant placement: description of a technique. *Int J Periodontics Restorative Dent* 2010;30(4):375–381.
24. Buser D, Chappuis V, Kuchler U, et al. 2013. Long-term stability of early implant placement with contour augmentation. *J Dent Res* 92(suppl 12): 176S–182S.
25. Chappuis V, Engel O, Shahim K, Reyes M, Katsaros C, Buser D. Soft tissue alterations in esthetic postextraction sites: a 3-dimensional analysis. *J Dent Res* 2015;94(suppl 9):187S–193S.