

Hüsamettin Günay, Ingmar Staufenbiel, Werner Geurtsen, Knut Adam

The granulation tissue preservation technique in regenerative therapy of peri-implantitis – a treatment concept with case reports

Introduction:

In recent years, the indication for the placement of dental implants has expanded consistently. Therefore, more and more patients are treated with implant supported restorations resulting in increasing implant associated complications. Inflammatory peri-implant diseases represent the most frequent complications. For peri-implantitis, especially in advanced cases, a surgical approach is still the gold standard. However, to date no preferential surgical protocol has been established. Previous surgical techniques recommended the removal of the intralesional granulation tissue followed by grafting of the bony defect.

Material und Methods:

The present article demonstrates the systematic treatment protocol for inflammatory peri-implant diseases performed in our department at Hannover Medical School and a new surgical technique. The aim of this technique is to preserve as much intralesional granulation tissue as possible. The efficiency of the granulation tissue preservation technique has already been proven for regenerative periodontal therapy. Three case reports illustrate the practical application and the effectiveness of this new surgical technique in the regenerative treatment of peri-implantitis.

Results and Conclusion:

The present case series demonstrates a significant gain of clinical attachment level and a remarkable bone fill, proving the success of the new surgical therapy protocol. In addition to the preservation of multipotent mesenchymal stem cells and blood vessels, the enhanced soft tissue support with an endogenous matrix resulted in less postoperative mucosal recessions. This is the main advantage of the new surgical technique.

Keywords:

regenerative treatment of peri-implantitis; surgical protocol; granulation tissue preservation technique; decontamination protocol

Department of Conservative Dentistry, Periodontology and Preventive Dentistry, Hannover Medical School: Prof. Dr. Hüsamettin Günay, PD Dr. Ingmar Staufenbiel, Prof. Dr. Werner Geurtsen, Dr. Knut Adam

Corresponding authors: Hüsamettin Günay, Ingmar Staufenbiel; these authors are equal first authors: Hüsamettin Günay, Ingmar Staufenbiel

Translation: Graham Wroe

Citation style: Günay H, Staufenbiel I, Geurtsen W, Adam K: The granulation tissue preservation technique in regenerative therapy of peri-implantitis – a treatment concept with case reports. Dtsch Zahnärztl Z Int 2019; 1: 4-15

Peer-reviewed article: submitted: 14.08.2018, revised version accepted: 05.10.2018

DOI.org/10.3238/dzz-int.2019.004-0015

Introduction

Progress in the use of dental implants has extended the indication of their clinical application. In many cases they are now replacing traditional prosthetics. There is no scientific corroboration, but, estimates for Germany, based on dental trade sales in recent years, have indicated that approximately one million implants are being inserted annually. Previous meta-analyses demonstrate good survival rates for dental implants after 10 years of functional loading. Depending on the design of the prosthetic suprastructure these were reported to be between 93.1 % [20] and 95.2 % [15]. However, on the other hand dental implantology has high complication rates. Complications vary and include primary biological (e.g. no osseointegration immediately after implant insertion), aesthetic, technical (e.g. screw fractures, abutments becoming dislodged or loose) and secondary biological complications (e.g. peri-implant inflammation). These complications vary in frequency depending on the design of the prosthetic suprastructures [1]. Overall, the most common complication is peri-implant inflammation. This can be categorized into either peri-implant mucositis or peri-implantitis. Peri-implant mucositis is restricted just to the soft tissues around the implant whereas peri-implantitis is more extensive resulting in a progressive loss of peri-implant bone [11, 30]. The incidence of peri-implant inflammation in the scientific literature varies considerably due to differing definitions of the disease [26]. In a current meta-analysis, the patient based incidence of peri-implant mucositis was reported to be 43 % and that of peri-implantitis 22 % [8].

Preventive strategies have been widely described and comprise pre- and postimplantation measures. Pre-implantation measures include adequate planning of both the number and position of the proposed implants, a hygienic design of the suprastructure, rehabilitation of the remaining dentition (dental and periodontal), an evaluation and elimination of risk factors (e.g. smoking)

as well as securing a basic compliance (individual oral hygiene instruction to ensure self-reliant, and effective home maintenance) [32]. Postimplantation there should be risk-based follow-up intervals for prevention and maintenance necessitating full clinical examinations. These would encompass the recording of probing depths and inflammatory indices together with a radiographic diagnosis of any noticeable abnormalities to enable prompt therapeutic intervention [14]. It is crucial that during follow-ups, clinical and radiological findings are referred to a baseline to enable a meaningful comparison. With regard to the latest classification of peri-implant disease, the comparison of current clinical and radiological findings with their initial status, is the paramount diagnostic indicator of peri-implantitis. Therefore, peri-implantitis is present, when clinical signs of inflammation are evident and there is progressive bone loss after the initial healing phase. These changes are associated with bleeding on probing and increased probing depths when compared to the initial measurements [24]. This new definition of peri-implantitis results in the recommendation that after every prosthetic phase of treatment a basic examination should be undertaken. This should include not only radiographic controls but also the measurement of peri-implant probing depths.

Due to the fact that peri-implantitis is a biofilm-associated disease [3], the decontamination of the implant surface is the basis of any therapeutic regimen. Peri-implant mucositis can be successfully treated by professional removal of the biofilm using hand instruments, sonic-driven brushes, or an air abrasive device [14]. Antiseptics can also be utilized but the use of local or systemic antibiotics have not been shown to provide additional benefits [14]. An important prerequisite for therapeutic success is the establishment of an effective and self-reliant home care regime for adequate oral hygiene [25]. Successful therapy in many cases does not mean that there is no residual bleeding around the treated im-

plant, but rather that no bone loss results [29]. When there has been bone loss resulting in the exposure of implant threads due to an initial peri-implantitis, the use of hand instruments to remove biofilm is unsuitable. Here, a meta-analysis has shown that air polishing or an Er:YAG laser gave the best results for decontaminating the implant surfaces [28]. Controlled clinical trials have shown that the supplemental use of topical antibiotics or photodynamic therapy can also improve treatment outcomes [2, 21]. However, in many cases, especially when advanced peri-implantitis is present, non-surgical treatment is limited and ineffective due to the morphological characteristics of the implant surface [18]. In 2016, an S3-guideline regarding the treatment of inflammation around dental implants was published for the first time in Germany. Peri-implantitis cases presenting with probing depths > 7 mm are classified as prognostically unfavorable and the non-surgical treatment should be supplemented by surgical intervention at the earliest opportunity. However, up to the present time no preferred surgical protocol can be inferred from the literature [31]. Consensus among the authors of the guideline was that after decontamination of the implant surface, augmentation procedures (autologous bone or bone substitute materials) may result in radiologically detectable infill of intrabony defects. However, it has not yet been defined, which materials are suitable for grafting defects, and especially when referring to bone substitute materials what is meant by biological. Whether these defect fillers are resorbed, integrated into new bone, or encapsulated by connective tissue remains unclear. In addition, the authors of the guideline recommend the intraoperative removal of the granulation tissue and report that the surgical treatment of peri-implantitis is associated with a high risk for the development of postoperative recession. The present paper shows a case series in which a new periodontal surgical procedure has been successfully conducted. The aim of this procedure is to preserve as much as pos-

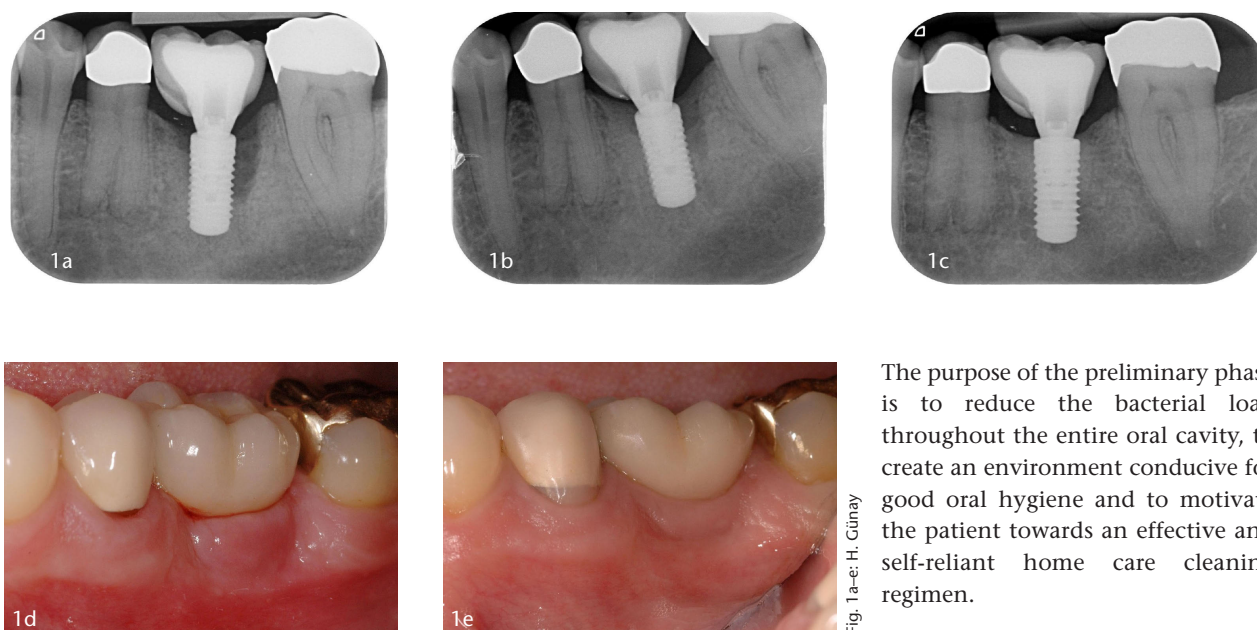


Fig. 1a-e: H. Günay

Figure 1a-e Clinical situation and radiographs before and after conservative therapy in a case of peri-implantitis regio 36; **Fig. 1a:** Radiograph before therapy; **Fig. 1b:** Radiograph one year after therapy; **Fig. 1c:** Radiograph 5.5 years after therapy; **Fig. 1d:** Clinical situation before therapy; **Fig. 1e:** Clinical situation 5.5 years after therapy

sible of the intralesional granulation tissue. By preserving this endogenous soft tissue support, postoperative recession can be significantly reduced. The effectiveness and safety of this procedure when used for regenerative periodontal surgery has already been demonstrated [10] and can be regarded as a part of the armamentarium for regenerative peri-implant treatment.

Systematic therapy of inflammatory peri-implant diseases

Successful treatment of peri-implant inflammation is never just limited to localized treatment of an affected implant, but must always include the whole mouth, which comprises all placed implants and any residual dentition. Therefore, there is a necessity for each patient presenting with peri-implant inflammation to undergo an appropriate preliminary phase as follows:

Preliminary phase

Since periodontal and peri-implant inflammations are always associated with a dysbiotic oral biofilm, it is important to eliminate this bacterial imbalance by employing a whole

mouth antibacterial strategy („Whole Mouth Therapy“). The preliminary phase includes the following treatment measures:

1. Establishment of an oral environment that permits good oral hygiene by rehabilitating any remaining dentition (such as extraction of any unsavable teeth, restoring carious lesions, recontouring and polishing overextended restoration margins, providing hygienic temporary restorations).
2. Professional prophylaxis with a thorough scaling and polishing. Recording of plaque and inflammation indices for individual information, motivation and instruction of patients (iIMI).
3. Evaluation and minimization of periodontal risk factors.
4. Evaluation of the implantological and peri-implantological history (see below).
5. Assessment of periodontal status and planning of the therapy regimen (see below).
6. Any non-surgical periodontal therapy for the residual dentition.
7. Assessing and if necessary modification of the implant suprastructure to enable adequate oral hygiene measures.

The purpose of the preliminary phase is to reduce the bacterial load throughout the entire oral cavity, to create an environment conducive for good oral hygiene and to motivate the patient towards an effective and self-reliant home care cleaning regimen.

Non-surgical peri-implantitis treatment

In contrast to non-surgical periodontitis therapy, non-surgical peri-implant therapy, especially in advanced cases, has low success rates due to the morphology of the implant surface (exposed threads, roughness, different surface modifications dependant on type of implant). This can hinder adequate mechanical removal of the biofilm without surgical access. The sufficient removal of mineralized biofilm (calculus) as part of non-surgical therapy is virtually impossible (Figure 3a).

The peri-implantological history, the defect morphology, and the accessibility to the implant surface should precisely be evaluated before initiation of the therapy. Peri-implantitis lesions at implants with a short history (functional loading < 1 year) do not show any mineralization of the submucosal biofilm in most cases. When there is adequate access to the peri-implant defect, regular closed decontamination of the implant surface without surgical intervention may result in remission of peri-implant bone loss. An appropriate case that demonstrates the potential of this conservative strategy are shown in Figures 1a–1e. The implant regio 36 had been under functional load for 11 months and presented with a 10 mm distal probing pocket depth at baseline. A pronounced vertical bone defect was visible radiographically (Fig. 1a).

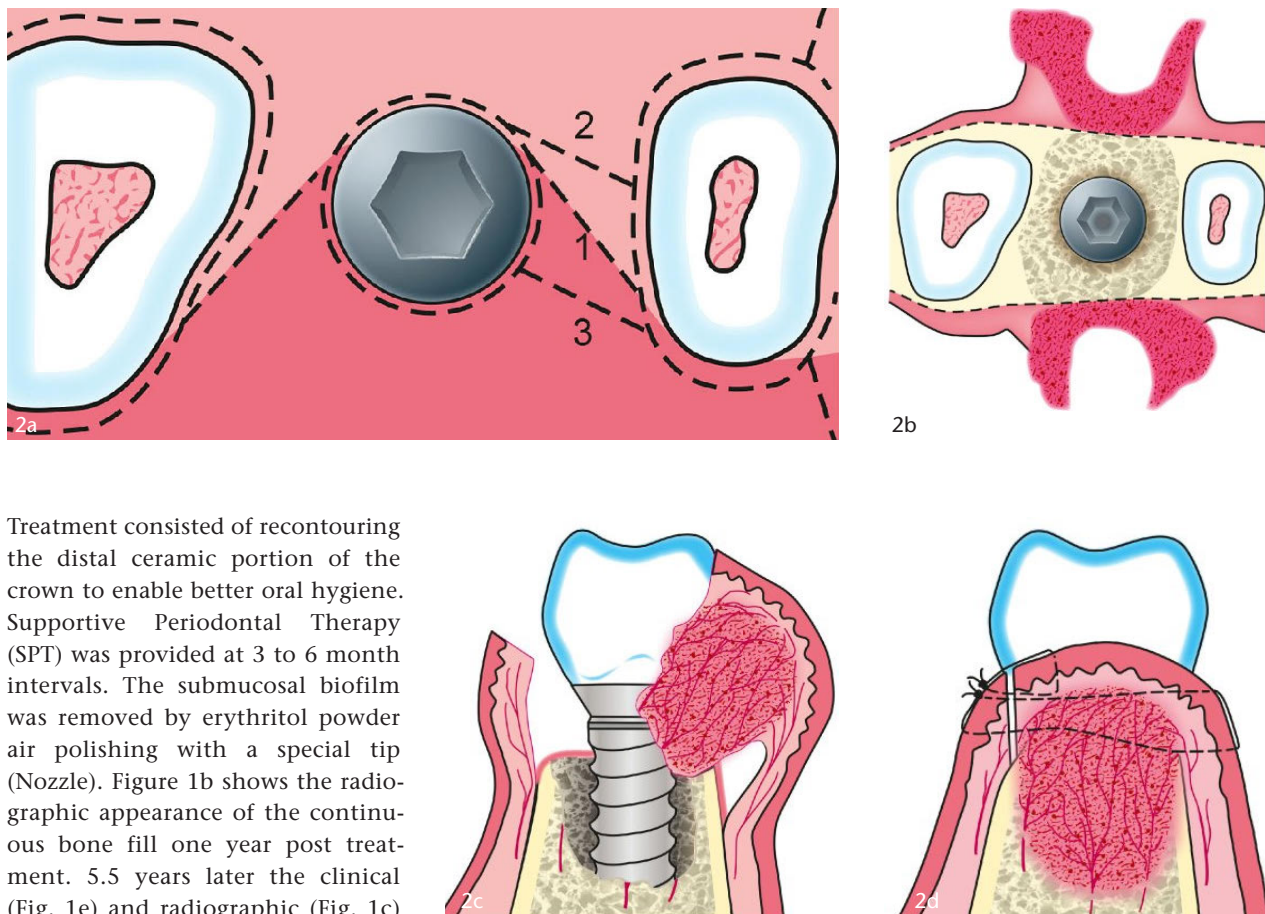


Figure 2a–d Schematic view of the granulation tissue preservation technique; **Fig. 2a:** Intrasulcular and z-shaped incisions; **Fig. 2b:** Mobilisation of the mucoperiosteal flap with adherent granulation tissue – occlusal view; **Fig. 2c:** Mobilisation of the mucoperiosteal flap with adherent granulation tissue – interproximal view; **Fig. 2d:** Reposition of the mucoperiosteal flap with adherent granulation tissue and wound closure by sutures

Fig. 2a–d: H. Günay, Digital Media/Graphics – Hannover Medical School

Treatment consisted of recontouring the distal ceramic portion of the crown to enable better oral hygiene. Supportive Periodontal Therapy (SPT) was provided at 3 to 6 month intervals. The submucosal biofilm was removed by erythritol powder air polishing with a special tip (Nozzle). Figure 1b shows the radiographic appearance of the continuous bone fill one year post treatment. 5.5 years later the clinical (Fig. 1e) and radiographic (Fig. 1c) follow-ups show stable, integrated bone replenishment with complete preservation of the marginal peri-implant soft tissue. Advanced peri-implantitis cases usually have a longer history and early surgical treatment is indicated. However, surgical intervention should also be preceded by a non-surgical therapy to eliminate or reduce inflammatory signs around implants. This is advantageous because it reduces intraoperative bleeding and the extent of postoperative mucosal recession, thereby contributing to the success of the surgical treatment. After non-surgical measures it has been shown to be worthwhile and it is recommended to wait for 2 to 3 weeks before commencing any surgery.

The protocol followed for non-surgical peri-implantitis treatment is shown in Table 1.

Using an air abrasive device submucosally involves the risk of emphysema particularly when there is a limited amount of keratinized tissue or a thin soft tissue. In such cases, the peri-implant soft tissue should be compressed with a wet


swab held parallel to the nozzle of the instrument, whilst decontaminating the implant surface. This will prevent any mixture of water, air and powder from penetrating the tissues.

Surgical treatment of peri-implantitis

In order to create optimal conditions for successful surgery, the preliminary phase and non-surgical therapy must have already been accomplished. In essence, there are two competing surgical strategies; using resective techniques or alternatively a regenerative approach. Resective procedures are limited to cases where regenerative methods are contraindicated. These include primarily patients with a high periodontal risk (heavy smokers, non-compliant patients, poor diabetic

control), but also local implant specific factors (poor design, oral hygiene measures hindered by the suprastructure). In addition, the morphology of the peri-implant bone defect and the implantological history are critical for the choice and predictability of the treatment regimen [27]. In particular, prior surgical augmentations must be enquired about. In cases of a single or two walled bony defect with no buccal plate and a history of pre-implantation augmentation it is likely that the current peri-implantitis derives from the base of a failed augmentation. In such cases, regenerative therapy has a poor prognosis and conservative or resective procedures are preferable.

Peri-implant surgical regenerative therapy by means of the Granulation Tissue Preservation Technique (GTPT)



Figures 3a–b Surface of a removed implant before and after decontamination with a titanium brush; **Fig. 3a:** Implant surface with mineralized bacterial deposits; **Fig. 3b:** Cleaned implant surface after decontamination with a (sonic) titanium brush

Fig. 3a–b: H. Günay

is performed in the following chronological order:

An antibacterial mouth rinse is applied 24 h and immediately before the operation, e.g. with a 0.2 % chlorhexidine digluconate solution (CHX). Local analgesia with an adrenalin containing local anesthetic is given followed by rinsing of the peri-implant pockets with CHX. Next an intrasulcular incision is made around the affected implant together with any neighboring teeth or implants using a microsurgical scalpel (Micro Miniature Blade 6962, Surgistar, Knoxville, USA). Interproximally the incision is contoured in an oblique z-shaped design (Fig. 2a). During mobilization of the mucoperiosteal flap, care must be taken to preserve the intralesional granulation tissue, so far as it is possible, by separating it distinctly from the underlying bony surface (Fig. 2b, 2c).

The mobilization of the mucoperiosteal flap should be made with a minimally invasive technique using a microsurgical raspatorium (Hamacher, Solingen, Germany) until the edge of the defect becomes visible. This ensures that there is a safe access for the decontamination of the implant surface. For the removal of soft, non-mineralized biofilm air polishing is sufficient. If mineralized bacterial deposits (calculus) are present (Fig. 3a), the additional use of a sonic-driven polymer pin

(e.g. Komet Dental, Lemgo, Germany) and/or a titanium brush (e.g. TiBrush, Straumann GmbH, Freiburg, Germany) is recommended to ensure their complete removal (Fig. 3b).

The mechanical decontamination of the implant surface can be chemically reinforced by the subsequent application of a saturated tetracycline hydrochloride solution or an EDTA gel (PrefGel, Straumann GmbH, Freiburg, Germany). After intensive rinsing with a sterile, isotonic saline solution, the implant surfaces are dried by means of aspirating using the surgical suction. Next follows the application of enamel matrix derivatives (Emdogain, Straumann GmbH, Freiburg, Germany) with care being exercised so that the exposed implant surfaces are not contaminated with blood or saliva. In cases where the application of enamel matrix derivatives is not possible (e.g., for religious or financial reasons), the decontaminated implant surface should be kept saliva free until a stable fibrin clot has had time to form. The mucoperiosteal flap is then replaced together with its adherent granulation tissue and fixed with sutures (e.g., GORE-TEX Suture CV-6, W.L. Gore & Associates, Putzbrunn, Germany and /or Prolene 6–0, Ethicon GmbH, Norderstedt, Germany; Figure 2d). A recommended suturing technique would

be to place either a modified mattress suture or a horizontal internal mattress suture in combination with a single interrupted suture. The surgery is completed by applying gentle pressure to the wound by means of moistened, sterile swabs for 1 min. Postoperative antibiotics should only be prescribed in extremely advanced cases of peri-implantitis (peri-implant bone loss > 50 %) or in unfavorable locations (e.g., deep lingual defect in the proximity of the sublingual space). In such cases, clindamycin (2x 600 mg daily over 7 days) has been effective. In regard to „Antibiotic Awareness“ antibiotics should in principle only be used judiciously. They are rarely indicated and should preferably be used as an adjunct to non-surgical treatment.

The protocol followed for surgical peri-implantitis treatment is shown in Table 2.

Postoperative care

In order to achieve the best possible treatment outcome, patients must comply with the postoperative instructions that they are given. In addition to a verbal explanation, it has been shown to be beneficial to hand out a written instruction leaflet prior to the surgery (possibly during the informed consent process) which the patient can take home and study. To ensure optimal wound healing, the patient should not perform any home based oral hygiene at the surgical site for at least 14 days after the procedure. During this time, a twice daily use of a CHX containing mouth wash to rinse the area is recommended except the first 24 h postoperatively. In this period a gentle mouth bath of isotonic saline solution at 2 hourly intervals should be employed and has been shown to be adequate for initial home care. Vigorous rinsing, at any time, should definitely be avoided to prevent dehiscences and wound breakdown. In most cases, normal oral hygiene measures can be resumed after 14 days with a soft manual toothbrush. However, it is recommended that interdental hygiene measures be discontinued for another 2 weeks in order to ensure a safe healing of the interdental papil-

lae. Just as important as the patient's compliance with postoperative instructions are frequent professional follow-up appointments in order to supervise the healing process. The postoperative follow-up regimen should include controls at 1, 2, 3 and 6 weeks postoperatively. At each appointment, careful debridement and biofilm removal is performed in the region of the surgical site. The sutures should be removed 2 weeks postoperatively.

Supportive peri-implant therapy

Analogous to supportive periodontal therapy [7, 16], follow-up intervals every 3 months are recommended for the first postoperative year following peri-implant treatment. This is followed by a recall frequency adapted to the individual risk profile. However, follow-up intervals of 6 months should not be exceeded. As a part of supportive peri-implant therapy, in addition to professional cleaning and maintenance of any remaining teeth, it is always advisable to use an air abrasive device (powder based on glycine or erythritol) on any treated implants. Bone regeneration around an implant is slower when compared to that seen around natural teeth and consequently radiographs should be taken at least 1 year postoperatively for diagnostic purposes. A radiograph 6 months after surgery may demonstrate healing tendency but is probably too early to show any regenerative effects.

Case reports

Case report 1

The patient was 47 years old when she was referred to the Department of Conservative Dentistry, Periodontology and Preventive Dentistry of the Hannover Medical School due to an advanced peri-implantitis regio 46. She revealed no periodontal risk factors and her periodontal and dental status was adequate. As part of her initial evaluation, a radiograph of the implant regio 46 was made (Fig. 4a) and the probing depths around the implant were measured (maximum probing depth distoves-

Chronological decontamination protocol	
1	1 minute use of a chlorhexidine digluconate (0.2%) (CHX) or octenidine dihydrochloride (0.1%) (OCT) mouthwash
2	Local analgesia
3	Remove (if possible) and clean the suprastructure
4	Antibacterial irrigation of the peri-implant pockets with CHX (0.2%) or OCT (0.1%)
5	Supramucosal removal of the biofilm with a sonic-driven brush, polymer pin and air abrasive device
6	Glycine or erythritol powder air polishing with a special tip (Nozzle) to remove submucosal biofilm
7	Antibacterial irrigation of the peri-implant pockets with CHX (0.2 %) or OCT (0.1 %)
8	Application of a local antibiotic (e.g., Ligosan® Kulzer GmbH, Hanau, Germany) or systemic antibiotic (e.g., clindamycin) in exceptional cases

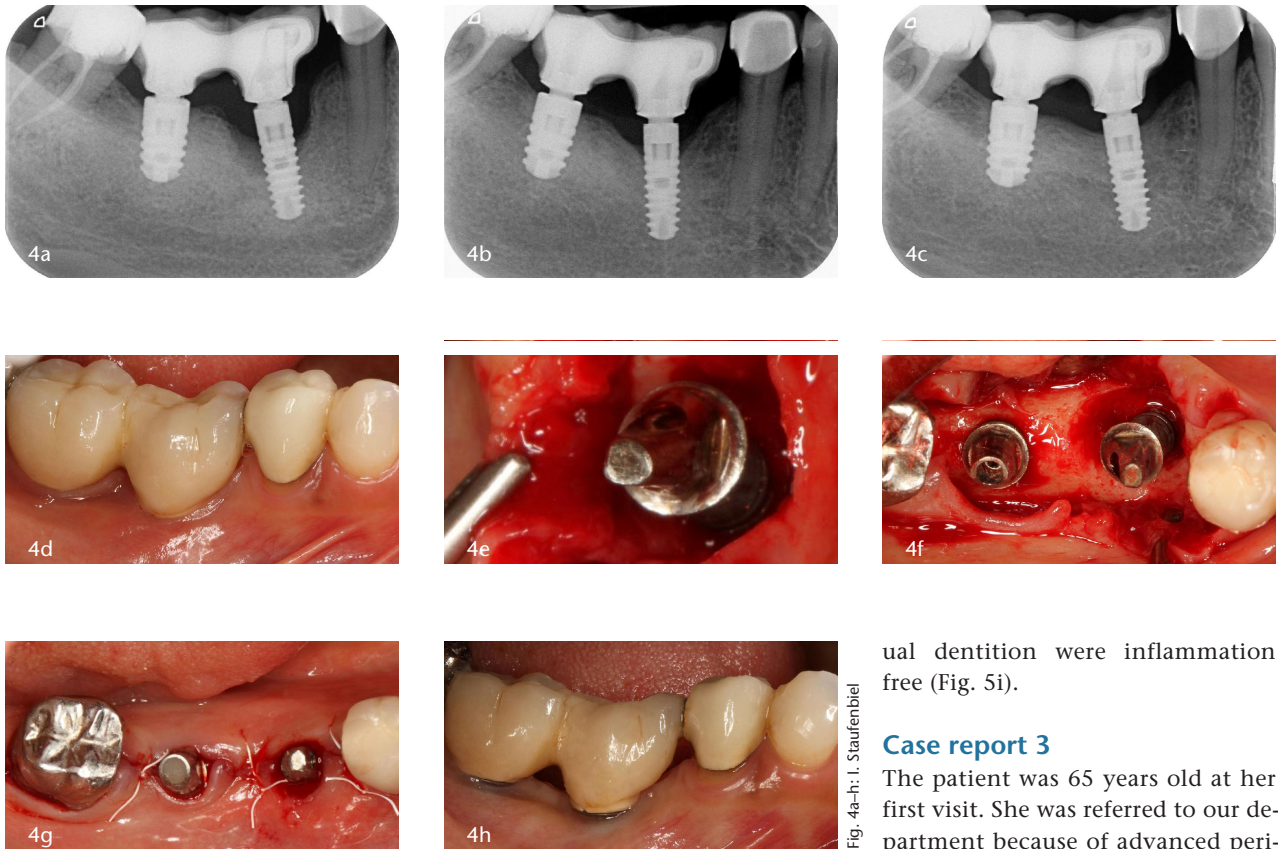
Table 1 Decontamination protocol in non-surgical periimplantitis therapy (Tab. 1 and 2: I. Staufenbiel and H. Günay)

tibular: 9 mm). The patient was informed about the diagnosis and treatment options and underwent professional oral hygiene at the same session. In a second session, a non-surgical peri-implant treatment was carried out at the implant regio 46 under local analgesia. There was a slight mobility of the crown block 46/47. After removal of this crown block it became obvious that the luting cement of the crown 46 had been completely lost. In addition, its screw channel was exposed, resulting in a massive plaque accumulation in this conduit. This was identified as a potential etiological factor. The splinted crowns and abutment were professionally cleaned. The decontamination of the implant surface was carried out according to the decontamination protocol (Table 1). After 2 weeks, surgical intervention was performed according to the surgical protocol (Table 2). The patient returned for all immediate postoperative follow-up appointments and attended to supportive peri-implant therapy at 3-monthly

intervals. The clinical situation before surgery, intraoperatively and after suture closure is shown in Figure 4d–4g. Radiographs taken after 1 and 2.5 years following the surgery document the resolution of the osseous defect (Fig. 4b, 4c). The clinical picture 2.5 years postoperatively (Fig. 4h) reveals the development of a 1 mm mucosal recession. The periodontal parameters after surgery show a significant reduction in probing depths (Δ PD 7 mm) and marked clinical attachment gain (Δ CAG 6 mm) compared to the baseline findings.

Case report 2

The patient was 71 years old when first seen in our department. He had been referred due to generalized periodontal and localized peri-implant problems around the implant regio 45. The patient had chronic generalized periodontitis but no lifestyle associated periodontal risk factors. As part of his initial diagnosis, a radiograph was taken of the implant regio 45 (Fig. 5a). The initial



Figures 4a–h Case 1 – regenerative therapy in a case of peri-implantitis regio 46; **Fig. 4a:** Radiograph before therapy; **Fig. 4b:** Radiograph one year after therapy; **Fig. 4c:** Radiograph 2.5 years after therapy; **Fig. 4d:** Clinical situation before therapy; **Fig. 4e:** Intraoperative view after mobilisation of the mucoperiosteal flap with adherent granulation tissue; **Fig. 4f:** Intraoperative view of the bony defect (three-wall defect) after decontamination of the implant surface; **Fig. 4g:** Clinical situation after reposition of the mucoperiosteal flap and wound closure by sutures; **Fig. 4h:** Clinical situation 2.5 years after therapy

probing depths around this implant revealed a maximum probing depth of 8 mm. The patient was informed about the diagnostic and therapeutic options and underwent systematic periodontal therapy. As part of his non-surgical periodontal therapy, decontamination of the implant surface was carried out under local analgesia according to the decontamination protocol (Table 1). To do this, the screw retained bridge regio 45, 46, 47 was removed (Fig. 5d) and healing abutments were inserted in its place. As an etiological factor, noticeable plaque accumulation on the bottom side of the bridge (Figure 5e) was identified. This indicated insufficient home care and poor oral hygiene. The patient was instructed accordingly and the bridge was professionally cleaned in the dental laboratory. After 3

weeks surgical peri-implant therapy was carried out according to the surgical protocol (Table 2) (Fig. 5f, 5g). The patient attended to the postoperative follow-ups and was recalled subsequently every 3 months for supportive peri-implant therapy. The bridge was refastened on its abutments 6 weeks after surgery. Figure 5h shows the clinical situation after suture closure. The radiographs at 1 and 3 years postoperatively (Fig. 5b, 5c) show the resolution of the bony defect. The periodontal measurements 3 years after surgery (maximum probing depth 3.5 mm) demonstrate a significant reduction in probing depths (Δ PD 4.5 mm) compared to the baseline findings. Since no mucosal recession occurred, 4.5 mm of clinical attachment was re-established. Clinically, the implant regio 45 and the resid-

ual dentition were inflammation free (Fig. 5i).

Case report 3

The patient was 65 years old at her first visit. She was referred to our department because of advanced peri-implantitis regio 43. As part of the initial diagnosis, a radiograph was made of the implant regio 43 (Fig. 6a) and the initial probing depths were recorded around the implant (maximum probing depth buccal: 9 mm). The patient underwent professional tooth cleaning. At the same session non-surgical peri-implant therapy on the implant regio 43 was conducted under local analgesia. The suprastructure was cement retained and showed no marginal leakage. The implant angulation was unfavorable for adequate oral hygiene measures and this seemed to be the crucial etiological factor in this case. Through individual instruction, the patient was able to achieve satisfactory plaque control at home despite the challenging unhygienic design limitations. Therefore, the suprastructure was left in position. The decontamination of the implant surface was carried out according to the decontamination protocol (Table 1). After 2 weeks surgical peri-implant therapy was performed according to the surgical protocol (Table 2). However, in this case no enamel matrix derivatives were used. The patient returned for all immediate postoperative follow-

Fig. 4a–h: I. Staufenbergel

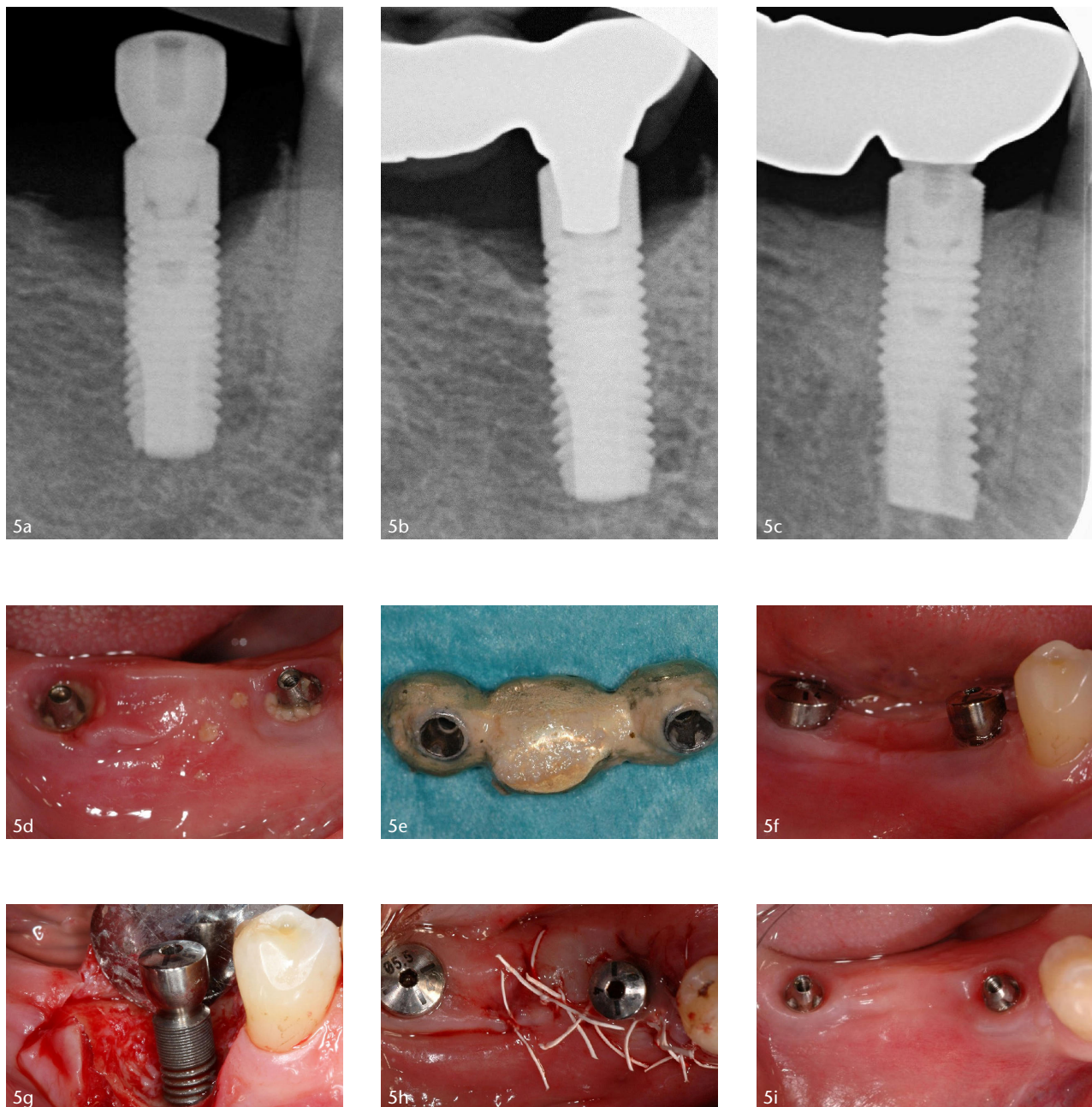


Fig. 5a-i: H. Günay

Figures 5a–i Case 2 – regenerative therapy in a case of peri-implantitis regio 45; **Fig. 5a:** Radiograph before therapy; **Fig. 5b:** Radiograph 1 year after therapy; **Fig. 5c:** Radiograph 3 years after therapy; **Fig. 5d:** Clinical situation after removal of the bridge; **Fig. 5e:** Bridge with matured biofilm – basal view; **Fig. 5f:** Clinical situation before surgery with inserted healing abutments; **Fig. 5g:** Intraoperative view of the bony defect (three-wall defect) after decontamination of the implant surface; **Fig. 5h:** Clinical situation after reposition of the mucoperiosteal flap and wound closure by sutures; **Fig. 5i:** Clinical situation 3 years after therapy

up appointments and then began supportive peri-implant therapy at 3-monthly intervals. The clinical situation before surgery, intraoperatively and after suture closure are shown in Figures 6d–6f. The dental film 30 months postoperatively shows an infilling of the bony defect (Fig. 6b). After 6 years the condition remained stable (Fig. 6c). In comparison to the baseline findings,

the probing depths were significantly reduced (Δ PD 6 mm), resulting in a clinical attachment gain of 6 mm. The corresponding clinical picture shows the most important advantage of the granulation tissue preserving technique: soft tissue conditions remained stable over the observation period and no mucosal recession occurred (Fig 6g).

Discussion

Presently, despite the high prevalence of peri-implant inflammation, there are no evidence-based treatment recommendations. Although the new S3-guideline for the treatment of peri-implant inflammation provides information on the effectiveness of various methods for decontaminating the implant surface, it also reveals the low success rate of non-surgical

Surgical protocol	
1	One minute use of a chlorhexidine digluconate (0.2 %) (CHX) or octenidine dihydrochloride (0.1 %) (OCT) mouthwash
2	Local analgesia
3	Remove (if possible) and clean the suprastructure
4	Antibacterial irrigation of the peri-implant pockets with CHX (0.2 %) or OCT (0.1 %)
5	Mobilization of a mucoperiosteal flap with adherent intraslesional granulation tissue (intrasulcular incision)
6	Removal of mineralized biofilm with a polymer pin and/or a titanium brush Removal of the biofilm with sonic-driven brush, titanium brush and/or air abrasive device (powder based on glycine or erythritol).
7	Irrigation of the peri-implant pockets with sterile isotonic saline
8	Chemical decontamination with an EDTA gel (PrefGel®)
9	Irrigation of the peri-implant pockets with sterile isotonic saline solution
10	Regenerative therapy preferred with enamel matrix derivatives (EMD – Emdogain®) (Note: Inform patients about non-indicated specific use of the EMD!)
11	Suture and compression of the surgical field
12	Systemic antibiotics (e.g., clindamycin) only in exceptional cases
13	Information on postoperative instructions (information sheet)

Table 2 Operation protocol for surgical periimplantitis therapy

approaches to pronounced peri-implantitis. The recommendation, therefore, is to treat cases of advanced peri-implantitis early with a surgical approach. However, the question of which surgical protocol is preferable is still unresolved [31]. Basically, the following different operative procedures compete:

1. Access flap surgery, decontamination of the implant surface [6, 23]
2. Access flap surgery, decontamination of the implant surface and defect filling with bone substitute materials with or without the use of a membrane [6, 23]
3. Access flap surgery, decontamination of the implant surface and defect grafting with autologous

bone with or without use of a membrane [6, 23]

4. Access flap surgery, decontamination of the implant surface and application of biological mediators, e.g. enamel matrix derivatives [12, 13].

All these procedures recommend the removal of intraslesional granulation tissue, although the subsequent increased risk of postoperative mucosal recession is well known [31]. The case reports shown in the present paper were invariably operated on using the granulation tissue preserving technique. The greatest possible preservation of the intraslesional granulation tissue provides the following advantages:

1. The greatest possible preservation of multipotent mesenchymal stem cells, which are essential for regeneration, especially when enamel matrix derivatives are used.
2. Preservation of the vascular network in the granulation tissue allows for faster and better wound healing.
3. The intraslesional granulation tissue represents the body's own matrix, serves as an optimal soft tissue support, prevents the development of postoperative mucosal recession and thus allows the greatest possible bony defect filling.

For regenerative periodontal therapy it has been shown that the presence of mesenchymal stem cells is an important prerequisite [17]. Previous *in vitro* studies have revealed that populations of multipotent mesenchymal stem cells are present in periodontal and peri-implant granulation tissue [9, 19]. The granulation tissue preservation technique also allows the implant to be in the proximity of the greatest possible number of multipotent mesenchymal stem cells, which are of crucial importance for regeneration, especially when biological mediators such as enamel matrix derivatives are used.

The goal of regenerative therapy of peri-implantitis is the reosseointegration of previously contaminated implant surfaces. There is general agreement in the literature that an open, surgical procedure and a closed healing phase give better results for reosseointegration than a non-surgical, closed procedure and an open, transgingival healing [22]. However, as yet no procedure has been identified that predictably leads to a reosseointegration of previously contaminated implant surfaces. The healing of peri-implant defects is frequently associated with the formation of a long junctional epithelium or a connective tissue attachment and can therefore not be regarded as regeneration but as repair [5]. In regenerative periodontal therapy, regeneration of the root cementum, the periodontal ligament and alveolar bone can be achieved by the use of enamel matrix derivatives. This effect from enamel matrix derivatives is based essentially

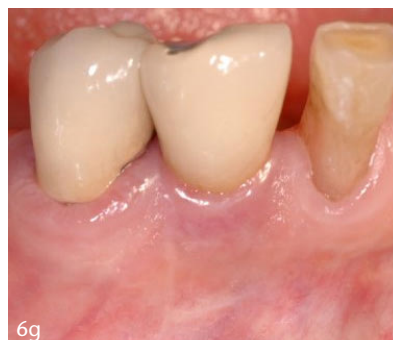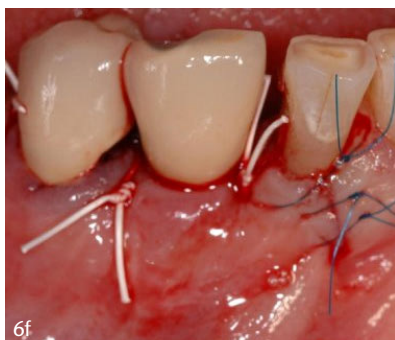
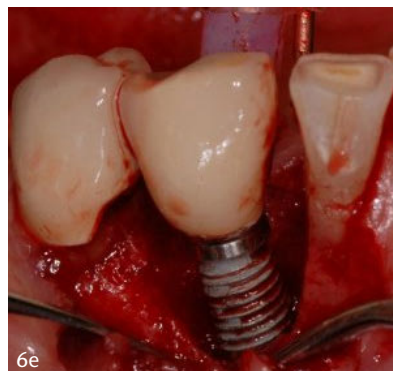
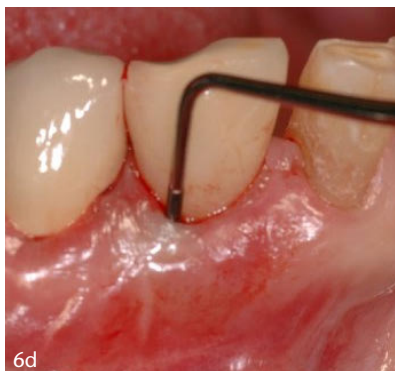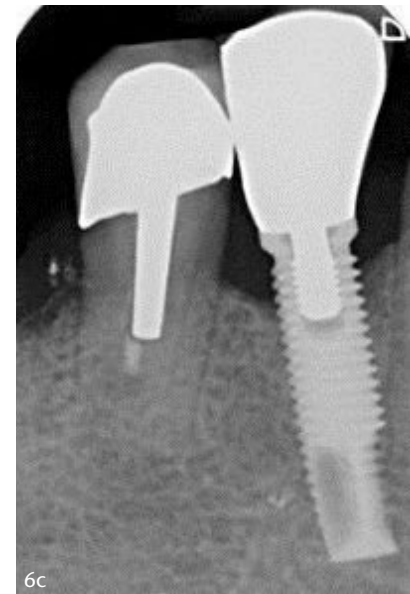
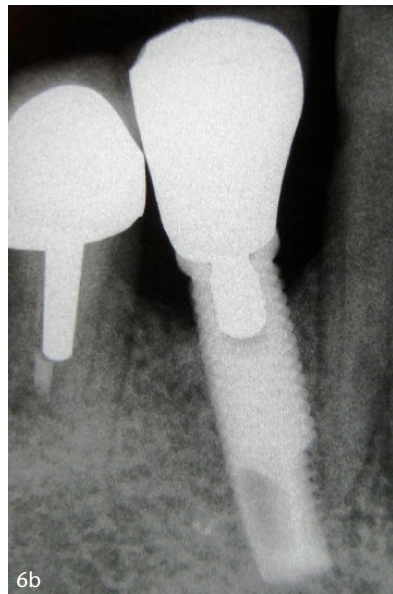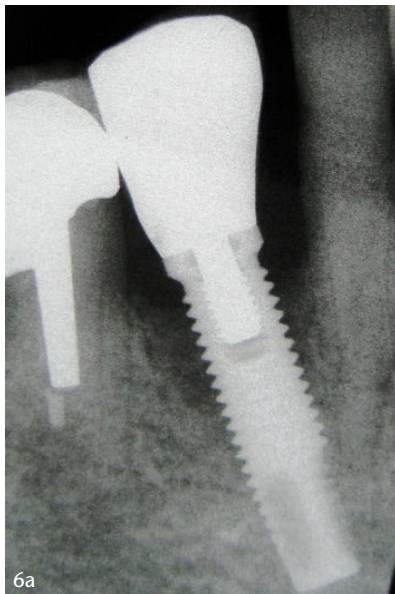


Fig. 6a-g: H. Gümay

Figures 6a–g Case 3 – regenerative therapy in a case of peri-implantitis regio 43; **Fig. 6a:** Radiograph before therapy; **Fig. 6b:** Radiograph 2.5 years after therapy; **Fig. 6c:** Radiograph 6 years after therapy; **Fig. 6d:** Clinical situation before therapy; **Fig. 6e:** Intraoperative view of the bony defect (three-wall defect) after decontamination of the implant surface; **Fig. 6f:** Clinical situation after repositioning of the mucoperiosteal flap and wound closure by sutures; **Fig. 6g:** Clinical situation 2.5 years after therapy

on an inhibition of the cells of the gingival epithelium and a stimulation of the cells of the periodontal ligament and alveolar bone. For a detailed description of the effects of

enamel matrix derivatives on the cells of the periodontium, reference should be made to the review by Bosshardt [4]. A regenerative effect from enamel matrix derivatives is also

more than likely in the healing of peri-implant defects. However, so far there is no histological evidence that enamel matrix derivatives, applied during regenerative therapy of peri-implantitis, prevent the formation of a long junctional epithelium or a connective tissue attachment and promote reosseointegration.

In the third case report, the application of enamel matrix derivatives was abandoned and yet a pronounced bone fill was achieved. This shows that the application of enamel matrix derivatives is not an absolute prerequisite but only one aspect of regenerative peri-implant therapy. Many factors contribute to predictable therapeutic success. In addition to adequate pre-treatment and post-operative care, this primarily includes the surgical technique. In the past, even in non-surgical peri-implantitis therapy, soft tissue curettage (exfoliation of the pocket epithelium and infected connective tissue) was recommended, but in most cases today, preservation of the soft tissue level is the primary focus. For this, the use of microsurgical instruments, a minimally invasive surgical procedure, an adequate decontamination of the implant surface, the stability of the fibrin clot and sufficient suture closure are of crucial importance. All of these components can be combined through the rationale of the granulation tissue-preserving technique. The use of enamel matrix derivatives

is in no way disadvantageous and in many cases can accelerate the healing time. Therefore, in most cases, the granulation tissue preservation technique should be supplemented with an application of enamel matrix derivatives.

Conclusion

The three case reports show the potential and demonstrate the effectiveness of the granulation tissue preservation technique, especially with regard to the prevention of postoperative mucosal recession and the achievement of the greatest possible infilling of bony defects. In addition, enamel matrix derivatives have been shown to be an important supplement in the surgical treatment of peri-implantitis.

Conflicts of interest:

The authors declare that there is no conflict of interest within the meaning of the guidelines of the International Committee of Medical Journal Editors.

Literature

- Albrektsson T, Donos N; Working Group 1: Implant survival and complications. The third EAO consensus conference 2012. *Clin Oral Implants Res* 2012; 23: 63–65
- Bassetti M, Schär D, Wicki B et al.: Anti-infective therapy of peri-implantitis with adjunctive local drug delivery or photodynamic therapy: 12-month outcomes of a randomized controlled clinical trial. *Clin Oral Implants Res* 2014; 25: 279–287
- Berglundh T, Armitage G, Araujo MG et al.: Periimplant diseases and conditions: Consensus report of workgroup 4 of the 2017 World Workshop on the Classification of Periodontal and Peri-Implant Diseases and Conditions. *J Clin Periodontol* 2018; 45(Suppl 20): 286–291
- Bosshardt DD: Biological mediators and periodontal regeneration: a review of enamel matrix proteins at the cellular and molecular levels. *J Clin Periodontol* 2008; 35: 87–105
- Carcuac O, Abrahamsson I, Charalampakis G, Berglundh T: The effect of the local use of chlorhexidine in surgical treatment of experimental peri-implantitis in dogs. *J Clin Periodontol* 2015; 42: 196–203
- Claffey N, Clarke E, Polyzois I, Renvert S: Surgical treatment of peri-implantitis. *J Clin Periodontol* 2008; 35: 316–332
- Cohen RE; Research, Science and Therapy Committee, American Academy of Periodontology: Position paper: periodontal maintenance. *J Periodontol* 2003; 74: 1395–1401
- Derks J, Tomasi C: Peri-implant health and disease. A systematic review of current epidemiology. *J Clin Periodontol* 2015; 42: 158–171
- Gousopoulou E, Adam K, Bakopoulou A et al.: Properties of stem cell-like populations in peri-implantitis-associated granulation tissue. *J Clin Periodontol* 2018; 54 (S19): 362
- Günay H, Weinspach K, Geurtsen W, Staufienbiel I: Die Rolle des intraläsionalen Granulationsgewebes bei der regenerativen Parodontalchirurgie – Fallberichte. *Dtsch Zahnärztl Z* 2013; 68: 526–537
- Heitz-Mayfield LJA, Salvi GE: Peri-implant mucositis. *J Clin Periodontol* 2018; 45(Suppl 20): 237–245
- Ished C, Holmlund A, Renvert S, Svenson B, Johansson I, Lundberg P: Effectiveness of enamel matrix derivative on the clinical and microbiological outcomes following surgical regenerative treatment of peri-implantitis. A randomized controlled trial. *J Clin Periodontol* 2016; 43: 863–873
- Ished C, Svenson B, Lundberg P, Holmlund A: Surgical treatment of peri-implantitis using enamel matrix derivative, an RCT: 3- and 5-year follow-up. *J Clin Periodontol* 2018; 45: 744–753
- Jepsen S, Berglundh T, Genco R et al.: Primary prevention of peri-implantitis: managing peri-implant mucositis. *J Clin Periodontol* 2015; 42: 152–157
- Jung RE, Zembic A, Pjetursson BE, Zwahlen M, Thoma DS: Systematic review of the survival rate and the incidence of biological, technical, and aesthetic complications of single crowns on implants reported in longitudinal studies with a mean follow-up of 5 years. *Clin Oral Implants* 2012; 23: 2–21
- Lang NP, Tonetti MS: Periodontal risk assessment (PRA) for patients in supportive periodontal therapy (SPT). *Oral Health Prev Dent* 2003; 1: 7–16
- Lin N-H, Menicanin D, Mrozik K, Gronthos S, Bartold PM: Putative stem cells in regenerating human periodontium. *J Periodont Res* 2008; 43: 514–523
- Lindhe J, Meyle J: Group D of European Workshop on Periodontology: Peri-implant diseases: Consensus Report of the Sixth European Workshop on Periodontology. *J Clin Periodontol* 2008; 35: 282–285
- Park JC, Kim JM, Jung IH et al.: Isolation and characterization of human periodontal ligament (PDL) stem cells (PDLSCs) from the inflamed PDL tissue: in vitro and in vivo evaluations. *J Clin Periodontol* 2011; 38: 721–731
- Pjetursson BE, Thoma D, Jung R, Zwahlen M, Zembic A: A systematic review of the survival and complication rates of implant-supported fixed dental prostheses (FDPs) after a mean observation period of at least 5 years. *Clin Oral Implants Res* 2012; 23: 22–38
- Renvert S, Lessem J, Dahlén G, Lindahl C, Svensson M: Topical minocycline microspheres versus topical chlorhexidine gel as an adjunct to mechanical debridement of incipient peri-implant infections: a randomized clinical trial. *J Clin Periodontol* 2006; 33: 362–369
- Renvert S, Polyzois I, Maguire R: Osseointegration on previously contaminated surfaces: a systematic review. *Clin Oral Implants Res* 2009; 20: 216–227
- Renvert S, Polyzois I, Claffey N: Surgical therapy for the control of peri-implantitis. *Clin Oral Implants Res* 2012; 23: 84–94
- Renvert S, Persson GR, Pirih FQ, Camargo PM: Peri-implant health, peri-implant mucositis, and peri-implantitis: case definitions and diagnostic considerations. *J Clin Periodontol* 2018; 45(Suppl 20): 278–285
- Salvi GE, Ramseier CA: Efficacy of patient-administered mechanical and/or chemical plaque control protocols in the management of peri-implant mucositis. A systematic review. *J Clin Periodontol* 2015; 42: 187–201
- Salvi GE, Cosgarea R, Sculean A: Prevalence and mechanisms of peri-implant diseases. *J Dent Res* 2017; 96: 31–37
- Schwarz F, Sahm N, Schwarz K, Becker J: Impact of defect configuration on the clinical outcome following surgical regenerative therapy of peri-implantitis. *J Clin Periodontol* 2010; 37: 449–455
- Schwarz F, Schmucker A, Becker J: Efficacy of alternative or adjunctive measures to conventional treatment of peri-implant mucositis and peri-implantitis: a systematic review and meta-analysis. *Int J Implant Dent* 2015; 1: 22
- Schwarz F, Becker K, Sager M: Efficacy of professionally administered plaque removal with or without adjunctive measures for the treatment of peri-implant mucositis. A systematic review and meta-analysis. *J Clin Periodontol* 2015; 42: 202–213

30. Schwarz F, Derks J, Monje A, Wang H-L: Peri-implantitis. J Clin Periodontol 2018; 45(Suppl 20): 246–266

31. Schwarz F, Becker J: Die Behandlung periimplantärer Infektionen an Zahnimplantaten. <http://www.dgzmk.de/zahnaerzte/wissenschaft-forschung/leitlinien/details/document/die-behandlung-periimplantaerer-infektionen-an-zahnimplantaten-s3.html>. (letzter Zugriff am 25.09.2018)

32. Smeets R, Henningsen A, Jung O, Heiland M, Hammächer C, Stein JM: Definition, etiology, prevention and treatment of peri-implantitis – a review. Head Face Med 2014; 3: 10–34



PROF. DR. HÜSAMETTIN GÜNAY
Department of Conservative Dentistry,
Periodontology and Preventive
Dentistry, Hannover Medical School
Carl-Neuberg-Str. 1, 30625 Hanover,
Germany
Guenay.H@mh-hannover.de



PD DR. INGMAR STAUFENBIEL
Department of Conservative Dentistry,
Periodontology and Preventive
Dentistry, Hannover Medical School
Carl-Neuberg-Str. 1, 30625 Hanover,
Germany
Staufenbiel.Ingmar@mh-hannover.de

(Photos: Hannover Medical School)