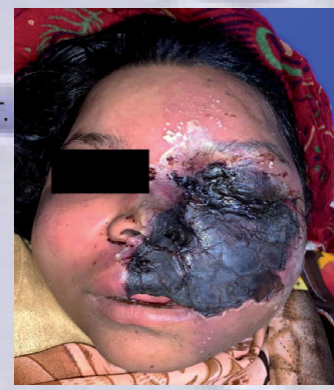

PRESENTED BY : DR. ARJUN MAHAJAN

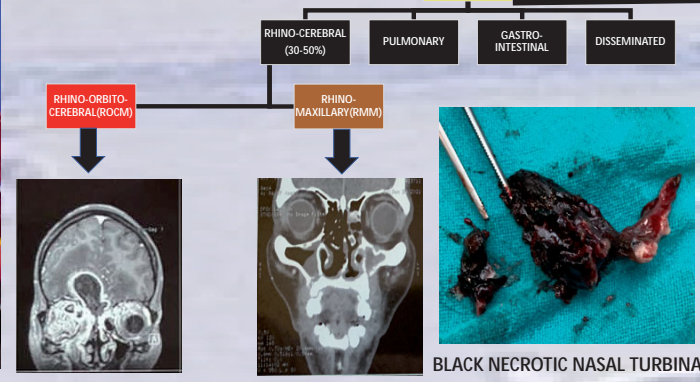
GUIDED BY: DR. NARESH KUMAR SHARMA, DR. NEERAJ KUMAR DHIMAN, DR. CHANDRESH JAISWARA, DR. PREETI TIWARI

INTRODUCTION

- COMMONLY KNOWN AS 'BLACK FUNGUS'
- EPIDEMIC OUTBURST DURING 2nd WAVE OF COVID-19 EPIDEMIC IN INDIAN SUBCONTINENT.
- ANGIOINVASIVE
- FULMINATES IN
 - HYPOXIA,
 - HYPERGLYCAEMIA,
 - ACIDOSIS,
 - IRON RICH ENVIRONMENT,
 - IMMUNOSUPPRESSION,
 - PROLONGED HOSPITALIZATION WITH VENTILATOR SUPPORT.

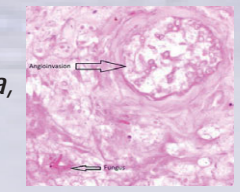


FORMS




ETIOLOGY

Genus: *Rhizopus mucor*, *Cunninghamella*, *Absidia*
Order: *Mucorales*
Class : *Zygomycetes* (*Rhizopus Oryzae* - most common)
-60% cases in humans and
-90% of the Rhino-orbital-cerebral (ROCM) FORM

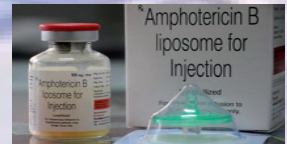


PHARMACOLOGICAL MANAGEMENT

- MODIFIED LANCET PROTOCOL USED IN BHU
- 1 UNIT NS OVER 1 HOUR + 1 AMP AVIL + 1 AMP FEVASTIN
- 5MG/KG/DAY LIPOSOMAL AMPHOTERICIN-B IN RMM
- 10MG/KG/DAY IN ROCM, IN 1 UNIT 5% DEXTROSE + R-INSULIN AS PER RBS OVER 6HRS
- 1 UNIT NS OVER 1 HR
- TAB POSACONAZOLE 300MG/DAY IN CASES WITH ALLERGY TO AMPHOTERICIN, FOLLOWUP CASES AND IN COMBINATION THERAPY.
- DAILY LFT, RFT, RBS MONITORING

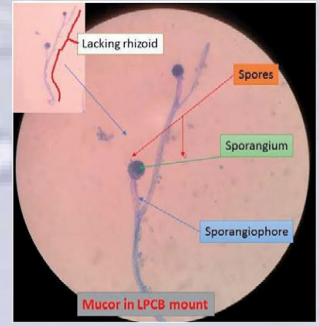


LIPOSOMAL AMPHOTERICIN-B WITH LIGHT PROOF INFUSION SET



DIAGNOSIS

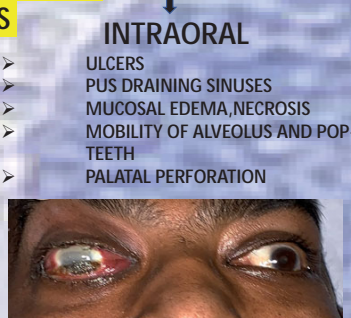
- CLINICAL
- RADIOGRAPHIC
- MICROBIOLOGICAL (CONFIRMATORY)-
DNE SPECIMEN SHOWS BROAD ASEPTATE HYPHAE (SPECIAL STAINS: GROCOTT METHENAMINE SILVER, PAS)
- HISTOPATHOLOGIC
 - NECROTIC BONE
 - FUNGAL SPORES IN VESSEL LUMEN



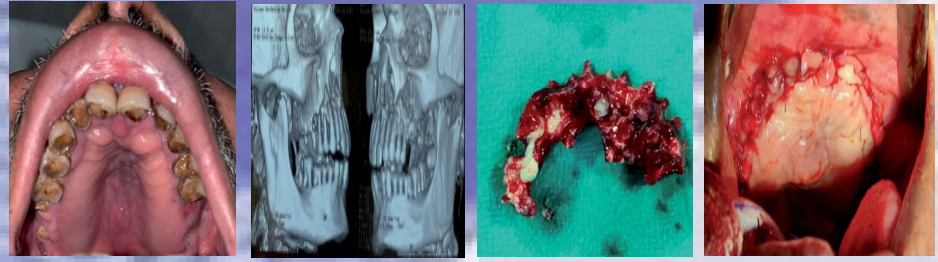
SIGNS SYMPTOMS AND FINDINGS

EXTRAORAL
FRONTAL HEADACHE, SINUSITIS
NASAL DISCHARGE (CSF RHINORRHEA)
PROGRESSES AS EDEMA
ERYTHEMA
NECROSIS
ESCHAR FORMATION
1950 SMITH AND KRICHNER CRITERIA CONSIDERED THE GOLD STANDARD.
CHEMOSIS, PROPTOSIS, OPTHALMOPLÉGIA, VISION LOSS.

INTRAORAL
ULCERS
PUS DRAINING SINUSES
MUCOSAL EDEMA, NECROSIS
MOBILITY OF ALVEOLUS AND POP+ TEETH
PALATAL PERFORATION



SURGICAL MANAGEMENT



KEY POINTS

- CREVICULAR INCISION IN DENTULOUS PART AND CRESTAL ON EDENTULOUS PART.
- RESECTION TILL FRESH BLEED IS OBSERVED.
- PRESERVATION OF LAST STANDING MOLAR IF POSSIBLE.
- IRRIGATION WITH LIPOSOMAL AMPHOTERICIN-B SOLUTION.
- NASAL PACK INFUSED WITH LIPOSOMAL AMPHOTERICIN-B CREAM.
- HISTOPATH. SPECIMEN IN 10% FORMALIN AND SALINE SPECIMEN FOR KOH MOUNT.

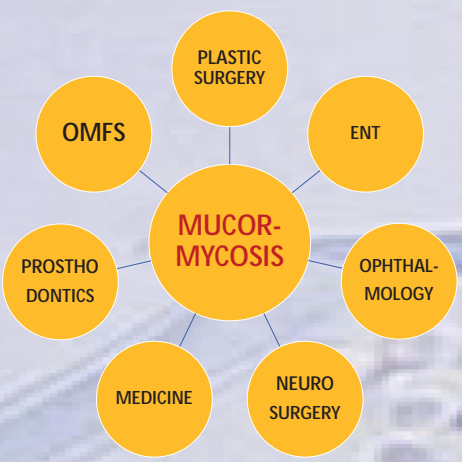
REHABILITATION

PROSTHETIC

MICROVASCULAR

ORBITAL PROSTHESIS

IMPLANTS



STATISTICS

