



THE TRANSFORMATIVE ROLE OF PATIENT-SPECIFIC IMPLANTS IN HEAD AND NECK RECONSTRUCTIVE SURGERY (Reg No. – 0764)



GUIDED BY – Prof. Dr Naresh k. Sharma (Professor IMS, BHU), Dr. Akhilesh Singh (Associate proffs IMS, BHU)

AIM: To signify role of Customized solutions in post-COVID mucor mycosis by reconstructing one's lost facial structures . To mark a transformative leap in field of Personalized Medicine that ensures optimal functionality and aesthetics

CASE 1: SINGLE UNIT PATIENT-SPECIFIC

CASE 2 : TWO UNIT PATIENT-SPECIFIC

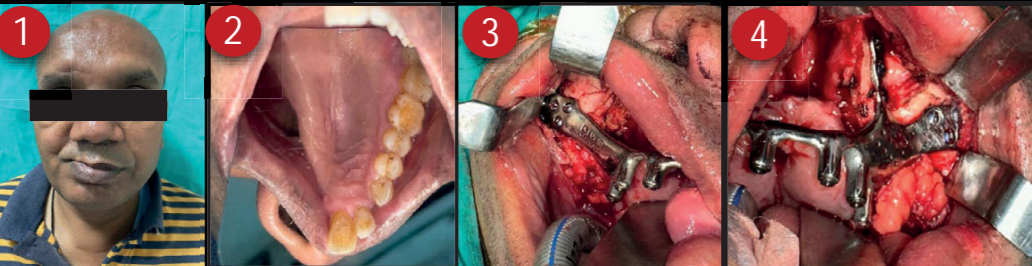


Fig (1,2,3)- Pre-operative pictures of the patient with post-covid mucormycosis showing right maxillary defect Fig (4) : Intra - op photos of the patient

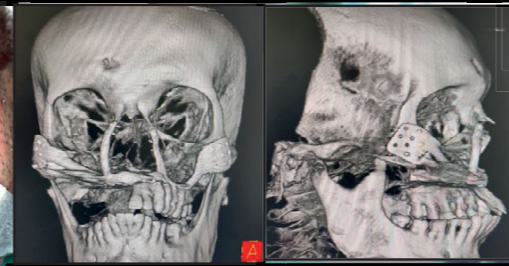

Fig (A,R) : Post operative CBCT of the patient after 2 months follow up

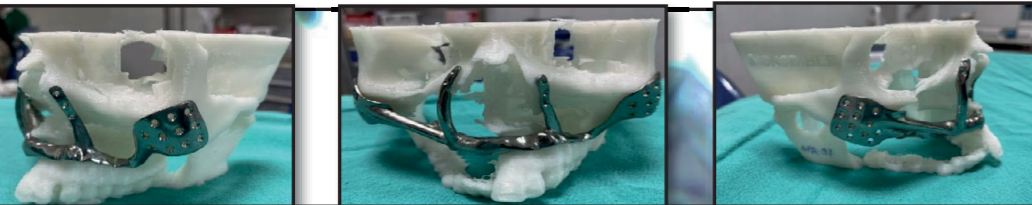
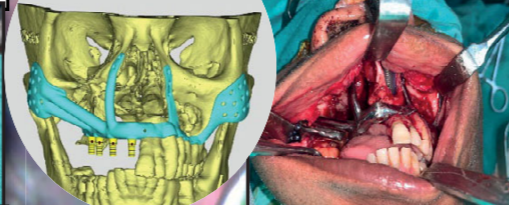
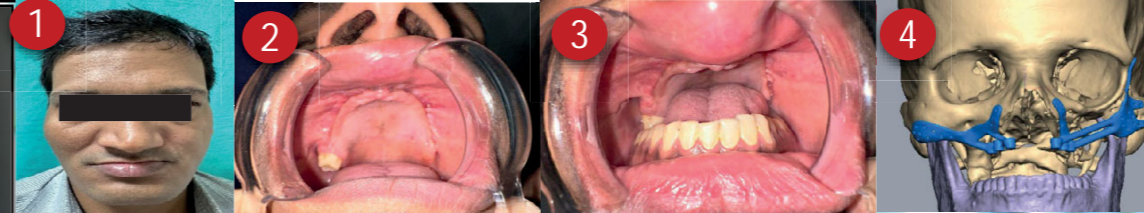


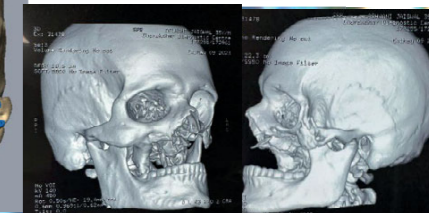
Fig (5,6,7) : Stereo lithic model of the patient fabricating using 3D printing along with the titanium PSI placed on the patient skull model.



PSI PLANNING INTRA OP PICS



PRE - OP PHOTOS (1-3) : EXTRA-ORAL AND INTRAORAL ; FIG 4 : PSI DESIGN FOR THE PATIENT



PRE-OP 3D CT

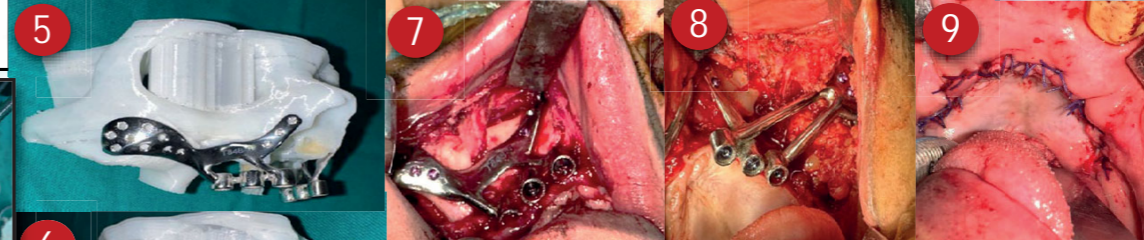
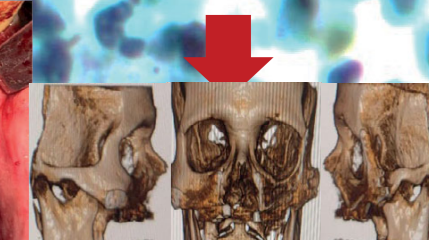


FIG 5: STEOLITHIC MODEL FIG 6 : INTRA -OP



POST-OP 3D CT

INTRODUCTION

- Mucormycosis : aggressive fungal infection
- Primarily affecting immunocompromised elderly individuals.
- COVID-19 pandemic in India, 77.6% of cases were rhino-cerebral mucormycosis.
- Key factors for COVID patients contracting Rhizopus Oryza –
 1. excessive corticosteroid use
 2. poorly managed diabetes
 3. prolonged ICU stays
 4. dialysis.

ORAL MANIFESTATION

- I. Massive tissue destruction leading to non-healing ulcers
- II. Osseous destruction
- III. Formation of oroantral communications

SURGICAL INTERVENTION

- I. Excision of necrotic bone, potentially leading to maxillectomy.
- II. Tissue and bone defects vary in complexity based on tissue loss extent.

CHALLENGES

- ✓ Rehabilitating post-COVID rhino-maxillary mucormycosis patients
- ✓ Lack of maxillary bone, including pterygoid and zygomatic bone involvement
- ✓ Adherence of nasal and sinus mucosa with palatal mucosa
- ✓ Fibrosed palatal mucosa
- ✓ Loss of lip support
- ✓ Reduced stress-bearing area
- ✓ Lack of vertical guidance
- ✓ Overclosure of the mandible

CONCLUSION

Emphasis on the transformative potential of customized solutions in treating post-COVID mucormycosis patients given by prioritizing both optimal functionality and aesthetics through patient-specific implants, these solutions offer a significant leap forward in personalized medicine.

Further research and development in biocompatible materials and 3D printing technology will allow for even more precise and adaptable implant designs, exploring cost-effective production methods can make these customized solutions more accessible to a wider range of patients.

Ultimately, the future of post-COVID mucormycosis rehabilitation lies in personalized care, empowering maxillofacial surgeons to restore not only physical function but also a sense of self-confidence and normalcy in their patients' lives.

