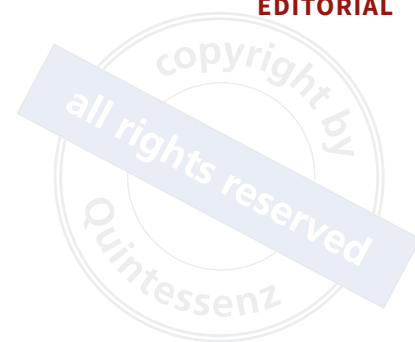



## Setting up our patients' dental implants for long-term success

Dental implant surgeons and restorative dental practitioners have several factors they can control to help improve long-term dental implant survival and provide stable peri-implant health. Several studies suggest that early marginal bone loss around an implant may be a risk factor for developing peri-implantitis in the future.<sup>1-4</sup> The goal should be to ensure there is adequate supporting bone from the start and that bone maintenance continues thereafter.

The dental implant surgeon must evaluate the bone volume that is required and available for implant placement in the planned sites. The previous recommendation of 2 mm bone surrounding a dental implant at the ridge crest was based on the circumferential horizontal loss of 1.5 mm bone around external hex implants. Several implant features are now available that can reduce this horizontal dimension of bone loss; these include platform-switching, a conical connection and tissue-level designs. Studies have shown the use of platform-switching implants is associated with less marginal bone loss compared to platform-matching implants.<sup>5</sup> A conical abutment connection was also found to show less marginal bone loss due to its superior performance in terms of forming a soft tissue seal and offering abutment stability.<sup>6</sup> Tissue-level implants have no microgap at the bone level, and stable soft tissue adhesion as no disruption occurs during fabrication of the crown or prosthesis. These features have a positive influence on marginal bone stability.<sup>7</sup> In many cases, the surgeon can also select an implant with a narrower diameter to increase the volume of surrounding bone at the neck. The dental implant surgeon should strongly consider selecting an implant with bone preserving features and employ surgical principles that may positively influence bone maintenance.

The dental implant surgeon must evaluate the soft tissue thickness in the planned implant site to


provide adequate peri-implant supracrestal tissue height for soft tissue adhesion or seal (4 to 5 mm). If the soft tissue is thin (< 4 mm), the surgeon can place the dental implant subcrestally to provide greater tissue height. Studies have shown that platform-switching implants placed in a subcrestal position reduce marginal bone loss.<sup>8</sup> In many cases, this strategy may be preferred to using a soft tissue graft to increase the tissue thickness. Depth of implant placement also influences the emergence profile and restorative contour. Placing a bone-level implant too shallow does not provide for adequate peri-implant supracrestal tissue height, resulting in an overcontoured restoration due to an acute emergence profile.<sup>9</sup> An acute emergence profile has been identified as a risk factor for increased marginal bone loss. The implant abutment height may also influence peri-implant marginal bone loss. This prosthetic factor likely correlates again with the tissue thickness. Studies have found marginal bone loss can be reduced significantly in early and late periods for bone-level implants with longer abutments (> 2 mm).<sup>10</sup> Excess cement has been identified as a potential risk factor for peri-implantitis.<sup>11</sup> As such, the restorative dental practitioner may wish to consider fabricating screw-retained restorations whenever possible and/or design custom abutments that have margins that are accessible for complete cement removal.

The width of keratinised mucosa should be assessed routinely in patients with implant restorations. Reduced keratinised mucosa width is associated with increased plaque accumulation, soft tissue inflammation, greater patient discomfort during the administration of oral hygiene, mucosal recession and marginal bone loss.<sup>12</sup> Although the impact of the amount of keratinised mucosa width (< 2 or ≥ 2 mm) as a risk factor for developing peri-implant disease remains low,<sup>13</sup> soft tissue augmentation has been associated with more favourable

peri-implant health.<sup>14</sup> Once dental implants have been loaded and are in function, an individualised supportive implant care programme should also be structured, including periodical assessment of peri-implant tissue health.<sup>15</sup> As the prognosis of peri-implantitis treatment outcomes remains relatively variable, early detection and treatment are crucial for peri-implant disease management<sup>16</sup>; however, prevention should be considered the best form of treatment.



Craig M Misch, DDS, MDS  
Editor in Chief



Maggie A Misch-Haring, DMD, MS  
Specialist in Periodontics

## References

1. Derks J, Schaller D, Håkansson J, Wennström JL, Tomasi C, Berglundh T. Peri-implantitis - Onset and pattern of progression. *J Clin Periodontol* 2016;43:383–388.
2. Windael S, Collaert B, De Buyser S, De Bruyn H, Vervaeke S. Early peri-implant bone loss as a predictor for peri-implantitis: A 10-year prospective cohort study. *Clin Implant Dent Relat Res* 2021;23:298–308.
3. Galindo-Moreno P, Catena A, Pérez-Sayáns M, Fernández-Barbero JE, O'Valle F, Padial-Molina M. Early marginal bone loss around dental implants to define success in implant dentistry: A retrospective study. *Clin Implant Dent Relat Res* 2022;24:630–642.
4. Ravidà A, Samal A, Qazi M, et al. Interproximal implant thread exposure after initial bone remodeling as a risk indicator for peri-implantitis. *J Periodontol* 2023;94:751–764.
5. Hsu YT, Lin GH, Wang HL. Effects of platform-switching on peri-implant soft and hard tissue outcomes: A systematic review and meta-analysis. *Int J Oral Maxillofac Implants* 2017;32:e9–e24.
6. Rodrigues VVM, Faé DS, Rosa CDDRD, et al. Is the clinical performance of internal conical connection better than internal non-conical connection for implant-supported restorations? A systematic review with meta-analysis of randomized controlled trials. *J Prosthodont* 2023;32:382–391.
7. Kang MH, Jung UW, Cho KS, Lee JS. Retrospective radiographic observational study of 1692 Straumann tissue-level dental implants over 10 years. II. Marginal bone stability. *Clin Implant Dent Relat Res* 2018;20:875–881.
8. Valles C, Rodríguez-Ciurana X, Clementini M, Baglivo M, Paniagua B, Nart J. Influence of subcrestal implant placement compared with equicrestal position on the peri-implant hard and soft tissues around platform-switched implants: A systematic review and meta-analysis. *Clin Oral Investig* 2018;22:555–570.
9. Saleh MH, Galli M, Siqueira R, Vera M, Wang HL, Ravidà A. The prosthetic-biologic connection and its influence on peri-implant health: An overview of the current evidence. *Int J Oral Maxillofac Implants* 2022;37:690–699.
10. Chen Z, Lin CY, Li J, Wang HL, Yu H. Influence of abutment height on peri-implant marginal bone loss: A systematic review and meta-analysis. *J Prosthet Dent* 2019;122:14–21.
11. Schwarz F, Derks J, Monje A, Wang HL. Peri-implantitis. *J Clin Periodontol* 2018;45(suppl 20):S246–S266.
12. Sanz M, Schwarz F, Herrera D, et al. Importance of keratinized mucosa around dental implants: Consensus report of group 1 of the DGI/SEPA/Osteology Workshop. *Clin Oral Implants Res* 2022;33(suppl 23):47–55.
13. Ravidà A, Arena C, Tattan M, et al. The role of keratinized mucosa width as a risk factor for peri-implant disease: A systematic review, meta-analysis, and trial sequential analysis. *Clin Implant Dent Relat Res* 2022;24:287–300.
14. Thoma DS, Naenni N, Figuero E, et al. Effects of soft tissue augmentation procedures on peri-implant health or disease: A systematic review and meta-analysis. *Clin Oral Implants Res* 2018;29(suppl 15):32–49.
15. Herrera D, Berglundh T, Schwarz F, et al. EFP workshop participants and methodological consultant. Prevention and treatment of peri-implant diseases-The EFP S3 level clinical practice guideline. *J Clin Periodontol* 2023;50(suppl 26):4–76.
16. Monje A, Insua A, Wang HL. Understanding peri-Implantitis as a plaque-associated and site-specific entity: On the local predisposing factors. *J Clin Med* 2019;8:279.