

Effect of Provisional Restorations with Ovate Pontics on Preservation of the Ridge after Tooth Extraction: Case Series

Yang YANG^{1*}, Feng Juan CUI^{2*}, Xiao Qiang LIU¹, Ting Ting PU¹, Jian Feng ZHOU¹, Jian Guo TAN¹

Objective: To evaluate the effect of provisional restorations using ovate pontics on the hard and soft tissues of the alveolar ridge after tooth extraction.

Methods: Patients with intact buccal bone after extraction of a maxillary incisor underwent a series of treatments. The protocol included tooth extraction and provisional restoration using ovate pontics. The outcomes were assessed 1, 3 and 6 months after the procedure, regarding changes in bone volume and soft tissue dimension.

Results: A total of 11 patients (6 female and 5 male) were treated using an ovate pontic provisional restoration after tooth extraction. After 6 months, bone loss at level 1, 3 and 5 mm below the most coronal section of the bone crest was 2.28 ± 0.53 mm, 1.51 ± 0.30 mm and 1.46 ± 0.41 mm, respectively. Changes in bone volume of these three levels were significantly lower ($P < 0.01$) than changes previously reported in the literature. The mesial and distal papillae recessed 0.47 ± 0.24 mm and 0.88 ± 0.57 mm, respectively, whereas the midfacial shrinkage was 0.86 ± 0.44 mm. The dimension of the ridge contour around the socket reduced mostly at 3 and 5 mm below the coronal section and the gingival mucosa, with values of 1.68 ± 0.48 mm and 1.61 ± 0.48 mm, respectively.

Conclusion: Using a provisional restoration with ovate pontics after tooth extraction may preserve the alveolar ridge by sustaining the soft tissue, in particular the gingival papilla.

Key words: ovate pontics, alveolar ridge preservation, provisional restoration, gingiva recession, bone loss

Chin J Dent Res 2019;22(3):181–188; doi: 10.3290/j.cjdr.a43112

After tooth extraction, the alveolar ridge undergoes evident reduction in both vertical and horizontal directions. The healing process of the extraction socket

and related changes of respective hard and soft tissues has become a well-investigated research field. The alveolar ridge resorption has been widely described in the literature as mainly occurring during the first 3 months after tooth extraction and involving the buccal bone wall of the socket particularly, resulting in the loss of as much as 50% of the buccal wall^{1,2}. According to the evidence reported by systematic review articles^{3,4}, the reduction of the vertical dimension on the buccal side is 1.24 mm after 6 months, whereas the reduction of the horizontal dimension is greater, of around 3.8 mm after 6 to 7 months. In addition, the interdental papilla recedes after tooth extraction. The poor aesthetic appearance due to the ‘black triangle’, especially in the maxillary anterior region, has been a concern for both patients and clinical professionals⁵. Hence, many techniques have been widely used for the alveolar ridge preservation to counteract the changes in the soft and hard tissues that occur after tooth extraction. Thus, various surgical

1 Department of Prosthodontics, Peking University School of Stomatology. National Engineering Laboratory for Digital and Material Technology of Stomatology. National Clinical Research Center for Oral Diseases. Beijing, P.R. China.

2 Department of Stomatology, The First Affiliated Hospital of University of Science and Technology of China, Division of Life Sciences and Medicine. Hefei, Anhui Province, P.R. China.

*These authors contributed equally to this work.

Corresponding authors: Prof. Jian Guo TAN and Dr Jian Feng ZHOU, Department of Prosthodontics, Peking University School of Stomatology, 22# Zhongguancun South Avenue, Haidian District, Beijing 100081, P.R. China. Tel & Fax: 86 10 82195532. Email: kqtangjg@bjmu.edu.cn; dentistzjf@163.com

The study was financial supported by National Natural Science Foundation of China (No. 81200807), Peking University School and Hospital of Stomatology (No. PKUSSNCT-12B12), and Foundation of Chinese Stomatological Association (No. CSA-R2018-01).

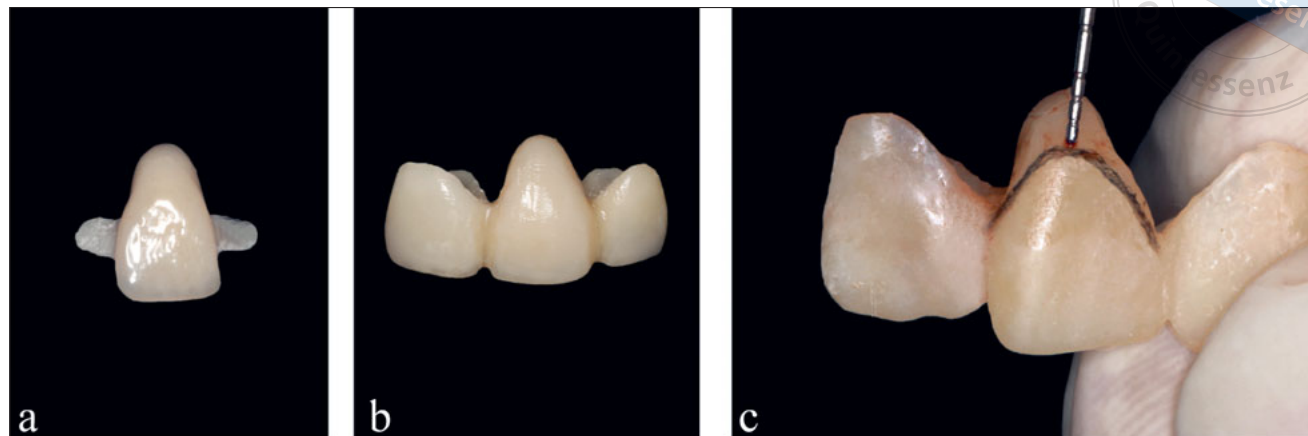


Fig 1 Provisional restorations: (a) Resin-bonded prosthesis with two wings; (b) Fixed partial denture; (c) Modified and measured length of the ontic 'sunk' into the wound.

reconstructions can be performed with different levels of risk and predictability.

The ovate pontic design was first used to maintain or enhance the soft tissue contours⁶, especially the interdental papilla of fixed partial dentures⁷. It has been suggested that using a pontic with the ideal shape and relatively smooth surface, shortly after tooth extraction, may maintain the normal height of the soft tissue, especially the height of the interdental papillae, as long as the underlying bone on the adjacent teeth are adequate⁸. This is of utmost importance, because if the height of the papilla has been lost following extraction, it can rarely be re-created. One option involves placing a provisional denture with an ovate pontic at the time of tooth extraction to provide support to the proximal papillae, the facial soft tissue, and to promote the healing of the gingival tissue⁹. However, studies assessing the changes of bone volume after tooth extraction could not be found in the literature. Therefore, it is still unknown whether the preservation of the ridge prolife provided by ovate pontics, is due to the reduced bone loss or the improved soft tissue healing. There is also lack of overall knowledge on the volume and shape of the alveolar ridge and hard and soft tissues after using a provisional restoration with ovate pontics. Hence, the objective of this study was to investigate the influence of provisional restoration with ovate pontics on the alveolar ridge after tooth extraction.

Materials and methods

Subjects

This study aimed to assess the soft tissue and bone healing process after tooth extraction during a 6-month period.

The provisional restorations (modified resin-bonded prosthesis or fixed partial denture) with ovate pontics were used for post-extractive socket preservation.

The protocol was approved by the Ethics Committee of the Peking University School and Hospital of Stomatolgy (no. PKUSSIRB-201412018). The patients enrolled in the present study were selected from patients presenting to the Department of Prosthodontics clinic at the Peking University School and Hospital of Stomatolgy, between August 2014 and November 2015. They were included in the treatment plan for maxillary anterior tooth extraction for any clinical indications. Patients were between 18 and 60 years of age. All patients signed the informed consent. Inclusion criteria were as follows:

1. Presence of a single failing tooth in maxillary central incisors;
2. Unable or unwilling to undergo an immediate post-extraction implant placement due to any reasons;
3. Ideal soft tissue level/contour at the facial aspect of the failing tooth in perfect harmony with the surrounding teeth;
4. Thick gingival biotype;
5. Willing to participate in the study and to sign the informed consent.

Exclusion criteria were as follows:

1. Systemic conditions which could impact the wound healing, like uncontrolled diabetes;
2. Irradiation therapy history in the head or neck area;
3. Pregnancy or lactation;
4. Untreated periodontitis or poor oral hygiene and motivation;
5. Addiction to alcohol or cigarettes (> 10 cigarettes/day);
6. Lack of intact facial wall after tooth extraction.

Clinical procedures

For the first visit, all patients were evaluated clinically, and their medical histories were recorded. The initial situation was recorded via photographs and impressions, which were taken using a polyether material (Impregum, 3M ESPE, Seefeld, Germany). Bone volumes were analysed using a cone beam computed tomography (CBCT) scan (Cranex 3D, Soredex, Tuusula, Finland). Before tooth-extraction surgery, provisional prostheses, such as resin-bonded prostheses or fixed partial dentures (Fig 1), were manufactured by one dental technician (Ms. Ting Ting PU) using Ceramage (Shofu Dental Products, Kyoto, Japan), which is a light-cured zirconia silicate, indirect hybrid composite resin. The selection of the resin-bonded prostheses or fixed partial dentures depended on whether adjacent teeth were defected. If one or both of adjacent teeth needed crowns, the fixed partial dentures were chosen. Otherwise, only resin-bonded prostheses with two wings were used. The pontic was designed with an oval-shape. The pontic was completely ‘sunk’ into the wound until about 3-mm depth to preserve the original emergence profile after tooth extraction.

A prophylactic antibiotic therapy was prescribed (2 g amoxicillin or 600 mg clindamycin if the patient was allergic to penicillin) for each patient, 1 h before the intervention. All surgical procedures were performed by the same experienced clinician (Dr Jian Feng ZHOU). Patients rinsed with 0.2% chlorhexidine mouthwash for 1 min prior to the intervention. For all the 11 patients, local anaesthesia was administered using articaine hydrochloride with adrenaline 1:100,000 (Orabloc, Pierrel, Milan, Italy). Teeth were removed, using a flapless approach with as minimal trauma as possible to preserve the facial alveolar bone. Sockets were then thoroughly debrided using a curette, to ensure complete removal of the granulation tissue. The facial walls were evaluated visually and using a periodontal probe, to make sure they were intact after tooth extraction. The provisional restoration was placed shortly after tooth extraction to seal the socket. Minor changes were conducted on the pontic to ensure that the length was about 3 mm into the wound, and the dimension of the pontic was suitable for the socket. After the polishing step, the provisional restoration was cemented on the adjacent tooth using TempoCemNE (DMG, Hamburg, Germany). The provisional restorations were not in contact with the opposite dentition, both in the static and dynamic occlusion.

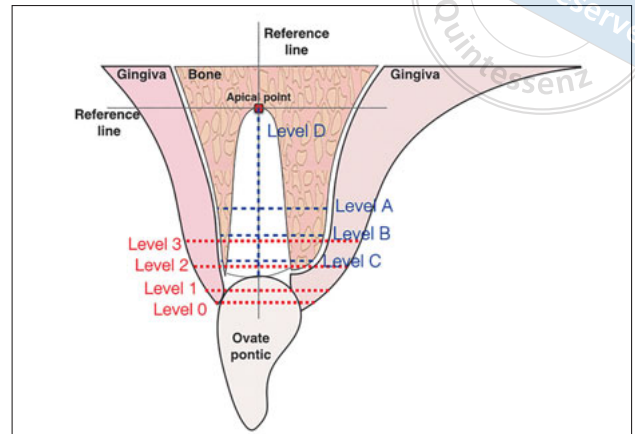


Fig 2 Vertical and horizontal volumetric change measurements of bone loss and ridge contour.

Provisional prostheses survival and complications

Patients were evaluated for provisional prostheses survival and complications 1, 3, and 6 months following the tooth-extraction surgery. Complications included biologic (abscesses and fistulas), and technical (adhesion failure of the resin-bonded prostheses, loss of retention of the crown, and fracture of prostheses).

Bone volume changes

The CBCT scans were performed before teeth extraction and 6 months after the socket preservation procedure. The data was exported as Digital Imaging and Communication in Medicine (DICOM) and analysed using the Amira software, version 5.2.1 (Visage Imaging, Carlsbad, CA, USA). A superimposition of the pre- and postoperative DICOM data was performed on the unchanged anatomical areas and manually checked for a complete match. The most apical point of the pre-extraction socket (the most apical point of the root apex) was defined in the baseline image and two reference lines were drawn subsequently. A vertical reference line was drawn in the centre of the tooth socket, crossing the apical reference point. A horizontal reference line was drawn perpendicular to the vertical line, crossing the apical reference point. The horizontal ridge width was measured at three levels, localised at 1, 3, and 5 mm below the most coronal aspect of the bone crest, parallel to the horizontal reference line, and named level A, B and C, respectively (Fig 2). The vertical dimension was also measured at the level between the buccal and lingual wall peaks, parallel to the vertical reference line, and named level D. The bone loss was calculated for each value, corresponding to the difference between pre- and postoperative measurements.

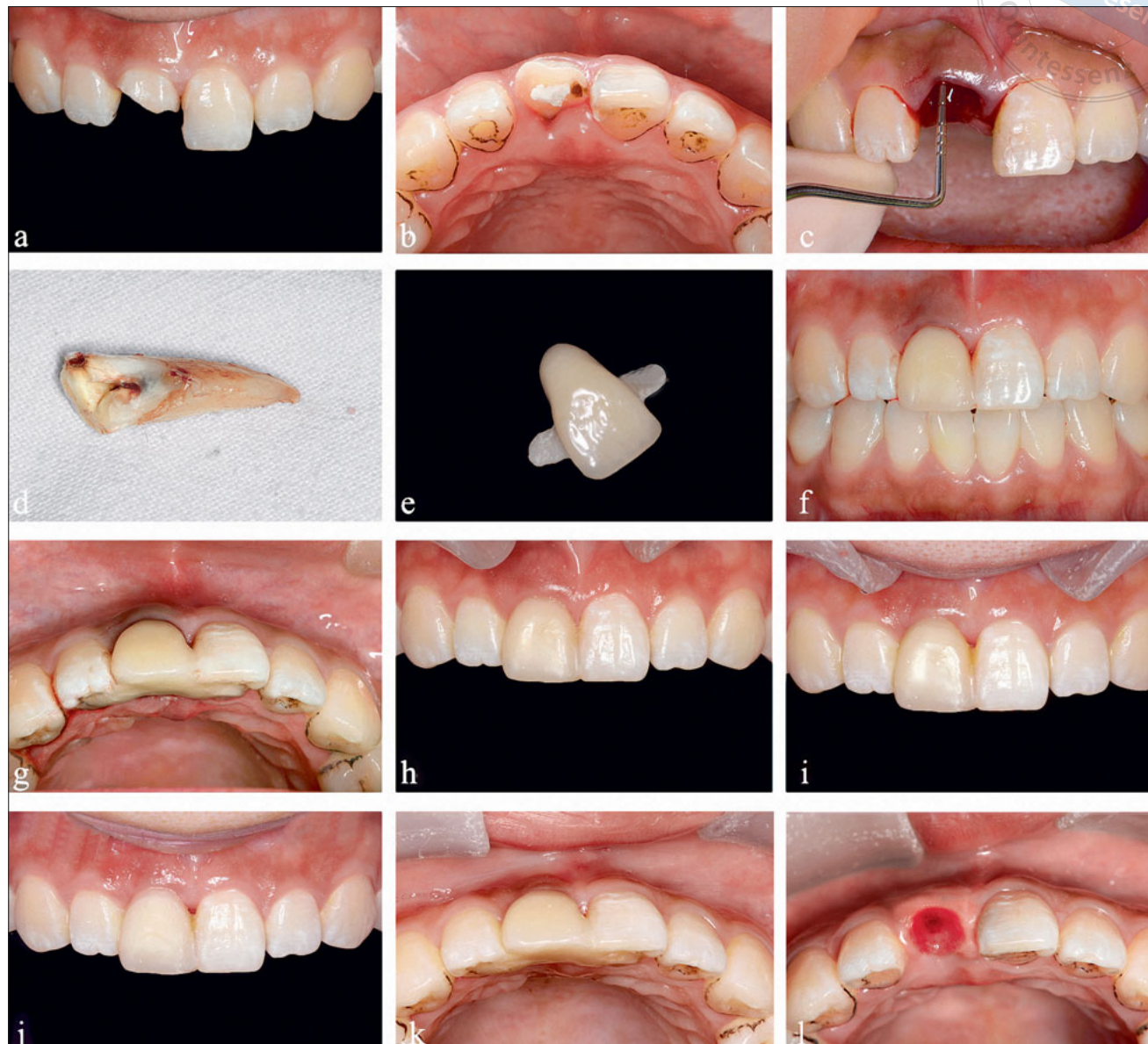
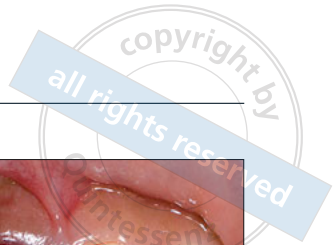


Fig 3 Treatment sequence of a representative patient: **(a)** Tooth 8 suffered a traumatic injury and root fracture; **(b)** Occlusal view of tooth 8 before treatment; **(c)** Soon after tooth extraction (note that the buccal bone was intact); **(d)** Extracted tooth; **(e)** Resin-bonded prosthesis with ovate pontics; **(f)** Provisional restoration was performed in situ after the tooth extraction; **(g)** Occlusal view of the post-extraction socket with provisional restoration; **(h)** Clinical view 1 month after tooth extraction; **(i)** Clinical view 3 months after tooth extraction; **(j)** Clinical view 6 months after tooth extraction; **(k)** Occlusal view of the ridge contour 6 months after tooth extraction; **(l)** Occlusal view of the soft tissue underneath the pontic 6 months after tooth extraction.

Soft tissue dimension changes

The soft tissue dimension was measured immediately following tooth extraction, and after 1, 3, and 6 months. Polyether impressions for each patient were taken to fabricate study casts. Subsequently, the casts were optically 3D laser scanned (D-250, 3Shape A/S, Copenhagen, Denmark). The generated 3D model data were saved as STL files and imported into the reverse engineering software (Geomagic Control 2015, Cary,

NC, USA). In addition, intraoral photographs were taken at every visit. The 3D model data and photographs were used for measurement of the soft tissue dimensions (at 1, 3, and 6 months in comparison with the preoperative status) by means of the following parameters:

1. Papilla reduction: where the top of the mesial or distal papilla level was measured on photographs using the incisal level of adjacent unrelated tooth as primary standard;

Table 1 Types of provisional restoration and complications in patients.

		Number of cases
Types of provisional restoration	Resin-bonded prostheses	9
	Fixed partial dentures	2
Complications	Mechanical complications	2
	Adhesion failure	1

Table 2 Horizontal and vertical bone volume changes (mm) after 6 months.

	Level A	Level B	Level C	Level D
mean	2.28	1.51	1.46	1.21
SD	0.53	0.30	0.41	0.26
95%CI	2.59-1.97	1.69-1.33	1.70-1.22	1.37-1.06

Table 3 Papilla reduction and midfacial recession (mean ± standard deviation, mm).

Months	Mesial papilla	Distal papilla	Midfacial
0-1	0.34 ± 0.19	0.65 ± 0.42	0.71 ± 0.32
0-3	0.45 ± 0.25	0.83 ± 0.57	0.74 ± 0.39
0-6	0.47 ± 0.24	0.88 ± 0.54	0.86 ± 0.44

Table 4 Horizontal changes in the ridge profile (mean ± standard deviation, mm).

Months	Level 0	Level 1	Level 2	Level 3
0-1	0.20 ± 0.14	0.56 ± 0.35	0.97 ± 0.39	0.80 ± 0.47
0-3	0.43 ± 0.22	0.93 ± 0.32	1.43 ± 0.50	1.31 ± 0.38
0-6	0.52 ± 0.25	1.10 ± 0.37	1.68 ± 0.48	1.61 ± 0.48

2. Midfacial recession: the midfacial mucosa level was measured on photographs using the incisal level of adjacent unrelated tooth as primary standard.
3. Ridge contour reduction: the horizontal dimension of the mucosa was measured on the 3D model data of study casts at four levels, localised at 0, 1, 3, and 5 mm below the most coronal aspect of the gingival mucosa, named level 0, 1, 2 and 3, respectively (Fig 2).

Statistical analysis

All the data analysis was performed according to a pre-established analysis plan by a clinician (Dr Feng Juan CUI) with expertise in statistics. The differences of means at patient level for continuous outcomes (horizontal and vertical ridge profile changes and bone volume changes) were tested for statistical significance

with one-way analysis of variance (post-hoc analysis using the Tukey method). Bone loss against the values in reference was compared by *t* tests. All statistical comparisons were conducted at the significance level of 0.05.

Results

A total of 11 patients (6 female and 5 male; aged between 20 to 54 years) were consecutively enrolled in the trial; eight teeth were lost because of root fracture (six caused by traumatic injury and two due to failed post and core crown restorations), and three teeth were lost because of extensive caries. Following tooth removal and provisional restoration insertion, healing for all patients was uneventful, with minimal swelling and inflammation and no signs of postoperative infection. The key clinical findings are depicted in Figure 3.

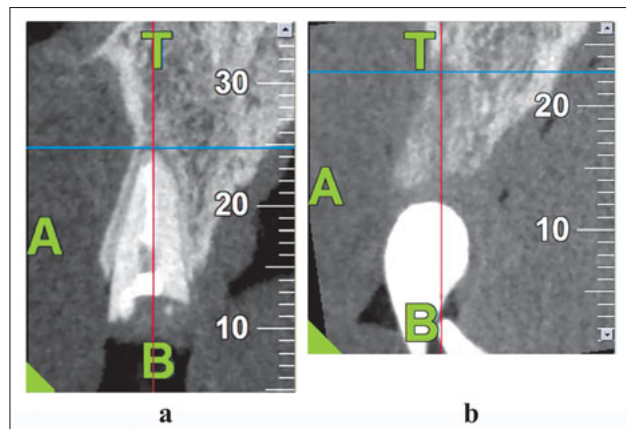



Fig 4 CBCT scans: (a) Before tooth extraction; (b) 6 months after tooth extraction with oval pontics provisional restoration.

The treatment types and complications are shown in Table 1. There were two cases of mechanical complications, which consisted both of small fractures in the wings of the resin-bonded prostheses. The fractures were fixed using flowable composite LuxaFlow (DMG, Hamburg, Germany). Only one case showed adhesion failure of the resin-bonded prosthesis. The prosthesis was recemented one day after it fell off.

The bone volume changes were evaluated on the CBCT data (see Table 2 and Fig 4). After 6 months, the greatest reduction in horizontal bone volume was 2.28 ± 0.53 mm ($P < 0.01$) in level A (1 mm below the most coronal aspect of the bone crest). In level B and C (3 mm and 5 mm below the most coronal aspect of the bone crest), the bone loss was 1.51 ± 0.30 mm and 1.46 ± 0.41 mm, respectively. All changes in bone volume in all three levels were significantly lower ($P < 0.01$) than the reference value, which was 0.38 mm. As for the vertical bone loss, the change in level D was 1.21 ± 0.26 mm. There was no significant difference compared with the reference value, which was 1.24 mm.

Table 3 depicts the papilla reduction and midfacial recession around the socket in relation to the pre-operative status. The mesial papilla remained the highest at every time point ($P < 0.05$), and there were no cases demonstrating advanced mesial papilla reduction (1 mm) at the end of the study. The distal papilla recession (0.88 ± 0.57 mm) and midfacial shrinkage (0.86 ± 0.44 mm) presented no significant difference ($P = 0.91$) after 6 months of healing. The dimensional changes of the ridge contour around the socket in relation to the preoperative status are shown in Table 4

and Figure 5. The reductions observed in level 2 and 3 in the dimensional changes of the ridge contour after 6 months were 1.68 ± 0.48 mm and 1.61 ± 0.48 mm, respectively. The contour of the soft tissue remained the same in the coronal zone (level 0 and 1).

Discussion

The present study demonstrated substantial changes in the bone loss, soft tissue recession and in the ridge profile during the healing phase following the extraction of a maxillary central incisor. Interestingly, using ovate pontics at the postextraction site preserved the alveolar ridge by sustaining the soft tissue, especially in the gingival papilla, and reduced the bone loss in the horizontal level more than the average bone loss reported by a previous systematic review³.

A previous clinical and histological study showed that the increased pressure from smooth, polished, and glazed convex pontics with excellent plaque control did not induce inflammation of the adjacent tissues¹⁰. It has also been reported that the mucosa under the ovate pontics remains healthy if dental floss is used regularly¹¹. Overall, after tooth extraction and the mechanical preparation of the extracted sites with oval pontics, there is a progressive epithelialisation of the wound that results in the formation of stratified squamous epithelium, typical of the gingival tissue¹². The time required for complete healing is variable and depends on various factors; one of which is an adequate provisional restoration material that allows plaque control and promotes the development of healthy tissue. Although bone remodelling takes several months or years to complete, the process becomes substantially slower in the late phase of healing (after 3 months)¹². In the present study, we found that the ridge contour change and gingival recession showed nearly 50% at 1 month and 85% at 3 months compared with 6 months after extraction. The papilla reduction and midfacial recession remained the same during the 3 to 6 months observation period.

During the healing process, the soft tissue migrates into the extraction socket, accompanied by a modulation of the crestal bone¹². This is why the sharp coronal bone edges of the extraction wound are rounded off, which leads to vertical height loss of the alveolar bone. Moreover, the alveolar bone is narrowed in the horizontal direction, especially in the buccal plate, which is made up of bundle bone¹³. This may be partially due to scar contraction that occurs during soft tissue healing over this region. Using provisional restoration with ovate pontics after tooth extraction, quickly provides an optimum sealing of the wound⁸. The subgingival length

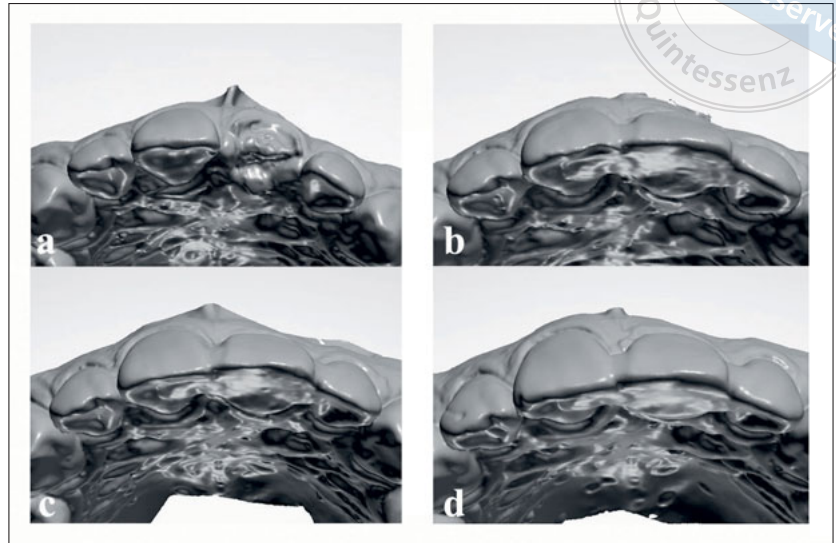


Fig 5 Occlusal view of model scans: (a) Tooth extraction, (b) 1 month after tooth extraction using oval pontics as provisional restoration; (c) 3 months after using provisional restoration; (d) 6 months after using provisional restoration.

of the pontic was about 3 mm. The distance from the gingival margin to the crest of the bone was nearly 3 to 4 mm, measured by a periodontal probe soon after the tooth extraction. Therefore, the pontic located right above the socket fully sustained the soft tissue. We also assumed that the pontic prevented the contraction of the soft tissue during healing. In the present study, the reduction of the ridge profile in level 0 and 1 (where the pontic provided support) was 0.5 to 1 mm, respectively.

Previous animal studies suggested that distributing or reducing mechanical stress in the region can improve blood flow and reduce the alveolar ridge resorption^{14,15}. In a randomised controlled trial, after tooth extraction with socket preservation using an epithelial connective tissue graft and porcine collagen matrix, the vertical bone loss was nearly 1.47 mm and 1.60 mm, respectively, after 5 months¹⁶. Given the above results, we suggest the following bold hypothesis: that the lack of pressure on the contracted gingiva may reduce the resorption of the facial bundle bone; however, this hypothesis still requires further studies to be confirmed.

The area where the ridge contour reduced the most – level 2 and 3 (3 to 5 mm below the most coronal aspect of the gingival mucosa) – was consistent with the most horizontal area of bone loss (level A: the most coronal level of the bone measurement), which was still the sharp edge of the bundle bone. In this area, the horizontal bone loss was 2.28 ± 0.53 mm, while the whole ridge contour changed nearly 1.6 mm, which was lower than the former. Furthermore, the papilla reduction and midfacial recession after 6 months were also lower compared with the vertical bone loss (1.21 ± 0.26 mm).

This indicates an increase on the volume of soft tissue during the healing process; thus, the ovate pontic not only provided support to the soft tissue but also enhanced gingival healing. The controlled pressure provided by the pontic has been shown to enhance the interdental papilla and creates the illusion of the pontic emerging from the soft tissue, thus, providing a natural look^{17,18}.

Although all the patients in our study showed optimum postoperative results, the inclusion and exclusion criteria were very important. The patients that were enrolled in the study belonged to the thick gingival biotype and had an intact facial wall after tooth extraction. It has been previously reported that sites with thicker tissues preoperatively have a lesser bone loss and better ridge profile compared with thinner tissues after tooth extraction and dental implant placement, especially in the aesthetic zone^{19,20}. Furthermore, only patients with intact facial bone after tooth extraction, who were also unable and unwilling to perform an immediate implant, were enrolled in this study. It has been suggested that if more than 50% of the bone is missing, the standard open-flap ridge preservation/ augmentation (hard-tissue preservation) may be performed using current guided bone regeneration procedures²¹⁻²³.

To the best of our knowledge, this is one of the few studies²⁴ reporting an overall assessment of the dimension and shape of the alveolar ridge, and hard and soft tissues, after using a provisional restoration with ovate pontics. Despite the absence of a control group in the present study, the results were compared with the previous findings reported by a systematic review³, which is considered to contain the average values for bone loss.

Furthermore, the patients that were enrolled here were all favourable cases, having the buccal bone intact and thick biotype; this may also decrease the reliability of the results.

Despite the limitations of this clinical study, we were able to draw as a conclusion that using provisional restoration with ovate pontics shortly after tooth extraction has a positive effect in the alveolar ridge preservation. The ovate pontics sustained the soft tissue around the post-extraction site, especially in the gingival papilla, and thus, may play a role in reducing bone loss. Implementing this technique into clinical practice has the potential to provide the dental professionals with effective means to promote improved gingival aesthetics. Nevertheless, further studies are required to provide an evidence-based conclusion.

Acknowledgements

The authors thank Dr Mu Qing LIU (Department of Radiology, Peking University School of Stomatology) for his help with the CBCT scan, and Ms. Yi Jiao ZHAO and Mr. Guan Bo WANG (National Engineering Laboratory for Digital and Material Technology of Stomatology) for their assistance with the model scan and analysis.

Conflicts of interest

The authors reported no conflicts of interest related to this study.

Author contribution

Drs Yang YANG, Feng Juan CUI, Ting Ting PU and Jian Feng ZHOU, performed the clinical treatments; Drs Yang YANG, Feng Juan CUI and Xiao Qiang LIU collected the data and wrote the manuscript; Drs Jian Feng ZHOU and Jian Guo TAN revised the manuscript.

(Received Feb 15, 2019; accepted May 16, 2019)

References

1. Van der Weijden F, Dell'Acqua F, Slot DE. Alveolar bone dimensional changes of post-extraction sockets in humans: a systematic review. *J Clin Periodontol* 2009;36:1048–1058.
2. Zhao JH, Chang YC. Alveolar ridge preservation following tooth extraction using platelet-rich fibrin as the sole grafting material. *J Dent Sci* 2016;11:345–347.
3. Tan WL, Wong TL, Wong MC, Lang NP. A systematic review of post-extraction alveolar hard and soft tissue dimensional changes in humans. *Clin Oral Implants Res* 2012;23 Suppl 5:1–21.
4. Hämmerle CH, Araújo MG, Simion M, Osteology Consensus Group 2011. Evidence-based knowledge on the biology and treatment of extraction sockets. *Clin Oral Implants Res* 2012;23 Suppl 5:80–82.
5. Carnio J, Carnio AT. Papilla reconstruction: Interdisciplinary consideration for clinical success. *J Esthet Restor Dent* 2018;30:484–491.
6. Dylina TJ. Contour determination for ovate pontics. *J Prosthet Dent* 1999;82:136–142.
7. Korman RP. Enhancing esthetics with a fixed prosthesis utilizing an innovative pontic design and periodontal plastic surgery. *J Esthet Restor Dent* 2015;27:13–28.
8. Spear FM. Maintenance of the interdental papilla following anterior tooth removal. *Pract Periodontics Aesthet Dent* 1999;11:21–28, 30.
9. Taleghani M, Roshan S, Baker FL, Denson PS, Herrman AB. Nonsurgical management of interdental papillae loss following extraction of anterior teeth. *Gen Dent* 2008;56:326–331.
10. Tripodakis AP, Constandinides A. Tissue response under hyperpressure from Convex pontics. *Int J Periodontics Restorative Dent* 1990;10:408–414.
11. Zitzmann NU, Marinello CP, Berglundh T. The ovate pontic design: a histologic observation in humans. *J Prosthet Dent* 2002;88:375–380.
12. Araújo MG, Silva CO, Misawa M, Sukekava F. Alveolar socket healing: what can we learn? *Periodontol* 2000 2015;68:122–134.
13. Araújo MG, Sukekava F, Wennström JL, Lindhe J. Ridge alterations following implant placement in fresh extraction sockets: an experimental study in the dog. *J Clin Periodontol* 2005;32:645–652.
14. Maruo Y, Nishigawa G, Irie M, et al. Stress distribution prevents ischaemia and bone resorption in residual ridge. *Arch Oral Biol* 2010;55:873–878.
15. Yoshino H, Morita I, Murota SI, Ishikawa I. Mechanical stress induces production of angiogenic regulators in cultured human gingival and periodontal ligament fibroblasts. *J Periodontol Res* 2003;38:405–410.
16. Meloni SM, Tallarico M, Lolli FM, Deledda A, Pisano M, Jovanovic SA. Postextraction socket preservation using epithelial connective tissue graft vs porcine collagen matrix. 1-year results of a randomised controlled trial. *Eur J Oral Implantol* 2015;8:39–48.
17. Kim TH, Cascione D, Knezevic A. Simulated tissue using a unique pontic design: a clinical report. *J Prosthet Dent* 2009;102:205–210.
18. Fradeani M. Esthetic rehabilitation in fixed prosthodontics. Volume 1: Esthetic analysis: a systemic approach to prosthetic treatment. p425–430, Quintessence Publishing, 2009.
19. Bhat PR, Thakur SL, Kulkarni SS. The influence of soft tissue biotype on the marginal bone changes around dental implants: A 1-year prospective clinico-radiological study. *J Indian Soc Periodontol* 2015;19:640–644.
20. Akcalı A, Trullenque-Eriksson A, Sun C, Petrie A, Nibali L, Donos N. What is the effect of soft tissue thickness on crestal bone loss around dental implants? A systematic review. *Clin Oral Implants Res* 2017;28:1046–1053.
21. Jung RE, Ioannidis A, Hämmerle CHF, Thoma DS. Alveolar ridge preservation in the esthetic zone. *Periodontol* 2000 2018;77:165–175.
22. Brandam L, Malmstrom H, Javed F, Calvo-Guirado JL, Romanos GE. Ridge preservation techniques in the anterior esthetic zone. *Implant Dent* 2015;24:699–712.
23. Lee AMH, Poon CY. The clinical effectiveness of alveolar ridge preservation in the maxillary anterior esthetic zone – A retrospective study. *J Esthet Restor Dent* 2017;29:137–145.
24. Pozzi A, Tallarico M, Moy PK. The implant biologic pontic designed interface: description of the technique and cone-beam computed tomography evaluation. *Clin Implant Dent Relat Res* 2015;17 Suppl 2:e711–720.