



Sebastian Bürklein, Edgar Schäfer

Human Immunodeficiency Virus (HIV) and endodontics: a review



Edgar Schäfer
Department of Operative
Dentistry,
University of Münster,
Waldeyerstr. 30,
D-48149 Münster,
Germany
Tel: +49 251 8347040
Email: eschaef@uni-muen-
ster.de

Sebastian Bürklein
Private Practice,
Münster,
Germany

Key words *AIDS, CD4 cell count, HAART, infection control, Kaposi's sarcoma, prophylactic antibiotic treatment, treatment outcome*

Due to the introduction of highly active antiretroviral therapy (HAART), HIV infection has gradually become more of a chronic immunodeficiency disease. In response to HAART, the CD4 cell count, in most cases, increases and thereby the HIV-infected patients are at a lower risk of developing opportunistic infections; this leads to an enhanced quality of life and a reduced mortality. Therefore, nowadays, the endodontist is more likely to encounter an HIV-infected patient in need of endodontic treatment. Unfortunately there is a lack of guidelines for the treatment of HIV-infected or AIDS patients. The intention of this overview is to evaluate current knowledge regarding endodontic treatment and its outcome in HIV-infected patients.

■ Introduction

Worldwide more than 40 million people are infected with the human immunodeficiency virus (HIV). Annual new infections are estimated to be 4.9 million, and annual deaths 3.1 million. Since the first description of this disease to the year 2004, a total of approximately 27.1 million people died from AIDS (acquired immunodeficiency syndrome). In West and Central Europe, the number amounts to 720,000 HIV-infected people, which corresponds to a prevalence of about 0.3% HIV-infected adults. For a long time the number of new infections remained at a constant level or was even slightly decreasing. However, in 2005 the Robert-Koch institute reported a substantial increase in infection of about 20% compared with previous years. The clear indication is that it is prudent not to play down the risk of HIV infection and the importance of HIV. With the opening of

global markets and the eastward enlargement of the European Union, East European and central Asian states must also be included in the statistics. The estimated numbers will rise. The estimated increase is approximately 2.32 million HIV-infected adults with a prevalence of around 1%^{1,2}.

In 1981 the clinical appearance of AIDS was first described by Gottlieb as an unusual accumulation of rare and often fatal running illness of previously healthy young homosexual men in the USA. A combination of *Pneumocystis jiroveci* infections and Kaposi's sarcoma (Figs 1a and 1b) were observed, a clinical picture that up to that time was associated only with immunocompromised patients. Therefore even at that early stage an acquired immunodeficiency disease was considered to be the most probable cause. The lymphadenopathy virus (LAV), which was thought to be the perpetrator of AIDS, was isolated in 1983 by a French group led by Luc Montagnier.

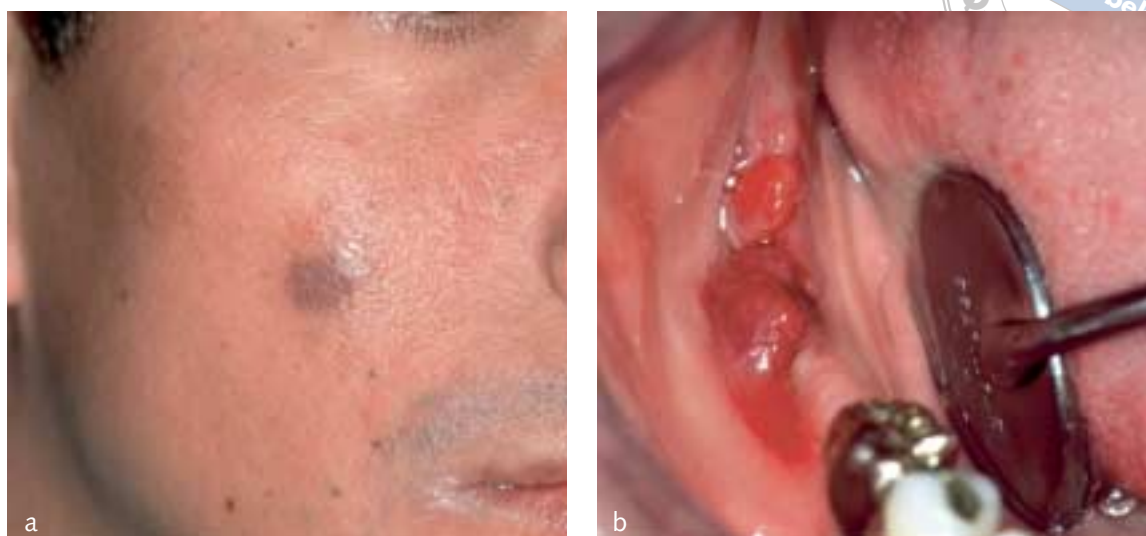


Fig 1 Patient with a Kaposi's sarcoma, both a) extraoral, on the skin of the cheek, and b) intraoral, visible in the distal region of the right mandible.

From 1985, a test for the detection of the LAV virus was available. A year later, the virus was named HIV. Nowadays, two different types of viruses (HIV I and HIV II) are recognised, with many subtypes depending on regional locality.

In the first decade of the HIV epidemic, HIV infection and AIDS were described as a disease with a fulminant course leading in most cases to rapid death. At that time, HIV-infected patients were considered to be at a higher risk of developing opportunistic infections than medically healthy patients. In the last 10 years this has changed dramatically. Since the introduction of highly active antiretroviral therapy (HAART), HIV infection has gradually become more of a chronic immunodeficiency disease. In response to HAART, the CD4 cell count in most cases increases and thereby the HIV-infected patients are at lower risk for developing the above-mentioned infections. On the whole, remarkable advances have

been made in improving the immune status of HIV-infected patients, leading to an enhanced quality of life and an improved lifespan³.

■ Pathogenesis of HIV infection

In the case of the first infection, an acute HIV syndrome develops, corresponding symptomatically to influenza. This stage can last up to three weeks. There is an initial rise of plasma viral load with a corresponding reduction of the number of CD4 lymphocytes⁴. A humoral immunity response does not occur⁵, which is why a negative antibody result is possible up to six weeks after the infection⁶. This asymptomatic stage can be followed by symptoms and are assigned to the clinical group B (Table 1)⁷. The symptoms are due to a possible disorder of the cellular defence, which is normally associated with

Table 1 Classification of HIV infection as proposed by the American Centers for Disease Control and Prevention.

Category	CD4 cell count (cells/ μ l)	Clinical symptoms
A	A1: ≥ 500 A2: 200–499 A3: < 200	<ul style="list-style-type: none"> symptomatic HIV-infection, or persisting generalised lymphadenopathy, or acute, primary HIV-infection without presence of AIDS-defining diseases.
B	B1: ≥ 500 B2: 200–499 B3: < 200	<ul style="list-style-type: none"> ARC-symptoms (e.g. oral candidiasis) without AIDS-defining diseases [ARC = AIDS-related complex; a suspicion of a clinical picture justifying AIDS]
C	C1: ≥ 500 C2: 200–499 C3: < 200	<ul style="list-style-type: none"> AIDS-defining diseases: e.g. candidiasis of the oesophagus, the trachea, respiratory tract, and the lungs, Kaposi's sarcoma, repeated pneumonia (>1 within 12 months), repeated salmonella septicaemia, <i>Pneumocystis jiroveci</i> pneumonia, lymphoma



a secondary rise in the virus load and the continuous reduction of the CD4 cells, combined with a change for the worse in the CD4/CD8-ratio. In severe immune defect cases, the CD4 cell count is below 200 cells/mm³; in patients with substantially suppressed immune systems, the occurrence of AIDS-related diseases, leading to mortality after differing times, must be expected in the worst case⁷.

HIV is an RNA virus and possesses a reverse transcriptase that processes the RNA genome into complementary DNA. The virus has receptors for T lymphocytes, the primary cells to be infected. The virus attaches via the protein gp120 onto a specific membrane protein of the host cell, the so-called CD4 protein. After the decomposition of the nucleocapsids, the viral RNA is rewritten in DNA and finally integrated into the DNA of the host organism. Once the virus establishes itself intracellularly, infected cells can then attach to other cells and the virus can then be transferred from cell to cell. The resultant viral structure and enzyme proteins are assembled together with the RNA to form new viruses and released. The infected CD4 lymphocytes become inactive after weeks to months; however, this is not the case for the macrophages as they act as a kind of reservoir⁸. The affected CD4 cells (T lymphocytes, epidermal Langerhans' cells and macrophages) represent important control elements in the immune defence. If HIV reaches the body, it evokes a marked defence reaction; however, the antibodies formed on this occasion are not able to eliminate the virus. A small number of the affected T helper cells will be destroyed directly by the virus. Furthermore, indirect attack mechanisms can lead to restricted and misguided controlled defence reactions and will thereby reduce significantly the number of the T4 helper cells. That is the reason why otherwise harmless infections, so-called opportunistic infections, can be life-threatening⁹.

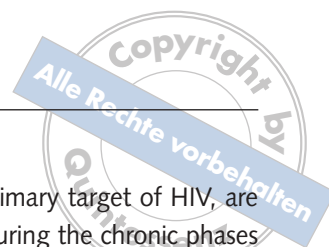
HIV infection is classified according to the CDC classification, proposed by the American Centers for Disease Control and Prevention, and was last revised in 1993. The classification is based on three different categories depending on the clinical picture of the disease (A-C) and categorised according to the status of the CD4 T helper cells^{1,2,4}.

■ HIV and endodontics

Until now, there has been only limited information available about the pathology and clinical progress of an existing apical periodontitis or the prognosis of endodontic treatment in HIV-infected patients. The results of immunohistological studies, case reports and basic immunological principles suggest that, in general, endodontic treatment of apical periodontitis would have a poorer prognosis in immunocompromised patients, such as HIV-infected patients. It is well known that T cells play an important role in the pathogenesis, as well as healing, of apical periodontitis¹⁰⁻¹².

Even if treatment of HIV-infected patients is only palliative or to avoid root canal treatment in molars^{13,14}, the principles of standard root canal treatment are applicable to HIV-infected patients, or those with AIDS. The necessity for antibiotic prophylaxis before endodontic treatment is still a matter of debate^{14,15}, in particular with regard to possible post-operative complications¹⁶. Unfortunately, evidence-based recommendations from clinical trials on this question have been absent until now. The following recommendations are based on current knowledge¹⁷⁻²⁰:

- During endodontic treatment, prophylactic antibiotic therapy is not indicated for patients assigned to categories A and B (Table 1) as long as the granulocytes count is less than 500 cells/ μ l of blood.
- If the granulocytes count ranges above 500 cells/ μ l of blood, endodontic treatment should be performed under prophylactic antibiotic cover.
- The indication for the root canal treatment or the alternative of an extraction with patients with AIDS-defining diseases belonging to category C (Table 1) should be carefully evaluated with respect to the general health of the patient and their immune resistance. In this case, antibiotic prophylaxis should be obligatory prior to treatment. The advice of the patient's general medical practitioner or haematologist should be sought prior to dental treatment. The assessment should focus on the seriousness of the patient's immune suppression and the state of the thrombocytes.
- Patients with CD4 cell counts below 200 cells/ μ l, those in categories A3, B3 and C3 (Table 1), might suffer from a disorder of blood coagulation due a thrombocytopenia. If the thrombocyte



count is more than 60,000 cells/mm³, routine dental treatment is normally allowable without the risk of massive secondary haemorrhage. Infiltration and/or intraligamentary anaesthesia is preferred in order to avoid complications associated with mandibular or maxillary block anaesthesia. If the thrombocyte count is below 60,000 cells/mm³ a specialist should be consulted before planning dental treatment, or, if necessary, the patient should be referred to a specialist.

- Antimicrobial mouthrinses two to three days before planned dental treatment is recommended (e.g. chlorhexidine) in order to achieve a significant reduction of oral microorganisms and thereby reduce the risk of post-operative complications.

Shortly after the discovery of AIDS, only a few case reports could be found in the literature, but now many more, including retrospective studies, have been published. Nevertheless, there are still several unanswered questions on HIV and endodontic treatment. Dental practitioners are left to decide how best to treat an HIV-infected patient. There is still scarcity of data on the clinical progression of apical periodontitis or the prognosis of endodontic treatment in patients with HIV. The current knowledge of endodontic treatment of patients suffering from HIV infection is discussed below (Table 2).

Histological studies of HIV patients have revealed high concentrations of proviral HIV DNA present in pulp tissue. This has important implications with regard to infection control in the dental practice²¹. Moreover, HIV can also be found in the granuloma in chronic apical periodontitis²². From the findings of further histological studies it is known that in the early phases of apical periodontitis, CD4 cells, which

are at the same time the primary target of HIV, are predominant. In contrast, during the chronic phases CD8 cells are predominant, while simultaneously CD4 cells gradually decrease in number. CD8 cells are, in comparison to the CD4 cells, relatively unaffected by HIV²³⁻²⁵. Observations from several case reports, including a report by Gerner et al²², have suggested that the observed delayed healing of apical periodontitis after endodontic treatment of HIV-infected patients may be due to a relative lack of T helper cells. Since CD4 T cells play an important role in activating B cells, macrophages and other T cells, it would be reasonable to assume that patients with low counts of these cells may have a compromised local immune function and thus show an ineffective immunological defence against residual microorganisms in the root canal system²⁶. On the other hand, Gerner et al²² reported that root canal treatments of all teeth with vital pulps were performed successfully.

In 1993, a retrospective study on conventional root canal treatment in patients with HIV infection was published²⁰. However, the observation period in this study was quite short, only three months (Table 2). Moreover, the criteria for success were not very well described; success was defined as a lack of clinical signs of apical disease at the one- and three-month follow-up visits. The immediate post-operative complication rate was exceedingly low in both the HIV-positive and the control groups. There is no significant difference in post-operative complications between HIV-infected and healthy patients. The authors concluded that as far as short-term success rates are concerned, root canal therapy can be carried out on HIV-infected patients using standard procedures without the need for antibiotic prophylaxis. Nevertheless, due to limitations including possible

Table 2 Summary of retrospective studies evaluating the outcome of nonsurgical root canal treatment in HIV-positive patients.

Study	Observation period	Evaluation criteria	Number of HIV-infected patients	Control: number of healthy patients	Success: HIV-infected patients	Success: healthy patients	Remarks
Cooper ²⁰	1-3 months	Lack of complications	32; 40 teeth	16; 17 teeth	97.9%	100%	No statistical analysis
Quesnell et al ²⁶	1 year	Radiographs; improvement of PAI score	33	33	87.9%	87.9%	No statistically significant difference
Suchina et al ²⁷	6 months to 6 years; mean 26 months	Clinical examination; radiographs	54; 60 teeth	No control group	Clinically: 88%; Radiographically: 80%		CD4 cell count had no effect on outcome



bias in design, the study is of limited value^{23,25}. Moreover, this study was performed before the clinical availability of new combinations of HAART and of viral load assessment. This might be of importance when interpreting the study results because patients receiving highly active therapy may be better protected against post-operative complications¹⁶.

Recently, two studies have been published that may prove more helpful for the evaluation of treatment outcome in HIV-positive patients (Table 2)^{26,28}. In the first investigation, a retrospective study was carried out, comparing periapical healing between 33 HIV-positive and 33 HIV-negative patients one year after root canal treatment of teeth with infected pulps and chronic apical periodontitis²⁶. No patients were diabetic or immunocompromised. The CD4 counts of the HIV-infected patients were near normal. The primary inclusion criterion was the presence of radiographically observable apical periodontitis with a minimum lesion size of 2x2 mm associated in a non-vital tooth. All the pre-operative radiographs were scored by three experienced endodontists using the periapical index (PAI)²⁷. All root canal treatments were performed in at least two visits, and calcium hydroxide was placed as an intracanal dressing. No prophylactic antibiotic was prescribed. Follow-up radiographs were taken 12 months after root canal obturation and again scored by three endodontists using PAI. The mean change of PAI was used to assess the degree of healing and was statistically analysed and compared between the two groups. There was no statistically significant difference between the two groups with regard to periapical healing (Table 2). The authors concluded that nonsurgical root canal treatment of HIV-positive patients has the same prognosis as that of medically healthy patients and that there is no need for clinicians to alter their standard endodontic treatment procedure; the prognosis of root canal treatment with HIV-infected patients is not reduced²⁶.

In another retrospective study, the long-term outcome over a six-year period, with a minimum of six months follow-up of nonsurgical root canal treatment in HIV-positive patients was evaluated (Table 2)²⁸. The endodontic treatment was assessed with 60 teeth from 54 patients; all of the patients were HIV-positive, with 12 carrying the diagnosis AIDS. Root canal treatment was performed on 26 anterior and

34 posterior teeth (32 without and 22 with periapical lesions), and was evaluated clinically (palpation, mobility, sinus tract, percussion, function, infection, swelling, occlusion, and subjective symptoms) and radiographically (periodontal ligament space, rarefaction, lamina dura, root resorption, and quality of obturation) at review. All root canal treatment was performed over several appointments and the mean follow-up time was 26 months. The CD4 cell counts were in the range of 10 to 790 cells/mm³ with a mean cell count of 240 cells/mm³. It was reported that treatment was judged a success clinically in 88%, questionable in 10%, and a failure (i.e. these patients developed an apical lesion after the therapy) in only 2% of cases. When judged radiographically, treatment was considered a success in 80%, and a failure in 5% of the cases. The results are remarkable since inadequate obturation was observed in 31% of the treated teeth. Statistically, CD4 cell count, type of tooth treated, quality of obturation, and antibiotic therapy had no significant effect on treatment. Based on these results and improved survival of HIV-infected or AIDS patients due to HAART, the authors concluded that endodontic treatment of HIV/AIDS patients with irreversible pulpal disease should be as of standard treatment²⁸.

In a retrospective review of 2477 dental procedures performed on 331 HIV-infected patients on an outpatient basis, amongst others, the rate of post-operative complications after root canal treatment was assessed²⁹. Only patients with a CD4 cell count below or equal to 200 cells/mm³ were included in this study. A total of 73 endodontic procedures were performed and in the immediate follow-up period, no post-operative complications were identified, and the overall complication rate of all dental treatment procedures was 0.9%. As the incidence of inter-appointment flare-ups in the medically healthy population is reported to be about 3.2%³⁰, this finding is somewhat surprising²⁸.

Interestingly, with HIV-positive patients who underwent routine dental care on a regular basis, approximately 36% less endodontic procedures were indicated compared with HIV-infected patients seeking only occasional dental treatment³¹. These non-regular attendees have five-times as many anterior and twice as many premolar teeth root treated when compared with regular attendees (Fig 2). Therefore a

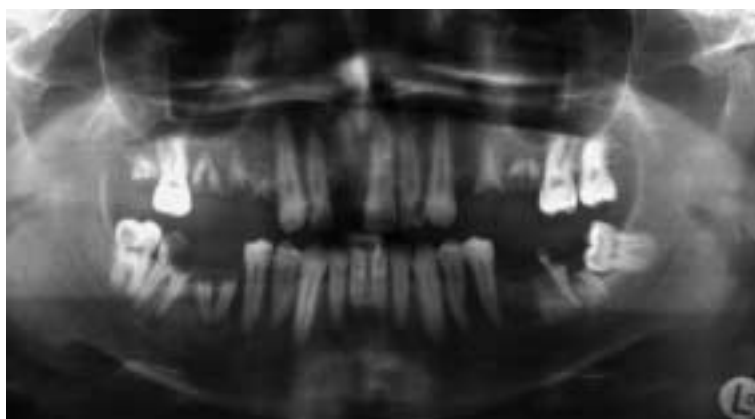
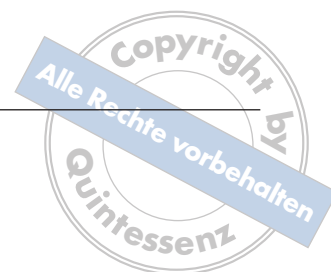

Fig 2 HIV-infected patient seeking only occasional dental treatment. Apart from destroyed and carious teeth, apical periodontitis is also visible.

recall system should be established for HIV-positive or AIDS patients in order to ensure that they receive regular dental care (Figs 3a and 3b). Fortunately, the attitude of endodontists towards HIV-infected patients has changed dramatically over the years³². In 1986, only 21% of the endodontists were willing to treat HIV-infected patients, but this had increased to 93% in 1995³². However, according to the same survey, in 1995 only 67% of the general dentists were willing to treat these patients. A dentist may not ethically refuse to treat purely because of a patient's HIV status! According to this survey, based upon patient self-reporting, less than 1% of all patients in endodontic practices were HIV-positive³². In fact, it is safe to assume that some patients are unaware of their HIV status, so the incidence of HIV-infected patients in daily practice is certainly higher than just 1%.

In summary, it can be stated that endodontic treatment must be seen as standard for HIV-infected

or AIDS patients on an outpatient basis. These patients have the same prognosis with nonsurgical root canal treatment as medically healthy patients (Figs 4a and 4b). Considerable efforts should be directed in encouraging patients to seek regular, rather than occasional, dental care.

■ HIV infection control precautions

The risk of accidental HIV transmission in dental practice is estimated to be very low. The potential for salivary transmission of HIV has been investigated in detail³³. Although HIV was found in half of the infected 83 patients in this study, in only one case was it possible to detect HIV in saliva³³. Even in this case it took three weeks of intensive culturing to isolate the virus. It seems that the virus load of saliva is very low, and at the same time saliva is known to inhibit HIV-1.

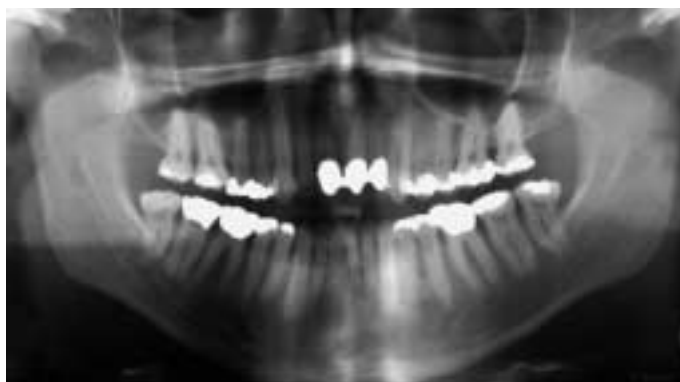

Fig 3a HIV-infected patient recalled for routine dental care. During this appointment apical periodontitis was observed radiographically with tooth 47 and mesial carious lesions in 16 and 17.

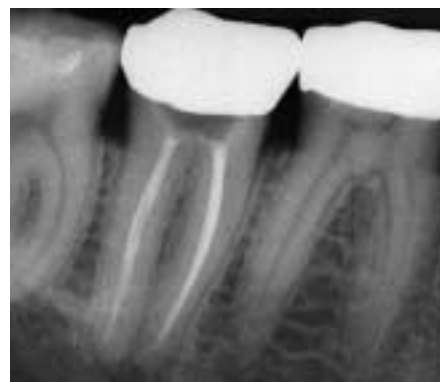

Fig 3b Tooth 47 following root canal filling.

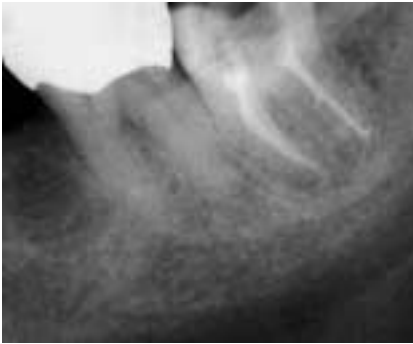

Fig 4a HIV-infected patient: post-operative radiograph showing the obturated root canals of tooth 37 which is associated with apical periodontitis.

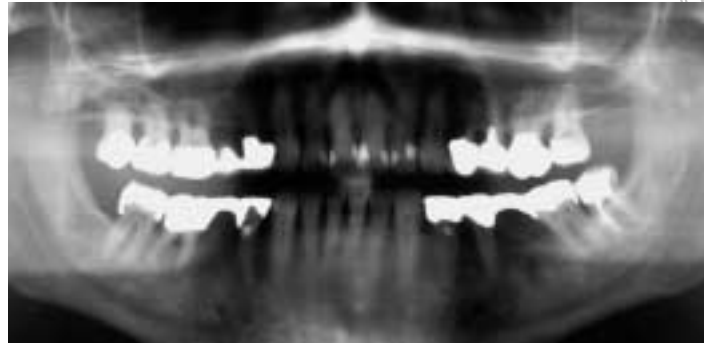


Fig 4b A 3.5 year follow-up radiograph of the root canal filling of tooth 37 showing complete apical healing. A radiographically visible apical periodontitis associated with tooth 46 was discovered and root canal re-treatment is indicated.

Another mode of transmission might be an accidental needle stick or other accidental injury (e.g. with a scalpel) with HIV-infected blood. According to several prospective studies, the risk of seroconversion after a needle stick with HIV-infected blood is approximately 0.03%^{34,35}. The risk of virus transmission after a needle stick with hepatitis B-infected blood, is approximately 6–8%³⁶ and could be as high as 50% if the patient is hepatitis Be antigen (HBeAg)-positive³³. In the case of deep-penetrating injuries with accidental exposure to HIV-infected body fluids, a prophylactic administration of a triple antiretroviral therapy regimen is advised. This should be a combination of two nucleoside reverse transcriptase inhibitors [NRTI; for instance zidovudine (also known as azidothymidine, AZT), 3TC, and abacavir] and either one protease inhibitor (e.g. lopinavir, ritonavir) or one non-nucleoside reverse transcriptase inhibitor (NNRTI, e.g. nevirapine, efavirenz)^{37,38}. Immediate referral to a specialist is highly recommendable. The usual precautions, such as not putting a used injection needle back into the sheath, and wearing gloves and goggles during the treatment, are regarded as adequate infection control precautions³⁹.

Furthermore, of utmost importance when treating HIV-infected patients is to inform all staff members of the patient's infection before the beginning of treatment to ensure vigilance. Since HIV can be found both in pulpal tissues and apical granuloma^{21,22}, the use of rubber dam is a simple and very effective measure for optimal infection control during endodontic and restorative treatment procedures and should be mandatory. Finally, with rotary root

canal instrumentation technique using nickel-titanium instruments, not only the used instruments but also the handpiece must be disinfected and sterilised after every treatment.


■ Clinical conclusions

A dentist may not ethically refuse to provide treatment purely because of a patient's HIV status.

Nonsurgical endodontic therapy in HIV-positive patients should be routine and on an outpatient basis^{16,28}. Current knowledge supports that there is no need for a routine prophylactic antibiotic treatment except for patients with a substantially suppressed immune system, those in category C (Table 1). There is some scientific evidence showing that HIV-infected patients enjoy the same prognosis with nonsurgical root canal treatment as medically healthy patients. In future, considerable efforts must be performed to improve dental prophylaxis in these patients and to encourage them to seek routine dental care on a regular basis.

■ References

1. UNAIDS. 2004 report on the global HIV/AIDS epidemic. 4th Global Report. Geneva: UNAIDS 2004.
2. UNAIDS. 2006 report on the global AIDS epidemic. May 2006. http://data.unaids.org/pub/GlobalReport/2006/2006_GR_C_H02_en.pdf
3. Hirschel B, Francioli P. Progress and problems in the fight against AIDS. *N Engl J Med* 1998;338:906-911.
4. Staszewski S, Stephan C. State of the HAART. Current strategies for antiretroviral therapy. *Internist* 2004;45: 1428-1436.



5. Gürtler L. Diagnostik der HIV-Infektion. HIV-Infektion: Pathogenese, Diagnostik und Therapie. In: Ruf B, Pohle HD, Goebel FD, L'age M (eds) Wessobrunn: SMVerlagsgesellschaft 1996.
6. Jessen H, Jäger H. Primary HIV infection. Pathology, diagnosis, management. Stuttgart: Thieme 2005.
7. Centers for Disease Control and Prevention. 1993 revised classification system for HIV infection and expanded surveillance case definition for AIDS among adolescents and adults. *J Am Med Assoc* 1993;269:729-730.
8. Dalgleish AG, Beverley PC, Clapham PR, Crawford DH, Greaves MF, Weiss RA. The CD4 (T4) antigen is an essential component of the receptor for the AIDS retrovirus. *Nature* 1985;312:763-767.
9. Deutsche AIDS-Hilfe (2004). HIV/Aids Heutiger Wissensstand. Berlin: Deutsche AIDS-Hilfe 2004.
10. Marton IJ, Kiss C. Protective and destructive immune reactions in apical periodontitis. *Oral Microbiol Immunol* 2000;15:139-150.
11. Torabinejad M, Kettering JD. Identification and relative concentration of B and T lymphocytes in human chronic periapical lesions. *J Endod* 1985;11:122-125.
12. Pulver WH, Taubman MA, Smith DJ. Immune components in human dental periapical lesions. *Arch Oral Biol* 1978;23:435-443.
13. Samaranayake LP. Oral care of the HIV infected patient. *Dent Update* 1992;19:56-58.
14. Scully C, Porter SR, Luker J. An ABC of oral health care in patients with HIV infection. *Br Dent J* 1991;170:149-150.
15. Epstein JB, Chong S, Le ND. A survey of antibiotic use in dentistry. *J Am Dent Assoc* 2000;131:1600-1609.
16. Patton LL, Shugars DA, Bonito AJ. A systematic review of complication risks for HIV-positive patients undergoing invasive dental procedures. *J Am Dent Assoc* 2002;133:195-203.
17. Little JW, Falance DA. Zahnärztliche Behandlung von Risikopatienten. Köln: Deutscher Ärzte-Verlag 1991.
18. Grassi M, Abb J, Hämmerle C. AIDS in der Zahnarztpraxis. Stuttgart: Thieme 1991.
19. Reichart PA, Gelderblom HR. Die HIV-Infektion und ihre oralen Manifestationen. Offenbach: Hoechst Marion Roussel 1998.
20. Cooper H. Root canal treatment in patients with HIV infection. *Int Endod J* 1993;26:369-371.
21. Bender IE, Hargreaves KM. The dental pulp in systemic disorders. In: Hargreaves KM, Goodis HE (ed). Selzer and Bender's dental pulp. Chicago: Quintessenz 2002; 469-492.
22. Gerner NW, Hurlen B, Dobloug J, Brandtzaeg P. Endodontic treatment and immunopathology of periapical granuloma in an AIDS patient. *Endod Dent Traumatol* 1988;4:127-131.
23. Trowbridge HO. Inflammation: a review of the process. London: Quintessence Berlin 1997.
24. Kawashima N, Okiji T, Kosaka T, Suda H. Kinetics of macrophages and lymphoid cells during the development of experimentally induced periapical lesions in rat molars: a quantitative immunohistochemical study. *J Endod* 1996;22:311-316.
25. Stashenko P, Yu SM. T helper and T suppressor cell reversal during the development of induced rat periapical lesions. *J Dent Res* 1989;68:830-834.
26. Quesnell BT, Alves M, Hawkinson RW Jr, Johnson BR, Wenckus CS, BeGole EA. The effect of human immunodeficiency virus on endodontic treatment outcome. *J Endod* 2005;31:633-636.
27. Ørstavik, D, Kerekes K, Eriksen HM. The periapical index: a scoring system for radiographic assessment of apical periodontitis. *Endod Dent Traumatol* 1986;2:20-34.
28. Suchina JA, Levine D, Flaitz CM, Hicks MJ. Retrospective clinical and radiologic evaluation of nonsurgical endodontic treatment in human immunodeficiency virus (HIV) infection. *J Contemp Dent Pract* 2006;7:1-8.
29. Glick M, Abel SN, Muzyka BC, DeLorenzo M. Dental complications after treating patients with AIDS. *J Am Dent Assoc* 1994;125:296-301.
30. Walton R, Fouad A. Endodontic interappointment flare-ups: a prospective study of incidence and related factors. *J Endod* 1992;18:172-177.
31. Hastreiter RJ, Jiang P. Do regular dental visits affect the oral health care provided to people with HIV? *J Am Dent Assoc* 2002;133:1343-1350.
32. Cohen AS, Jacobesen EL, Begole EA. National survey of endodontists and selected patient samples: infectious diseases and attitudes toward infection control. *Oral Surg Oral Med Oral Pathol Oral Radiol Endod* 1997;83:696-702.
33. Cottone JA. Hepatitis, HIV infection and AIDS: some issues or the practitioner. *Int Dent J* 1989;39:103-107.
34. Petereit G, Kirch W. Arzneimittelkommission: Berufliche HIV-Exposition und medikamentöse Postexpositionsprophylaxe. *Zahnärztl Mitt* 1997;87:72-73.
35. Marcus U. Risiken und Wege der HIV-Übertragung. Auswirkungen auf Epidemiologie und Prävention der HIV-Infektion. *Bundesgesundheitsblatt Gesundheitsforschung Gesundheitsschutz* 2000;43:449-458.
36. Schreier E, Höhne M. Hepatitis C: Epidemiologie und Prävention. *Bundesgesundheitsblatt Gesundheitsforschung Gesundheitsschutz* 2001;44:554-561.
37. Torre D, Tambini R, Speranza F. Nevirapine or efavirenz combined with two nucleoside reverse transcriptase inhibitors compared to HAART: a meta-analysis of randomized clinical trials. *HIV Clin Trials* 2001;2:113-121.
38. Oldfield V, Plosker GL. Lopinavir/Ritonavir: a review of its use in the management of HIV infection. *Drugs* 2006;66:1275-1299.
39. Guidelines of the DGZMK: Virusinfektionen in der Zahnarztpraxis. *Dtsch Zahnärztl Z* 2000;55:298-299.