



Andreas K Braun, Luc van der Sluis

The management of complications related to the mesio-buccal root canal of a maxillary first molar



Andreas K Braun
Department of Cariology
Endodontology
Paedodontology,
ACTA,
Amsterdam,
The Netherlands

Key words location, mesio-buccal root, strip perforation

In this case report, the non-surgical retreatment of a maxillary first molar is described. The management of a strip perforation is explained.

Luc van der Sluis
Department of Cariology
Endodontology
Paedodontology,
Academic Centre for
Dentistry Amsterdam
(ACTA),
Louwesweg 1,
1066 EA Amsterdam,
The Netherlands
Tel: +31 20 5188651
Fax: +31 20 6692881
Email: l.vd.sluis@acta.nl

■ Introduction

An untreated infected second mesio-buccal canal is often the cause of treatment failure. Schwarze et al¹ showed that, with the help of an operating microscope, in 93.7% of the mesio-buccal roots, a second mesio-buccal canal can be located¹. However, only in 41.3% of these cases was this canal identified using magnifying loupes (2x magnification) instead of an operating microscope, demonstrating the difficulty in locating the second mesio-buccal canal. In a recent review on the anatomy of the maxillary first molar, the incidence of two canals in the mesio-buccal root was found to be higher in the laboratory (60.5%) than in clinical studies (54.7%)². When a surgical telescope was used, the incidence of two canals was 96% in the laboratory and 71.2% in clinical studies². In a recent study, a total of 39 endodontically treated maxillary first molars were evaluated using CT scan; 30 out of these 39 mesio-buccal roots had two canals³. Of these, 27 were not filled, and 22 roots with an unfilled canal were associated with a periapical lesion³.

During a root canal treatment, the design of the access cavity is crucial in aiding canal location. Suc-

cessful treatment is impossible without an adequate access cavity. This case report demonstrates the outline of the access cavity that is needed to locate the second mesio-buccal root canal.

A strip perforation refers to an excessive thinning of the lateral root wall with possible perforation⁴. It occurs mainly in mesial-buccal roots of maxillary molars or mesial roots of mandibular molars because more root dentine is present in the mesial compared with the distal (furcal) area² (Figs 1 and 2).

In this case report, the location of a second mesio-buccal canal and management of a strip perforation is described.

■ Case report

■ Diagnosis

A 45-year-old female Caucasian was referred to an endodontist for retreatment of the first maxillary left molar (tooth 26). The tooth had been endodontically treated six years ago and the tooth was restored with

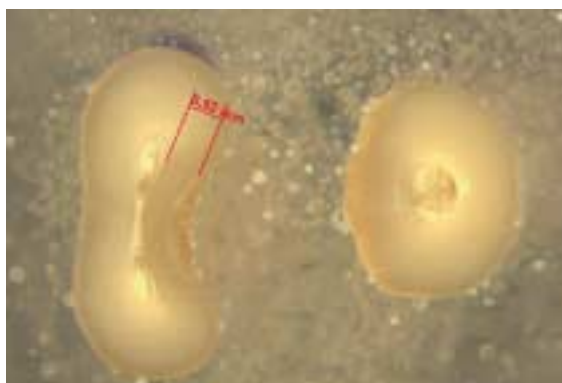


Fig 1 Cross section of the mesial root of a lower molar before preparation. Note the difference in the amount of dentine on the mesial and distal aspect of the root.

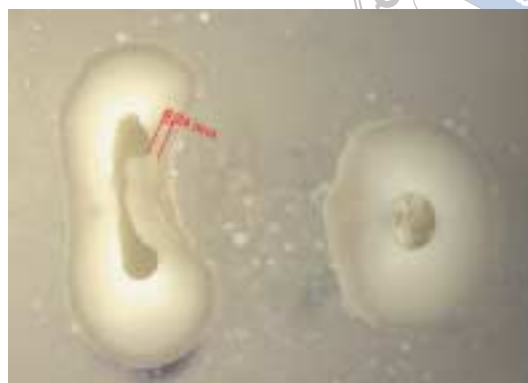

Fig 2 Cross section of the same mesial root shown in Fig 1, after preparation that caused a thinning of the distal aspect of the root.

a porcelain bonded to metal crown. At that time, the diagnosis was a symptomatic irreversible pulpitis. Three root canals had been located and chemo-mechanical preparation of these canals had been performed using rubber dam for tooth isolation. Thereafter, the patient had been free of symptoms until now.

When the patient presented herself, she was in severe pain. The tooth was sensitive to percussion. A diagnostic radiograph showed a radiolucent area around the mesio-buccal root and in the furcation area distal to the mesio-buccal root (Fig 3). It was not possible to probe the furcation. A diagnosis of symptomatic apical periodontitis was made, which might be caused by an untreated second mesio-buccal canal and a strip perforation in the mesio-buccal root.

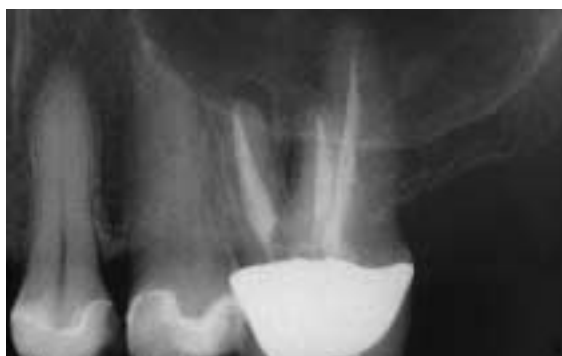

Fig 3 Diagnostic radiograph of tooth 26 before retreatment.

■ Treatment

Since only the mesio-buccal root showed signs of periapical pathology and the crown had good marginal adaptation, it was decided to only retreat the mesio-

buccal root. Local anaesthetic was administered. The tooth was isolated with rubber dam. An endodontic access cavity through the crown was made and the underlying filling material was removed until the floor of the pulp chamber was reached.

An existing perforation was located in the floor of the pulp chamber, in a straight line from the mesio-buccal to the palatal root canal (Fig 4, white arrow). The second mesio-buccal canal was located more towards the mesial aspect of the pulp chamber and was easily found after complete removal of the roof of the pulp chamber (Fig 4, black arrow, Figs 5 and 6). Following removal of the gutta-percha root filling from the mesio-buccal canal, a strip perforation was detected. The canal was not prepared because it was wide enough to allow sufficient irrigation.

The length of the two root canals was determined using an electronic apex locator (Root ZX, Morita Corp., Kyoto, Japan). Since the root canals were infected, a working length 0.5 mm short of the apical foramen was chosen⁵.

The second mesio-buccal canal was prepared with GT rotary files (Dentsply Maillefer, Ballaigues, Switzerland) in a crown-down sequence starting with size 35, taper 0.12 for the coronal flaring followed by a series of sizes 20 and 30, 0.10–0.04 taper. Between changes of instruments, the canal was irrigated with 2 ml of a 2% solution of sodium hypochlorite (NaOCl), using a syringe and a 27-gauge needle that was placed as deep as possible in the root canal but not deeper than 1 mm short of the working length. The final file (master apical file, MAF) was size 30, 0.06 taper. After preparation the root canals were filled with a 17% EDTA solution for 1 minute⁶ and thereafter irrigated with

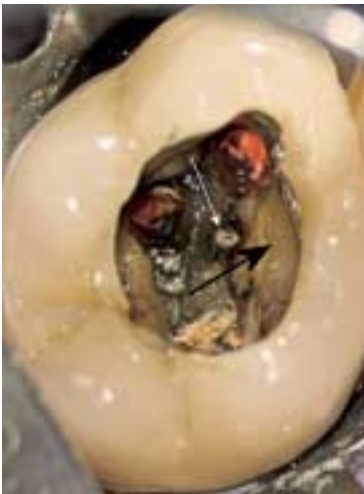

Fig 4 Existing perforation in the floor of the pulp chamber (white arrow) and the incompletely removed roof of the pulp chamber (black arrow).

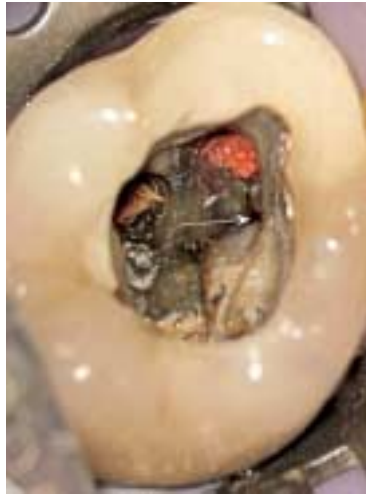

Fig 5 Second mesio-buccal canal (white arrow).

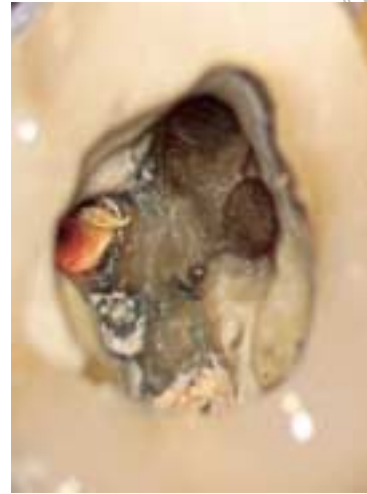


Fig 6 The prepared orifice of the second mesio-buccal canal.

a 2% solution of NaOCl using a passive ultrasonic activation for 3 minutes. No intracanal dressing with Ca(OH)₂ was used because there is no scientific evidence that this should result in a more efficient disinfection control of the root canal system or a higher success rate⁷.

The root canals were dried with paper points (Dentsply Maillefer) and filled with gutta-percha (Dentsply Maillefer) and AH 26 sealer (Dentsply De Trey, Konstanz, Germany). The apical part of this canal was filled using a cold lateral compaction technique. Both the mesio-buccal canals fused in the apical area.

The gutta-percha cones were sheared off at approximately 3 mm short of the working length with a warm spreader (System B, Sybron Endo Corp., West Collins, USA), and vertically compacted. Thereafter, the canals were filled with a warm vertical compaction technique using thermoplasticised gutta-percha (Obtura II, Spartan Corp., Fenton, USA). The first mesio-buccal canal was filled to the strip perforation. The orifice of the first mesio-buccal canal was flushed with a 2% NaOCl solution to remove remnants of AH 26 and then mineral trioxide aggregate (MTA, ProRoot, Dentsply, Konstanz, Germany) was placed on the cleaned and disinfected perforation (Fig 7). To ensure complete setting of the MTA, it was covered with a layer of calcium hydroxide (UltraCal XS, Ultradent Products Inc., South Jordan, USA) and the access cavity was temporarily filled with Cavit

(3MEspe, Seefeld, Germany) and Fuji II (Fuji GC Company, Tokyo, Japan).

A post-treatment radiograph was taken (Fig 8). The patient was referred to her own dentist for a definitive coronal restoration.

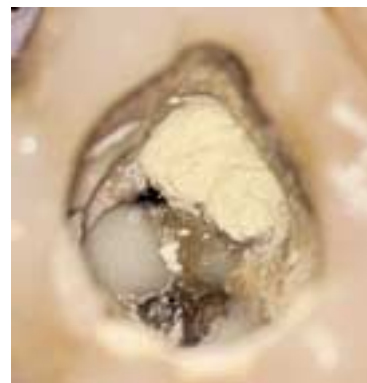

Fig 7 MTA was placed on the strip perforation.

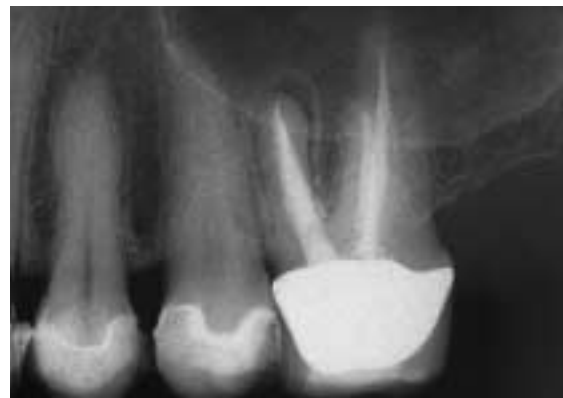

Fig 8 Periapical radiograph after retreatment.

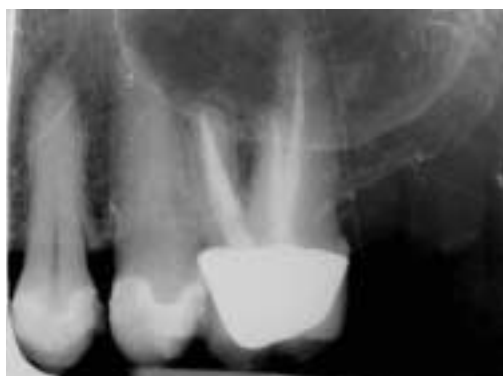

Fig 9 Periapical radiograph after 34 months.

■ Results

After 34 months, the patient was recalled. The patient was symptom-free. The tooth was not tender to percussion or palpation, and no fistula or sinus tract were present. A radiograph showed a normal, but slightly widened periodontal ligament (Fig 9).

■ Discussion

Failure due to infection related to the mesio-buccal root of an endodontically treated maxillary first molar is often associated with an untreated second mesio-buccal canal because this additional canal is often difficult to locate³. When diagnosed with a CT scan, 22 out of 27 unfilled root canals were associated with a periradicular lesion, indicating apical pathology³. Although the second mesio-buccal canal is difficult to locate, it is important for successful treatment outcome⁸. The surgical microscope can offer some help in locating this elusive canal².

When mesial-buccal roots of maxillary molars or mesial roots of mandibular molars are endodontically treated, care must be taken during the instrumentation to avoid a strip perforation⁹. An adequate access cavity can help instrumentation and minimise this procedural error. The access cavity must be located towards the mesial aspect of these canals where

the bulk of dentine is located. Furthermore, the opening of the orifice of the root canal should be situated towards the mesial aspect of the root canal to prevent strip perforation, because this will keep the files in the right position of the root canal.

Although it was possible to endodontically treat this molar, given the strip perforation the prognosis of this tooth is reduced.

■ Conclusions

When treating a mesio-buccal root of a maxillary molar it is often difficult to locate the second mesio-buccal canal; however, it is important to try to locate this because it could negatively influence the prognosis of the endodontic treatment⁹.

■ References

1. Schwarze T, Baethge C, Stecher T, Geurtsen W. Identification of second canals in the mesiobuccal root of maxillary first and second molars using magnifying loupes or an operating microscope. *Aust Endod J* 2002;28:57-60.
2. Cleghorn BN, Christie WH, Dong CCS. Root and root canal morphology of the human permanent maxillary first molar: a literature review. *J Endod* 2006;32:813-821.
3. Huuononen S, Kvist T, Grondahl K, Molander A. Diagnostic value of computed tomography in re-treatment of root fillings in maxillary molars. *Int Endod J* 2006;39:827-833.
4. Gutmann JL, Dumsha Th C, Lovdahl PE, Hovland EJ. *Problem Solving in Endodontics*. Missouri: Mosby Year Book 1997:107.
5. Wu MK, Wesselink PR, Walton RE. Apical terminus location of root canal treatment procedures. *Oral Surg Oral Med Oral Pathol Oral Radiol Endod* 2000;89:99-103.
6. Hülsmann M, Heckendorff M, Lennon A. Chelating agents in root canal treatment: mode of action and indications for their use. *Int Endod J* 2003;36:810-830.
7. Sathorn C, Parashos P, Messer HH. Effectiveness of single-versus multiple-visit endodontic treatment of teeth with apical periodontitis: a systematic review and meta-analysis. *Int Endod J* 2005;38:347-355.
8. Wolcott J, Ishley D, Kennedy W, Johnson S, Minnich S, Meyers J. A 5 yr clinical investigation of second mesiobuccal canals in endodontically treated and retreated maxillary molars. *J Endod* 2005;31:262-264.
9. Wu MK, van der Sluis LWM, Wesselink PR. The risk of furcal perforation in mandibular molars using Gates-Glidden drills with anticurvature pressure. *Oral Surg Oral Med Oral Pathol Oral Radiol Endod* 2005;99:378-382.