

Foundation for Oral Rehabilitation (FOR) consensus text on “The Rehabilitation of Missing Single Teeth”

■ Methodology used for establishing the consensus text

The Foundation for Oral Rehabilitation (FOR) gathered 11 experts for 2 days at the University of Mainz Medical Center to discuss the rehabilitation of missing single teeth. They had distributed their review papers to each other ahead of the meeting, which were written during the preceding months. The main conclusions of each review were briefly presented and discussed during the meeting.

The key findings of all review papers were integrated in the consensus text, which was iteratively composed by all participants. After the meeting another opportunity was provided to react to the final draft of the consensus and to amend it. Finally all experts agreed and no minority viewpoints were expressed.

■ Prevalence and treatment options

Prevalence of missing single teeth, which was defined as a gap of one tooth bordered by one or more natural teeth on either side, is high and thus a relevant oral health issue.

The experts listed a whole range of treatment options such as orthodontic space closure, removable partial dentures, resin-bonded fixed dental prostheses, tooth-supported fixed dental prostheses and implant-retained crowns. No treatment with professional monitoring was another alternative.

To propose a patient-centered treatment option, one must take into account general patient characteristics such as age, general health, medication, social interaction, psychology, professional background and economic constraints.

Oral health parameters are of course key decision factors, such as for example the health status of the neighbouring teeth and mucosa, and whether the edentulous space is visible during social interactions or interferes with phonetics or other oral functions.

Only after listening to the patient's wishes and expectations, eventually involving the relatives, and after thoroughly explaining the different options, i.e. their costs, benefits and side-effects, is the patient in a position to consent to a certain treatment.

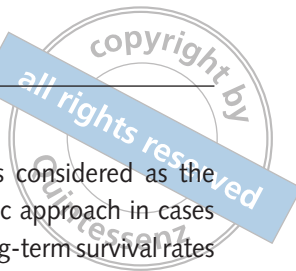■ Preoperative radiological evaluation of missing single teeth¹

Pretreatment diagnostics assessing a missing single tooth area usually involves radiological imaging. Justification for imaging should be defined at the individual patient level. Thus one cannot impose general rules for the type of imaging that is indicated. Consideration should be given to the risks and benefits of radiation and its cost-effectiveness.

Particular attention to justification needs to be given where the radiation dose is known to be significant, such as with cross-sectional imaging with some Cone beam computed tomography (CBCT) equipment and multislice computerised tomography. This especially applies in younger age groups.

An important consideration in favour of cross-sectional imaging is when it is likely to have an impact upon diagnosis, treatment planning and patient outcome, but the body of research is small, of mixed quality and sometimes contradictory.

For the prosthetic rehabilitation of missing single teeth, intraoral radiographs suffice in the great majority of patients. For the dorsal areas, panoramic



radiographs may provide sufficient information but not as good as intraoral radiographs. However, when an implant-based treatment is considered to be cross-sectional imaging, CBCT is widely used but the evidence for efficacy is limited. In some studies, the use of cross-sectional imaging appeared to increase the confidence of the surgeon in terms of bone volume evaluation and the selection of the proper implant size. CBCT should not be the first imaging option when assessing a new patient, because an intraoral radiograph may reveal conditions which would eliminate use of an implant as a treatment option.

■ Missing upper lateral incisors²

Congenitally missing upper lateral incisors can be a relevant clinical problem. It is the second most common agenesis, after that of the third molar. Although the evidence is weak because of the absence of Randomised Controlled Trials (RCT), comparative studies indicate that orthodontic space closure leads to a better periodontal condition than when a fixed prosthesis on teeth is used. One comparative study reveals patient satisfaction to be superior after orthodontic treatment, when compared to prosthetic rehabilitations on teeth, while another study found no difference.

Early diagnosis of the congenitally missing lateral incisor is important, since it allows for the planned extraction of the primary lateral incisor and the guided eruption of the canine into a position adjacent to the secondary central incisor. Subsequently, this may be followed by space closure or by opening of the space for prosthodontic rehabilitation. If aesthetic problems may occur after orthodontic closure because of size, shape and colour differences between the canines and the central incisors, restorative interventions may be required. In such patients, the use of an implant may be advisable. In growing patients with a high smile line the orthodontic option should be considered first to obtain long-term aesthetic results. Not all patients are suitable for orthodontic space closure, for example individuals with sagittal skeletal discrepancies.

Even when prosthetic rehabilitation of missing lateral incisors is used, it is often preceded by orthodontic treatment to establish an appropriate space.

Single implant placement is considered as the most conservative prosthodontic approach in cases of sound adjacent teeth. The long-term survival rates reported renders it an attractive therapeutic option. Distalising a mesially erupted canine can lead to a sufficient bone volume to allow implant insertion in the lateral incisor area. When planning the timing of implant placement, one must consider the growth phase of the patient.

■ Guided surgery for single implant insertion³

Although high accuracy and high cumulative survival rates – better than for mucosa-supported templates in edentulism - have been reported for single tooth replacement by implants using fully guided surgery, the evidence supporting the advantages of using a template-based approach remains weak.


The use of 3D software can improve diagnostics, increase the surgeon's confidence and eventually reduce perioperative complications. Fully guided surgery facilitates a minimally invasive (flapless) approach which seems to improve the soft tissue appearance. The higher cost should be considered but the shorter treatment time and reduced side effects should also be taken into account.

The literature suggests that proper training remains a prerequisite even for single implant insertion using surgical templates.

■ Impact of immediate placement and/or loading (functional or not) of single implants on hard and soft tissues in the anterior region⁴

Recent literature, limited to the anterior maxilla, indicates that immediate implant placement after a single tooth extraction is a favourable option. Prospective studies on the immediate placement of implants (flapless for > 400 out of 626 implants) with immediate provisional prosthetic rehabilitation out of occlusal contact, report a 98.25% survival rate.

The remaining space between the placed implant surface and the alveolar wall reached up to



4 mm and satisfactory results were obtained while no grafting was performed in one third of the patients.

Those studies which report on marginal bone level show similar changes for the staged as for the immediate approach. Mean marginal bone loss was less than 1 mm for a mean of 31 months of follow-up.

Primary stability was generally high as measured by a minimum insertion torque value of 32 Ncm and/or an ISQ value of 60, in order to meet the inclusion criteria of those individual studies. Gingival papillae migrate incisally when a crown with a proper contour is placed. This can take up to 1 year.

Minimal invasivity in most of the studies was reflected by flapless implant insertion. None of the papers used soft tissue grafting or bone grafting, except in some papers for filling the gap between the implant surface and the alveolar wall.

These findings are divergent from a previous review which did not favour immediate implant placement and rehabilitation because of subsequent midfacial mucosal recession. This difference may be due to the fact that in the present review minimal surgical invasiveness was used by most authors. The patient inclusion criteria were stringent and may also have positively influenced the results.

■ Replacement of missing single teeth in posterior areas⁵

In the posterior areas of the mouth, reports on missing single teeth were limited to molars⁵, as data were not available for premolars. The definitions of immediate and of delayed loading were very variable, therefore no meta-analysis could be performed. In two comparative papers reporting on nearly a thousand implants, the survival and success rates were higher for delayed loading of single implants in the molar areas (98.3% vs 95.4%).

For the alternative treatment option of fixed partial dentures on teeth, the literature reports a mean survival rate of 85.6% with follow-up times of 3 to 13 years.

The tendency to use large diameter implants may explain the observation of increased marginal bone loss around implants in the molar region but less so for immediately placed implants: average

of 0.91 mm for delayed vs 0.73 mm for immediate loading. Survival rates did not reveal significant differences between immediate implant placements in extraction sockets when compared with delayed placement. When success rates were considered, delayed implant placement seems more favourable.

■ Bone augmentation for single tooth implants⁶

When bone augmentation procedures prior to implant placement are needed, several studies report on onlay and inlay grafts and only one reports on distraction osteogenesis. Autografts, allografts, xenografts and alloplasts all seem to function with very high implant survival rates. The subsequent graft resorption is sparsely evaluated in the literature, although autogenous grafts seem more prone to volume reduction than the other materials. The use of postoperative CBCT to evaluate the change of graft volumes over time is not justified in routine clinical practice.

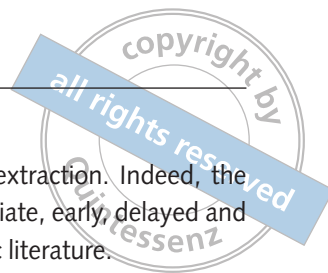
The majority of studies of onlay grafts used a staged approach and a delayed loading protocol. A variety of membranes were used in conjunction with bone augmentation and seemed to preserve the graft better.

Sinus inlay grafts with immediate implant placement and delayed loading seems to be the treatment protocol of choice in the posterior maxilla.

Shorter implants without grafting when compared with longer implants in former grafted regions may have similar outcomes.

■ Bonded vs all-ceramic and metal-ceramic fixed prostheses⁷

Single tooth replacement can also be achieved by tooth-supported all-ceramic vs metal-ceramic or resin-bonded fixed dental prostheses. Resin-bonded fixations perform better in the anterior segments when abutment teeth are being prepared and when a single-retainer cantilever design is chosen. The most frequent complication is debonding. For all-ceramic prostheses based on zirconia frameworks, chipping fractures of the ceramic veneer are frequent. Based



on systematic reviews, the 5-year survival rates for these three treatment options (all-ceramic, metal-ceramic and resin-bonded prostheses) are 94.3%, 94.4% and 92.3%, respectively. For the latter, a 2-unit cantilever design was used in the anterior region. However, since the year 2008, two 5-year prospective clinical studies have been published showing 100% survival for 3-unit zirconia fixed dental prostheses. It indicates the technology for zirconia all-ceramic restorations reached a mature level.

Monolithic zirconia restorations which were introduced with the aim of eliminating veneer chipping fractures remain a matter of concern because of the low temperature degradation phenomena. There are also fiber reinforced composite resins and inlay retained dental prostheses but these have no predictable long-term outcome.

■ Long-term outcome of single implant-based restorations⁸

Long term (≥ 10 years) survival rates have been reported for single implants but more or less exclusively for titanium implants with a turned surface.

The literature reveals a 93.8% cumulative patient-implant treatment survival and 95.0% at 'implant level' but, because of the retreatment need, only an 89.5% cumulative survival for the supported single crown.

The 10-year survival rate of implant-based crowns was always better when compared to fixed 3-unit prostheses on teeth (90%).

Recent unpublished data on 620 patients from one center reveal that for implants with a moderately rough surface, the 10-year survival rates are even better than for the turned surface implants: reaching 98.5% vs 95.8%, respectively for the maxilla and 97.2% vs 95.1%, respectively for the mandible.

■ Timing of single implant placement and long-term observation of marginal bone levels⁹

Available literature is inconclusive regarding the impact on the timing of implant placement on the

outcome after single tooth extraction. Indeed, the meaning of the terms immediate, early, delayed and late varies greatly in scientific literature.

Interproximal bone level changes in relation to implants placed in non-healed sockets (immediate or early) vs in healed sockets (late) was not significantly different in short-term (at 1 year) and long-term studies (at 10 years).

In 14 out of 22 controlled studies, survival rates appeared lower in the test group (immediate/early) compared to the control group (delayed/late), while only one study showed the opposite (seven studies showed identical survival rates in the two groups).

In long-term peri-implant bone remodelling, mostly bone loss but sometimes bone gain was observed. However one should keep in mind that the implants that underwent follow up over the years were those which survived. Therefore neglecting to give consideration to the lost implants can bias the conclusions when it comes to whether the timing of implant placement has a long-term impact on marginal bone level.

The buccal bone level was assessed by CBCT in only a few trials. Due to low resolution and various types of artefacts related to this radiographic method, CBCT should not be used as a standard in monitoring the marginal bone around implants.

■ Patient information on treatment alternatives¹⁰

Data on patient knowledge and transfer of information on treatment options for replacing missing single teeth mostly originate from Asia (20 out of 29 papers). The patient sample size varied from 109 to 10,000, with a total of 23,702 responding participants. The treatment choices were 62% for fixed partial dentures, 54% for removable partial dentures and 50% for implant-supported prostheses. The socioeconomic and cultural heterogeneity amongst those studies should be stressed. When patients were questioned about the origin of their information, 45% indicated their clinician vs 28% for the media. It is noteworthy that most reports indicate slightly more than half the patients feel their knowledge is insufficient and more than two-thirds feel a need for more information. The cost factor was

the most important impeding factor for choosing the implant option in Austrian Gallup studies. The surgeon and or clinician were identified as being the people responsible for the greatest proportion of the total cost of treatment.

■ Cost-effectiveness of treatment options¹¹

The cost-benefit aspects of the different therapeutic approaches for single tooth replacement are very difficult to analyse systematically, considering the large variation in personnel and overhead costs or social healthcare systems in different countries. However, since most scientific reports on this subject compare the cost of different procedures in a well-defined area, some useful information can still be gathered.

Most papers concluded that implant-based treatments are generally more cost-effective than fixed dental prostheses supported by teeth. However endodontic treatment and retreatment, to maintain a compromised tooth, are more cost-effective than a fixed partial denture or implant-supported prosthesis. Autotransplantation of teeth is of course more cost-effective than a tooth or implant-supported replacement.

Patient interviews revealed on the one hand a higher degree of satisfaction with implant-based rehabilitations but on the other hand more complaints about the cost and frequency of postoperative maintenance appointments. The patients' opinion is that implants should become more affordable.

The common use of a tooth-supported fixed prosthesis by clinicians may be related to the familiarity with the procedure and constraints in certain health care and insurance systems. The lower survival rate of fixed partial dentures leads to a higher cost in long-term perspectives because of the retreatments.

No treatment for a missing single tooth can be considered as an alternative when there is an established dental arch stability, a healthy periodontium and when oral functions like phonetics or social appearance are not compromised. Proper professional follow-up is still advocated.

■ Recommendations of the group of experts

While all review papers presented for this consensus conference detected an impressive number of publications related to each subject, very few papers passed the quality-based inclusion criteria used by the experts to build evidence-based guidelines.

Too few RCTs were available. More evidence-informed guidelines for clinical trial protocols are needed.

In the absence of scientific evidence at the highest level, the expert group felt to the best of their knowledge and experience that:

- The selected treatment should be evidence-based, whenever relevant data are available, and taken in the best interests of the patient rather than depend on the clinician's preferences or abilities.
- Patient referral to qualified specialists should be considered in some circumstances.
- The use of single implants offers a higher survival rate than tooth-supported fixed dental prostheses.
- The profession should become more aware of the cost-effectiveness of different methods for replacing missing teeth.
- Validated checklists, such as the Drummond Checklist, and collaboration with a health economist are recommended for studies involving cost-effectiveness.
- Since, besides hardware, time is a universal measure for cost-effectiveness, future research should identify the time involved by all participants in the treatment team, the patient and relatives when assessing the cost of replacing missing single teeth.
- Scientific organisations, independent from industry and professional interests, with patients and/or public involvement, should provide the public with balanced and evidence-based information to improve the population awareness of different treatment modalities.
- Standardised definitions of immediate, early and of delayed implant placement and loading should be used. It is proposed that immediate placement means within the same day of tooth extraction, while early means within 1 week and up to 8 weeks after extraction. The term immediate

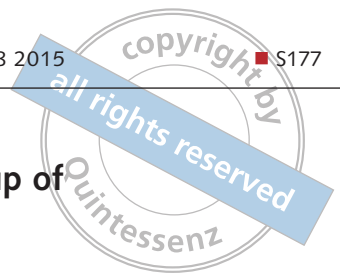


Fig 1 From left to right Drs Gabor Tepper, Stavros Kiliaridis, Paul Weigl, Matthias Karl, Charles Goodacre, Ann Wenzel, Bertil Friberg, Torsten Jemt, Friedrich Neukam, Keith Horner, Daniel van Steenberghe and Christian Walter. Missing for the group picture: Drs Wilfried Wagner, Alexander Pozzi and Peter Moy.



loading should be reserved for oral implants that are subject to a full occlusal load within 3 days, whereas early loading means after 1 to 2 weeks. Occlusal loading after more than 2 weeks, even if the implant has been exposed intraorally and thus subject to eventual loading by the food bolus, should be coined delayed loading.

- Preoperative diagnostic imaging should not systematically opt for cross-sectional viewing unless it will be used in preoperative planning for guided implant surgery. One region which regularly requires cross-sectional imaging is the posterior mandible where the inferior alveolar nerve is a liability.
- In the absence of universally defined guidelines it is proposed that after a baseline radiograph at the fitting of the prosthesis, a control radiograph, with a strict paralleling technique, should be taken after 1 year to monitor the result and bone remodeling. If marginal bone loss appears ≤ 1 mm, then a new radiograph after 5 years seems adequate. A radiograph can be taken at any time point if there is a clinically evident problem.
- There is a need for setting up oral hygiene protocols after immediate implant placement and throughout the surgical healing phase.

■ References

1. Horner K, Shelley A. Preoperative radiological evaluation of missing single teeth: A review. *Eur J Oral Implantol* 2016.
2. Kiliaridis S, Sidira M, Kirmanidou Y, Michalakis K. Treatment options for congenitally missing lateral incisors. *Eur J Oral Implantol* 2016.
3. Pozzi A, Polizzi G. Accuracy, aesthetic and implant survival rate using computer-assisted template-based surgery for implant-supported single-tooth restorations: A critical review. *Eur J Oral Implantol* 2016.
4. Weigl P. The impact of immediate placement and/or loading of single-tooth implants on hard and soft tissues. *Eur J Oral Implantol* 2016.
5. Moy P, Nishimura G, Danda A, Pozzi A. Single implants in dorsal areas – A systematic review. *Eur J Oral Implantol* 2016.
6. Friberg B. Bone augmentation for single tooth implants: A review of the literature. *Eur J Oral Implantol* 2016.
7. Karl M. Outcome of bonded vs. all-ceramic and metal-ceramic fixed prostheses for single tooth replacement. *Eur J Oral Implantol* 2016.
8. Hjalmarsson L, Gheisarifar M, Jemt T. A systematic review of survival of single implants as presented in longitudinal studies with a follow-up of at least 10 years. *Eur J Oral Implantol* 2016.
9. Schropp L, Wenzel A. Timing of single implant placement and long-term observation of marginal bone levels. *Eur J Oral Implantol* 2016.
10. Edelmayer M, Woletz K, Tepper G. Patient information on treatment alternatives for missing single teeth–Systematic Review. *Eur J Oral Implantol* 2016.
11. Goodacre C, Naylor WP. Single implant and crown versus fixed partial denture: a cost-benefit, patient-centered analysis. *Eur J Oral Implantol* 2016.