

Treatment of condylar neck fracture by Otten's minihooks

Language: English

Authors: Dr.Dr. Sirichai Kiattavorncharoen¹, PD.Dr.Dr.Johannes Kleinheinz², Prof.Dr.Dr.Dr. hc Ulrich Joos²

¹Department of Oral and Maxillofacial Surgery, Faculty of Dentistry, Mahidol University, Thailand

²Department of Cranio- and Maxillofacial Surgery, University of Muenster, Germany

Date/Event/Venue:

18-23 January 1998

20th Asia Pacific Dental Congress

Bangkok, Thailand

Introduction

Nowadays there are two different concepts of the treatment of condylar neck fracture. They are conservative and surgical treatment. The conservative treatments have traditionally been treated by maxillomandibular fixation. One technique for conservative treatment using Otten's minihooks is described. This technique has been described by J-E Otten 1981.

Materials

1. Otten's minihook is a S-shaped 0.8 mm wire hook.
2. Osteosynthesis minihooks (Diameter 2 mm.)



Fig. 1 Otten's minihooks and osteosynthesis miniscrews

Technique

1. Local anesthesia
2. Vertical incision oral mucosa in area of nasal spine and symphysis of mandible.
3. Exposing the bone.
4. Drilling the bone with drill 1.5 mm
5. Fixing Otten's minihooks with 2 mm osteosynthesis miniscrews, which inserted into the nasal spine and the symphyseal region of mandible.
6. Suture the wounds
7. Insert maxillary splint
8. Intermaxillary fixation with elastics or wire
9. After the 10 days of intermaxillary fixation, the Otten's minihooks and osteosynthesis microscrews are removed under local anesthesia.
10. Active functional treatment

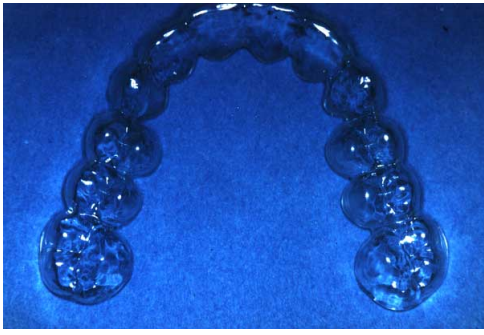

Fig. 2 Maxillary splint

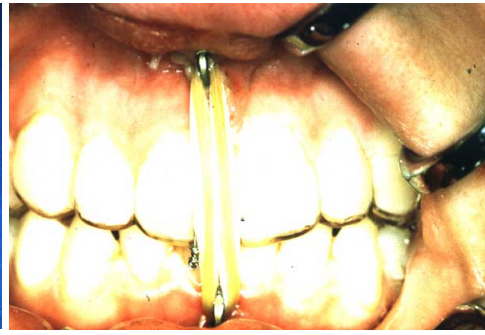

Fig. 3 Intermaxillary fixation with elastics and wire over Otten's minihooks and maxillary splint.

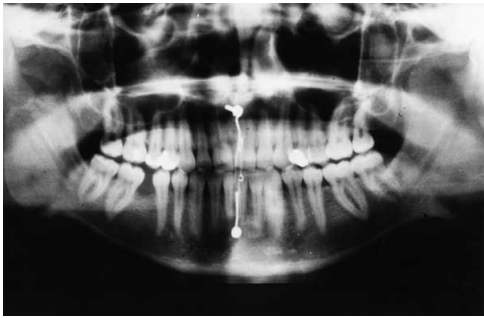

Fig. 4 X-ray OP postoperative

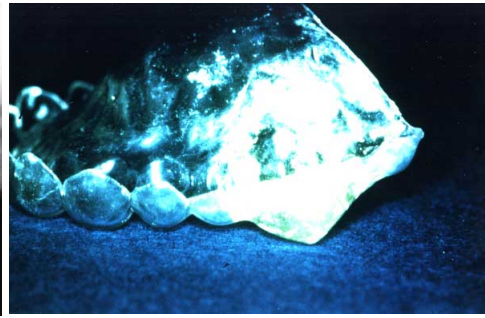


Fig. 5 Splint with hypomochlion

Indications

1. High condylar neck fractures without dislocation
2. Intracapsular condylar fractures
3. Condylar neck fracture in children (<16 years)

In case of condylar neck fracture with mild dislocation, if the establishment of correct relationships does not bring about the correct position of the displaced condylar fragment, one can make use of the indirect action of reducing forces by insertion of a fulcrum (Hypomochlion) in the molar region of maxillary splint on the fracture site and by means of intermaxillary traction in the incisor region.

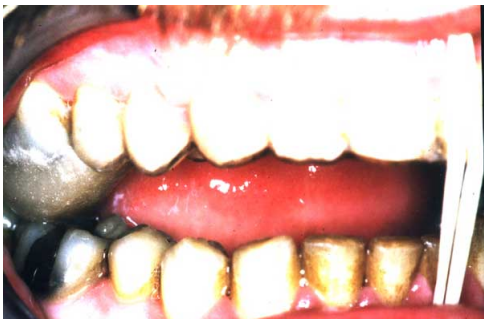

Fig. 6 Maxillary splint with hypomochlion in place intraorally

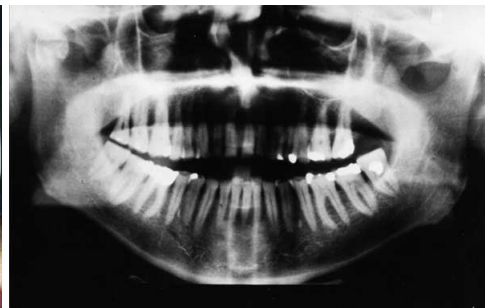

Fig. 7 X-ray OP in case of condylar neck fracture with mild dislocation

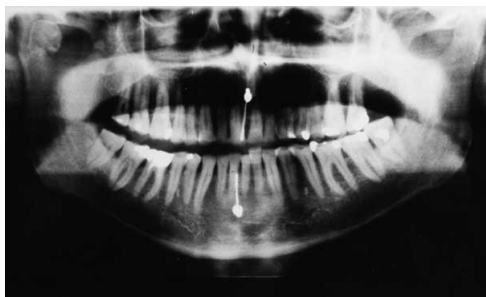

Fig. 8 X-ray OP postoperative with hypomochlion in place

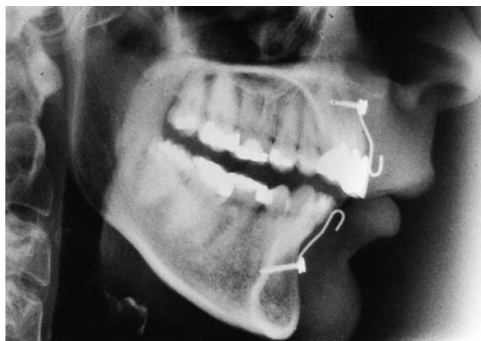

Fig. 9 X-ray lateral view with hypomochlion in place

Summary

The technique for conservation treatment of condylar neck fracture by Otten's minihooks is simple and appears to be a time-saving method. It is also easy to maintain proper oral hygiene and can be performed under local anesthesia.

References

1. Otten JE. Modifizierte Methode zur intermaxillaren Immobilisation. Dtsch Zahn Arztl Z 1981;36:91-2.
2. Win KKS et al. Intermaxillary fixation using screws. Report of a technique. Int J Oral Maxillofac Surg 1991;20:283-4.

This poster was submitted by Dr.Dr. Sirichai Kiattavorncharoen.

Correspondence address:

Dr.Dr. Sirichai Kiattavorncharoen

Department of Oral and Maxillofacial Surgery

Faculty of Dentistry

Mahidol University

Yotee Road

Bangkok 10400

Thailand



Treatment of condylar neck fracture by Otten's minihooks

Kiattavorncharoen S *, Kleinheinz J, Joos U

Department of Cranio-Maxillofacial Surgery, Wilhelms University, Muenster, Germany. *Department of Oral and Maxillofacial Surgery, Mahidol University, Bangkok, Thailand.

Nowadays there are two different concepts of the treatment of condylar neck fracture. They are conservative and surgical treatment. The conservative treatments have traditionally been treated by maxillomandibular fixation. One technique for conservative treatment using Otten's minihooks is described. This technique has been described by J-E Otten 1981.

Materials

1. Otten's minihook is a S-shaped 0.8 mm wire hook.
2. Osteosynthesis minihooks. (Diameter 2 mm.)



Fig. 1 Otten's minihooks and Osteosynthesis miniscrews.

Technique

1. Local anesthesia.
2. Vertical incision oral mucosa in area of nasal spine and symphysis of mandible.
3. Exposing the bone.
4. Drilling the bone with drill 1.5 mm.
5. Fixing Otten's minihooks with 2 mm osteosynthesis miniscrews, which inserted into the nasal spine and the symphyseal region of mandible.
6. Suture the wounds.
7. Insert maxillary splint.
8. Intermaxillary fixation with elastics or wire.
9. After the 10 days of intermaxillary fixation, the Otten's minihooks and osteosynthesis miniscrews are removed under local anesthesia.
10. Active functional treatment.




Fig. 2 Maxillary splint.

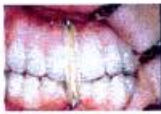

Fig. 3 Intermaxillary fixation with elastics and wire over Otten's minihooks and maxillary splint.

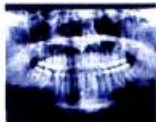

Fig. 4 X-ray OP Postoperative.

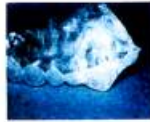

Fig. 5 Splint with Hypomochlion

Indications

1. High condylar neck fractures without dislocation.
 2. Intra capsular condylar fractures.
 3. Condylar neck fracture in children (< 16 years.)
- In case of condylar neck fracture with mild dislocation. If the establishment of correct occlusal relationships does not bring about the correct position of the displaced condylar fragment, one can make use of the indirect action of reducing forces by insertion of a fulcrum (Hypomochlion) in the molar region of maxillary splint on the fracture site and by means of intermaxillary traction in the incisor region.

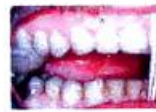

Fig. 6 Maxillary splint with Hypomochlion in place intraorally.

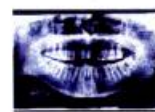

Fig. 7 X-ray OP in case of condylar neck fracture with mild dislocation.

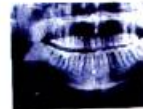


Fig. 8 X-ray OP Postoperative with Hypomochlion in place.

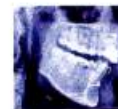

Fig. 9 X-ray lateral view with Hypomochlion in place.

Summary

The technique for conservative treatment of condylar neck fracture by Otten's minihooks is simple and appears to be a time-saving method. It is also easy to maintain proper oral hygiene and can be performed under local anesthesia.

References

1. Otten JE. Modifizierte Methode zur intermaxillaren Immobilisation. Dtsch Zahn arzt Z 1981;36:91-92.
2. Win KKS et al. Intermaxillary fixation using screws. Report of a technique. Int J Oral Maxillofac Surg 1991;20:283-284.