



Immediate Loading versus Early Loading: a case report

Alberto Maltagliati, Francesca Parducci, Luciano Cingano and Andrea Ottonello

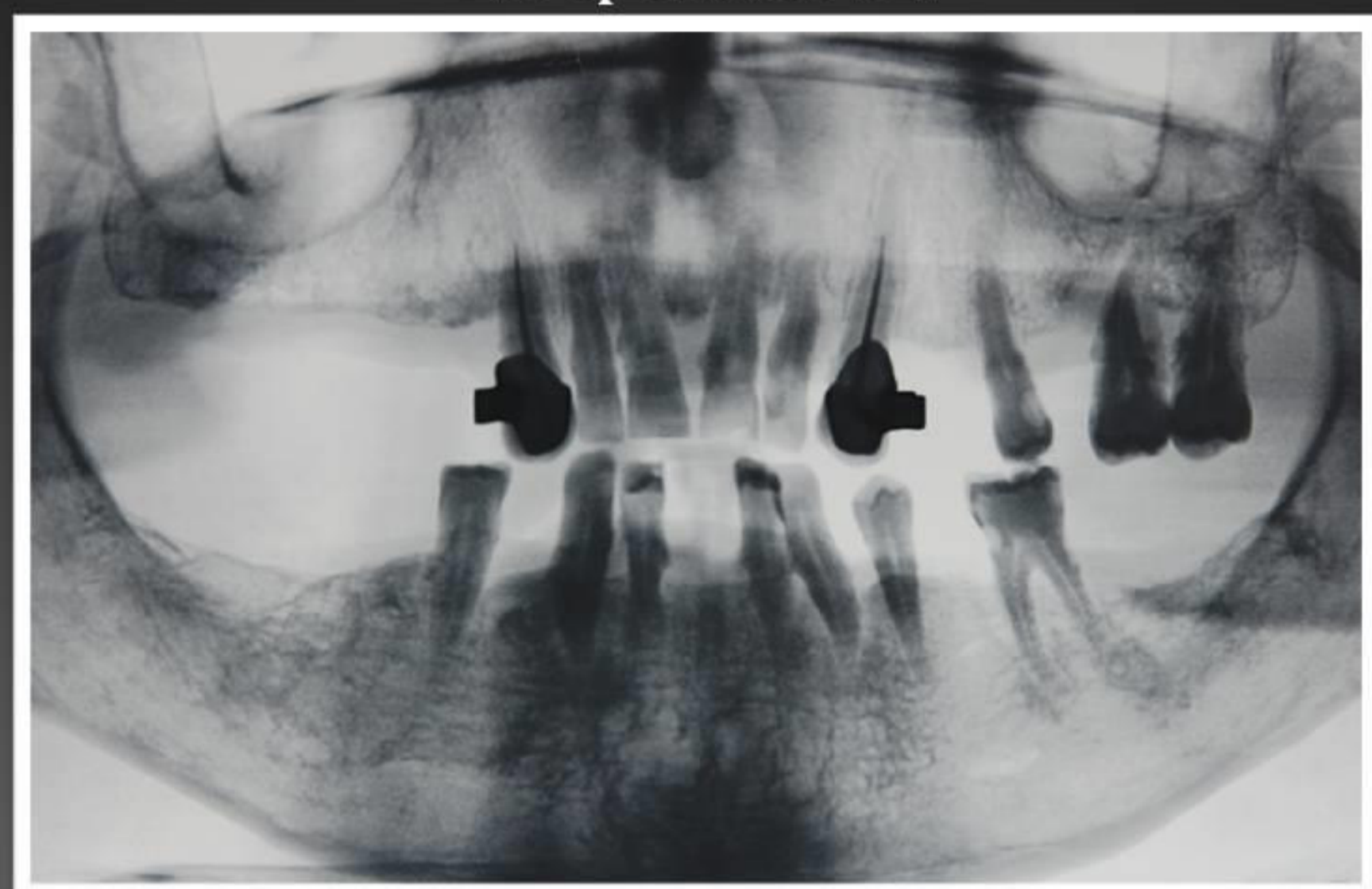
Università degli Studi di Genova, Dipartimento di Scienze Chirurgiche e Diagnostiche integrate, Sezione di Clinica Odontostomatologica

“Immediate Loading” is currently the golden standard in order to maintain appropriate anatomic and topographic proportions between dental archers, to maintain the contact with the marginal periodontium and finally for the “occlusal/contact memory”. The concepts of “primary stability”, torque wrench, osseointegration and adequate/suitable denture, are the main factors for immediate and long-distance clinical outcome. We placed 233 implants – 110 in the mandibula and 123 in the maxilla. 115 implants have been prosthesised with cemented technique after 60-90 days; 118 implants have been prosthesised with screwed technique after 72 hours. We used autologous fibrin glue to increase peri-implant connective tissue formation, to manage inflammation and healing, and to accelerate vascularization thanks to growth factors (i.e. VEGF, PDGF) contained in the buffy coat. All clinical cases have been monitored radiographically with the same machine after 12 and 24 months from loading. The same doctor monitored all the clinical cases making periodontal probe after 6, 12, 18 and 24 months.

Basing on our controls, we report a 2 mm conical peri-implant reabsorption on 6 implants loaded after 72 hours after 18 months; in our opinion this may be caused by prosthetic parafunctions in full-arch rehabilitations of only one arch and natural teeth as antagonist. We did not notice any reabsorption in full-arch rehabilitations regarding both arches on the same patients. 2 implants in the maxilla (first left molar and first right molar in the same patient), both loaded after 72 hours, got lost. We succeeded in confirming an augmentation of the short-term aesthetic in the Immediate Loading technique within 24 months, with a physiological maintenance of the interimplant papilla and a good trophism of the periodontium. Both the techniques used reached a good mid- and long-term predictability and repeatability; with both methods we could assure mid-grade aesthetic and function. Finally, in our opinion, the Immediate Loading technique (with full-arch rehabilitation using the screwed technique) represents nowadays the gold standard in implantoprosthesis rehabilitation, because it reduces intraoperative time and increases wound healing, both in bone and in soft tissues, with an excellent compliance from patients.

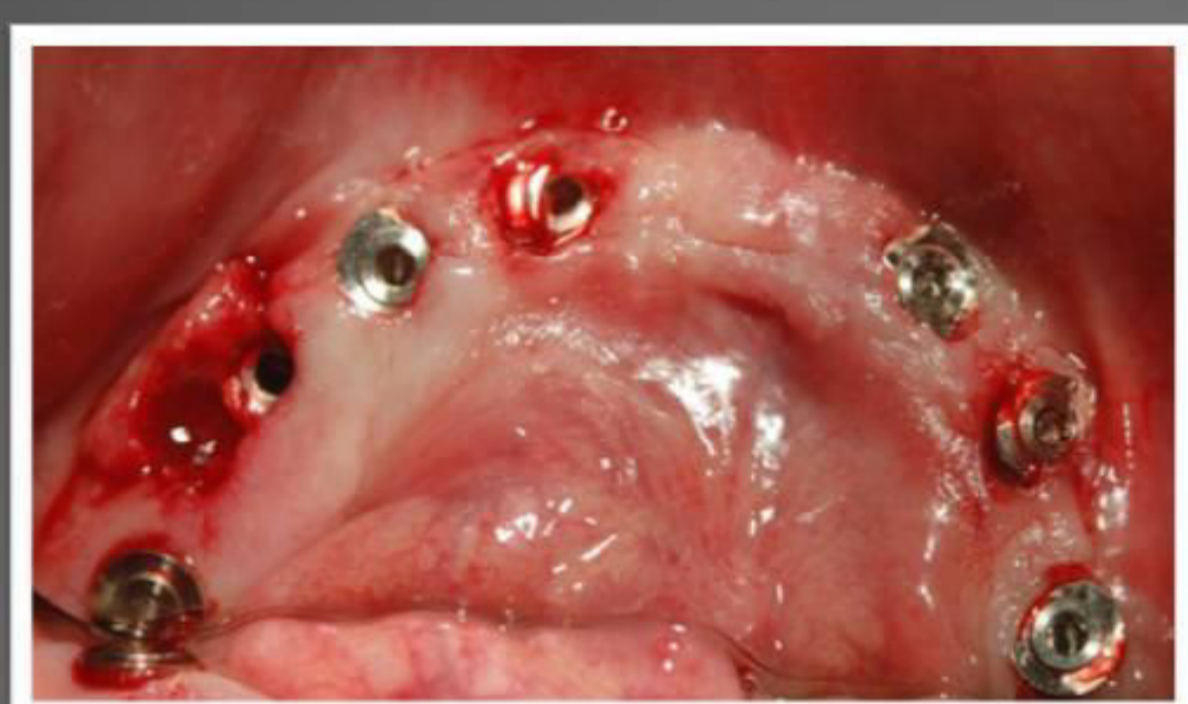
CASE 1

Preoperative Rx

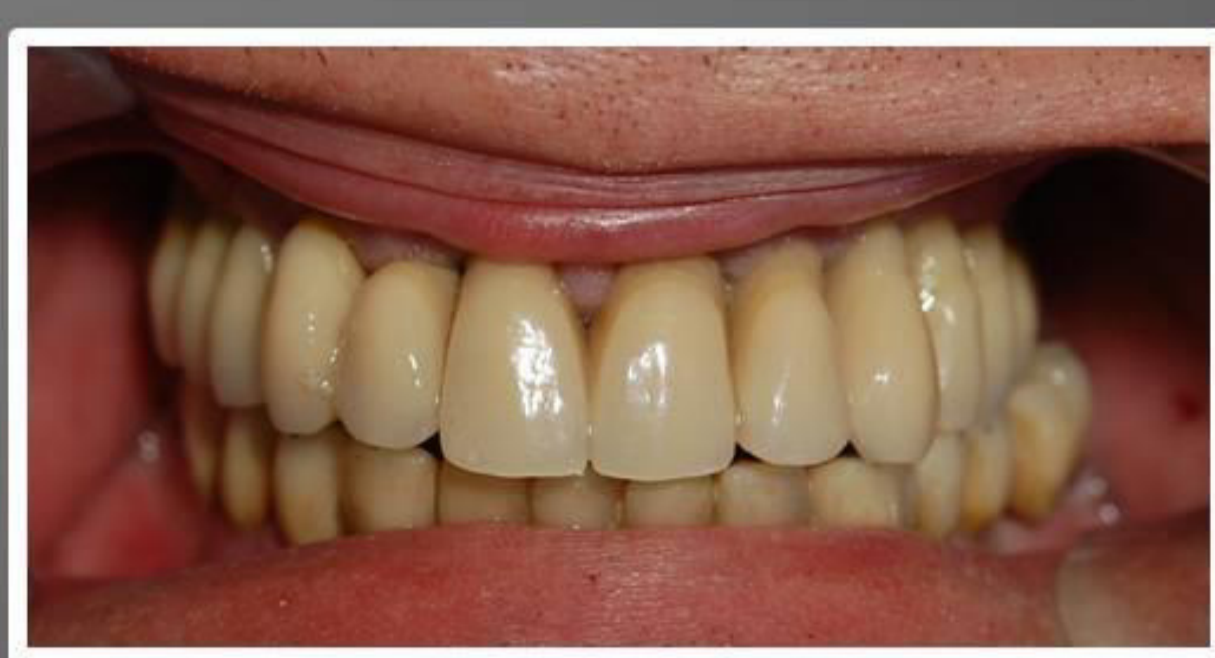
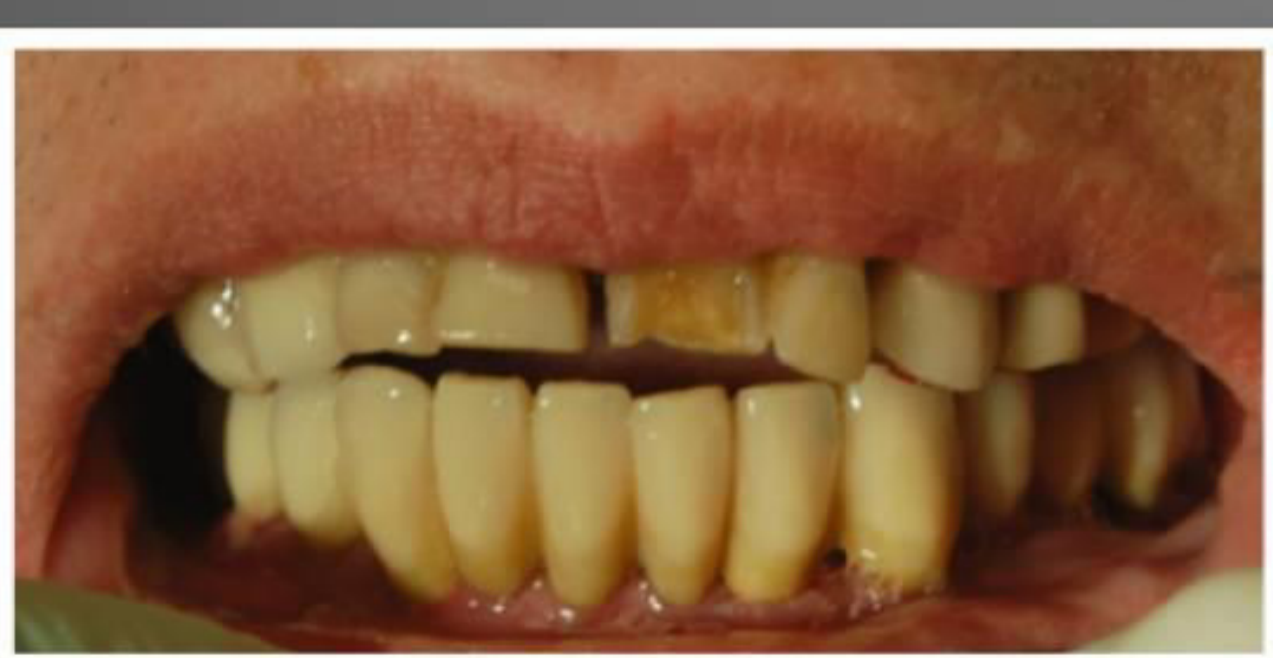
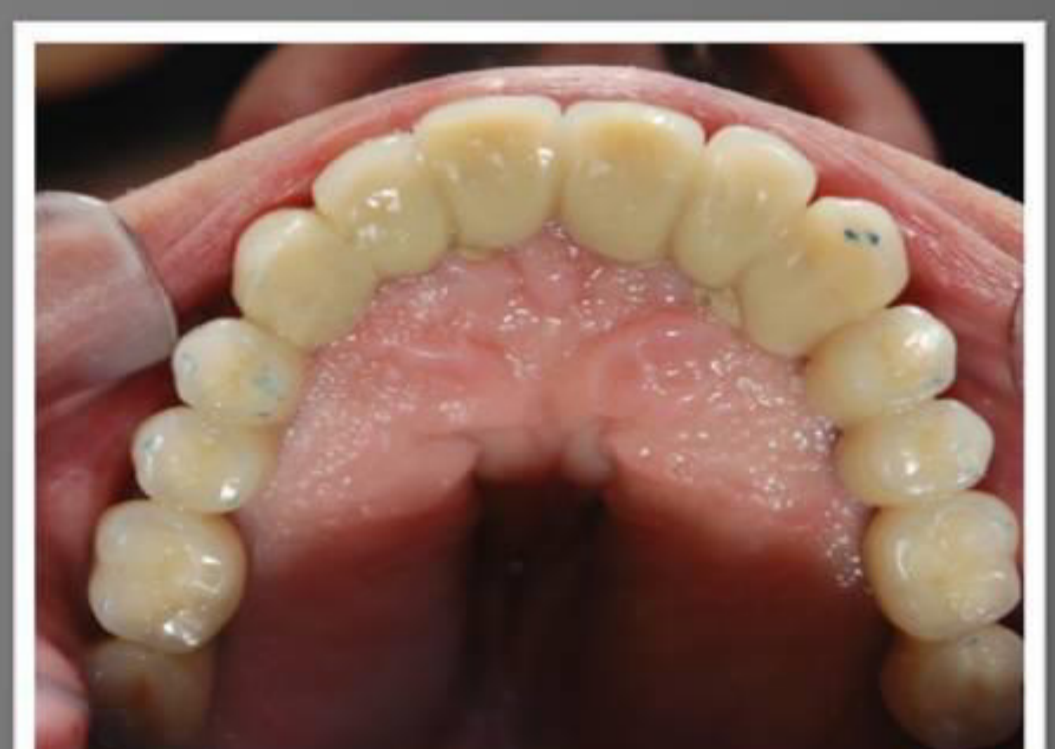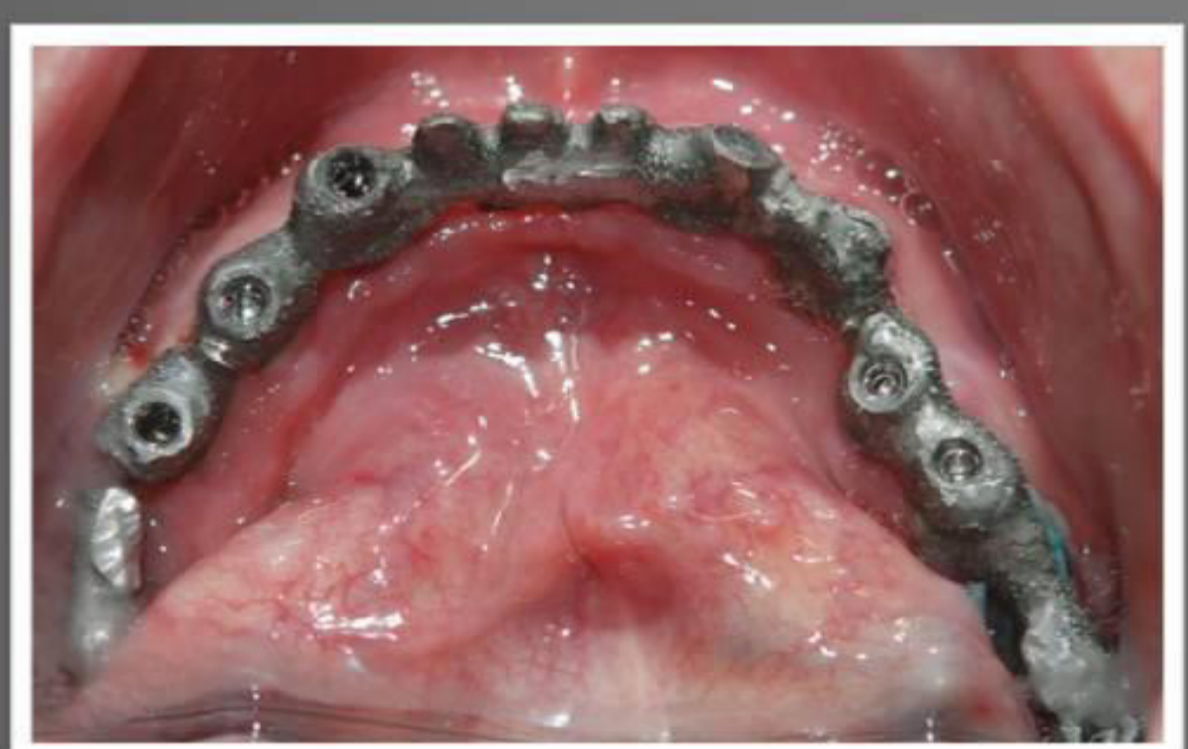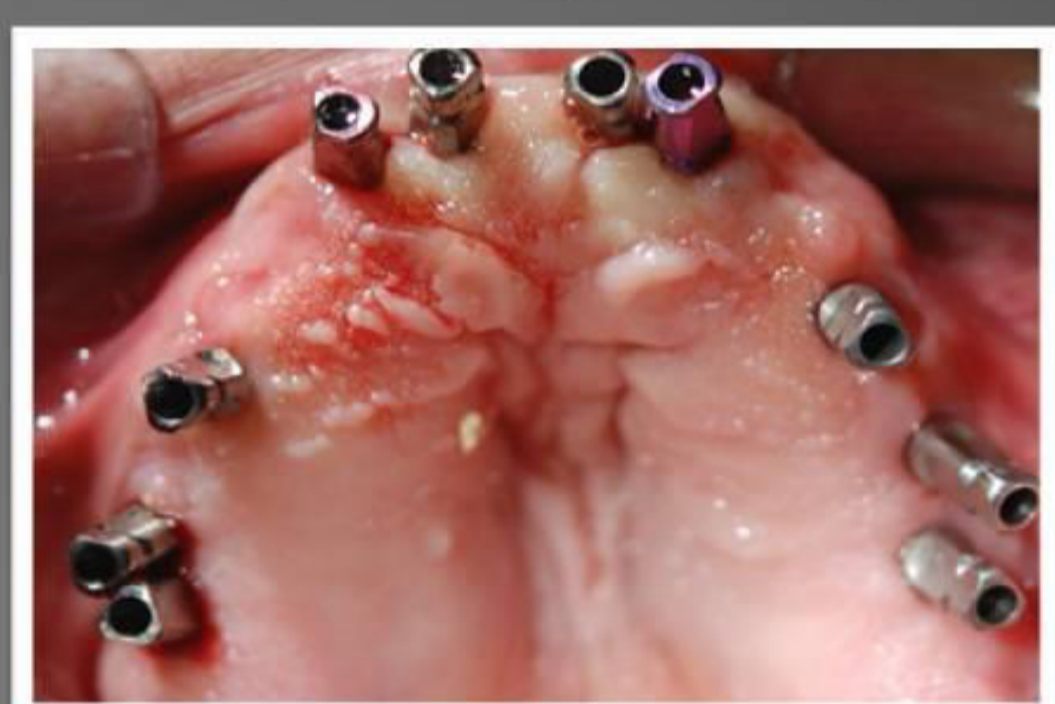Surgery

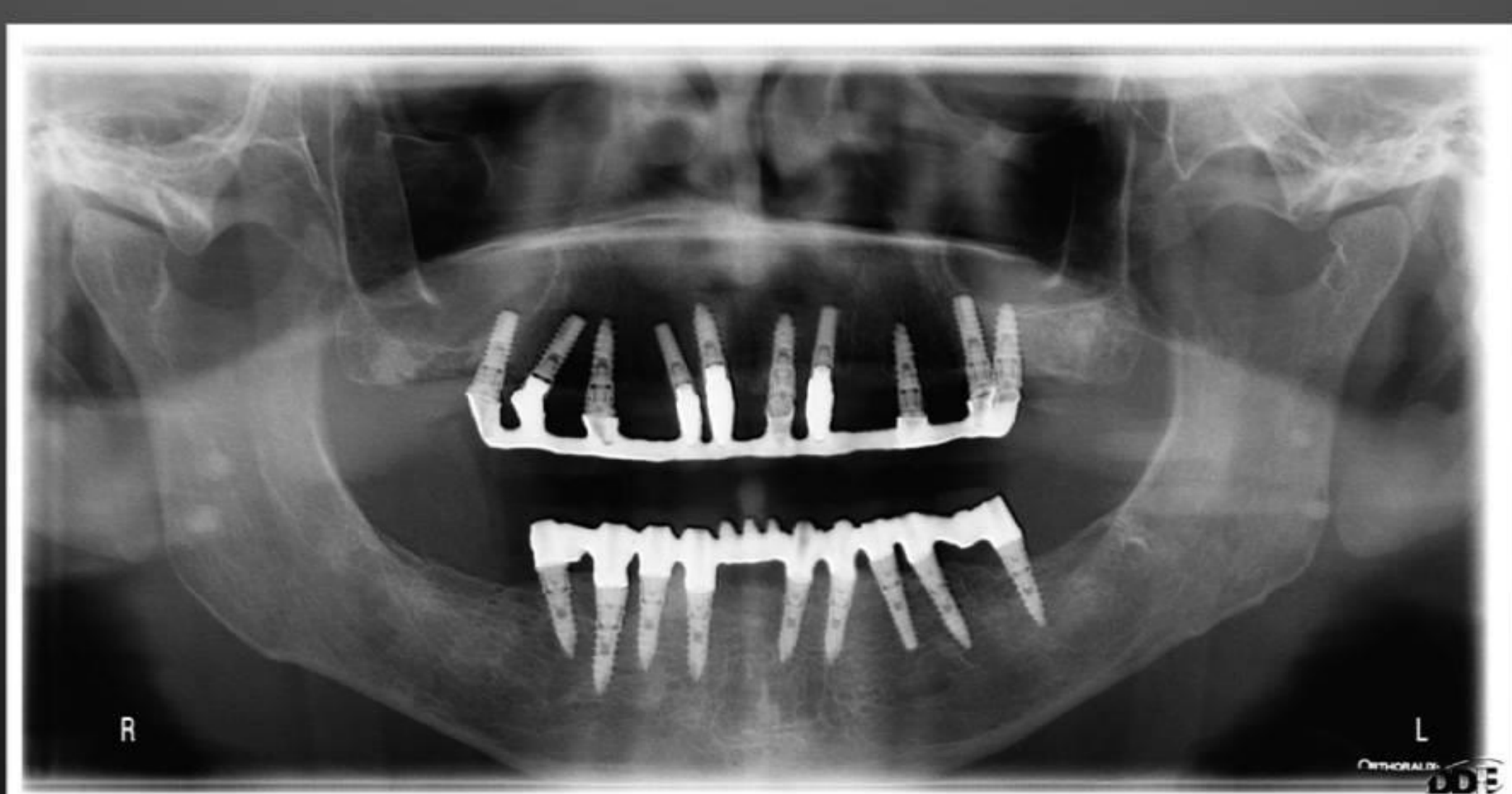Mandibula
Immediate Loading @ 72 h



Maxilla
Early Loading @ 60 days

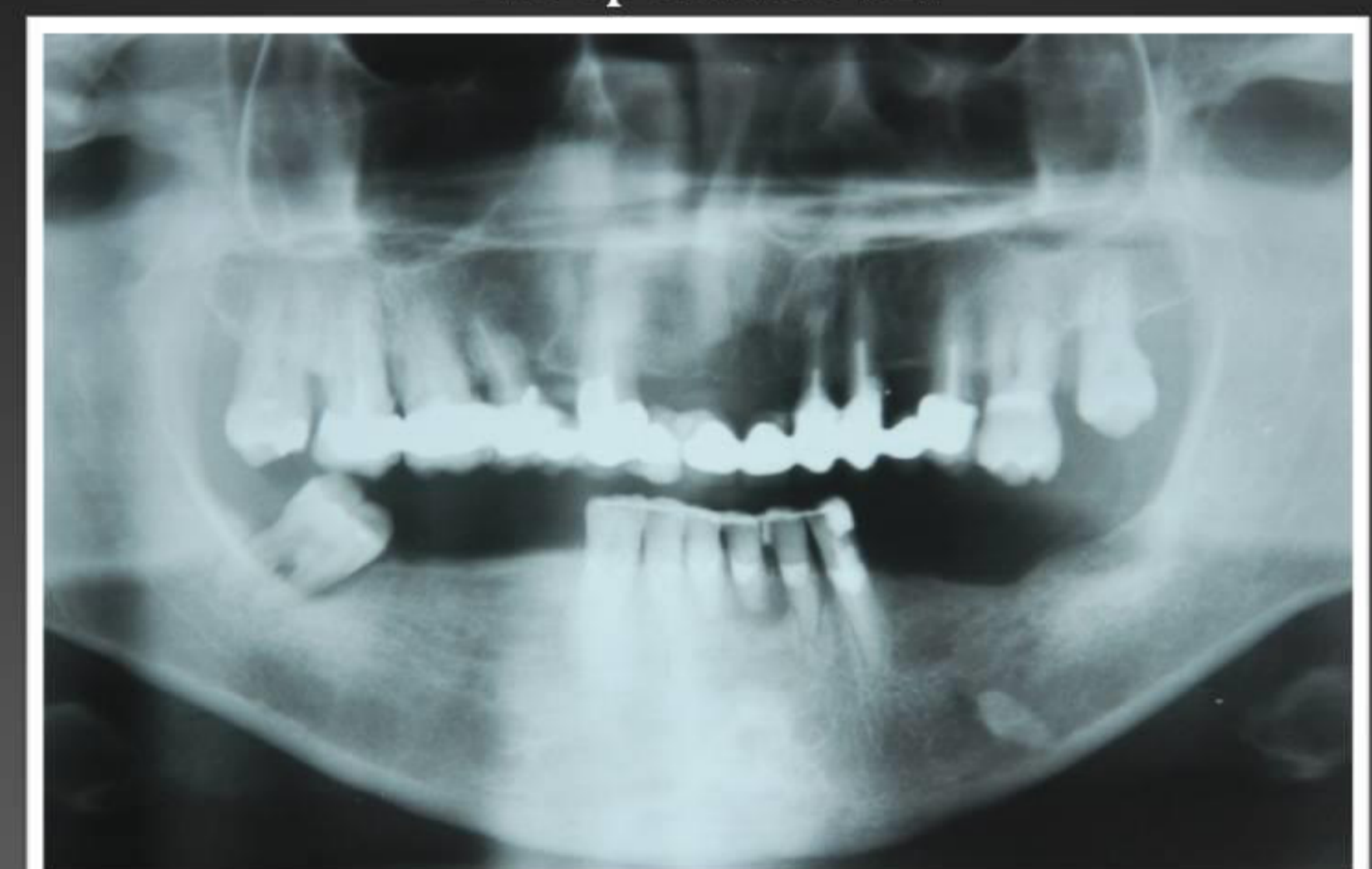


Final Rx



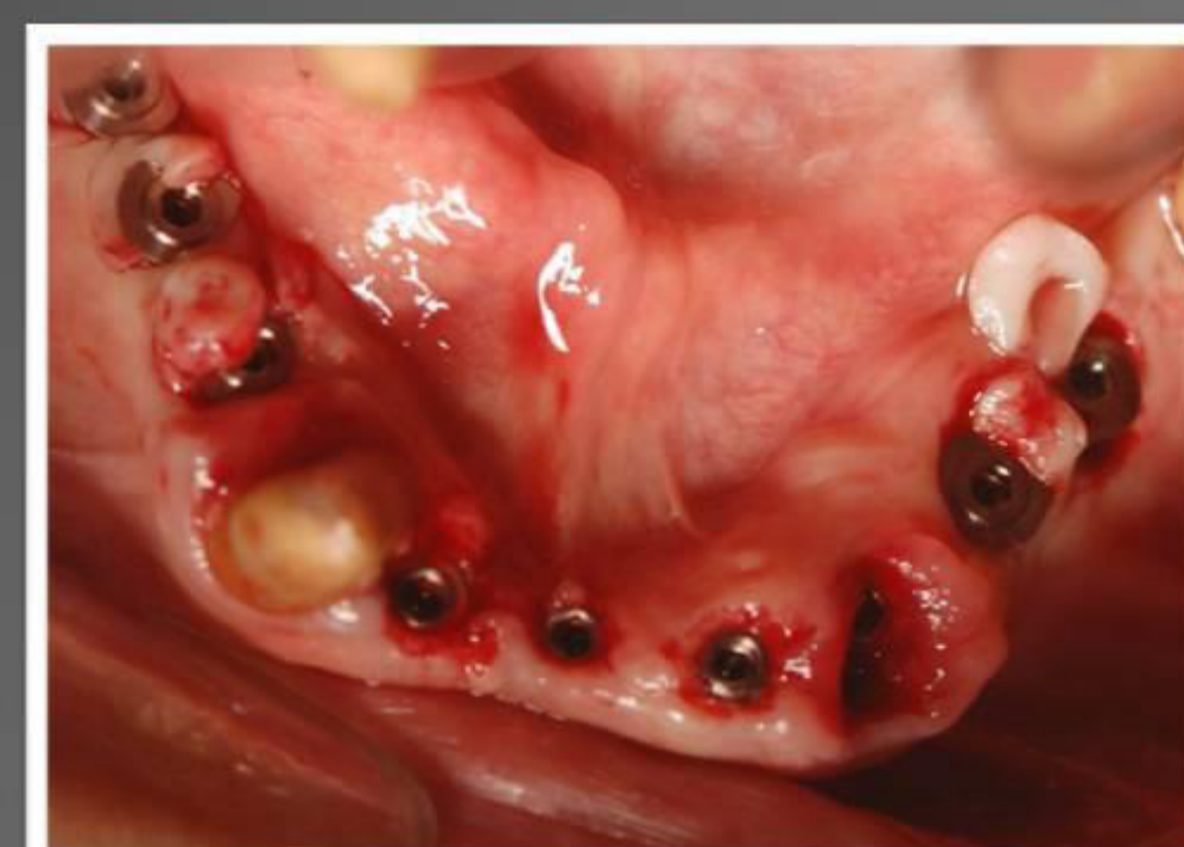CASE 2

Preoperative Rx

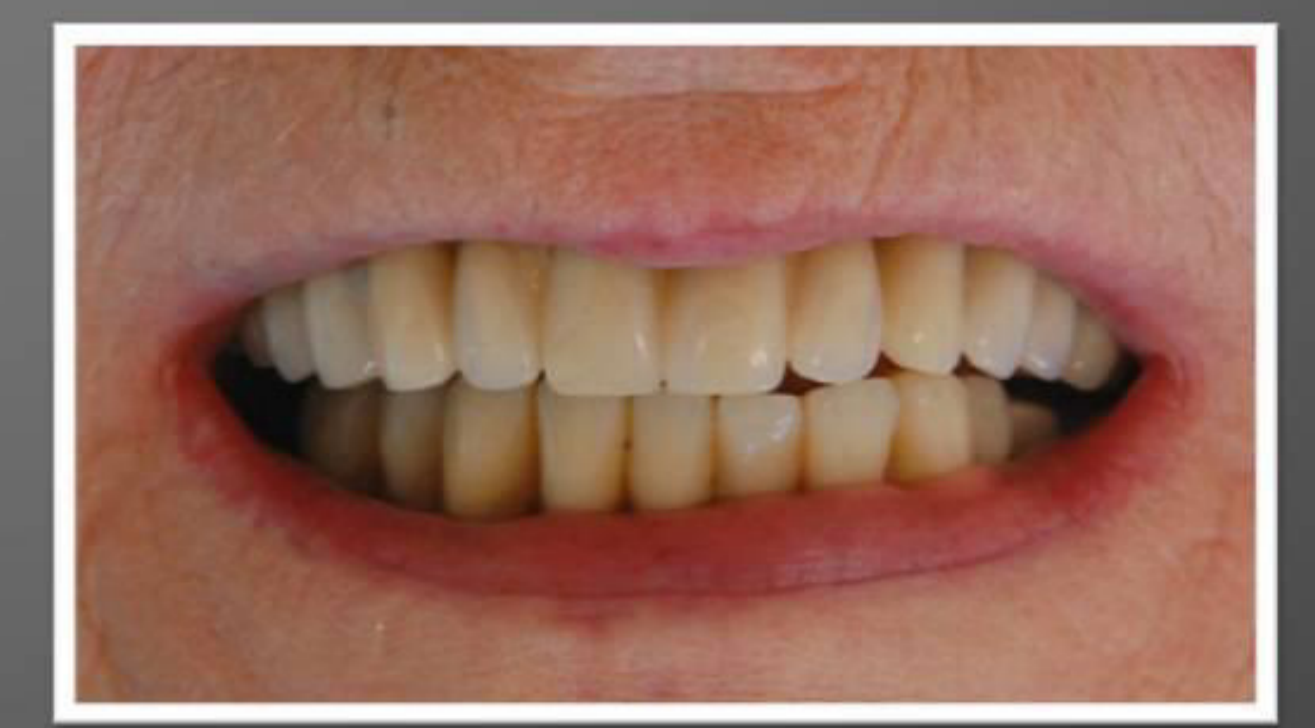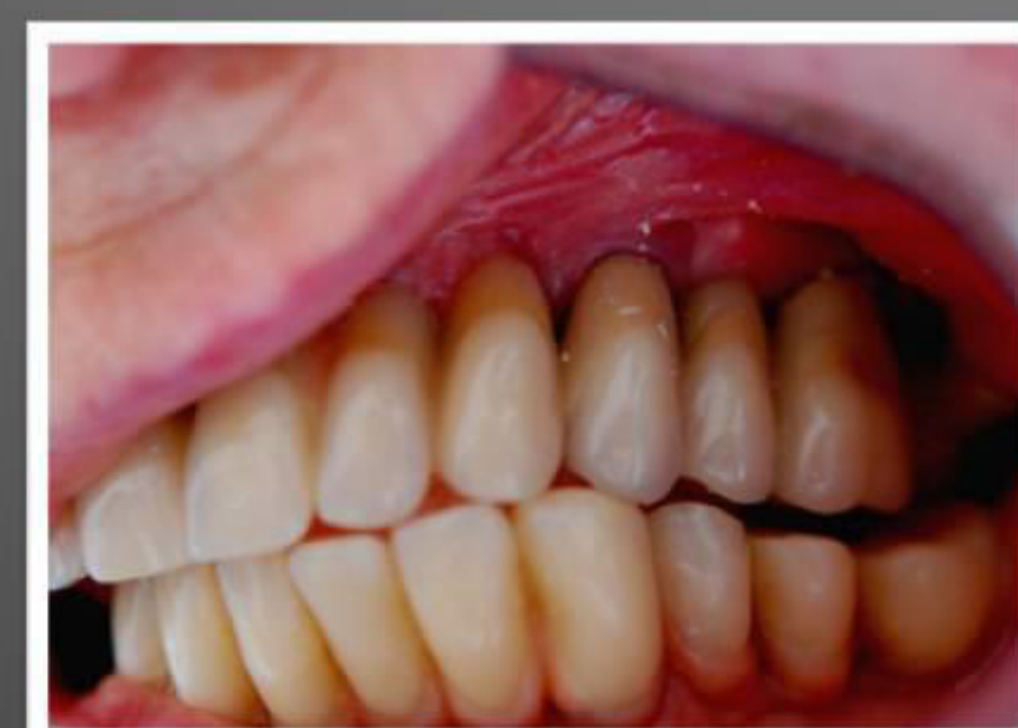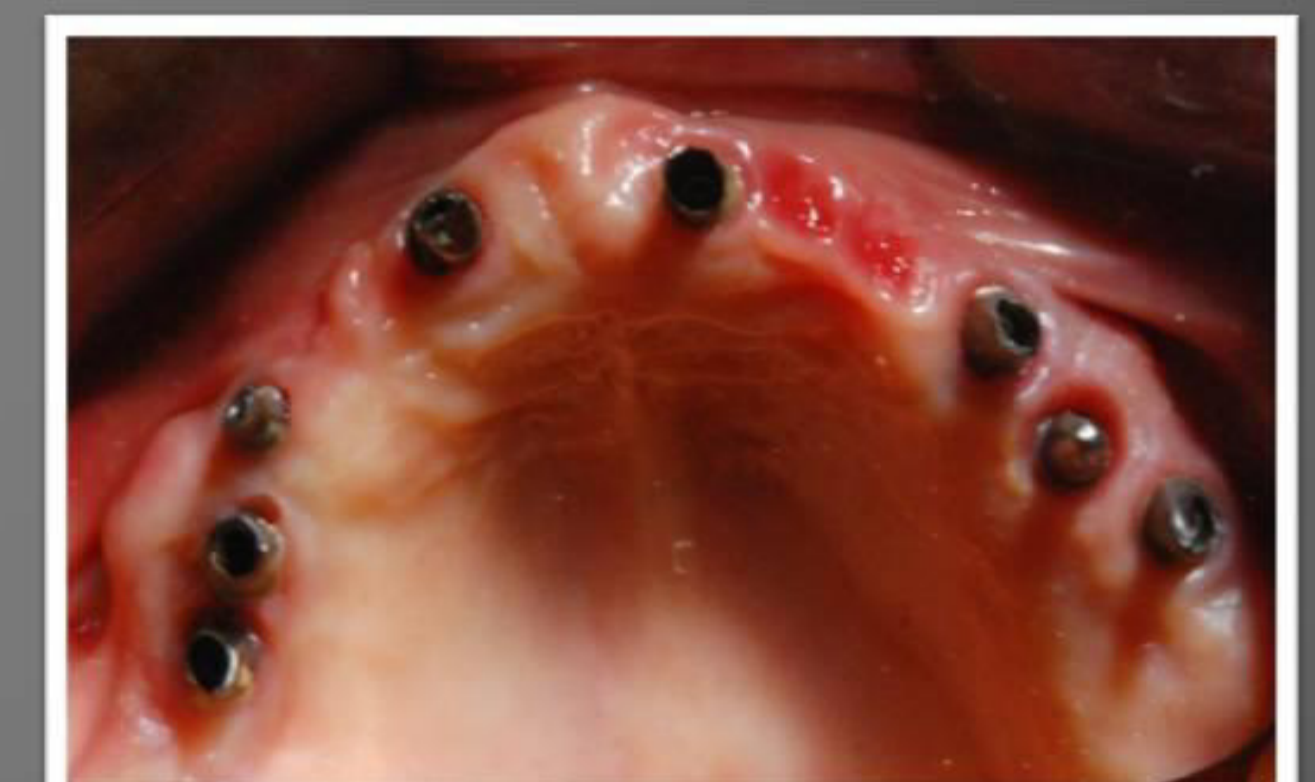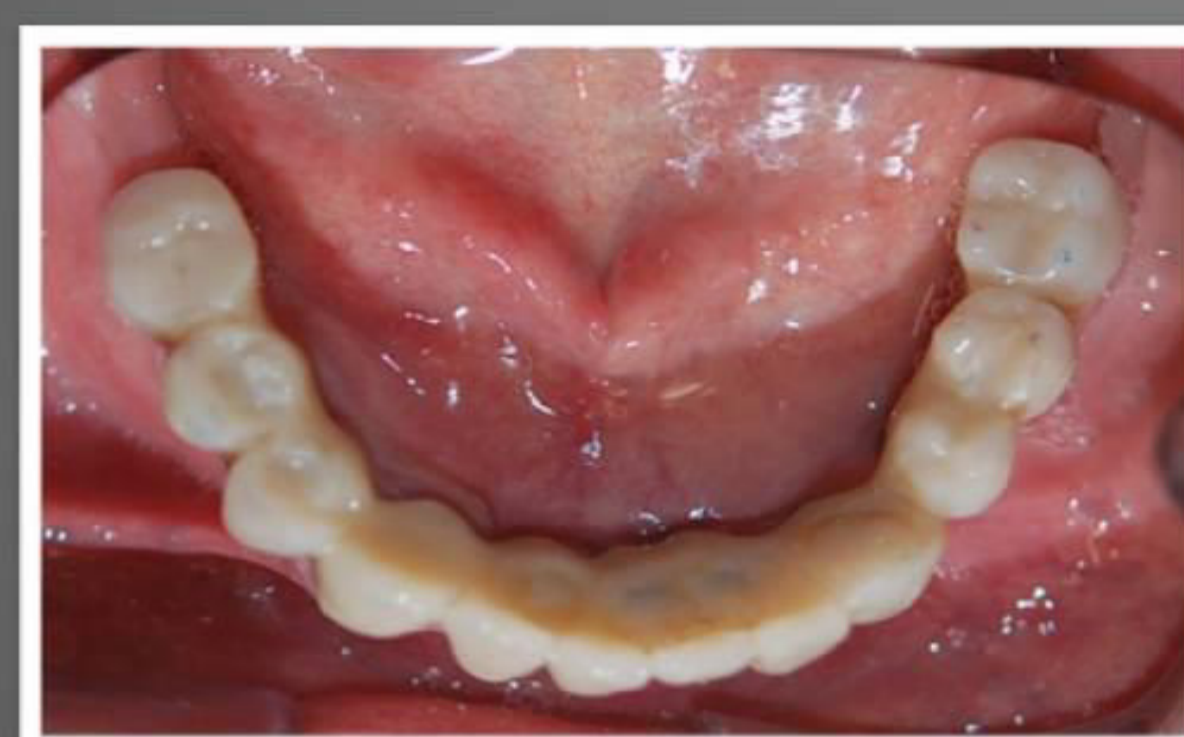
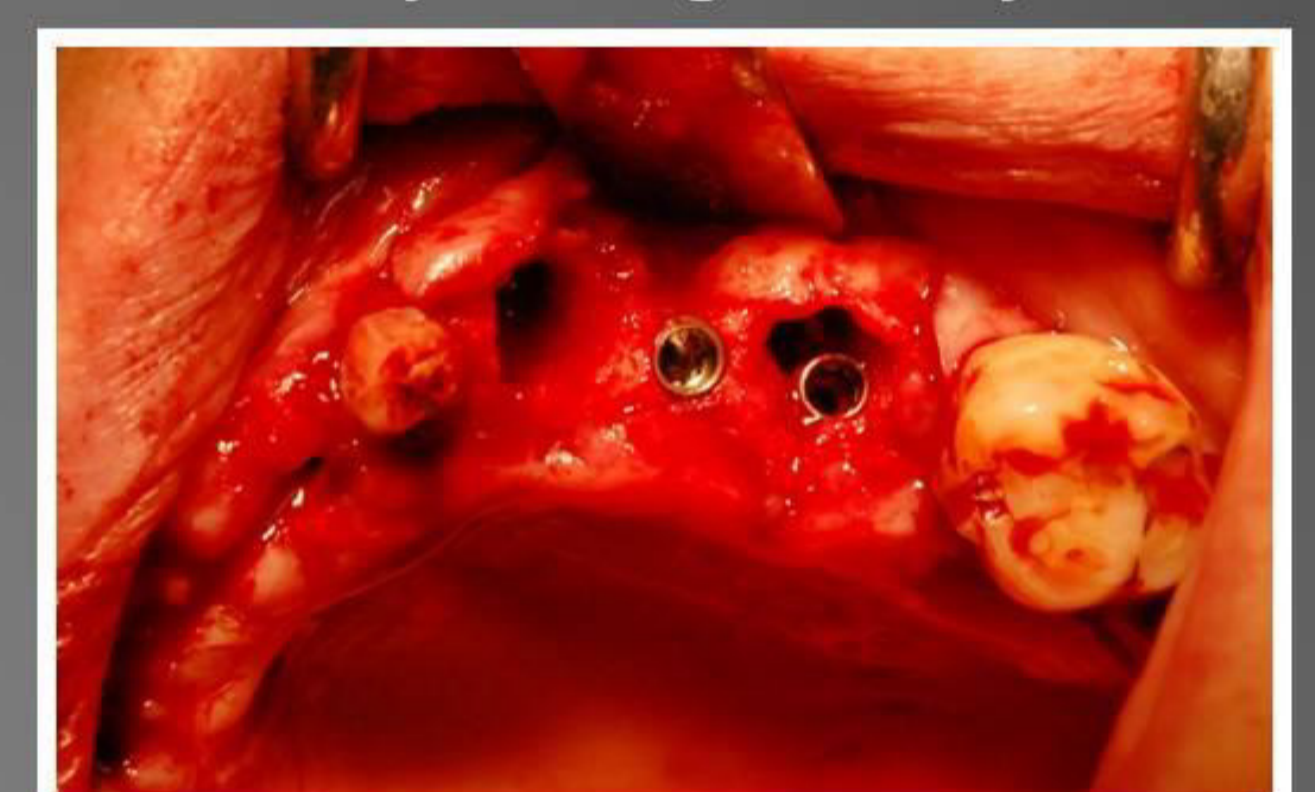


Surgery

Mandibula
Immediate Loading @ 72 h



Maxilla
Early Loading @ 60 days



Final Rx

