

A tapered variable-thread design implant with a 3.0 mm diameter (NobelActive®) placed in the anterior region – Interim results of a multi-center retrospective study with 1 year follow-up

Philippe Russe, DDS¹, James E. Cherry, DMD², Marc Hermans, DDS³, Giovanni Polizzi, MD, DDS⁴,
Nikhil Sisodia, BDS⁵, Luke Villata BDS, MS, MRACDS (Perio)⁶

¹ Private practice, Reims Implant Institute, Reims, France, ² Private practice, Jacksonville, FL, USA,

³ Private Practice, Brussels, Belgium; Department of Implant Dentistry, Université Libre de Brussels, Belgium, ⁴ Private practice, Bränemark Study Center Srl, Verona, Italy,

⁵ Private practice, ten™ – the pavement dental health, London, United Kingdom,

⁶ Private practice, Sydney Periodontics & Implant Centre, Sydney, Australia, School of Dentistry & Health Services, Charles Sturt University, Australia

OBJECTIVES

To retrospectively evaluate a novel narrow diameter implant, (NobelActive, Nobel Biocare, Göteborg, Sweden) with a 3.0mm diameter that has been developed for safe and reliable implant placement in areas with limited space. The 3.0mm implant is intended for replacement of single unit maxillary lateral incisors as well as single unit lateral and central mandibular incisors.

METHODS

Six centers participated in the retrospective study. Twenty-four patients (11 females and 13 males) with a mean age of 31.9 years (range: 18 to 75 years) receiving a total of 29 implants between November 2010 and October 2011 were included in this analysis with a minimum follow-up of 1 year. Implants were placed in healed sites, extraction sites or in sites exhibiting congenitally missing teeth. Implants were inserted either with an open flap or a flapless surgical protocol. All types of loading protocols were applied (i.e. immediate, early or conventional loading). When necessary, bone grafting was performed. Implants were restored according to the manufacturer's guidelines. At routine follow-up, the implants were inspected clinically according to each clinic's standard practice. For some centers this included Jemt's papilla index and bleeding on probing (BOP). Hygiene level was assessed as: excellent, good, acceptable or poor.

RESULTS

Implants

- Twenty-nine implants were placed in 24 patients.
- One implant was lost at 2 months due to trauma (automobile accident).
- One complication, a broken abutment screw was noted.
- Mean follow-up 15.1 months (range 12–24 months).

Table 1: Implant sites	Maxilla (n=21)	Mandible (n=8)
Extraction sites (n=6)	1	5
Healed sites (n=6)	6	0
Congenitally missing teeth (n=17)	14	3

Surgical protocol

- Eight implants were placed using flapless surgery and 21 using a flap.

Table 2: Surgical procedure*	1-Stage, non-submerged (n=15)	2-Stage, submerged (n=11)
Immediate function: within 48 h (n=9)	9	0
Early loading: > 48 h up to 3 months (n=8)	4	4
Delayed loading: >=3 months (n=9)	2	7

* Excluded 3 implants: 2 data not available and 1 lost implant d/t automobile accident.

Soft tissue evaluation

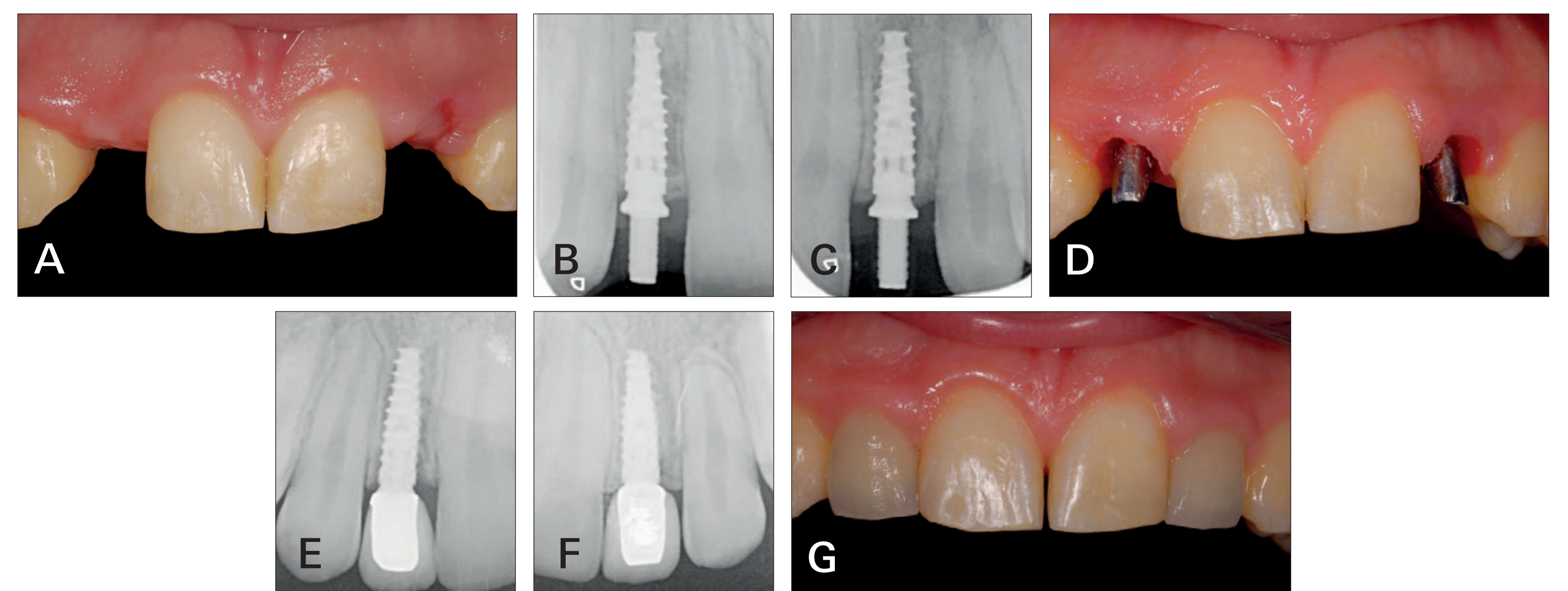
- At follow-up, papilla index was assessed in 21 implants and BOP was assessed in 14 implants.

Table 3: Soft tissue analyses			
Papilla index	n=21	Bleeding on probing (BOP)	n=14
Index 1	1	0 (no bleeding)	14
Index 2	7		
Index 3	12		
Index 4	1		

CLINICAL CASES

Case 1

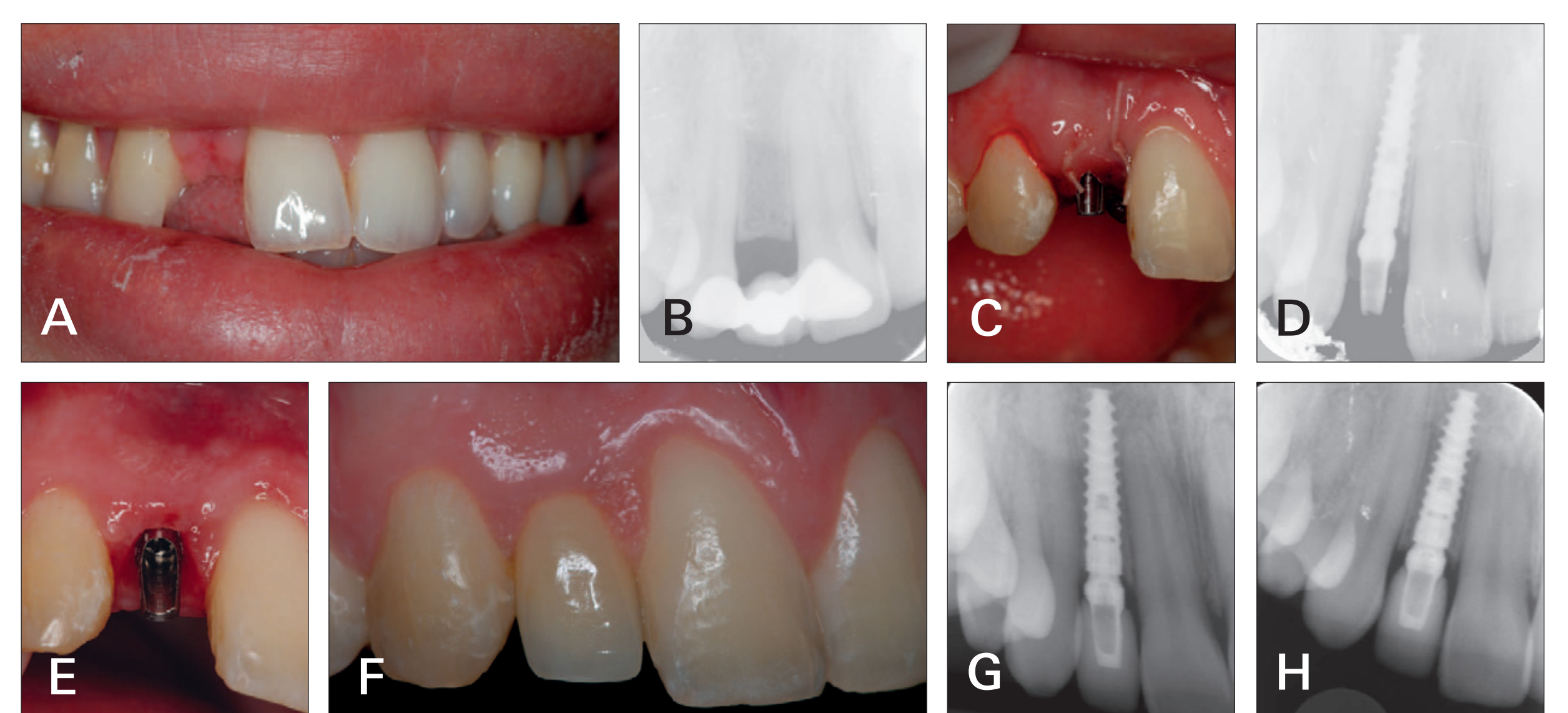
Two 3.0 mm diameter implants (NobelActive) were placed in a 24 year old male patient missing both maxillary lateral incisors. The patient had soft bone, quantity category A (Lekholm & Zarb classification) and oral hygiene was acceptable. A flapless procedure was performed. The implants were placed sub-crestally with an insertion torque of 35 Ncm, using a one-stage surgery and immediate function protocol. Temporary abutments were connected and temporary crowns were cemented the same day.



A) Initial presentation, with healed sites and acceptable hygiene level, **B)** X-ray at baseline taken post-operatively, position 12, **C)** X-ray at baseline taken post-operatively, position 22, **D)** Situation after placement of final abutment (Esthetic Abutment), **E)** X-ray at 1 y follow-up, position 12, **F)** X-ray at 1 y follow-up, position 22, **G)** Final restoration at follow-up.

Case 2

A single 3.0 mm diameter implant (NobelActive) was placed in a 21 year old female patient to treat a congenitally missing tooth at position 12. The patient had soft bone, quantity category A (Lekholm & Zarb classification) and oral hygiene was good. An open flap procedure was performed. The implant was placed crestally, using a one-stage surgery and immediate function protocol.



A) Initial presentation, with a single congenitally missing tooth and good hygiene level, **B)** X-ray at baseline taken pre-operatively, **C)** Post-operative situation, **D)** X-ray at baseline taken post-operatively, **E)** Healing around 15° Esthetic Abutment placed at implant insertion, **F)** Final restoration 6 months after implant insertion, **G)** X-ray 6 months after implant insertion, **H)** X-ray of implant in situ after 20 months.

CONCLUSIONS

Within the limitations of this retrospective study, the results on implant survival and soft tissue analyses with this novel 3.0 mm diameter tapered variable-thread design implant (NobelActive) seem to indicate that this implant is a viable and safe treatment option for subjects in need of an implant in anterior areas with limited space or for the treatment of congenitally missing teeth areas. Additionally, soft tissue evaluation indicates that the implant supports stable tissue.

Acknowledgment(s): With the support of 



To download a copy of this poster to your smart phone.