

Differential diagnosis of single pigmented lesions of the oral mucosa – case series



Diana de Macedo¹, Joana Cabrita¹, Ana Louraço², Filipe Freitas³, João Caramês⁴

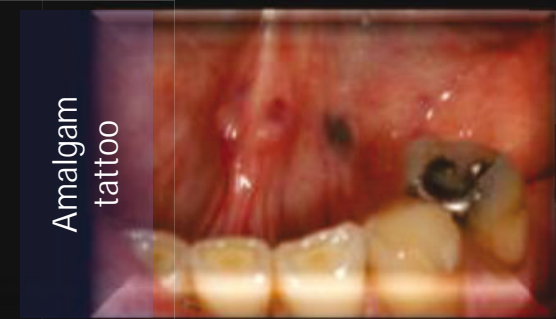Department of Surgery and Oral Medicine, Dental Medicine School, University of Lisbon
¹Student of the Dental Medicine Master Degree; ²Senior Tutor of the Oral Surgery and Medicine Clinic; ³Assistant Lecturer of the Oral Surgery Medicine Clinic; ⁵Senior Professor, Chairman of the Oral Surgery and Medicine Clinic

INTRODUCTION AND OBJETIVES

The color changes in the oral mucosa may correspond to a a great variety of physiological or pathological, benign or malignant and local or systemic entities.

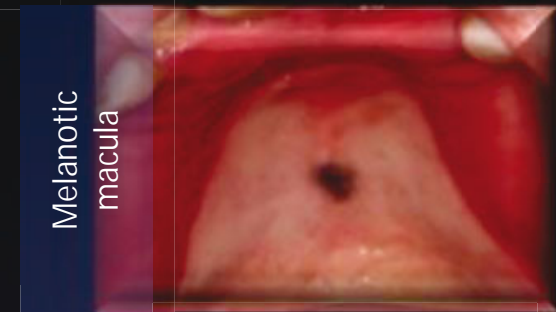
The aim of this communication is to demonstrate through clinical cases which oral pigmented lesions are most relevant in the oral cavity.

DESCRIPTION OF CLINICAL CASES



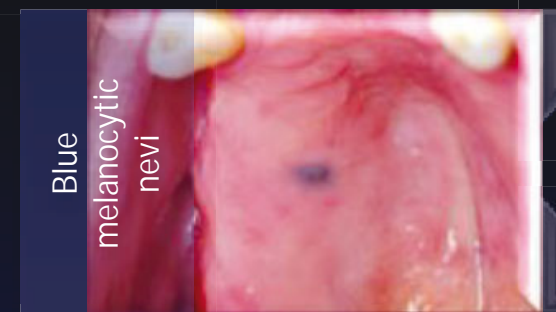
A 60-year-old female patient was observed with a single greyish macular lesion on the oral floor. Excisional biopsy was performed and the pathological examination confirmed the diagnosis of amalgam tattoo.

It is one of the most common causes of intraoral pigmentation. It is clinically a blue-gray lesion with variable dimensions and gingiva and alveolar mucosa are the most common sites (1). The diagnosis is essentially clinical and radiographic, and may, in case of doubt, be performed a biopsy to demonstrate the presence of amalgam particles in the connective tissue (2).



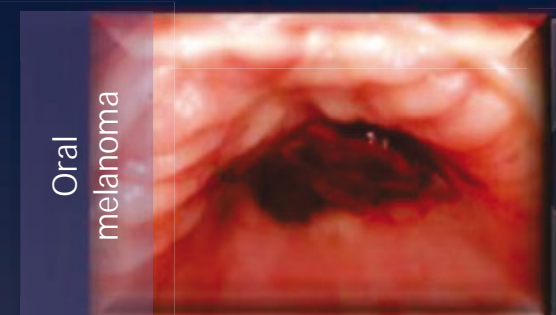
A 13-year-old male patient was observed with a single brown macular lesion on the hard palate. Excisional biopsy was performed and the pathological examination confirmed the diagnosis of oral melanotic macula.

Arises from excessive deposition of melanin (3), provides small and brownish / black color, and it is well circumscribed (1)(4). It is normally required biopsy to establish a correct diagnosis, excluding the possibility of melanoma, especially if the lesion is on the palate or gums, where it is most prevalent. Any further treatment is not required (1).



A 66-year-old male patient was observed with a single bluish macular lesion on the hard palate. Excisional biopsy was performed and the pathological examination confirmed the diagnosis of blue melanocytic nevi.

It is characterized by proliferation of dermal melanocytes that are in depth in the tissue. It is the second most common type of these lesions and appears more often on the palate, as well as melanoma, being fundamental its histological diagnosis after excisional biopsy (2).



A 12-year-old female patient was observed with a single brown macular lesion on the hard palate. Incisional biopsy was performed and the pathological examination confirmed the diagnosis of oral melanoma.

It is rare and most often is presented on the palate and maxillary gingiva. Its therapy is usually a combination of surgery, radiotherapy and chemotherapy (5). It is initially asymptomatic, having a brownish/black clinical aspect with irregular edges. It quickly grows associated with ulceration, bleeding, pain and bone destruction (6).

CONCLUSIONS

The differential diagnosis of oral pigmented lesions is usually a major challenge to the dentist. A biopsy is a valuable tool in establishing the definitive diagnosis, essential for the implementation of the appropriate therapy.

REFERENCES

- 1.Kauzman A PMBNBG. Pigmented Lesions of the Oral Cavity: Review, Differential Diagnosis, and Case Presentations. Journal of the Canadian Dental Association. 2004 November; 70: p. 682-3.
- 2.Tarakji B UAPDAM. Diagnosis of oral pigmentations and malignant transformations. Singapore Dental Journal. 2014; 35: p. 39-46.
- 3.Gaeta G SRBA. Oral Pigmented Lesions. Clinics in Dermatology. 2002; 20: p. 286-288.
- 4.Bragni-Carlos R CENAMTAVPJLJAO. Oral melanoacanthoma and oral melanotic macule: a report of 8 cases, review of the literature, and immunohistochemical analysis. Medicina Oral, Patologia Oral y Cirurgia Bucal. 2007; 12: p. 374-9.
- 5.Meleti M LCMWVPWI. Oral malignant melanoma: a review of the literature. Oral Oncology. 2007; 43: p. 116-121.
- 6.Gondak RO SJRJLMVP. Oral pigmented lesions: Clinicopathologic features and review of the literature. Medicina Oral Patologia Oral y Cirurgia Bucal. 2012 Nov; 1: p. 919-24.