

Tim F. Wolff, Eik Schiegnitz, Knut A. Grötz

Indication and treatment strategies in antiresorptive risk patients

Summary:

Antiresorptive drug related osteonecrosis of the jaw (ARONJ) develops primarily in patients with bisphosphonate and/or denosumab therapy. The therapeutic indications of these drugs range from patients with osteoporosis to multi-morbid patients with osseous metastases of solid tumors. In addition to reduced bone remodeling, etiology also describes other factors such as changes to the soft tissues, vessels and the immune system. Here, trigger factors such as inflammatory changes in the oral cavity, periodontitis, peri-implantitis or even surgical procedures such as tooth extractions and prosthesis pressure points play a decisive role in the pathological process. If a full dental functional rehabilitation is to be realized, it is crucial to select a treatment regime that considers the least possible risk of developing osteonecrosis. Clearly general dental surgical procedural risks should also be considered. In individual cases functional rehabilitation may also include an implant-supported denture. The possible risk factor for the development of a drug-associated necrosis of the jaw by prosthetic pressure points caused by removable dentures can be reduced by using implant-supported restoration.

Keywords:

bisphosphonate; individual risk; antiresorptive drug related osteonecrosis of the jaw (ARONJ); DGI-evaluation chart; dental implant insertion; current state of the guidelines

Zahnärzte am Rathaus, Am Oberborn 2, 63791 Karlstein am Main: Dr. Tim Wolff, M.Sc.

Clinic for Oral and Maxillofacial Surgery – Plastic Surgery – Universitätsmedizin Mainz, Augustusplatz 2, 55131 Mainz: Dr. Dr. Eik Schiegnitz

Private Clinic Oral and Maxillofacial Surgery Burgstrasse 2-4, 65183 Wiesbaden and Clinic for Oral and Maxillofacial Surgery, Helios Dr. Horst Schmidt Kliniken, Ludwig-Erhard-Str. 100, 65199 Wiesbaden: Prof. Dr. Dr. Knut A. Grötz

Translation: Jacobi Übersetzungen

Citation: Wolff TF, Schiegnitz E, Grötz KA: Indication and treatment strategies in antiresorptive risk patients. Dtsch Zahnärztl Z Int 2019; 1: 16-23

Peer-reviewed article: submitted: 18.03.2018, revised version accepted: 14.06.2018

DOI.org/10.3238/dzz-int.2019.0016-0023

Introduction

Bisphosphonates have been used successfully in medicine for more than 25 years for the treatment of osteoporosis as well as for osseous metastases of solid tumors. The first description of bisphosphonate-associated osteonecrosis of the jaw [BP-ONJ] in 2003 [18] presented doctors and dentists with new challenges and new treatment issues. On the one hand bisphosphonates achieve positive bone balance and thus a reduction of bone resorption through effective inhibition of osteoclast activity. On the other hand, however, they lead to reduced rate of bone regeneration and remodeling, which can lead to osteonecrosis of the jaw under certain circumstances. Osteonecrosis of the jaw similar to that of bisphosphonate-associated osteonecrosis of the jaw, has subsequently been described following the use of other medications. The term bisphosphonate-associated osteonecrosis of the jaw was replaced by the term antiresorptive drug related osteonecrosis of the jaw because this old terminology was based on the commonality of the antiresorptive properties in bone metabolism or the osteoprotective properties factors involved. The terminology of medication-associated osteonecrosis of the jaw (MRONJ) describes the same entity and is used in particular to cover new medication groups, e.g. Bevacizumab (Avastin), whereby these are much more rarely associated with osteonecrosis of the jaw.

The occurrence of ARONJ is usually fostered by intraoral wounds, e.g. inflammatory changes to the oral mucous membrane, periodontal disease, surgical intervention or denture pressure points (Figure 1). An interdisciplinary approach with cooperation between dentists and medical doctors is best adopted to ensure a successful outcome in such cases. Implant support for the prevention of or sustained reduction of denture pressure points on the oral mucous membrane can reduce individual risk for the patient and lead to improved retention and stability of the prosthesis. As any surgical procedure on the jaw of an ARONJ patient entails the risk of later osteonecrosis of the jaw

the risk must be measured against benefit and an individual risk profile analysis carried out.

This article discusses current recommendations in the literature, the classification of risk profiles, and prevention strategies adopted in ARONJ patients undergoing dental implant regimes [33].

Bisphosphonates and anti-resorptive drug related osteonecrosis of the jaw (BPONJ/ARONJ)

Physiological bone metabolism involves a coordinated system of bone resorption and formation processes. The osteoblasts that form the bone substance, the osteoclasts that break it down and the osteocytes that are created, are regulated by different regulatory systems both inside and outside the bone matrix. Stimulation of the osteoblasts leads to bone formation. Stimulation of the osteoclasts, on the other hand, has the opposite effect, leading to continually regulated resorption and formation. "In a steady state the resorption and formation are balanced, which leads to continual renewal of the existing bone tissue (bone remodeling)" [10]. Different pathological situations can substantially disrupt this balance. The most important diseases in this category are osteoporosis, in which generalized negative bone balance occurs, and oncological diseases associated with bone metastases (e.g. mammary and prostate carcinoma) or that occur primarily in the bone tissue (plasmocytom, multiple myeloma). The issue that all these diseases have in common is the progressive instability of the skeletal system with increasing risk of spontaneous fracture and consequences through to paraplegia. Bisphosphonates strive, as a group of medications, to intervene positively into this derailed regulation mechanism.

Bisphosphonates are synthetically manufactured analogs of pyrophosphates and inhibit an enzyme, mainly in osteoclasts. The suppressed enzyme in the osteoclasts then leads to reduced resorption of the bone. The intervention into this regulatory circuit of bone metabolism means that the physiological bone remodel-

ing no longer occurs and the bone-remodeling rate reduces. However the intervention into the regulatory circuit as described above is considered to be the main cause of antiresorptive drug related osteonecrosis of the jaw, in combination with other factors.

The leading symptom of antiresorptive drug associated osteonecrosis of the jaw is exposed bone which may be determined by inspection or palpation with a probe. Further classical symptoms are loose teeth, foeter ex ore, jaw ridge fistula with or without exudation, swelling or spontaneous sensitivity disorders of the lower lip (Vincent symptom). A patient's existing or intermittent pain should not be considered as a principal symptom. This is rather an expression of the (super) infection and frequently characterized by additional pus exudation.

The monoclonal IgG2-Anti-RANKL antibody denosumab (trade name: Prolia or X-Geva) is also associated with the formation of osteonecrosis [6]. Denosumab also intervenes in the bone metabolism by deactivating a protein that normally activates osteoclasts, precipitating osteoclast inhibition. Denosumab and bisphosphonate therapy produce a similar incidence of osteonecrosis in ARONJ, oncological and osteoporosis patients [22, 27].

Treatment of primary and secondary osteoporosis as well as supportive therapy for oncological diseases are the main indications for antiresorptive agents. These include:

- multiple myeloma (or plasmocytom),
- the osseous metastases of solid tumors, whereby mammary carcinoma and prostate carcinoma are the main indication here,
- primary (usually postmenopausal) osteoporosis,
- secondary (usually therapy-induced) osteoporosis,
- Paget's disease.

Probably the most frequent treatment with antiresorptive agents is for primary osteoporosis with oral bisphosphonate medication or intravenous dose just once a year. Cases of secondary osteoporosis or malign diseases without bone metastases usually indicate intravenous adminis-

tration 2 to 4 times a year [6]. Osseous metastases and multiple myeloma, however, require increased medication commonly with one intravenous therapy every 4 weeks [1, 30].

Besides the above antiresorptive agents several other medications are also now suspected of being able to trigger osteonecrosis of the jaw. The only secured data on the subject is on the prevalence of osteonecrosis of the jaw with the angiogenesis inhibitor bevacizumab, which (without accompanying bisphosphonate medication) is 0.3–0.4 % [11]. However the combination of an angiogenesis inhibitor such as bevacizumab or sinitinib with bisphosphonates reveals an ONJ risk elevation of 16 % [3].

Further case reports for triggered osteonecrosis of the jaw exist for the medications trastuzumab (trade name: Herceptin) and aflibercept (trade name: Zaltrap) [19, 20, 37]. It is not currently possible to make a statement on the prevalence for these medications.

Therefore, the group of antiresorptive agents and the individual medication Alvestin are important and must be included in the dentist's medical history record.

Definition and prevalence of the antiresorptive drug related osteonecrosis of the jaw

The special aspect of the patient group with using antiresorptive agents is not explained wholly on the basis of the prevalence rates but rather with the knowledge that there

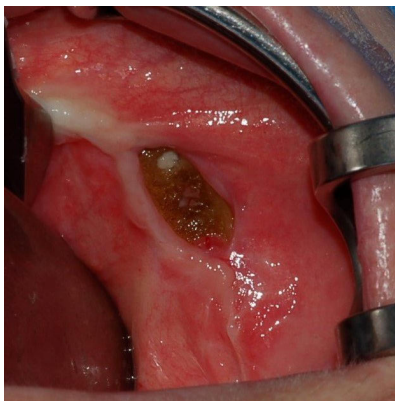


Figure 1 Exposed bone around lower jaw. Typical clinical picture of antiresorptive drug related osteonecrosis.

is a half-life time that can last several years caused by the complex bond of the medication to the hydroxyapatite of the bone that is sometimes extremely long and individually very difficult to estimate. This means that osteonecrosis of the jaw can even develop after years without oral mucous membrane symptoms.

The currently recognized definition of antiresorptive drug related osteonecrosis of the jaw is a combination of 3 symptoms:

- exposed bone for more than 8 weeks (inspection or probe palpation),
 - bisphosphonate, denosumab medication or intake of another corresponding medication and
 - a lack of head/neck radiotherapy in the medical history [18, 24, 25].
- Patient risk susceptibility to ONJ is variable. In order to determine the individual risk of each person we must first differentiate the risk according to literature-based rates of osteonecrosis of the jaw for three typical groups of patients that are described in the guideline on bisphosphonate-associated osteonecrosis of the jaw (BP-ONJ) and other medication-associated osteonecrosis of the jaw [6]:

- Low risk profile: 0.1 %
 - With primary osteoporosis (usually oral alendronate, more rarely zoledronate 5 mg i.v. every 12 months or 60 mg denosumab every 6 months)
- Moderate risk profile: 1 %
 - With therapy-induced osteoporosis (e.g. zoledronate 4 mg every 6 months or denosumab) or with prophylactic administration without bone metastases
- High risk profile: 4 to 20 %
 - With oncological indications with bone metastases or with plasmocytom (e.g. zoledronate 4 mg or denosumab 120 mg every 4 weeks) [6].

This categorization of patients into a low, moderate or high-risk profile is very helpful but only represents an initial approach to the evaluation of the individual's risk profile. This comprises [23, 31, 32]:

- The selected bisphosphonate preparation (non-amino versus amino-BP),

- The method of application (i.v. versus oral intake),
- The dose and number of individual doses,
- The therapy duration,
- The underlying disease (oncological versus non-oncological),
- Further medication and therapies (e.g. chemo, cortisone, anti-angiogenic or radiation therapy),
- Other risk factors (e.g. diabetes mellitus, nicotine abuse, other underlying diseases etc.),
- Local infection entry sites (periodontitis, oral hygiene with any injury to the oral mucous membrane, surgical intervention, denture pressure points).

A so-called 'routing slip' has been developed in order to simplify this very complex evaluation of the individual's risk profile for the dentist and to improve the necessary, interdisciplinary communication between the doctors prescribing the antiresorptive agents. Use of this slip is also recommended in the S3 guideline [8]. It includes the patient's underlying disease, the type of medication and any other oncological therapies (chemotherapy, radiation therapy, immune or antibody therapy or cortisone therapy) and can be implemented individually.

Etiology and pathogenesis of antiresorptive drug-related osteonecrosis

Multiple factors are assumed in the development of ARONJ [12, 35]. Besides the reduced bone remodeling rate described above the medication that is used has a differing level of influence on the gingiva. This involves fibroblast, keratinocyte and vessel cell functions.

It has become apparent that infections in the jaw area are possible trigger factors. These include gingivitis, periodontitis and dentito difficilis. The literature also reveals that tooth extraction, injury to the oral mucous membrane from denture pressure points, sharp bone edges, defective cleaning or biting inter alia, have a strong influence on oral bacterial populations.

Several studies support the assumption that there is a direct correlation between having untreated or

exacerbated periodontitis and the development of osteonecrosis of the jaw [21, 26, 28, 29]. Thus patients with bisphosphonate-associated osteonecrosis of the jaw usually have fewer teeth than corresponding control groups and greater quantitative (more teeth) and qualitative attachment loss (more severe affliction) [28, 36]. The same evidence exists for the important triggers 'denture pressure point' and 'tooth extraction without safety provisos'. It is important that the infection is manifest in the soft tissue (including the parodontium) or that the bacterial population is in the bony embedding tissue at the 'integumental perforation' (pressure point) or open soft tissue bone wound (extraction alveolus). This does not then cause passing osteitis or osteomyelitis, in contrast to infected osteoradionecrosis or more rarely sequestration in chronic osteomyelitis, but rather to the bone directly entering necrosis (Figures 2–5).

Primary importance is placed on all measures to avoid an ONJ before beginning antiresorptive therapy (ONJ prophylaxis) or during or after AR therapy (ONJ prevention). The cooperation of dentist, doctor and patient are required for a successful outcome.

A 2016 study involving 192 inter-nists, orthopedists and pediatricians in Seoul were interviewed on ARONJ, the prophylaxis, prevention and therapy. 22 % of those questioned were not aware of osteonecrosis as a disease. Only less than 30 % refer for oral prophylaxis/prevention measures [14]. The central point is that 78 % of those questioned were aware of the ONJ problem but still only approximately 30 % initiated an ONJ prophylaxis! The aim was to alert this almost 50 % of those questioned so that they refer the patient to the relevant dentist before AR therapy. This study reveals the major issue that osteonecrosis cannot be prevented if the dentist is aware of the disease but the patient is still not provided with information by the doctor treating him or her.

ONJ Prophylaxis

This is why prophylaxis for osteonecrosis of the jaw is carried out prior to

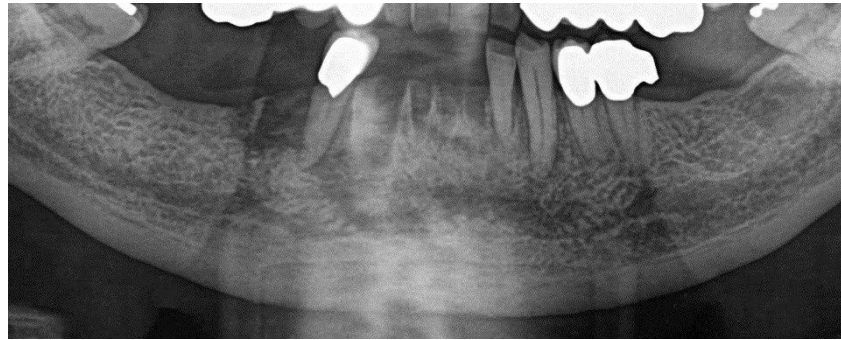


Figure 2 Part of an OPTG. The extraction sockets and osteolytic processes in the lower jaw front and region 45 are clearly visible.

therapy with antiresorptive agents. It should be noted that the measures listed correspond to standard dental prophylaxis and are not a special therapy for bisphosphonate patients [6]:

- Extraction of teeth and implants that cannot be saved or are not worth maintaining,
- Rehabilitation of infections in recesses by beginning systematic periodontal therapy on teeth with periodontal disease that are worth maintaining (this can also be continued in parallel to the beginning of the BP therapy),
- Beginning a systematic peri-implantitis therapy on implants that are worth maintaining (this can also be continued in parallel to the beginning of the BP therapy),
- Removal of partially retained teeth with chronic pericoronitis,
- Removal of cysts, foreign bodies and other enossal chronic sources of infection,
- Root tip re-sectioning only with clinically symptomatic apical periodontitis (caution: a radiological finding alone for apical osteolysis is not an indication of WSR because of the reduced rate of bone remodeling in these patients!),
- Root canal treatment on non-vital teeth without root treatment,
- Rehabilitation of existing and avoidance of future entry points for pathogens by treating existing pressure points (modification of dentures),
- Reduction of the risk of pressure points by adapting the prosthesis base, smoothing sharp bone edges, exostoses and tori with relevant

risk for future mucous membrane perforation,

- Motivation and instruction relating to above average oral hygiene,
- Classification of the patient in a risk-adapted recall program.

Achievable oral hygiene should be taken into account for all the recommendations to the patient. Of course optimum results in domestic oral hygiene should be exhausted and the patient re-motivated in the course of the treatment or at check up appointments. However, limitations of oral hygiene because of possible general disorders (e.g. rheumatoid arthritis, Parkinson's disease or a condition following a stroke) must also be considered in the approach to and assessment of the value of maintaining teeth with existing periodontal disease. If the patient is not capable of appropriate oral hygiene even after implementing all possibilities then he or she should be classified as a high-risk patient for the formation of osteonecrosis of the jaw.

Following the confirmation of any necessary surgical intervention in this group of patients, subsequent ONJ risk factors should be considered and balanced against the consequences of non-action. For example, degree of dental/periodontal pathology and their likely consequences versus risk of ARONJ.

Tegumental denture pressure points represent a further risk factor that could also trigger the occurrence of osteonecrosis [34]. The insertion of implants is a good way to reduce the risk of a denture pressure point by avoiding tegumental dentures. However, implants per se do represent a

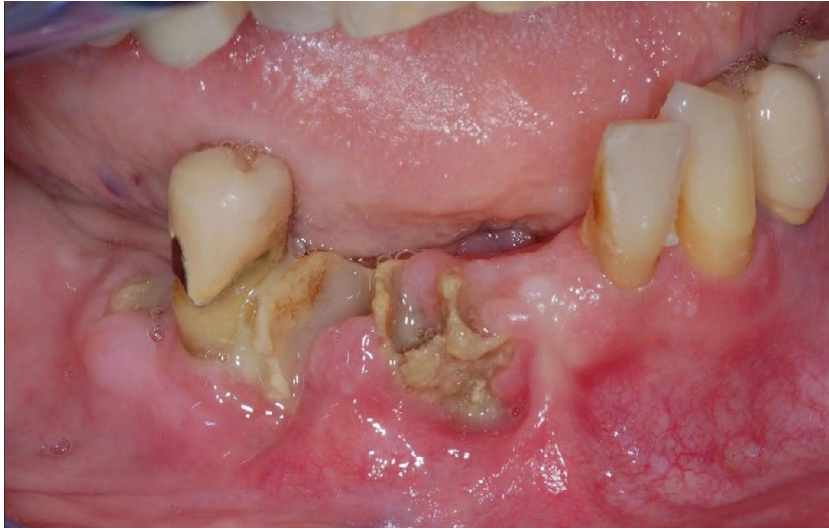


Figure 3 The corresponding enoral clinical picture. Exposed bone at the alveoli with a putrid superinfection show the enoral status.

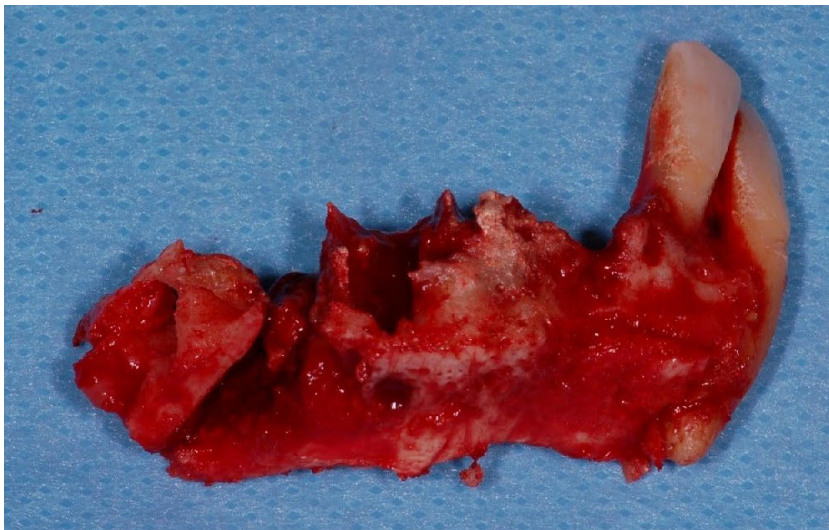

Figure 4 Resectate of the lower jaw with partial greyish-green bone necrosis.

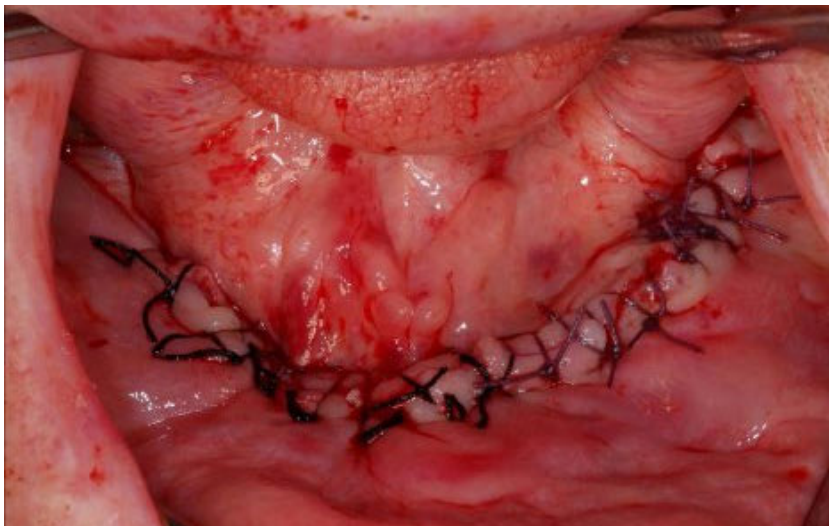


Figure 5 Condition after resection and smoothing of the sharp bone edges in the lower jaw with plastic covering.

risk for the development of osteonecrosis of the jaw [34] from possible periimplantitis or intervention following antiresorptive agent therapy.

Precautionary measures for tooth removal

As with other patients, a necessary tooth extraction should not be long delayed in risk patients. A number of defined safety measures exist in order for the intervention to take place with as few problems as possible:

- A prolonged, peri-operative, systemic antibiotic prophylaxis at least from the day before the operation and until the clinical signs of bacterial load abate. Here the antibiotic Amoxicillin, 1 g is recommended 3× daily, or (in the case of a penicillin allergy) Clindamycin 600 mg 3× daily.
- Minimally invasive operations and atraumatic procedures (avoiding thermal or mechanical lesions in the bony tissue),
- Careful removal of the sharp bone edges (modeling osteotomy), particularly in order to prevent secondary perforation of the mucosa. It should be noted here that a flap opening or formation of a flap is still necessary for 'simple' tooth extraction. Minimally invasive piezosurgery has established itself for the additional, atraumatic smoothing of the sharp bone edges.
- Primary, plastic cover of the defect with tension-free wound closure.

Antiresorptive agents and implants

A new guideline was published in 2016 entitled 'Tooth implants during medical treatment with bone antiresorptive agents (including bisphosphonate) [33] in order to help both the patient and his or her doctor/dentist with this issue.

Risk evaluation is the primary factor to be considered in functional rehabilitation involving antiresorptive agent therapy as described above. A risk evaluation sheet with traffic light classification has been developed and commissioned by the German Association for Implantology. in order to simplify risk assessment for surgeons. The risk assessment consider underlying disease, antiresorptive medication

dosage dynamics, oncological considerations bone remodeling dynamics. The relevant ONJ risk is classified as 'low = green', 'moderate = yellow' or 'high = red' [5].

Particular significance is given to the radiological diagnosis of a 'persistent alveolus'. Radiological changes in the panoramic tomography that are induced by the antiresorptive agent therapy can mean that an unhealed alveolus in the x-ray can be taken as a very low level of bone regeneration [4]. The clinical and radiological healing process of alveolus should therefore be included in the evaluation of a possible implant procedure [33].

A difficult but necessary factor involving all patients with underlying oncological diseases is the prognosis *quoad vitam*. The participation of the patients oncologist should be sought in this respect [33].

The implant indication should also be checked with regard to whether the risk of osteonecrosis can be lowered through the insertion of implants by avoiding denture pressure points and therefore reducing the stress on the mucous membrane [33]. The degree to which the peri-implant embedding tissue needs to be improved with bone augmentation procedures will determine the risk of a wound healing disorder, of osteonecrosis and the possible failure of implants.

A table from the guidelines: 'Dental implants during medication with bone resorptive agents (including bisphosphonate)' [33] provides a good summary of implant indication (Table 1). The attending dentist or physician can also go through the algorithm to reach a decision for or against an implant together with the patient.

If the above aspects are observed and the patient is classified in the correct risk group then implantation in antiresorptive agent patients is promising. Past studies and meta-analyses and evaluation of the literature show implant survival rates of 95–100 % [7, 16] or 86 % [13]. While most studies were carried out with patients with primary and secondary osteoporosis and involved concurrent oral bisphosphonate medication, it

Arguments in favor of an implant	Arguments against an implant
Low risk of osteonecrosis	High risk of osteonecrosis
No osteonecrosis in personal medical history	Existing/prior osteonecrosis
Good oncological prognosis	Poor oncological prognosis
No source of infection	Existing source of infection
Clinically no sharp bone edges, radiologically no persistent alveoli	Clinically and radiologically poor bone remodeling and poor bone remodeling rate
Good compliance	Poor compliance
Good oral hygiene	Poor oral hygiene
Avoidance of denture pressure points	No avoidance of denture pressure points
High strength of indication	Questionable necessity of an implant or equivalent conventional prosthetic replacements possible
No augmentation necessary	Augmentation necessary

Table 1 Overview and summary of implant indication in antiresorptive agent patients. From S3 guideline: „Dental Implants in Medicinal Treatment with Bone Antiresorptive agents (Including Bisphosphonates)“ [33]

should be noted that subjects involved had a rather lower risk to develop osteonecrosis. Two systematic reviews from 2013 show no absolute contraindication for implant therapy in oral or intravenous bisphosphonate therapy [2, 9].

Patients must be informed at the end of the pre-operative phase. The patient should be informed of the individual risk of osteonecrosis prior to the planned implant insertion. This information should also include alternatives to the therapy, the advantages and disadvantage and the necessary structured aftercare, along with a note of these subsequent costs. Two central points should be discussed with patients: the risk of osteonecrosis from a dental operation, i.e. the implantation itself, and the possible future risk of periimplantitis. Studies currently show that the risk of periimplantitis, i.e. of bacterial population of the gingiva and the embedding tissue around the implant, is seen as a significant factor in

causing osteonecrosis of the jaw compared to the risk of the implantation itself. As several implants need to be inserted in order to avoid a removable denture the consequent prophylaxis and aftercare for the implants is one of the central points for the patient and the dentist [15, 17, 28, 34]. Regular aftercare is essential for dentures mounted on implants. The focus here is on correct fit, particularly of small denture saddles in the distal area. This could also lead to pressure point-associated necrosis with an imprecise fit.

Surgical procedure

Surgical intervention on antiresorptive agent patients requires an exact planning phase. There is no resilient data in current literature for a so-called 'drug holiday' around the time of the operation and this cannot be recommended [33].

Implant placement can take place safely if certain safety precautions are observed (including prolonged peri-

operative treatment with antibiotics, a strict diet of liquid or soft food, a minimally invasive operation). The peri-operative, systemic antibiotics prophylaxis should be carried on with all antiresorptive agent patients. However, no uniform regime of antibiotics can be recommended. Antibiotic indications must be assessed individually. Analogously to the endocarditis prophylaxis a single dose 30–60 min before the intervention could be sufficient, whereby antibiotic regimes are sometimes started earlier in the literature and given over a period of several days [33]. A prolonged, peri-operative, systemic antibiotic screen has proven effective in clinical practice until clinical signs of germ population have abated after the operation.

Overall conservative treatment regimes dominated with these patients, following assessment of a positive indication for implantation:

- No immediate implantation (together with tooth extractions!),
- No immediate restoration,
- No immediate loading,
- Preference for medium strength primary stability (e.g. thread tapping, avoidance of conicity),
- Preference for regimes to avoid periimplantitis (e.g. angulation, vertical biological width etc.).

There is no reliable data available concerning implant healing. Transgingival healing with initial, possibly lesser contamination of the bone via the larger wound is contrasted with a second intervention when exposing subgingival healing. Healing time following implantation is also based on conjecture. A longer healing time can be assumed, based on the reduced bone-remodeling rate, until the implant is integrated into the bone.

Conclusion

The new guideline ‘Dental implants in the medical treatment with bone antiresorptive agents (including bisphosphonate)’ provides the caregiver with a valuable decision reaching aid. The indication for implant care can be reviewed precisely in combination with a further risk evaluation using the ASORS routing slip and the DGI evaluation sheet. The insertion of im-

plants in antiresorptive agent patients may include functional rehabilitation in certain circumstances and thus probably reduce the risk of the development of osteonecrosis by avoiding denture pressure points. However, further long-term studies are necessary in order to evaluate the probability of success of the implant/denture solution for the patient.

Conflicts of Interest:

The authors declare that there is no conflict of interest as defined by the guidelines of the International Committee of Medical Journal Editors.

Literature

1. Arantes HP, Silva AG, Lazaretti-Castro M: Bisphosphonates in the treatment of metabolic bone diseases. *Arq Bras Endocrinol Metabol* 2010; 54: 206–212
2. Chadha GK, Ahmadih A, Kumar S, Sedghizadeh PP: Osseointegration of dental implants and osteonecrosis of the jaw in patients treated with bisphosphonate therapy: a systematic review. *J Oral Implantol* 2013; 39: 510–520
3. Christodoulou C, Pervena A, Klouvas G et al.: Combination of bisphosphonates and antiangiogenic factors induces osteonecrosis of the jaw more frequently than bisphosphonates alone. *Oncology* 2009; 76: 209–211
4. Groetz KA, Al-Nawas B: Persisting alveolar sockets—a radiologic symptom of BP-ONJ? *J Oral Maxillofac Surg* 2006; 64: 1571–1572
5. Groetz KA, Al-Nawas B: Laufzettel Biophosphonate Risiko-Evaluation bei antiresorptiver Therapie vor Implantation. 2013
6. Groetz KA, Piesold J-U, Al-Nawas B: S3-Leitlinie: Bisphosphonat-assoziierte Kiefernekrose (BP-ONJ) und andere Medikamenten-assoziierte Kiefernekrosen. AWMF 007–091 2012
7. Groetz KA, Schiegnitz E, Wolff TF: Handbuch MKG 2016: MKG-Update 2016 ONKO II: SUPPORTIVE TU-BE-TREUUNG, Wiesbaden 2016
8. Grötz KA: Patientenbezogener Laufzettel „Überweisung/Konsil vor Bisphosphonat-Therapie“, ASORS Arbeitsgemeinschaft Supportive Maßnahmen in der Onkologie, Rehabilitation und Sozialmedizin der Deutschen Krebsgesellschaft, Stand 06/2012, ASORS
9. Grötz KA, Al-Nawas B, Terheyden H: Implantate und Bisphosphonat-Therapie. *Implantologie* 2013; 21: 53–59

10. Grötz KA, Schiegnitz E, Wolff TF: Handbuch ZMK 2015: ZMK-Update 2015 Risikopatienten in der ZMK (inkl. Impl. bei Risikopatienten), Wiesbaden 2015

11. Guarneri V, Miles D, Robert N et al.: Bevacizumab and osteonecrosis of the jaw: incidence and association with bisphosphonate therapy in three large prospective trials in advanced breast cancer. *Breast Cancer Res Treat* 2010; 122: 181–188

12. Hagelauer N, Ziebart T, Pabst AM, Walter C: Bisphosphonates inhibit cell functions of HUVECs, fibroblasts and osteogenic cells via inhibition of protein geranylgeranylation. *Clin Oral Investig* 2015; 19: 1079–1091

13. Kasai T, Pogrel MA, Hossaini M: The prognosis for dental implants placed in patients taking oral bisphosphonates. *J Calif Dent Assoc* 2009; 37: 39–42

14. Kim JW, Jeong SR, Kim SJ, Kim Y: Perceptions of medical doctors on bisphosphonate-related osteonecrosis of the jaw. *BMC Oral Health* 2016; 16: 92

15. Krimmel M, Ripperger J, Hairass M, Hoefert S, Kluba S, Reinert S: Does dental and oral health influence the development and course of bisphosphonate-related osteonecrosis of the jaws (BRONJ)? *Oral Maxillofac Surg* 2014; 18: 213–218

16. Kumar MN, Honne T: Survival of dental implants in bisphosphonate users versus non-users: a systematic review. *Eur J Prosthodont Restor Dent* 2012; 20: 159–162

17. Kwon TG, Lee CO, Park JW, Choi SY, Rijal G, Shin HI: Osteonecrosis associated with dental implants in patients undergoing bisphosphonate treatment. *Clin Oral Implants Res* 2014; 25: 632–640

18. Marx RE: Pamidronate (Aredia) and zoledronate (Zometa) induced avascular necrosis of jaws: a growing epidemic. *J Oral Maxillofac Surg* 2003; 61: 1115–1117

19. Pilanci KN, Alco G, Ordu C et al.: Is administration of trastuzumab an independent risk factor for developing osteonecrosis of the jaw among metastatic breast cancer patients under zoledronic acid treatment? *Medicine (Baltimore)* 2015; 94: e671

20. Ponzetti A, Pinta F, Spadi R et al.: Jaw osteonecrosis associated with aflibercept, irinotecan and fluorouracil: attention to oral district. *Tumori* 2015; 102: S74–S77

21. Pushalkar S, Li X, Kurago Z et al.: Oral microbiota and host innate immune response in bisphosphonate-related osteonecrosis of the jaw. *Int J Oral Sci* 2014; 6: 219–226

22. Qi WX, Tang LN, He AN, Yao Y, Shen Z: Risk of osteonecrosis of the jaw in cancer patients receiving denosumab: a meta-analysis of seven randomized controlled trials. *Int J Clin Oncol* 2014; 19: 403–410
23. Rahimi-Nedjat RK, Sagheb K, Pabst A, Olk L, Walter C: Diabetes mellitus and its association to the occurrence of medication-related osteonecrosis of the jaw. *Dent J* 2016; 4: 1–7
24. Ruggiero SL, Dodson TB, Assael LA, Landesberg R, Marx RE, Mehrotra B: American Association of Oral and Maxillofacial Surgeons position paper on bisphosphonate-related osteonecrosis of the jaws – 2009 update. *J Oral Maxillofac Surg* 2009; 67: 2–12
25. Ruggiero SL, Mehrotra B, Rosenberg TJ, Engroff SL: Osteonecrosis of the jaws associated with the use of bisphosphonates: a review of 63 cases. *J Oral Maxillofac Surg* 2004; 62: 527–534
26. Saia G, Blandamura S, Bettini G et al.: Occurrence of bisphosphonate-related osteonecrosis of the jaw after surgical tooth extraction. *J Oral Maxillofac Surg* 2010; 68: 797–804
27. Smith MR, Saad F, Coleman R et al.: Denosumab and bone-metastasis-free survival in men with castration-resistant prostate cancer: results of a phase 3, randomised, placebo-controlled trial. *Lancet* 2012; 379: 39–46
28. Thumbigere-Math V, Michalowicz BS, Hodges JS et al.: Periodontal disease as a risk factor for bisphosphonate-related osteonecrosis of the jaw. *J Periodontol* 2014; 85: 226–233
29. Tsao C, Darby I, Ebeling PR et al.: Oral health risk factors for bisphosphonate-associated jaw osteonecrosis. *J Oral Maxillofac Surg* 2013; 71: 1360–1366
30. von Moos R: Bisphosphonate treatment recommendations for oncologists. *Oncologist* 2005; 10 (Suppl 1): 19–24
31. Walter C, Al-Nawas B, Frickhofen N et al.: Prevalence of bisphosphonate associated osteonecrosis of the jaws in multiple myeloma patients. *Head Face Med* 2010; 6: 11
32. Walter C, Al-Nawas B, Grotz KA et al.: Prevalence and risk factors of bisphosphonate-associated osteonecrosis of the jaw in prostate cancer patients with advanced disease treated with zoledronate. *Eur Urol* 2008; 54: 1066–1072
33. Walter C, Al-Nawas B, Haßfeld S, Sader R, Ullner M, Groetz KA: Zahnimplantate bei medikamentöser Behandlung mit Knochenantiresorptiva (inkl. Bisphosphonate) – S3-Leitlinie (Langversion), Stand: Juli 2016
34. Walter C, Al-Nawas B, Wolff T, Schiegnitz E, Grotz KA: Dental implants in patients treated with antiresorptive medication – a systematic literature review. *Int J Implant Dent* 2016; 2: 9
35. Walter C, Klein MO, Pabst A, Al-Nawas B, Duschner H, Ziebart T: Influence of bisphosphonates on endothelial cells, fibroblasts, and osteogenic cells. *Clin Oral Investig* 2010; 14: 35–41
36. Walter C, Laux C, Sagheb K: Radiologic bone loss in patients with bisphosphonate-associated osteonecrosis of the jaws: a case-control study. *Clin Oral Investig* 2014; 18: 385–390
37. zm-online (2016): Rote-Hand-Brief für Zaltrap



(Photo: private)

DR. TIM WOLFF, M.SC.
 Zahnärzte am Rathaus
 Am Oberborn 2
 63791 Karlstein am Main
 Wolff.Tim@gmx.de
 www.zahnarzt-karlstein.de