

## Update of the S2k guideline

# Surgical removal of wisdom teeth

The second update of the S2k guideline „Surgical removal of wisdom teeth“ was completed in August 2019. It was originally one of the three pilot guidelines of the German Medical Association (BZÄK) and has now been revised in collaboration with the German Society of Dentistry and Oral Medicine (DGZMK) and the German Association for Oral and Maxillofacial Surgery (DGMKG).

The revision of the guideline was previously added to the list of priority topics by the quality task force, consisting of representatives from the DGZMK, KZBV and BZÄK. Findings from the literature from 2012 to June 2017, the results of an interdisciplinary consensus conference of the various associations (see box on page 235) in Bochum on December 13, 2017, and additional contributions from a Delphi procedure from February 2018 to April 2019 have been included. The guideline updates the status of the recommendations in the following specific areas:

- Indications for removing wisdom teeth and for leaving them in situ
- Significance of CB-CT diagnostics
- Significance of perioperative antibiotic prophylaxis
- Significance of piezosurgery
- Significance of coronectomy
- Selecting the time for extracting the tooth

As in the previous version, the principles for selection of the recommendations are explained in background text, which is included in the long version of the guideline. The text is reproduced here for information.

### Indications for extraction and preserving teeth

The second update still retains basically unchanged the core statement of the guideline, particularly with reference to (dental) medical indi-

cations, possible indications and contraindications with reference to the scientific literature of the period to June 2017.

However, the structured consensus of the expert group has made the following changes:

- a) The „Exposure of pulp by caries“ has been deleted from the group of „Indications for removal of wisdom teeth“ and transferred to the „Possible indications for removal of wisdom teeth“. This has made it correspond to the option of retaining the tooth by endodontic treatment as an alternative.
- b) „Halitosis requiring treatment“ has been added to the possible indications if other treatments for retention of teeth were not successful.
- c) Similar to the indications for removal, the indications for leaving wisdom teeth are classified as indications and possible indications (see box on page 80).

### Background: indications

Traditionally a distinction has been made between clinically or radiologically symptomless and symptomatic teeth in the indications for treatment. While the removal of clinically or radiologically symptomatic teeth is generally approved in the literature, a general recommendation for the removal of clinically symptomless wisdom teeth cannot be justified based on scientific evidence.

However, following more recent investigations the strict division by clinical symptoms cannot be justified without further study. Regardless of the presence of a clinically detectable pericoronitis and radiologically confirmed pericoronal radiolucency, a relevant proportion of wisdom teeth (20 to 60 percent) show pathological changes [Baycul et al., 2005; Blakey et al., 2002; Simsek-Kaya et al., 2011; Yildirim et al., 2008], which may affect the periodontal situation of the adjacent molars and may also have further effects [Blakey et al., 2010]. In addition, a high rate of distal caries must also be expected in adjacent 12-year molars (in the range of 50 percent) as a result of a close spatial relationship to the wisdom teeth [McArdle et al., 2016; Kang et al., 2016]. As a result, a fundamental distinction between removal of wisdom teeth for prophylactic and therapeutic reasons does no longer appear to be justified.

Longitudinal studies show that around 30 percent of wisdom teeth planned for removal at the age of 18 tend to become a regular part of the dentition by the age of 30 [Kruger et al., 2001]. On the other hand, two developments in opposing directions show themselves with increasing age. While the frequency of inflammatory complications reaches a maximum in the age group between 18 and 35 years and then decreases with age

[Fernandes et al., 2009], simultaneously with increasing age complications with surgical extraction tend to increase [Chuang et al., 2007; Baensch et al., 2017].

The benefit of removing wisdom teeth to prevent a tertiary crowding of the anterior teeth in the mandible on conclusion of the orthodontic treatment has been a subject of controversy for a longtime [Linguist & Thilander, 1982; Ades et al., 1990] and is still not fully clarified. A prospective, randomized study did not show a significant influence on tertiary crowding, but the length of the anterior dental arch was significantly reduced if the wisdom teeth were left in place [Harradine et al., 1998]. However, because more than 50 percent of the patients in this study had premolars extracted beforehand, the results cannot be applied to patients with complete dentition.

The primary influences on the likelihood of eruption of wisdom teeth are the retromolar space and premolar extraction [Artun et al., 2005; Kim et al., 2003].

Longitudinal data from the „Veterans Affairs Normative Aging Study“ show a relevant, unfavorable influence of impacted wisdom teeth on the prognosis of adjacent molars over a period of up to 25 years and in particular an unfavorable influence on the distal periodontal situation [Nunn et al., 2013]. The current Cochrane Review (CD003879: Surgical removal versus retention for the management of asymptomatic disease-free impacted wisdom teeth) with reference to inadequate „evidence“ according to the criteria of the Cochrane methodology refers to consulting with the patient to reach a decision subject to clinical experience.

### Tooth resorption:

The evaluation of resorption at the distal radix of second molars is extremely uncertain due to the superimposition by impacted teeth in the conventional panoramic image. The increased use of DVT imaging means that resorptions on 12-year molars are likely to be detected more often and will have to be considered when deciding whether to remove wisdom

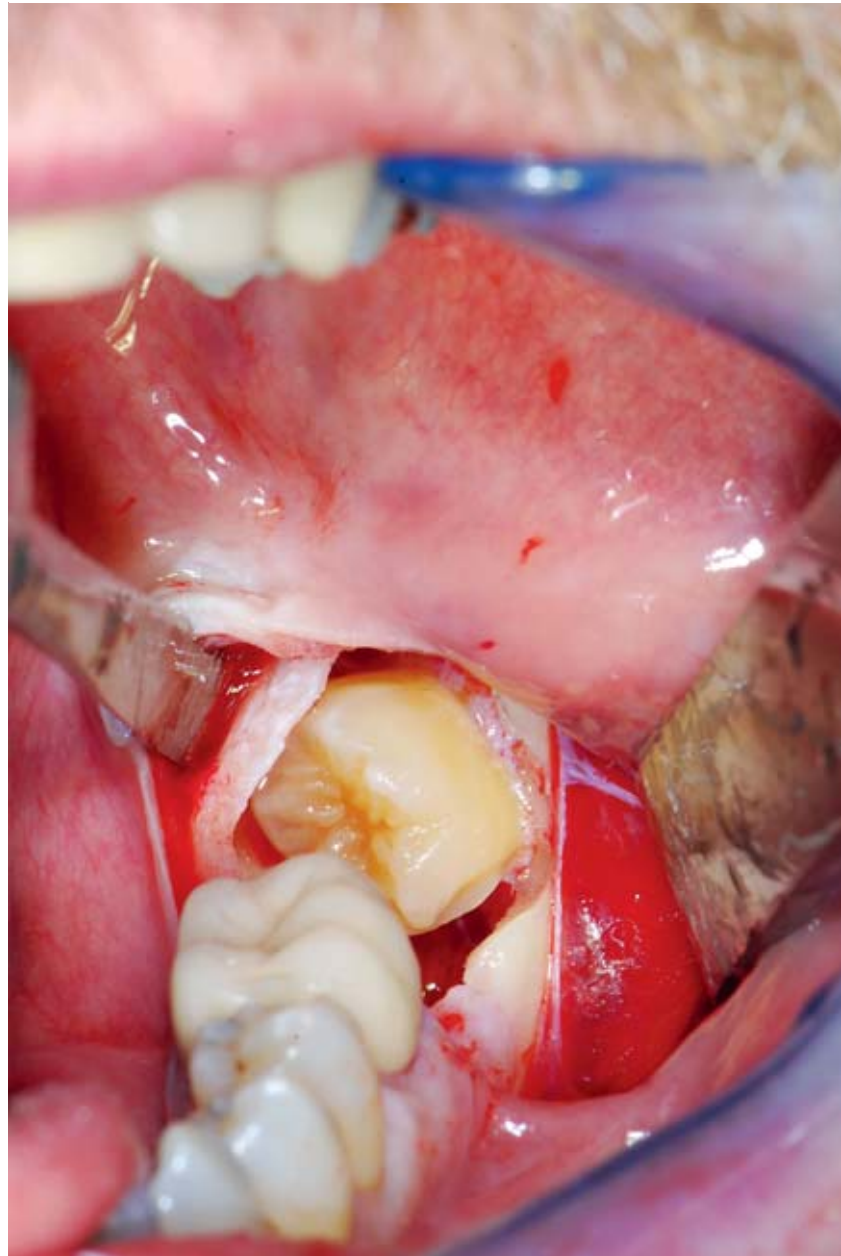


Photo: M. Kunkel

**Figure 1** Surgical site after uncovering of a wisdom tooth surrounded by pericoronal cysts

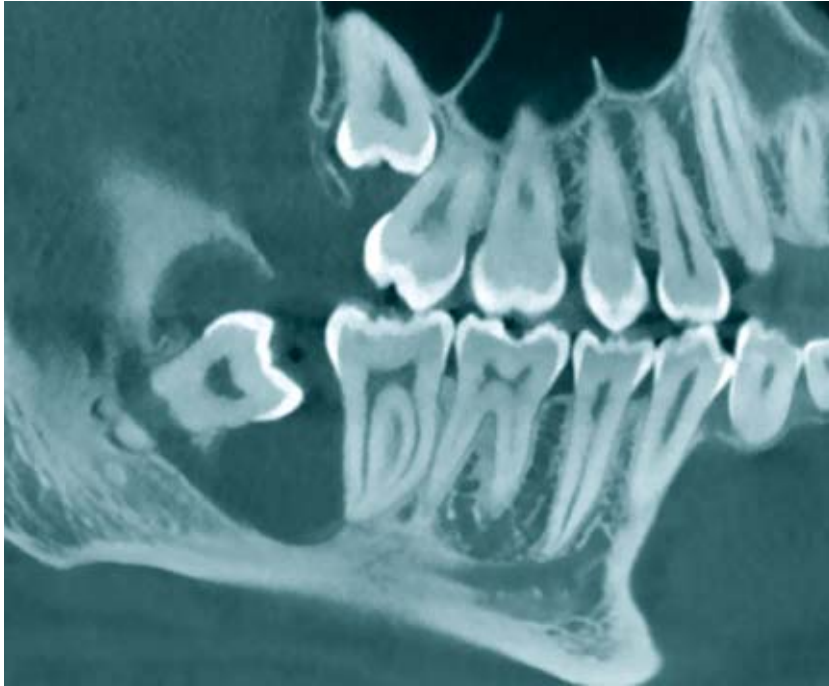
teeth. Epidemiological data on the frequency are still not available, but patient series with a prevalence of 20 % with horizontal and mesioangular inclined third molars lead to the expectation that the problem of external resorption will have a more prominent place in deciding the treatment in future [Oenning et al., 2014; Oenning et al., 2014; Wang et al., 2017]. For example, in the case of resorption at the distal root of the 12-year molar, it would be possible to remove or if applicable reposition the wisdom tooth by orthodontic treatment.

### DVT diagnostics

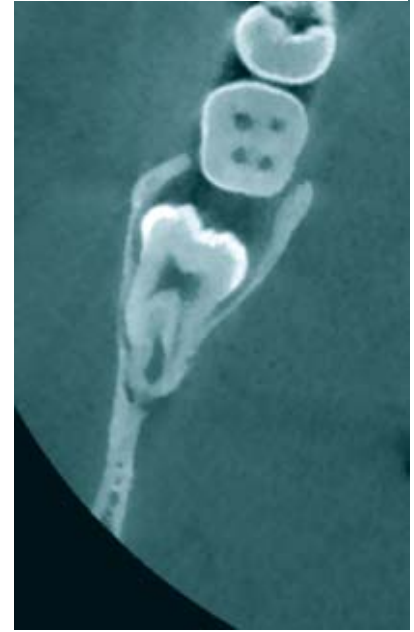
In spite of the wide range of new publications on DVT diagnostics, there have been no relevant changes to the indications for three-dimensional imaging. The guideline shows this in a statement and a recommendation:

#### Statement.

Three-dimensional imaging before removing a wisdom tooth is not required if conventional two-dimensional imaging shows no indication of any specific risks.



**Figure 2a** Course of the inferior alveolar nerve in the root region (sagittal reconstruction)



**Figure 2b** The frontal reconstruction shows the very unusual intraradicular course of the inferior alveolar nerve

### Recommendation:

Three-dimensional imaging (such as DVT/CT) may be indicated if the conventional two-dimensional imaging suggests an immediate spatial relationship to risk structures or pathological changes and at the same time the dentist considers that additional spatial information may be required for the risk assessment of the patient, planning the procedure or also for orientation during the procedure.

### Background:

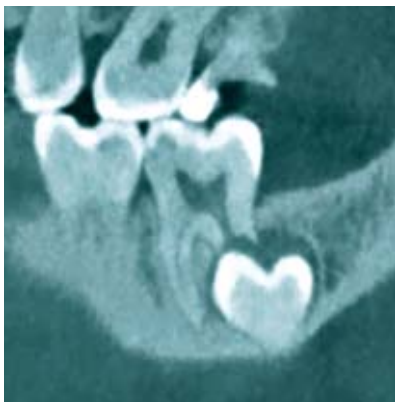Digital volume tomography (DVT) has become established as the three-dimensional imaging methodology used for indications and treatment in dentistry, oral surgery and maxillofa-

cial surgery. The advantages of DVT diagnostics with reference to topographical information, resolution and dimensional accuracy have been described in great detail in recent years. The availability of DVT has placed the question of the necessity of 3D diagnostics before surgical extraction of wisdom teeth in a central position.

A number of studies has shown that DVT is suitable for showing specific morphological features, positional anomalies and in particular the lack of a boundary between alveolus and nerve canal and thus can be used to assess the risk of nerve damage [Ghaeminia et al., 2009; Lübbers et al., 2011; Neugebauer et al., 2008; Suomalainen et al., 2010; Sursala and Dodson, 2007; Tant-anapornkul et al., 2007]. The authors therefore derive the indication of 3D imaging before surgery from the fact that these features are clearly shown in the 3D images. There are also preliminary indications that the surgical procedure may be changed in specific cases due to the inclusion of the DVT information [Ghaeminia et al., 2011]. Critical findings such as the resorption of 12-year molars by impacted wisdom teeth can also only be evaluated by three-dimensional imaging [Oenning et al., 2015].

However, it has so far not been possible to demonstrate that the increased information on the root morphology and topography found with the 3D diagnostics has actually resulted in changes to the surgical procedure and that this has resulted in a reduced rate of nerve damage. Due to the low frequency of such a result, confirmation of a reduction in the risk of nerve damage is practically impossible to obtain under the conditions of a randomized study, because plausible assumptions for the study parameters would result in a sample size of more than 150,000 patients [Roeder et al., 2012]. In practice, an evaluation of the necessity is possible only with the use of surrogate parameters, such as the display of risk indicators.

A prospective randomized study by Ghaeminia et al. contradicts this evaluation and reports of a sample size of 268 patients with 320 wisdom teeth [Ghaeminia et al., 2015]. However, the calculation of the sample size by this working group by implausible assumptions of basic frequencies of damage (12 percent) is not appropriate and is clearly faulty due to the actual frequency of nerve damage of 1.2 percent for the control group within the study population. In addition, the inclusion criteria for



**Figure 3** Tooth resorption



the study (wisdom teeth with increased risk of nerve damage based on the panoramic image (PSA)) contradict the evaluation by the surgeons, who assessed the extraction as difficult in only 20 percent of cases. The times required for the operation (DVT group: 11.1 min versus PSA group: 11.9 min) were virtually the same in both study groups. It is not clear that the information derived from the DVT has influenced the surgical procedure.

### The perioperative antibiotic prophylaxis

The recommendation for the perioperative antibiotic prophylaxis has been reduced from the clear endorsement („should“) to an open recommendation („may“).

#### Recommendation:

Perioperative antibiotic prophylaxis may be applied during removal of a wisdom tooth.

#### Background:

The discussion of the benefits of a prophylactic antibiotic therapy has been part of every surgical specialty since the beginning of the antibiotic era. The benefits of prophylactic antibiotic therapy have been a subject of dispute for a long time in the field of removal of wisdom teeth. Overall, a majority of methodologically high quality, systematic reviews confirm the benefits of prophylactic antibiotic therapy for the reduction of alveolar osteitis and also a reduction in infections from wounds [Ren and Malmstrom, 2007; Lodi et al., 2012; Ramos et al., 2016; Marcussen et al., 2016], but not all reviews show a significant therapeutic effect [Isiordia-Espinoza et al., 2015].

On the other hand, some authors point to the problems of potential resistance and changes in the microbiome even with short-term administration of antibiotics [Zaura et al., 2015; Aragon-Martinez et al., 2016]. Against this background there are also reviews in which the authors do not advise prophylactic antibiotic therapy, in spite of significant reductions in infectious complications (even in their own meta-

### Indications and possible indications for removing wisdom teeth and for leaving them in situ

#### Indications for removing wisdom teeth

##### One indication is present with:

- acute or chronic infections (dentitis difficilis)
- teeth destroyed by caries that cannot be restored or untreatable pulpitis
- in the case of patients with diffuse facial pain if there are indications that the wisdom tooth is a relevant cause of pain
- untreatable periapical changes
- manifest pathological structures in connection with tooth follicles (such as cysts, tumors) or suspicion of such changes
- in connection with the treatment of/ and limitation of the progress of periodontal diseases
- teeth that interfere with orthodontic and/or reconstructive surgery
- teeth in the fracture gap that interfere with treatment of a fracture
- use of the tooth for transplantation

#### Possible indications for removing wisdom teeth

##### One indication may be present:

- to simplify orthodontic tooth movements and/or to simplify orthodontic retention or to secure a completed orthodontic treatment.
- for prophylactic tooth extraction for higher-level reasons to improve quality of life (for example, poor availability of medical treatment, etc.)
- with resorption at neighboring teeth
- pulp exposed by caries

- Teeth that interfere with a planned prosthetic restoration, for example expected due to a secondary eruption due to continuing atrophy of the alveolar ridge or due to pressure from removable dentures
- if other measures are implemented under anesthesia and renewed anesthesia is required to remove a wisdom tooth
- if the elongated/tilted wisdom tooth interferes with the dynamic occlusion
- if the wisdom tooth is the cause of halitosis that requires treatment and other measures for retention of teeth were not successful.

#### Indications for leaving wisdom teeth in place

##### One indication for leaving wisdom teeth in place is present if:

- orthodontic treatment of the tooth is planned
- it is to be used for a prosthetic restoration

##### One indication for leaving wisdom teeth in place may be present if:

- a spontaneous regular setting of the wisdom teeth in the dental arch can be expected
- with deep impacted and displaced teeth without clinically or radiologically confirmed findings of a high risk of surgical complications.

**Source: DGMKG, DGZMK: S2k guideline for surgical removal of wisdom teeth, 2019. AWMF register number: 007-003**

analysis) [Lodi et al., 2012; Arteagoitia et al., 2016]. Although the overall data situation confirms the benefits of a prophylactic antibiotic therapy and in the meantime a methodologically acceptable cohort study on the benefits of a prophylactic antibiotic therapy under practice conditions is now available [Lang et al., 2017], the endorsement and also the rejection of prophylactic antibiotic therapy can both be scientifically supported.

### Piezosurgery

The scientific evidence for piezosurgery has significantly increased in the last five years, with the result that the significance of this method will continue to increase. However, the data on relevant clinical conclusions are not yet so unified that application of

piezosurgery can be generally promoted.

#### Recommendation:

Piezo osteotomy can be used as an alternative or supplement to conventional osteotomy for removal of wisdom teeth where neighboring anatomical structures are in danger.

#### Background:

Piezosurgical applications have been described in recent years as an alternative for numerous types of procedures in maxillofacial surgery and dental surgery, because due to the technical principle the danger to neighboring structures is likely to be reduced. In the case of wisdom tooth removal a number of prospective randomized studies and also results from systematic reviews [Jiang et al., 2015;

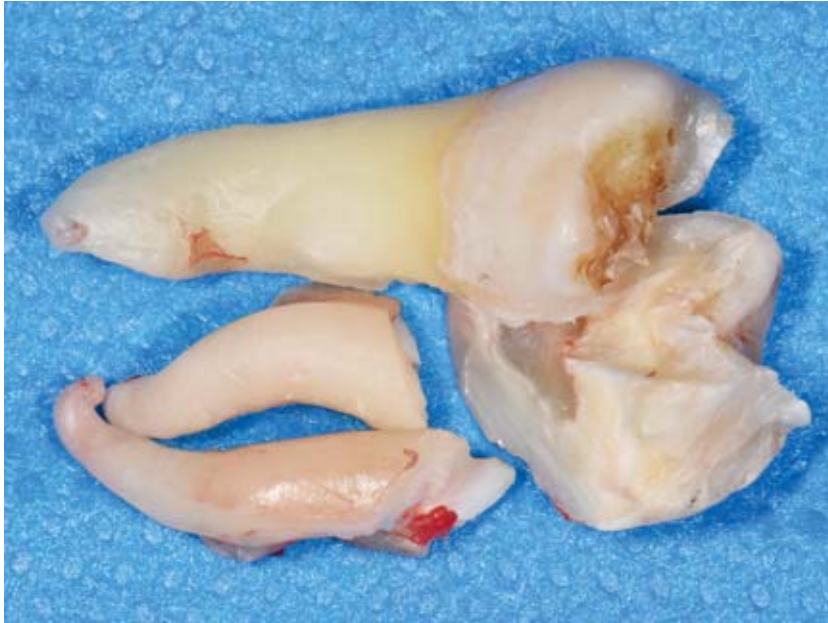

Photo: Kunkel

**Figure 4** Variations of tooth morphology

Moraissi et al., 2016; Badenoch-Jones et al., 2016] are now available. However, the selection of studies and parts of the evaluation methodology of Al-Moraissi et al. have been criticized in the literature [Badenoch-Jones et al., 2016]. The meta-analyses have consistently shown significant advantages with pain reduction, oral opening, swelling, but also significantly longer operation times compared to conventional osteotomy techniques. Initial evaluations for „nerve damage“ as the clinical outcome parameter [Badenoch-Jones et al., 2016] indicate that piezosurgery may also reduce the risk of nerve damage.

### Coronectomy

There have been no significant new insights into coronectomy over the period of this update. The scope of observations has certainly improved and post-operative observation periods over more than five years with low complications have been described. However, data on the longer-term effects over the life of patients are still not available, for example in the case of subsequent treatment with antiresorptives, immune suppression, diabetes, dialysis, tumor therapy and much more. To this extent coronectomy remains an alternative treatment with narrow limits in the indications.

### Recommendation:

As an alternative to complete tooth extraction a coronectomy can be conducted in the case of restricted space to the inferior alveolar nerve where there is a high risk of damage.

### Background:

In recent years the method of selectively removing the crown while leaving the root of the wisdom tooth has been revisited. This treatment concept is based on the fact that where the risk of injuring the inferior alveolar nerve is high, complete removal of the root can be avoided and only the crown and the follicular tissue of the wisdom tooth as a cause of pericoronitis are removed. In the meantime, some case series, a number of comparative cohort studies [Cilasun et al., 2011; Hatano et al., 2009; O’Riordan, 2004; Pogrel et al., 2004] and also prospective randomized studies [Leung and Cheung, 2009; Renton et al., 2005] have been published. These studies indicate that the risk of damage to the inferior alveolar nerve is reduced by the coronectomy. However, the long-term effects of leaving parts of the tooth, such as with reference to subsequent radiotherapy or antiresorptive treatment or even therapeutic immunosuppression, have not yet been adequately studied. Only very minor secondary complications were observed over a post-surgical observation period of up to five years [Leung and Cheung, 2016].

In addition to the classical coronectomy, modifications such as a planned two-stage removal after partial removal of the tooth crown [Landi et al., 2010], after partial removal of the bone [Tolstunov et al., 2011] or supplemented by orthodontic treatments [Wang et al., 2012] or Guided Bone Regeneration [Leung, 2016] have been described. So far, only results from small patient cohorts are available for the various modifications.

### Preferred time for tooth removal

A recommendation for selecting the time for tooth removal has now been added. This recommendation is based primarily on the significantly in-

#### Involved professional bodies and associations

- German Association for Oral and Maxillofacial Surgery (DGMKG)
- German Society of Dentistry and Oral Medicine (DGZMK)
- German Association for Orthodontics (DGKFO)
- German Academy of Oral and Maxillofacial Surgery (AGKi)
- Professional Association of German Oral Surgeons (BDO)
- National Association for Patient Integration (BAGP)
- German Medical Association (BZÄK)
- Interdisciplinary Working Group for Oral Pathology and Oral Medicine (AKOPOM)
- Federal Association for Statutory Health Insurance Dentists (KZBV)

Author of the guideline: Prof. Dr. Dr. M. Kunkel (DGMKG)  
 Co-authors: Prof. Dr. U. Fritz (DGKFO), Prof. Dr. Dr. H. Pistner (DGMKG), Prof. Dr. Dr. H. Terheyden (AGKi), Prof. Dr. Dr. U. Müller-Richter (AKOPOM), PD Dr. F. P. Strietzel (BDO), G. Bornes (BAGP), Dr. M. Frank (BZÄK), Dr. J. Beck (KZBV), Prof. Dr. Dr. R. Werkmeister („Dentoalveolar Surgery“ guideline group of the DGMKG), Prof. Dr. Dr. D. Weingart („Dentoalveolar Surgery“ guideline group of the DGMKG)

creased perioperative morbidity/comorbidity and the poorer periodontal regeneration at neighboring 12-year molars in advanced age.

#### **Recommendation:**

If there is an indication for removal of the wisdom tooth or an indication is foreseeable and the time of tooth extraction can be planned, this wisdom tooth should be removed during the time of development of the root, preferably before the age of 25.

#### **Background:**

For the decision on the time of surgical removal, in addition to the option of regular setting in the dental arch [Kruger et al., 2001] the primary focus for consideration is the stage of development of the tooth root and its current and anticipated relation-

ship to the inferior alveolar nerve, the danger of resorption at neighboring teeth [Wang et al., 2017], the age-dependent local operational risk [Chuang et al., 2007; Baensch et al., 2017] and the age-dependent periodontal regeneration on the neighboring 12-year molar [Kugelberg et al., 1991].

In addition to the long version of the guideline, a detailed guideline report is also available as a source of information. The documents can be downloaded from the web sites of the German Medical Association, the DGZMK and the AWMF. The next revision of the guideline is planned for 2024.

The literature list can be found at [www.zm-online.de](http://www.zm-online.de) or [www.online-dzz.com](http://www.online-dzz.com).



(Photo: private)

**PROF. DR. DR. MARTIN KUNKEL**  
Department of Oral and Maxillofacial  
Surgery, University Hospital Knapp-  
schachtskrankenhaus Bochum  
In der Schornau 23–25  
44892 Bochum  
[martin.kunkel@rub.de](mailto:martin.kunkel@rub.de)

## References

1. Absi, E.G. and Shepherd, J.P. A comparison of morbidity following the removal of lower third molars by the lingual split and surgical bur methods. *Int J Oral Maxillofac Surg*, 22: 149–153 (1993).
2. Ades, A.G., Joondeph, D.R., Little, R.M., Chapko, M. K. A long-term study of the relationship of third molars to changes in the mandibular dental arch. *Am J Orthod Dentofac Orthop*, 97: 323–35 (1990).
3. Anjrini, A.A, Kruger, E., Tennant, M. Cost effectiveness modelling of a 'watchful monitoring strategy' for impacted third molars vs prophylactic removal under GA: an Australian perspective. *British Dental Journal*, 219: 19–23 (2015).
4. Aragon-Martinez, O.H., Isirdia-Espinoza, M.A., Tejada Nava, F.J., Aranda Romo, S. Dental Care Professionals Should Avoid the Administration of Amoxicillin in Healthy Patients During Third Molar Surgery: Is Antibiotic Resistance the Only Problem? *J Oral Maxillofac Surg*, 74: 1512–1513 (2016).
5. Armond, A.C.V., Martins, C.C., Gloria, J.C.R., Galvão, E.L., dos Santos, C.R.R., Falci, S.G.M. Influence of third molars in mandibular fractures. Part 1: mandibular angle—a metaanalysis. *Int J Oral Maxillofac Surg*, 46: 716–729 (2017).
6. Armond, A.C.V., Martins, C.C., Gloria, J.C.R., Galvão, E.L., dos Santos, C.R.R., Falci, S. G.M. Influence of third molars in mandibular fractures. Part 2: mandibular condyle—a meta-analysis. *Int J Oral Maxillofac Surg*, 46: 730–739 (2017).
7. Arteagoitia, M.I., Barbier L., Santamaría, J., Santamaría G., Ramos, E. Efficacy of amoxicillin and amoxicillin/clavulanic acid in the prevention of infection and dry socket after third molar extraction. A systematic review and meta-analysis. *Med Oral Patol Oral Cir Bucal*. 21: e494–504 (2016).
8. Artun, J., Behbehani, F., Thalib, L. Prediction of Maxillary Third Molar Impaction in Adolescent Orthodontic Patients. *Angle Orthodontist*, 75: 904–911 (2005).
9. Badenoch-Jones, E.K., David, M., Lincoln, T. Piezoelectric compared with conventional rotary osteotomy for the prevention of postoperative sequelae and complications after surgical extraction of mandibular third molars: a systematic review and meta-analysis. *Br J Oral Maxillofac Surg*, 54: 1066–1079 (2016).
10. Baensch, F., Kriwalsky, M.S., Kleffmann, W., Kunkel, M. Third Molar Complications in the Elderly—A Matched-Pairs Analysis. *J Oral Maxillofac Surg*, 75: 680–686 (2017).
11. Baycul, T., Sagalam, A.A., Aydin, U. and Basak, K. Incidence of cystic changes in radiographically normal impacted lower third molar follicles. *Oral Surg Oral Med Oral Pathol Oral Radiol Endod*, 00 (2005).
12. Berge, T.I. Complications requiring hospitalization after third-molar surgery. *Acta Odontol Scand*, 54: 24–28 (1996).
13. Berge, T.I. Incidence of infections requiring hospitalization associated with partially erupted third molars. *Acta Odontol Scand*, 54: 309–313 (1996).
14. Berge, T.I. Incidence of large third-molar-associated cystic lesions requiring hospitalization. *Acta Odontol Scand*, 54: 327–331 (1996).
15. Bezerra, T.-P., Studart-Soares, E.-C., Pita-Neto, I.-C., Costa, F.-W.-G. and Batista, S.-H.-B. Do third molars weaken the mandibular angle? *Med Oral Patol Cir Bucal*, 16: e656–663 (2011).
16. Blakey, G.H., Gelesko, S., Marciani, R.D., Haug, R.H., Offenbacher, S., Phillips, C. and White, R.P. Third Molars and Periodontal Pathology in American Adolescents and Young Adults: A Prevalence Study. *J Oral Maxillofac Surg*, 68: 325–329 (2010).
17. Blakey, G.H., Jacks, M.T., Offenbacher, S., Nance, P.E., Phillips, C., Haug, R.H. and White, R.P. Progression of Periodontal Disease in the Second/Third Molar Region in Subjects with Asymptomatic Third Molars. *J Oral Maxillofac Surg*, 64: 189–193 (2006).
18. Blakey, G.H., Marciani, R.D., Offenbacher, S., Pabla, T. and White, R.P. Periodontal Pathology Associated with Asymptomatic Third Molars. *J Oral Maxillofac Surg*, 60: 1227–1233 (2002).
19. Blakey, G.H., Parker, D.W., White, R.P., Offenbacher, S., Philipps, C. and Haug, R.H. Impact of Removal of Asymptomatic Third Molars on Periodontal Pathology. *J Oral Maxillofac Surg*, 67: 245–250 (2009).
20. Bouloux, G.F., Busaidy, K.F., Beirne, O.R., Chuang, S.K., Dodson, T.B.: What is the Risk of Future Extraction of Asymptomatic Third Molars? A Systematic Review. *J Oral Maxillofac Surg*, 73: 806–811 (2015).
21. Chuang, S.-K., Perrott, D.H., Sursala, S.M. and Dodson, T.B. Age as a Risk Factor for Third Molar Surgery Complications. *J Oral Maxillofac Surg*, 65: 1685–1692 (2007).
22. Chuang, S.-K., Perrott, D.H., Sursala, S.M. and Dodson, T.B. Risk Factors for Inflammatory Complications Following Third Molar Surgery in Adults. *J Oral Maxillofac Surg*, 66: 2213–2218 (2008).
23. Cilasun, U., Guzeldemir, E. and Pektaş, Z.O. Coronectomy in Patients with High Risk of Inferior Alveolar Nerve Injury Diagnosed by Computer Tomography. *J Oral Maxillofac Surg*, 69: 1557–1561 (2011).
24. Daly B., Sharif M.O., Newton T., Jones K., Worthington H.V. Local interventions for the management of alveolar osteitis (dry socket). *Cochrane Database of Systematic Reviews* 2012, Issue 12. Art. No.: CD006968. DOI: 10.1002/14651858.CD006968.pub2.
25. Dunstan, S.P. and Sugar, A.W. Fractures after removal of wisdom teeth. *Br J Oral Maxillofac Surg*, 35: 396–397 (1997).
26. Eklund, S.A. and Pittmann, J.L. Third molar removal patterns in an insured population. *JADA*, 132: 469–475 (2001).
27. Eliav, E. and Gracely, R.H. Sensory changes in the territory of the inferior alveolar nerves following lower third molar extraction. *Pain*, 77: 191–199 (1998).
28. Ethunandan, M., Shanahan, D., Patel, M. Iatrogenic mandibular fractures following removal of impacted third molars: an analysis of 130 cases. *Br Dent J*, 212: 179–184 (2012).
29. Fernandes, M.J., Ogden, G.R., Pitts, N.B., Ogston, S.A. and Ruta, D.A. Incidence of symptoms in previously symptom-free impacted lower third molars assessed in general dental practice. *Br Dent J*, 207: E10 (2009).
30. Filippi, A., Irnich, G., Kirschner, H. and Pohl, Y. Lokale Beeinflussbarkeit der Wundheilung nach Osteotomie dritter Molaren. *Quintessenz*, 51: 337–344 (2000).
31. Fisher, E.L., Moss, K.L., Offenbacher, S., Beck, J.D. and White, R.P. Third Molar Caries Experience in Middle-Aged and Older Americans: A Prevalence Study. *J Oral Maxillofac Surg*, 68: 634–640 (2010).
32. Fuselier, J.C., Ellis, E.E. and Dodson, B. Do mandibular third molars alter the risk of angle fractures? *J Oral Maxillofac Surg*, 60: 514–518 (2002).
33. Ghaemina, H., Meijer, G.J., Soehardi, A., Borstlap, W.A., Mulder, J. and Berge, S.J. Position of the impacted third molar in relation to the mandibular canal. Diagnostic accuracy of cone beam computed tomography compared with panoramic radiography. *Int J Oral Maxillofac Surg*, 38: 964–971 (2009).
34. Ghaemina, H., Meijer, G.J., Soehardi, A., Borstlap, W.A., Mulder, J., Vlijmen, O.J.C., Bergé, S.J. and Maal, T.J.J. The use of cone beam CT for the removal of wisdom teeth changes the surgical approach compared with panoramic radiography: a pilot study. *Int J Oral Maxillofac Surg*, 40: 834–839 (2011).
35. Ghaemina, H., Gerlach, N.L., Hoppenreijts, T.J., Kicken, M., Dings, J.P., Borstlap, W.A., de Haan, T., Bergé, S.J.,



- Meijer, G.J., Maal, T.J.J. Clinical relevance of cone beam computed tomography in mandibular third molar removal: A multicentre, randomised, controlled trial. *J Cranio Maxillofac Surg*, 43: 2158e2167 (2015).
36. Ghaemina, H., Perry, J., Nienhuijs, M.E.L., Toedtling, V., Tummers, M., Hoppenreijts, T.J.M., Van der Sanden, W.J.M., Mettes, T.G. Surgical removal versus retention for the management of asymptomatic disease-free impacted wisdom-teeth. *Cochrane Database of Systematic Reviews* 2016, Issue 8. Art. No.: CD003879. DOI: 10.1002/14651858.CD003879.pub4.
37. Givol, N., Rosen, E., Bjørndal, L., Tascieri, S., Ofec, R., Tsesis, I. Medico-legal aspects of altered sensation following endodontic treatment: a retrospective case series. *Oral Surg Oral Med Oral Pathol Oral Radiol Endod*, 112:126–131 (2011).
38. Grau-Manclus, V., Gargallo-Albtol, J., Almendros-Marques, N. and Gay-Escoda, C. Mandibular Fractures Related to the Surgical Extraction of Impacted Lower Third Molars: A Report of 11 Cases. *J Oral Maxillofac Surg*, 69: 1286 – 1290 (2011).
39. Gülicher, D. and Gerlach, K.L. Inzidenz, Risikofaktoren und Verlauf von Sensibilitätsstörungen nach operativer Weisheitszahnentfernung. *Mund Kiefer Gesichtschir*, 4: 99–104 (2000).
40. Hägler, G. and Reich, R.H. Risiko und Vermeidung von Läsionen des N. lingualis bei der Weisheitszahnosteotomie. *Mund Kiefer Gesichtschir*, 6: 34–39 (2002).
41. Harradine, N.W.T., Pearson, M.H. and Toth, B. The Effect of Extraction of Third Molars on Late Lower Incisor Crowding: A Randomized Controlled Trial. *Br J Orthod*, 25: 117–122 (1998).
42. Hatano, Y., Kurita, K., Kuroiwa, Y., Yuasa, H. and Arijii, E. Clinical Evaluations of Coronectomy (Intentional Partial Odontectomy) for Mandibular Third Molars Using Dental Computed Tomography: A Case-Control Study. *J Oral Maxillofac Surg*, 67: 1806–1814 (2009).
43. Hugoson, A. and Kugelberg, C.F. The prevalence of third molars in a Swedish population. *Community Dent Health*, 5: 121–138 (1988).
44. Isiordia-Espinoza, M.A. Aragon-Martinez, O.H., Martínez-Morales J.F., Zapata-Moralesca J.R. Risk of wound infection and safety profile of amoxicillin in healthy patients which required third molar surgery: a systematic review and meta-analysis. *Br J Oral Maxillofac Surg*, 53: 796–804 (2015).
45. Jiang, Q., Qiu, Y., Yang, Ch., Yang, J., Chen, M., Zhang, Z. Piezoelectric Versus Conventional Rotary Techniques for Impacted Third Molar Extraction. A Meta-analysis of Randomized Controlled Trials. *Medicine*, 94: DOI: 10.1097/MD.0000000000001685 (2015).
46. Joshi, A., Goel, M., Thorat, A. Identifying risk factors causing iatrogenic mandibular fractures associated with exodontia: a systematic meta-analysis of 200 cases from 1953 to 2015. *Oral Maxillofac Surg*, 20: 391–396 (2016).
47. Kang, F., Cheng, H., Sak, M.K., Jiang, B. Effect of Eruption Status of the Mandibular Third Molar on Distal Caries in the Adjacent Second Molar. *J Oral Maxillofac Surg*, 74: 684–692 (2016).
48. Kim, J.W., Cha, I.H., Kim, S.J., Kim, M.R. Which risk factors are associated with neurosensory deficits of inferior alveolar nerve after mandibular third molar extraction? *J Oral Maxillofac Surg*, 70: 2508–2514 (2012).
49. Kim, T.W., Artun, J., Behbehani, F., Artese, F. Prevalence of third molar impaction in orthodontic patients treated nonextraction and with extraction of 4 premolars. *Am J Orthod Dentofacial Orthop*, 123: 138–145 (2003).
50. Kjølle G.K., Bjørnland, T. Low risk of neurosensory dysfunction after mandibular third molar surgery in patients less than 30 years of age. *Oral Surg Oral Med Oral Pathol Oral Radiol*, 116: 411–417 (2013).
51. Knutsson, K., Brehmer, B., Lysell, L. and Rohlin, M., Pathoses associated with mandibular third molars subjected to removal. *Oral Surg Oral Med Oral Pathol Oral Radiol Endod*, 82: 10–17 (1996).
52. Kruger, E., Thomson, W.M., Konthasinghe, P. Third molar outcomes from age 18 to 26. Findings from a population-based New Zealand longitudinal study. *Oral Surg Oral Med Oral Pathol Oral Radiol Endod*, 92: 150–155 (2001).
53. Kugelberg, C.F. Periodontal healing two and four years after impacted lower third molar surgery. *Int J Oral Maxillofac Surg*, 19: 341–345 (1990).
54. Kugelberg, C.F., Ahlström, U., Ericson, S., Hugoson, A., Thilander, H. The influence of anatomical, pathophysiological and other factors on periodontal healing after impacted lower third molar surgery – A multiple regression analysis. *J Clin Periodontol*, 18: 37–43 (1991).
55. Kunkel, M., Kleis, W., Morbach, T., Wagner, W. Severe Third Molar Complications Including Death – Lessons from 100 Cases Requiring Hospitalization. *J Oral Maxillofac Surg*, 65: 1700–1706 (2007).
56. KZBV-Jahrbuch 2017. Kassenzahnärztliche Bundesvereinigung (KZBV), ISBN 978–3–944629–05–6.
57. Landi, L., Mancione, P.F., Piccinelli, S. A Novel Surgical Approach to Impacted Mandibular Third Molars to reduce the Risk of Paresthesia. *J Oral Maxillofac Surg*, 68: 969–974 (2010).
58. Lang, M.S., Gonzalez, M.L., Dodson, T.B. Do Antibiotics Decrease the Risk of Inflammatory Complications After Third Molar Removal in Community Practices? *J Oral Maxillofac Surg*, 75: 249–255 (2017).
59. Lata, J., Tiwari, A.K. Incidence of lingual nerve paraesthesia following mandibular third molar surgery. *Nat J Maxillofac Surg*, 2: 137–140 (2011).
60. Leung, Y.Y. Coronectomy of lower third molars with and without guided-bone regeneration: a pilot study. *Br J Oral Maxillofac Surg*, 54: 155–159 (2016).
61. Leung, Y.Y., Cheung, L.K. Risk factors of neurosensory deficits in lower third molar surgery: a literature review of prospective studies. *Int J Oral Maxillofac Surg*, 40: 1–10 (2011).
62. Leung, Y.Y., Cheung, L.K. Safety of coronectomy versus excision of wisdom teeth: A randomized controlled trial. *Oral Surg Oral Med Oral Pathol Oral Radiol Endod*, 108: 821–827 (2009).
63. Leung, Y.Y., Cheung, L.K. Long-term morbidities of coronectomy on lower third molar. *Oral Surg Oral Med Oral Pathol Oral Radiol*, 121: 5–11 (2016).
64. Libersa, P., Roze, D., Cachart, T. and Libersa, J.C. Immediate and Late Mandibular Fractures After Third Molar Removal. *J Oral Maxillofac Surg*, 60: 163–165 (2002).
65. Liedholm, R., Knutson, K., Norlund, A. Economic aspects of mandibular third molar surgery. *Acta Odontologica Scandinavica*, 68: 43–48 (2010).
66. Lim, A.A., Wong, C.W., Allen, J.C. Maxillary third molar: patterns of impaction and their relation to orofacial perforation. *J Oral Maxillofac Surg*, 70: 1035–1039 (2012).
67. Lindquist, B., Thilander, B. Extraction of third molars in cases of anticipated crowding in the lower jaw. *Am J Orthod*, 81: 130–139 (1982).
68. Lodi G., Figini L., Sardella A., Carrassi A., Del Fabbro M., Furness S. Antibiotics to prevent complications following tooth extractions (Review). *Cochrane Database of Systematic Reviews* 2012, Issue 11. Art. No.: CD003811. DOI: 10.1002/14651858.CD003811.pub2.
69. Lübbers, H.T., Matthews, F., Dame-rau, G., Kruse, A.L., Obwegeser, J.A., Grätz, K.W., Eyrych, G.E. Anatomy of impacted lower third molars evaluated by computerized tomography: Is there an indication for 3 dimensional imaging? *Oral Surg Oral Med Oral Pathol Oral Radiol Endod*, 111: 547–50 (2011).
70. Marcussen, K.N., Laulund, A, S, Jørgensen, H.L., Pinholt, E.M. A Systematic



- Review on Effect of Single-Dose Preoperative Antibiotics at Surgical Osteotomy Extraction of Lower Third Molars. *J Oral Maxillofac Surg*, 74: 693–703 (2016).
71. McArdle, L.W., Patel, N., Jones, J., McDonald, F. The mesially impacted mandibular third molar: The incidence and consequences of distal cervical caries in the mandibular second molar. DOI: 10.1016/j.surge.2016.05.001.
72. McGrath, C., Comfort, M.B., Lo, E.C.M. and Luo, Y. Changes in life quality following third molar surgery – the immediate postoperative period. *Br Dent J*, 194: 265–268 (2003).
73. Al-Moraissi, E.A., Elmansi, Y.A., Al-Sharaee Y.A., Almalal, A.E., Alkhatari A.S. Does the piezoelectric surgical technique produce fewer postoperative sequelae after lower third molar surgery than conventional rotary instruments? A systematic review and meta analysis. *Int J Oral Maxillofac Surg*, 45: 383–391 (2016).
74. Neugebauer, J., Shirani, R., Mischkowski, R.A., Ritter, L., Scheer, M., Keeve, E., Zoeller, J.E. Comparison of cone-beam volumetric imaging and combined plain radiographs for localization of the mandibular canal before removal of impacted lower third molars. *Oral Surg Oral Med Oral Pathol Oral Radiol Endod*, 105: 633–642 (2008).
75. Nunn, M.E., Fish, M.D., Garcia, R.I., Kaye, E.K., Figueroa, R., Gohel, A., Ito, M., Lee, H.J., Williams, D.E., Miyamoto, T. Retained Asymptomatic Third Molars and Risk for Second Molar Pathology. *J Dent Res*, 92: 1095–1099 (2013).
76. Oenning, A.C.C., Melo, S.L.S., Gropo, F.C., Haiter-Nero, F. Mesial Inclination of Impacted Third Molars and its Propensity to Stimulate External Root Resorption in Second Molars – A Cone-Beam Computed Tomographic Evaluation. *J Oral Maxillofac Surg*, 73: 379–386 (2015).
77. Oenning, A.C.C., Neves, F.S., Alencar, P.N.B., Prado, R.F., Gropo, F.C., Haiter-Nero, F. External Root Resorption of the Second Molar Associated With Third Molar Impaction: Comparison of Panoramic Radiography and Cone Beam Computed Tomography. *J Oral Maxillofac Surg*, 72: 1444–1455 (2014).
78. O’Riordan, B.C. Coronectomy (intentional partial odontectomy of lower third molars). *Oral Surg Oral Med Oral Pathol Oral Radiol Endod*, 98: 274–280 (2004).
79. Philipsen, H.P., Reichart, P.A. Unicystic ameloblastoma. A review of 193 cases from the literature. *Oral Oncology*, 34: 317–325 (1998).
80. Pogrel, M.A., Lee, J.S., Muff, D.F. Coronectomy: A Technique to Protect Inferior Alveolar Nerve. *J Oral Maxillofac Surg*, 62: 1447–1452 (2004).
81. Polat, H.B., Özcan, F., Kara, I., Özdemir, H., Ay, S. Prevalence of commonly found pathoses associated with mandibular impacted third molars based on panoramic radiographs in Turkish population. *Oral Surg Oral Med Oral Pathol Oral Radiol Endod*, 105: e41–e47 (2008).
82. Pratt, C.A., Hekmar, M., Barnard, J.D.W., Zaki, G.A. Indications for third molar surgery. *J R Coll Surg Edinb*, 43: 105–108 (1998).
83. Punwutikorn, J., Waikakul, A., Ocharoen, P. Symptoms of unerupted mandibular third molars. *Oral Surg Oral Med Oral Pathol Oral Radiol Endod*, 87: 305–310 (1999).
84. Punwutikorn, J., Waikakul, A., Pauruchvej, V. Clinically significant oroantral communications – a study of incidence and site. *Int J Oral Maxillofac Surg*, 23: 19–21 (1994).
85. Rakprasitkul, S. Pathologic changes in the pericoronal tissues of unerupted third molars. *Quintessence Int*, 32: 633–638 (2001).
86. Ramos, E., Santamaría, J., Santamaría, G., Barbier, L., Arteagoitia, I. Do systemic antibiotics prevent dry socket and infection after third molar extraction? A systematic review and meta-analysis. *Oral Surg Oral Med Oral Pathol Oral Radiol*, 122: 403–425 (2016).
87. Ren, Y.F., Malmstrom, H.S. Effectiveness of Antibiotic Prophylaxis in Third Molar Surgery: A Meta-Analysis of Randomized Controlled Clinical Trials. *J Oral Maxillofac Surg*, 65: 1909–1921 (2007).
88. Renton, T., Hankins, M., Sproate, C., McGurk, M. A randomised controlled clinical trial to compare the incidence of injury to the inferior alveolar nerve as a result of coronectomy and removal of mandibular third molars. *Br J Oral Maxillofac Surg*, 43: 7–12 (2005).
89. Renton, T., McGurk, M. Evaluation of factors predictive of lingual nerve injury in third molar surgery. *Br J Oral Maxillofac Surg*, 39: 423–428 (2001).
90. Renton, T., Al-Haboubi, M., Pau, A., Shepherd, J., Gallagher, J.E. What Has Been the United Kingdom’s Experience With Retention of Third Molars? *J Oral Maxillofac Surg*, 70 (Suppl 1): 48–57 (2012).
91. del Rey-Santamaría, M., Valmaseda Castellón, E., Berini Aytés, L., Gay Escoda, C. Incidence of oral sinus communications in 389 upper third molar extraction. *Med Oral Patol Oral Cir Bucal*, 11: E334–338 (2006).
92. Roberts, R.C., Bacchetti, P., Pogrel, M.A. Frequency of Trigeminal Nerve Injuries Following Third Molar Removal. *J Oral Maxillofac Surg*, 63: 732–735 (2005).
93. Rodríguez Sánchez, F., Rodríguez Andrés, C., Arteagoitia Calvo, I. Does Chlorhexidine Prevent Alveolar Osteitis After Third Molar Extractions? Systematic Review and Meta-Analysis. *J Oral Maxillofac Surg*, 75: 901–914 (2017).
94. Roeder, F., Wachtlin, D., Schulze, R., Necessity of 3D visualization for the removal of lower wisdom teeth: required sample size to prove non-inferiority of panoramic radiography compared to CBCT. *Clin Oral Investig*, 16: 699–706 (2012).
95. Rothamel, D., Wahl, G., d’Hoedt, B., Nentwig, G.H., Schwarz, F., Becker J. Incidence and predictive factors for perforation of the maxillary antrum in operations to remove upper wisdom teeth: prospective multicentre study. *Br J Oral Maxillofac Surg*, 45: 387–391 (2007).
96. Selvi, F., Dodson, T.B., Nattestad, A., Robertson, K., Tolstunov, L. Factors that are associated with injury to the inferior alveolar nerve in high-risk patients after removal of third molars. *Br J Oral Maxillofac Surg*, 51: 868–873 (2013).
97. Sigron, G.R. Pourmand, P.P., Mache, B., Stadlinger, B., Locher, M.C. The most common complications after wisdom-tooth removal. Part 1. *Swiss Dent J*, 124: 1042–1046 (2014).
98. Simşek-Kaya, G., Özbek, E., Kalkan, Y., Yapici, G., Dayi, E., Demrci, T. Soft tissue pathosis associated with asymptomatic impacted lower third molars. *Med Oral Patol Oral Cir Bucal*, 16: e929–936 (2011).
99. Smith, A.C., Barry, S.E., Chiong, A.Y., Hadzakis, D., Kha, S.L., Mok, S.C., Sable, D.L. Inferior alveolar nerve damage following removal of mandibular third molar teeth. A prospective study using panoramic radiography. *Aust Dent J*, 42: 149–152 (1997).
100. Song, F., O’Meara, S., Wilson, P., Golder, S., Kleijnen, J. The effectiveness and cost-effectiveness of prophylactic removal of wisdom teeth. *Health Technol Assess*, 4 (1): 1–55 (2000).
101. Strietzel, F.P., Reichart, P.A. Wundheilung nach operativer Weisheitszahnentfernung. *Mund Kiefer Gesichtschir*, 6: 74–84 (2002).
102. Suomalainen, A., Ventä, I., Mattila, M., Turtola, L., Vehmas, T., Peltola, J.S. Reliability of CBCT and other radiographic methods in preoperative evaluation of lower third molars. *Oral Surg Oral Med Oral Pathol Oral Radiol Endod*, 109: 276–284 (2010).
103. Sursala, S.M., Dodson, T.B. Preoperative Computed Tomography Imaging in the Management of Impacted Mandibular Third Molars. *J Oral Maxillofac Surg*, 65: 83–88 (2007).

104. Taberner-Vallverdú, M., Sánchez-Garcés, M.Á., Gay-Escoda, C. Efficacy of different methods used for dry socket prevention and risk factor analysis: A systematic review. *Med Oral Patol Oral Cir Bucal*, 22: e750–758 (2017).
105. Tantanapornkul, W., Okouchi, K., Fujiwara, Y., Yamashiro, M., Marukoa, Y., Ohbayashi, N., Kurabayashi, T. A comparative study of cone-beam computed tomography and conventional panoramic radiography in assessing the topographic relationship between the mandibular canal and impacted third molars. *Oral Surg Oral Med Oral Pathol Oral Radiol Endod*, 103: 253–259 (2007).
106. Thangavelu, A., Yoganandha, R., Vaidhyanathan, A. Impact of impacted mandibular third molars in mandibular angle and condylar fractures. *Int J Oral Maxillofac Surg*, 39: 136–139 (2010).
107. Tolstunov, L., Javid, B., Keyes, L., Nattestad, A. Pericoronar Ostectomy: An Alternative Surgical Technique for Management of Mandibular Third Molars in Close Proximity to the Inferior Alveolar Nerve. *J Oral Maxillofac Surg*, 69: 1858–1866 (2011).
108. Valmaseda-Castellon, E., Berini-Ayres, L., Gay-Escoda, C. Inferior alveolar nerve damage after lower third molar surgical extraction: A prospective study of 1117 surgical extractions. *Oral Surg Oral Med Oral Pathol Oral Radiol Endod*, 92: 377–383 (2001).
109. Ventä, I., Lindqvist, C., Ylipaavalniemi, P. Malpractice claims for permanent nerve injuries related to third molar removals. *Acta Odontol Scand*, 56: 193–196 (1998).
110. Wang, Y., He, D., Yang, C., Wang, B., Qian, W. An easy way to apply orthodontic extraction for impacted lower third molar compressing to the inferior alveolar nerve. *J Craniomaxillofac Surg*, 40: 234–237 (2012).
111. Wang, D., He, X., Wang, Y., Li, Z., Zhu, Y., Sun, C., Ye, J., Jiang, H., Cheng, J. External root resorption of the second molar associated with mesially and horizontally impacted mandibular third molar: evidence from cone beam computed tomography. *Clin Oral Invest*, 21: 1335–1342 (2017).
112. Werkmeister, R., Fillies, T., Joos, U., Smolka, K. Relationship between lower wisdom tooth position and cyst development, deep abscess formation and mandibular fractures. *J Craniomaxillofac Surg*, 33: 164–168 (2005).
113. Worrall, S.F., Riden, K., Haskell, R., Corrigan, A.M. UK National Third Molar project: the initial report. *Br J Oral Maxillofac Surg*, 36: 14–18 (1998).
114. Yamaoka, M., Furusawa, K., Ikeda, M., Hasegawa, T. Root resorption of mandibular second molar teeth associated with the presence of the third molars. *Aust Dent J*, 44: 112–116 (1999).
115. Yamaoka, M., Tambo, A., Furusawa, K. Incidence of inflammation in completely lower third molars. *Aust Dent J*, 42: 153–155 (1997).
116. Yildirim, G., Ataoglu, H., Mihmanli, A., Kiziloglu, D., Avunduk, M.C. Pathologic changes in soft tissues associated with asymptomatic impacted third molars. *Oral Surg Oral Med Oral Pathol Oral Radiol Endod*, 106: 14–16 (2008).
117. Yoshii, T., Hamamoto, Y., Muraoka, S., Kohjitani, A., Teranobu, O., Furudoi, S., Komori, T. Incidence of deep fascial space infection after surgical removal of the mandibular third molars. *J Infect Chemother*, 7: 55–57 (2001).
118. Zaura, E., Brandt, B.W., Teixeira de Mattos, M.J., Buijs, M.J., Caspers, M.P.M., Rashid, M.U., Weintraub, A., Nord, C.E., Savell, A., Hu, Y., Coates, A.R. Hubank, M., Spratt, D.A., Wilson, M., Keijsers, B.J.F., Crielaard, W. Same Exposure but Two Radically Different Responses to Antibiotics: Resilience of the Salivary Microbiome versus Long-Term Microbial Shifts in Feces. *mBio*, 6: e01693–15. doi:10.1128/mBio.01693–15.