

Philip Leander Keeve

# Patient-specific treatment of peri-implant inflammation

**Summary:** The use of dental implants in order to rehabilitate patients with fixed or removable implant-supported restorations has become widespread in recent decades. For example, according to the current German Oral Health Study (DMS V), patients were already 10 times more likely to be treated with implants in 2014 than in 1997 [41]. According to statistics from the American Dental Association, an estimated 5 million implants are placed annually in the USA alone [30]. The increasing life expectancy together with the desire for fixed restorations is expected to further strengthen this trend in the future. The steadily increasing number of implants that are placed by dentists has also been accompanied by an increase in the overall number of post-implant complications. Thus, due to the increased prevalence of biological complications, relevant patient-specific risk factors must be accounted for as part of implant planning and treatment. In this sense, a synoptic treatment concept that considers the foreseeable patient-specific risk factors for peri-implant inflammation plays an important role from the pre-implant to the post-prosthetic treatment phase. The article explores the multitude of patient-specific risk factors and the various therapeutic options available as the key to long-term implant treatment success.

**Keywords:** implants; peri-implant mucositis; peri-implantitis; risk factor; treatment

---

Weser Specialist Dental Center, Hameln, Germany: Philip Leander Keeve, DDS, MSc  
Translation from German: Cristian Miron

**Citation:** Keeve PL: Patient-specific treatment of peri-implant inflammation. Dtsch Zahnärztl Z Int 2022; 4: 18–29

**Peer reviewed article:** submitted: 08.04.2021, revised version accepted: 18.09.2021

**DOI.org/10.53180/dzz-int.2022.0003**

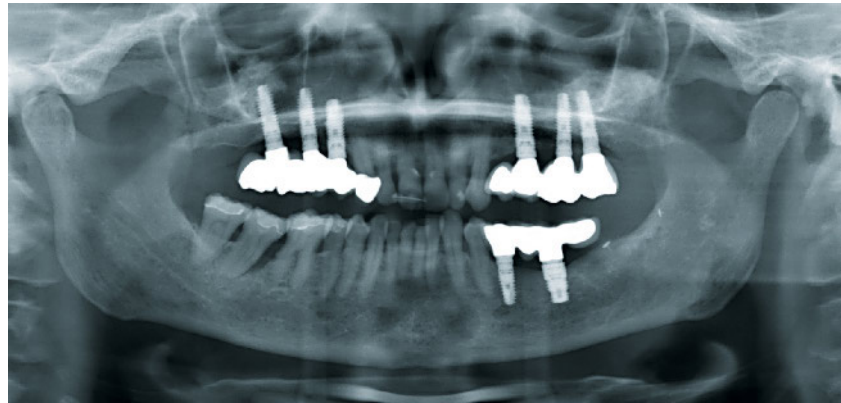
## Definition and diagnosis of peri-implant inflammation

When referring to peri-implant inflammation, reversible peri-implant mucositis, which is inflammation confined to the peri-implant soft tissue, must be distinguished from irreversible peri-implantitis, which also involves the progressive inflammation of the surrounding bone [4].

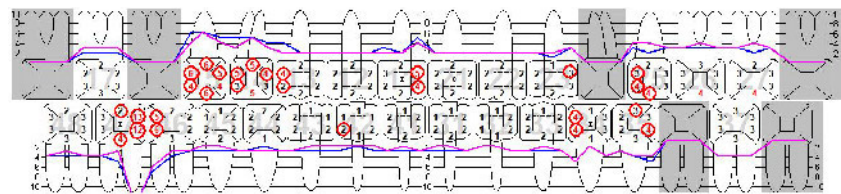
Due to the difficulty in diagnosing peri-implant conditions, the World Workshop on the Classification of Periodontal and Peri-implant Diseases and Conditions defined the characteristics of periodontal and peri-implant health for the first time in 2017. These include the absence of mucosal redness, bleeding on probing (BOP) as well as swelling and suppuration around implants. The definition of a critical probing depth, which is no longer associated with peri-implant health, is not readily available for implants, unlike for periodontitis. In the absence of clinical signs of inflammation, the peri-implant tissues around implants may be healthy even when increased pocket probing depths above 3 mm are present. If bleeding and/or suppuration occurs during gentle probing of the peri-implant soft tissues, this is defined as peri-implant mucositis. If there is a combination of bleeding/suppuration with an increasing probing depth compared to previous examinations, or probing depths of  $\geq 6$  mm and radiological detectable bone resorption beyond the initial bone level after implant placement, then this is referred to as peri-implantitis [11]. In the absence of initial radiological findings, bone resorption  $\geq 3$  mm apical to the intrabony part of the implant is considered indicative of peri-implantitis [91].

The prevalence of peri-implantitis has been estimated to vary between 10 and 29% [24, 42]. The variation of these prevalence figures is primarily due to the complex definition and diagnosis of peri-implantitis as well as a high heterogeneity of study criteria [67].

The prevalence of mucositis is on average 40% and of peri-implantitis 21.7% (95% CI 14–30%) according to systematic reviews [24]. Half of the implants affected by peri-implantitis become diseased within 3 years, and



**Figure 1** Orthopantomogram (initial condition).



**Figure 2** Clinical probing values of the entire dentition (initial condition).

overall, peri-implantitis is diagnosed considerably more often 5 years consecutive to prosthetic restoration [86, 87]. It is assumed that initial mucositis can develop into peri-implantitis and that peri-implant bone resorption accelerates over time [102].

For the classification of peri-implantitis and corresponding peri-implant bone lesions, a classification of different defect morphologies – especially against the background of the various therapeutic options – is recommended. In this respect, intrabony defects (Class I) are distinguished from horizontal supracrestal defects (Class II). The supracrestal portion is defined as the distance between the transition from the smooth to the machined implant portion and the peri-implant crestal alveolar bone [108].

Intrabony defects can be divided into purely vestibular or oral dehiscence defects (Class Ia), vestibular or oral dehiscence defects with additional semicircular portions (Class Ib), vestibular or oral dehiscence defects with additional circular bone resorption (class Ic), and into circular bone resorption with vestibular and oral dehiscence defects (class Id) or bilaterally preserved compact bone (class Ie).

Horizontal and intrabony defects mainly occur together. According to current data, 55.3% of peri-implant bone defects belong to Class Ie [103].

## Patient-specific risk assessment of treatment-relevant risk factors

Possible risk factors include patient age, gender, gene polymorphisms, cardiovascular disease, rheumatoid disease, osteoporosis, condition of residual dentition, implant design and surface as well as implant site and type of restoration. In the following chapter, the 5 most important treatment-relevant risk factors relating to peri-implant inflammation are discussed in detail [102].

## Association of periodontitis and peri-implant diseases

The similarity in the etiopathogenesis of peri-implant and periodontal inflammatory diseases highlights that periodontitis is a risk factor for biological complications and failures of dental implant treatment [42]. The corresponding causal association between plaque formation around implants and peri-implant mucositis has been demonstrated. However, the reaction of hard and soft tissues to

the pathological biofilm around teeth and implants is only to some degree comparable. The microflora found around teeth and implants, that have been exposed to the oral environment for 6 months, is already comparable; however, it does not lead to the development and progression of peri-implant disease in every case. Periodontitis is considered a risk factor for peri-implantitis due to the possible transfer of periodontal pathogens onto the implant surfaces and the reservoir effect of existing periodontal pockets [42]. Additionally, genetic factors are strongly involved in the etiopathogenesis of periodontitis and peri-implantitis and they lead to a correspondingly high susceptibility to both diseases in the same patient group [12, 34–36]. The occurrence of peri-implant diseases clearly correlates with the predisposition and severity of existing periodontitis in the individual patient. However, due to the anatomical conditions of peri-implant tissues, inflammation-induced bone resorption often proceeds faster than at natural teeth. Therefore, patients with severe forms of periodontitis have significantly lower implant survival rates (88–98.4%) than patients with moderate periodontitis (92.8–100%) or periodontally healthy individuals (96–100%) in a 5- to 10-year period after periodontal treatment and implant placement [58]. Implant success after 10 years is significantly lower in patients with generalized, severe periodontitis (83.33%) than in periodontally healthy patients who have success rates of up to 100% [66, 114]. Overall, periodontally treated patients with initial stage I–II periodontitis have higher implant survival rates and less bone resorption around implants than patients with more pronounced stage III–IV periodontitis [58, 86]. For more severe grade C periodontitis, much lower survival and success rates and greater marginal bone resorption [21] are observed than for grades A and B [66, 86, 114]. In particular, patients with a history of severe periodontitis accompanied by poor plaque control and irregular maintenance therapy are at significantly higher risk for the occurrence of peri-implantitis [23, 81, 86].

Currently, the strongest risk factors for peri-implantitis include remaining large pocket depths, lack of follow-up care, poor oral hygiene and severe forms of periodontitis. Even localized, remaining inflammation (PPD  $\geq$ 6 mm with BOP) leads to a 5-fold higher risk of inflammatory processes around implants compared to successfully treated periodontitis [17].

### Poor oral hygiene/irregular maintenance therapy

The lack of compliance during maintenance therapy is associated with tooth loss and attachment loss [6, 8, 121]. The relationship between microbial plaque and diseases such as gingivitis and periodontitis has been demonstrated in numerous studies [7, 8, 61]. Causal therapy in the sense of plaque removal showed improvements in inflammatory lesions in plaque-associated forms of etiopathogenesis [61]. A subsequent study involving mucositis patients demonstrated that efficient plaque control was critical for the prevention of peri-implantitis [18]. Thus, the incidence of peri-implantitis over a 5-year period was significantly lower in patients undergoing maintenance therapy (18%) than in patients not undergoing maintenance therapy (44%). A study by Rocuzzo et al [85] also found a higher prevalence of peri-implantitis over a 10-year period in the absence of maintenance therapy (41%) than in the presence of maintenance therapy (27%). Patients who attended maintenance therapy less than 2 times per year showed an increased risk of developing peri-implantitis (OR 4.69; 95% CI 1.17–18.79).

Moreover, a strong association between inadequate home-based oral hygiene and peri-implantitis was shown in 4 studies with an odds ratio ranging from 5 to 14 [3, 27, 90, 101]. However, conflicting findings have also been published [53, 65, 96], despite the fact that a singular plaque index recording in these studies generally does not reflect an exhaustive means of measuring the long-term oral hygiene status. Serino and Stroem investigated the oral hygiene ability of patients who displayed peri-

implantitis at implant-supported restorations [110] and were able to show that peri-implantitis was diagnosed in only 18% of the areas accessible to oral hygiene and in 65% of the areas not accessible to hygiene.

### Smoking

Smoking is associated with chronic periodontitis, attachment loss and tooth loss [9, 116]. There is also an association between smoking and peri-implantitis [25]. In a 10-year study by Karoussis et al, smokers displayed peri-implantitis at 18% of all implants and non-smokers at only 6% of all implants. In addition to the incorporation of nicotine, cotinine, and their decay products into periodontal tissues, smoking produces hydroxide and peroxy radicals which destroy host DNA, cause lipid peroxidation of the cell membrane, damage endothelial cells, and induce vascular smooth muscle growth, thus causing numerous tissue changes [117]. Reactive oxygen species (ROS) also activate the formation of proinflammatory mediators such as interleukin-6, tumor necrosis factor-alpha or interleukin-1 beta which are important in the pathogenesis of peri-implant diseases. Smoking also leads to a reduction of blood vessel density [84] and to the exacerbation of the inflammatory lesion through genetic variation in the biotransformation of N-acetyltransferase-2, cytochrome P450, CYP2E4, and glutathione S-transferase [51, 52]. Moreover, the functional capacity and number of polymorphonuclear neutrophil granulocytes decreases in smokers [33, 72] in relation to a cytotoxic effect of nicotine on fibroblast migration [26].

Lindquist et al. showed considerably greater crestal bone resorption in smokers than in nonsmokers [60]. However, contrasting results from Aguirre-Zorzano et al. showed a peri-implantitis prevalence of 15% in 239 patients over 5 years, with no increased risk among smokers [3, 20, 23, 76].

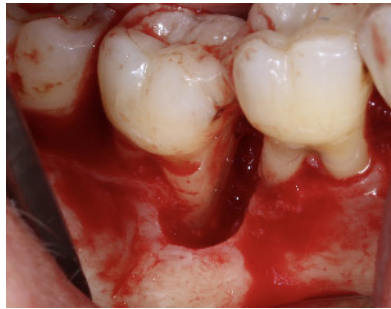On the whole, smoking cannot be considered a relevant predictor of peri-implantitis development, but it should be considered a cofactor, especially when other risk factors such as periodontitis are present. Patients

with existing cofactor smoking and a periodontally compromised dentition have a 4.6-fold increased risk of peri-implantitis compared to periodontally compromised nonsmokers [113].

Future studies should survey the cumulative amount of nicotine abuse in “pack-years” and differentiate between smokers, former smokers, and nonsmokers in order to further elucidate the associations [25].

### Diabetes mellitus

With a worldwide prevalence of approximately 8% in adults [111], diabetes mellitus is considered another important risk factor for peri-implant disease [11] and periodontitis [29]. Due to the parallels in the pathogenesis of peri-implantitis and periodontitis, it is suspected that biological complications at implants are favored by this metabolic disease. Since there are bidirectional relationships between periodontitis, peri-implantitis and diabetes mellitus, glycemic control (HbA<sub>1c</sub> value) and its re-evaluation are mandatory as part of patient-specific treatment. Hyperglycemia results in the formation of advanced glycation end products (AGE) which dock to inflammatory cells via their receptor (RAGE) and lead to an increased release of inflammatory molecules (reactive oxygen species and cytokines), a reduction in chemotaxis and the adhesion performance of inflammatory cells as well as an increase in bacterially induced inflammation of peri-implant tissues [31]. Collagen cross-linking via AGE also leads to more difficult turnover of the peri-implant connective tissue [31]. A large number of studies have found a higher risk of peri-implantitis in patients with poorly controlled diabetes mellitus. Ferreira et al. showed a peri-implantitis prevalence of 24% in untreated diabetic patients or patients with a blood glucose level of  $\geq 126$  mg/dL compared with 7% in the control group of non-diabetic patients, which corresponds to an odds ratio of 1.9 [27]. Patients who received their diabetes diagnosis at the time of implant placement showed a 3-fold higher risk of developing peri-implantitis at the time of the 11-year follow-up evaluation [19].



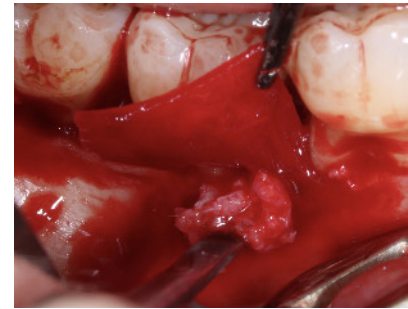
**Figure 3** Illustration of the morphology of the mesial intrabony defect at 46 by means of simplified papilla preservation flap after re-evaluation of the previously performed conservative periodontal therapy.

Tawil et al. studied 45 patients with diabetes mellitus over an average duration of 42 months (1–12 years); they diagnosed no peri-implantitis in patients with an HbA<sub>1c</sub>  $\leq 7\%$ , but in the group of patients with HbA<sub>1c</sub> values between 7 and 9%, they diagnosed peri-implantitis at 6 of 141 implants [115].

Diabetes is thus considered an important potential risk factor for peri-implantitis [76, 102]. More specifically, it has been shown that diabetics have a two-fold higher risk of peri-implantitis than non-diabetics (OR 2.5, 95% CI 1.4–4.5) [25]. From 3 studies in which the information on diabetes mellitus was collected, not only anamnestically, but also clinically, 2 studies showed a significant effect of diabetes [27] or HbA<sub>1c</sub> levels [115] on peri-implantitis.

### Attached and/or keratinized mucosa

Although previous reviews [119] have shown that the lack of attached mucosa has no negative influence on peri-implant health, further meta-analyses, mainly based on cross-sectional studies, have conveyed that lower plaque accumulation, less tissue inflammation, recession, and clinical attachment loss occurs when a minimum width of 1–2 mm keratinized mucosa is present in comparison to when this minimum width is absent [59]. A lack of attached mucosa may negatively affect the ability of the patient to clean [59]. Pain-free, home-based cleaning of implant superstructures is considered an im-



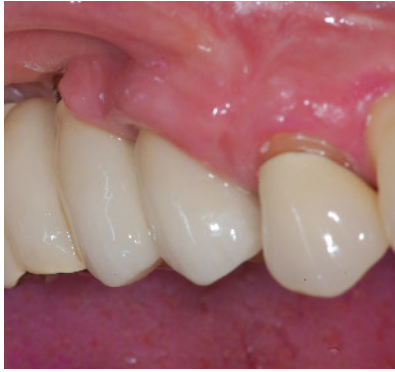**Figure 4** Debridement of the root surface with subsequent membrane positioning in the context of guided tissue regeneration and defect filling with autologous bone.

portant goal in patient-specific treatment. The attached mucosa – independent of muscle movements – should not allow any microorganisms to deposit on the peri-implant transmucosal attachment due to crevice formation in the area of the implant neck [55]. Recent reviews have shown significantly less peri-implant inflammation and lower plaque and gingival indices in patients with at least 2 mm of keratinized or attached peri-implant mucosa [13, 44, 59]. Although less gingival recession and attachment loss occurred with sufficient mucosa, no significant differences could be seen with respect to probing depth values [2, 44, 96, 123]. A non-significant trend indicates increased bone resorption when there is insufficient mucosa [46, 96]. Rokn et al. demonstrated a lack of keratinized mucosa as a statistically significant risk factor for peri-implantitis (OR 3.89; 95% CI 2.34–5.98) [90]. Moreover, Souza et al. found increased discomfort during home-based oral hygiene in areas where there is less than 2 mm of keratinized mucosa, which was accompanied by correspondingly higher plaque values and increased bleeding on probing [112].

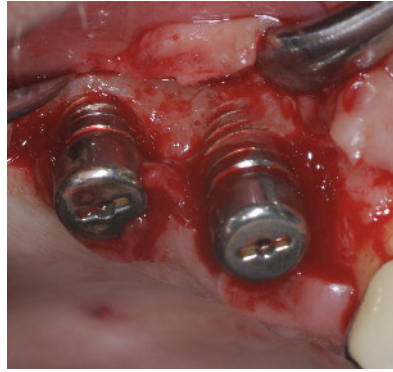
### Treatment options for peri-implant inflammation

#### Prevention of patient-specific risk factors

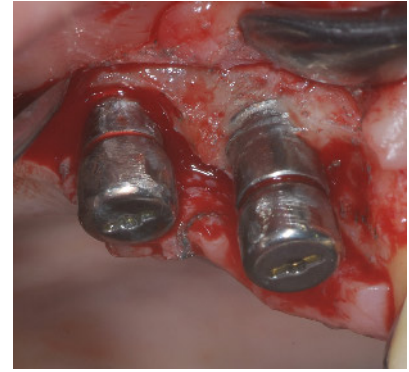Patient-specific treatment of peri-implant inflammation comprises of a synoptic treatment concept with, on



**Figure 5** Peri-implantitis in region 15 and 16 (initial clinical condition).



**Figure 6** Surgical treatment of peri-implantitis in region 15 and 16 (horizontal bone resorption) and removal of the superstructure 8 weeks after closed scaling and decontamination of the implant surface.



**Figure 7** Implantoplasty using rotary instruments and subsequent removal of the granulation tissue and direct insertion of the restoration.

the one hand, attention to the detailed risk factors so as to prevent the development or renewed progression of peri-implant infections and, on the other hand, anti-inflammatory, if possible reconstructive treatment of peri-implant lesions.

Fundamental to the success of implant treatment is the long-term avoidance of biological, technical and esthetic complications. At the biological level, the absence of peri-implant mucositis, peri-implantitis and the establishment of stable soft tissue conditions is necessary, especially as part of maintenance therapy after the active treatment of peri-implant infections. Biological complications at implants differ in their frequency and severity in patients with and without periodontitis. The implementation of careful anti-infective periodontal therapy with the reduction of inflammatory signs and probing depth values prior to the treatment of peri-implant inflammation is thus mandatory (Fig. 3–4).

For the successful long-term treatment of peri-implant inflammation, particularly from the patient-specific point of view, it is essential to design the prosthetic restoration as close as possible to the natural appearance of the teeth, with correspondingly good hygiene characteristics and an optically and functionally satisfactory result; often, this can only be achieved by restoring the lost tissue dimensions.

Tooth loss leads to both bone and soft tissue loss, which are often ex-

acerbated by atrophic bone remodeling processes. It is not uncommon to have partially limited bone volume at the time of the indication for implant placement. Augmentation of the alveolar ridge may be required in order to insert an implant in a physiological position, with sufficient bone quantity, and a prosthetically correct position.

The extent to which the crown-to-implant length ratio has an influence on the survival, marginal bone level or prosthetic complications in the absence of augmentation is controversially discussed. Some reviews concluded that no negative influences exist [69, 75]. In contrast, other systematic reviews observed a higher incidence of prosthetic complications such as abutment loosening or fractures, mainly in posterior jaw regions. Restoration of the near-original dimensions of the hard and soft tissues can minimize these risks in the long term [64]. Moreover, the esthetic result is significantly improved and the ability to maintain oral hygiene, thus ensuring the prevention of inflammatory processes [44].

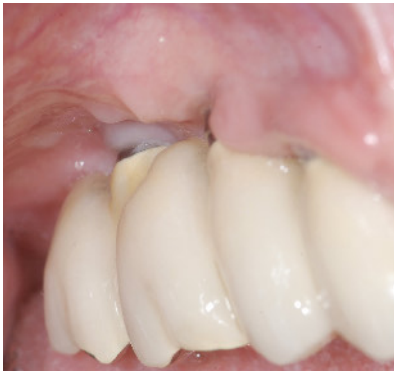### Treatment of peri-implant mucositis

If peri-implant mucositis develops despite consideration of these recommendations and risk factors, the causal therapy of the existing risk factors needs to start with the utmost priority; this includes smoking ces-

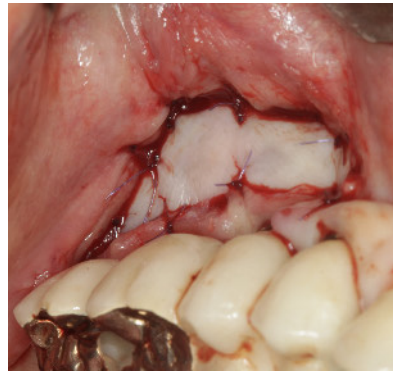
sation, control of diabetes mellitus and specific oral hygiene instruction. Localized plaque-induced inflammation should be eliminated by non-surgical mechanical plaque removal, optimization of oral hygiene skills, and inclusion in a regular maintenance therapy program [73]. Efficient plaque removal without damaging the implant structure is the primary goal [63]. Home-based oral hygiene can be carried out using manual or electric toothbrushes and appropriate interdental brushes [83].

In the case of isolated inflammatory sites in combination with cemented restorations, remaining cement remnants should be taken into account and gently removed by non-surgical cleaning. In cases where non-surgical cleaning is unsuccessful, the removal of the prosthetic restoration and surgical cleaning and cementation under direct view are recommended [83] because the removal of cement remnants leads to a significant improvement of peri-implant tissue health [120].

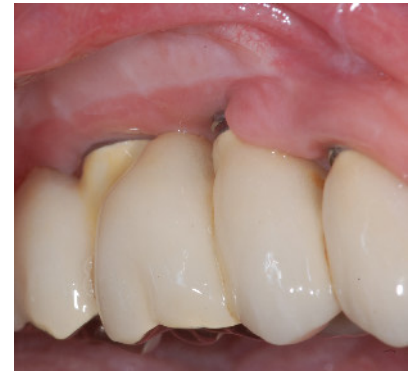The question of whether fixed prosthetic restorations should be screw-retained or cemented is still controversially discussed in literature. In a 2016 review, no clinically relevant differences were found with regard to marginal bone loss at the implant site for screw-retained or cemented restorations [57]. Other authors found increased plaque adhesion to cement remnants in combination with increased incidence of peri-implant in-



**Figure 8** Condition after surgical peri-implantitis treatment with insufficient soft tissue (3 months).



**Figure 9** Harvesting of free mucosal graft (right palate) and vestibuloplasty in order to widen the keratinized mucosa.



**Figure 10** Stable peri-implant and inflammation-free soft tissue condition at the time of a 3-year follow-up check of region 15 and 16.

flammation when methacrylate-based cements were used [71]. In periodontitis patients, the use of screw-retained restorations appears to be desirable because it reliably excludes retention of cement remnants and makes the construction easier to remove in cases of biological or technical complications. On the other hand, technical complications such as fracturing of the veneering are more common among screw-retained restorations [99]. Thus, when choosing cemented restorations, the fabrication of customized, anatomical abutments is helpful for preventing a deep subgingival position of the cement gap and for ensuring the removal of cement remnants. In addition, the avoidance of overhanging margins or concave surfaces on crowns and bridges should be aimed for in order to facilitate ideal home-based oral hygiene.

During mechanical cleaning, titanium and carbon fiber instruments as well as plastic and teflon coated ultrasonic systems are used specifically in order to protect the implant surface [97]; this appears to be advantageous for any potential augmentative therapy approaches in the future. However, it must be noted that debridement is in this case more ineffective and remnants may be left over on the surface [122]. In a randomized controlled trial, it was shown that the use of glycine powder systems gave better results for bleeding on probing in comparison to mechanical cleaning with carbon fiber instruments

[40, 98]. Nonsurgical therapy is considered a successful treatment step in reversible peri-implant mucositis and is subsequently characterized by the absence of bleeding or suppuration on probing [73].

#### Treatment of peri-implantitis

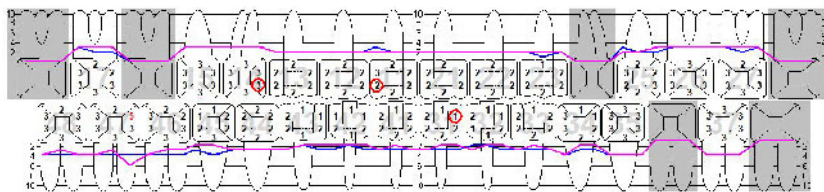
Peri-implantitis lesions can be differentiated into early and late infections. Early peri-implant inflammation occurs immediately or in the first weeks after implant placement and it is mostly caused by postoperative wound healing disorders. Late peri-implantitis is usually diagnosed after the implant's osteointegration has been completed and its prosthetic restoration [82].

The removal of the affected implant is usually indicated upon clinical and radiological diagnosis, as well as, very low Resonance Frequency Analysis (RFA) values or very high Damping Capacity Analysis (DCA) values, deep tapping sounds, mobility and large probing values, which check for osseointegration [73]. In all other cases, the peri-implant inflammation must be permanently reverted to a stagnation phase, beginning with a non-surgical treatment phase and the adjustment of all oral hygiene parameters.

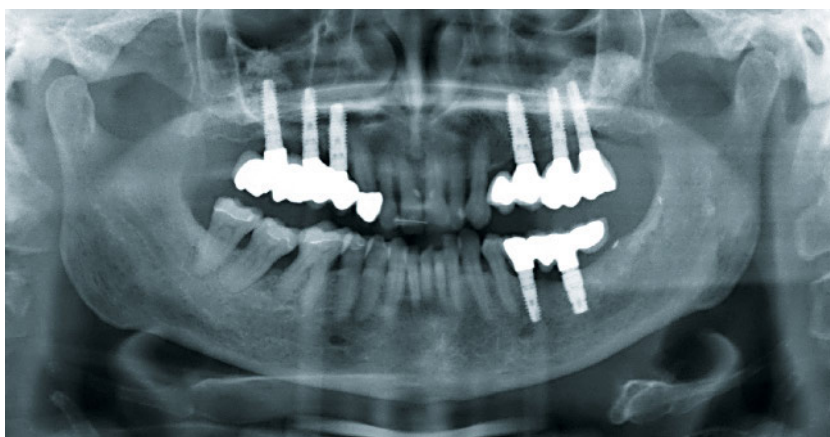
The basis for systematic and continuous prevention and treatment of peri-implant diseases is the original CIST concept (cumulative interceptive supportive therapy or antiseptic cumulative supportive therapy) ac-

ording to Mombelli and Lang [68]. The CIST concept is a step-by-step model divided into 4 treatment steps. Depending on the diagnostic course, the modular therapy guide initially includes hygiene instructions and professional dental cleanings (part A), followed by chlorhexidine rinses, gel applications (part B) and systemic antibiotic medication (part C) as well as subsequent surgical interventions with either resective or regenerative treatment approaches (part D). However, especially in the further development of patient-specific treatments, the existing risk factors must be recognized and adjusted, and the evaluation of the treatment at each step must not be made according to rigid consideration of the probing values, but according to the change in probing values over time [43].

Nonsurgical treatment of peri-implantitis can be expected to reduce bleeding on probing, but it can only result in a limited improvement in probing values [77, 118]. When adjuvant irrigation solutions or antibiotics were used, such as minocycline products and tetracycline derivatives, they proved to be effective and improved the bleeding on probing values as well as the probing depths [10, 14, 78, 79, 100]. However, the administration of systemic antibiotics should be avoided for nonsurgical procedures [77]. The adjuvant use of Nd:YAG and Er:YAG lasers in addition to mechanical therapy has also been shown to have only short-term



**Figure 11** Clinical probing values of the entire dentition 3 years postoperatively (final findings).



**Figure 12** Orthopantomogram 3 years postoperatively (final findings).

success, which lasted a few months in terms of bleeding on probing and probing depths [1, 80].

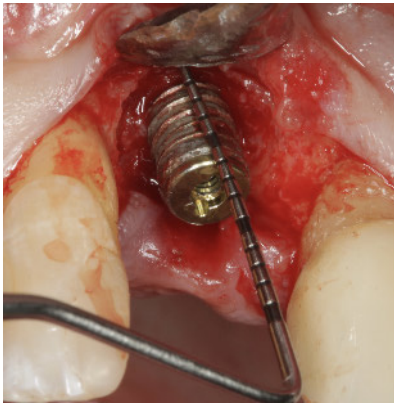
Six weeks after the nonsurgical procedure, surgical, mechanical debridement including chemical decontamination of the implant surface should be performed. Access flaps, resective therapy approaches with or without implantoplasty, or augmentative procedures can be used during this operative intervention. In this context, the bony defect morphology and the position of the affected implant – inside or outside the esthetic area – are considered to be the decisive factors in further treatment planning. In principle, augmentative measures for intrabony components such as bowl-shaped defects (class Ie [108]) and 3- or 4-walled bone defects can achieve improved clinical and radiological therapeutic results in addition to anti-inflammatory ones. The remaining bony defect morphologies are usually treated with resective therapeutic procedures.

Surgical access flaps and resective treatment approaches are indicated for supracrestal bone defects (horizontal bone resorption) with exposed im-

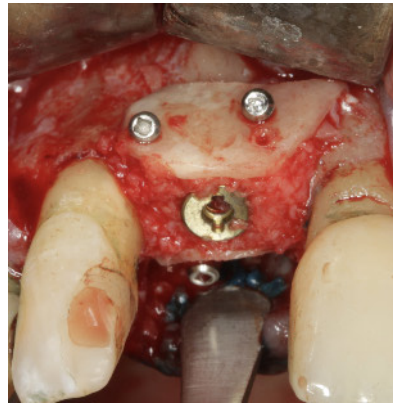
plant threads [45, 50]. Resective treatment of peri-implant inflammation can recontour the bone and reduce probing values. This can be performed together with or without smoothing of the implant surface. In the esthetic region, an access flap with a strictly intrasulcular incision can be used while preserving the soft tissue; in the posterior region, an apically displaced flap can be used [45]. In esthetic regions with moderate bone loss and shallow bone defects, the combination of surgical debridement with a free connective tissue graft is a recommended option in order to achieve significant clinical improvement while still avoiding the high risk of recession [37, 105]. In posterior areas, resective treatment together with implantoplasty lead to improved clinical and radiological results after a 3-year follow-up compared to the control group with only the resective approach without implantoplasty (STM:  $1.64 \pm 1.29$  vs.  $2.3 \pm 1.45$  mm) [93, 94] (Figs. 5–6). For implantoplasty, flame or ellipse shaped carbide burs (30 mm length) can be used with normal (12 cutting edges) and ultra-fine (30 cutting edges) finishing grades. The smoothing of the sur-

face is finalized with Arkansas and Greenie tips. However, the remaining titanium particles in the tissue should be reduced by means of gauze exposure and excision of the granulation tissue after implantoplasty or, depending on the indication and diagnosis, implantoplasty should be limited to the supramucosal areas before flap formation, since the effect of tissue reactions to the remaining titanium with regard to progressive peri-implant inflammation is currently unclear [45, 102]. In order to improve the course of treatment, it is recommended to remove the superstructure before the respective operative intervention, especially in the case of implantoplasty; in this way, the superstructure can be adapted with regard to its oral hygiene design before being reinserted [45]. Adjuvant systemic antibiotics in the case of resective procedures did not result in significant clinical and radiological long-term improvement [16].

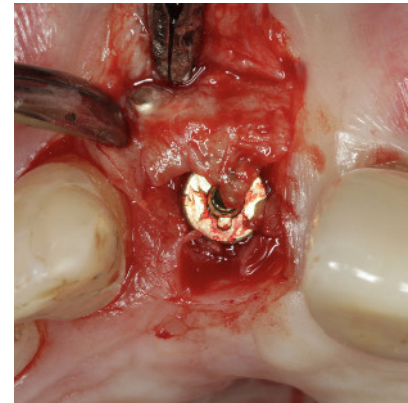
Augmentative procedures are indicated for bowl-shaped bone defects (Class Ie [108]) and 3- or 4-walled bone defects where the bone contour is preferably preserved as a scaffold shape, especially in the case of moderately rough implant surfaces after considering the corresponding existing risk factors [29, 73, 88, 103, 108]. Pre-operatively, especially the implant position and design as well as the hygienic suitability of the prosthetic reconstruction should be critically evaluated [73]. For the execution of augmentative surgical interventions, the use of bone or bone substitutes in combination with or without a membrane technique for guided tissue regeneration, or in combination with biologically active agents, primarily enamel matrix protein derivatives, bone morphogenetic proteins (BMPs) or platelet-rich fibrin membranes (PRF), is available [74]. In the majority of studies, the augmentative interventions resulted in an improvement of the clinical and radiological parameters over a study period ranging from 6 months to 7–10 years [74]. Bleeding on probing reduced by an average of 25.9% [32] to 91% [28] over the follow-up period of up to 7 years. The probing values also decreased between 0.74 mm and



**Figure 13** Combination of a supracrestal and Class Ie defect in the esthetic maxillary anterior region. After non-surgical treatment, surgical cleaning and decontamination of the implant surface is carried out.



**Figure 14** Augmentation of the defect using the biological 3D shell technique according to Khoury and retromolar bone harvesting with subsequent closed wound healing.



**Figure 15** Re-entry at the exposed site after 3 months with complete reconstruction of the bony alveolar process and insertion of the existing prosthetic restoration.

Fig. 1–15: P. Keeve

5.4 mm [48, 104]. The type of surface decontamination had no significant effect on these parameters [22, 48, 54], and thus, cleaning with saline-soaked gauze can be considered as the standard for all surgical procedures [107]. Titanium granules as a filler did not show a positive influence on clinical parameters in augmentative procedures compared to simple access flaps [5, 39]. In 2 studies, there were no significant differences between the use of autologous bone alone and the combination with resorbable [95] and non-resorbable membranes [48]. In contrast, one study provided better clinical results when bone graft substitute was combined with a membrane [106]. Furthermore, the addition of enamel matrix protein derivatives did not improve probing depths and bleeding on probing compared to the control group with access flaps [38]. Therefore, long-term studies currently show no evidence for the clinical superiority of any particular combination in [74].

The question of whether to allow open or closed healing [92] and the benefit of adjuvant systemic antibiotics [74] also cannot be clearly answered on the basis of the current state of literature. If the superstructure permits a non-destructive removal and, in particular, the use of membrane technology where a correspondingly increased risk of exposure is considered [48], closed healing may be favored.

### Stabilization and improvement of the treatment outcome

The described augmentative techniques, in contrast to the purely surgical access flaps and resective treatment approaches, aim not only to achieve an anti-inflammatory effect, but also to improve the therapeutic outcome in terms of probing depths, attachment level and defect filling. Additional options for hard and soft tissue management are described below.

### Hard Tissue Management

Generally, augmentative procedures are limited to the intrabony region, so supracrestal implant surfaces should be treated with either debridement only or supracrestal limited implantoplasty, depending on the risk profile [104]. In the esthetic area, 3D restoration of the alveolar process including the supracrestal portions may be considered in the absence of risk factors – currently without scientific evidence. The author recommends the shell technique as a modification to the autogenous block augmentation for vertical bone resorption consecutive to peri-implantitis, so as to improve healing and bone stability [49] (Figs. 13–15). This concept of bone block grafting from the retromolar mandible uses a thin block graft as a biological membrane, which gives the particulate bone graft material the desired shape and dimension. Particulate bone has an in-

creased surface area with a high regeneration potential and thus mostly improves osteoconduction. For closed healing, absolutely tension-free wound closure with periosteal slitting or adjunctive rotation/swing flaps is mandatory.

### Soft Tissue Management

Before, during and after surgical peri-implantitis treatment, all risk factors (e.g. lack of attached keratinized mucosa) must be immediately checked [109]. If there is a strong muscular influence on the peri-implant soft tissue, the width of the keratinized mucosa should be increased previous to surgical augmentation therapy in order to optimize soft tissue handling, including primary wound closure. In the remaining cases, to prevent recurrence, this potential risk factor can be surgically resolved after successful treatment of the peri-implant inflammation [109]. In most cases, there is a deficit of attached keratinized mucosa after hard tissue augmentative or resective surgery. In this regard, despite limited scientific evidence, the absence or inadequate width of keratinized peri-implant mucosa is considered a source of risk for recurrent peri-implant disease. The presence of an adequate keratinized collar reduces plaque accumulation, tissue inflammation, mucosal recession, and attachment loss [44]. From a clinical perspec-



tive, a minimum width of 2 mm of keratinized, attached peri-implant mucosa is recommended in order to improve peri-implant soft tissue stability, allow the patient to adequately clean and minimize subsequent risks due to increased plaque accumulation. In the absence of this keratinized mucosa, it is imperative to utilize a free mucosal graft so as to improve the clinical situation. [15, 89, 109] (Figs. 8–10). In this regard, autologous free mucosal grafts from the palate show better results in terms of widening the keratinized mucosa compared to vestibuloplasty alone, acellular dermal matrices, or xenogeneic collagen matrices [15, 62].

### Follow-up care

Follow-up care (supportive periodontal therapy) is key to the successful, long-term treatment of peri-implant inflammation [73] and it only functions when potential patient-specific risk factors are taken into consideration. During maintenance therapy, intensive, repetitive instruction, demonstration, and motivation of the patient is indispensable [47]. Moreover, the peri-implant probing depth values must gently be recorded and the re-evaluation of effective home-based as well as professional hygiene skills must be carried out. The recall interval should be selected according to the individual's risk profile [56, 70], whereby patients with previous peri-implant inflammation are generally considered to be at an increased risk [73]. For this reason, a close-meshed 3-month interval for supportive periodontal therapy should always be selected initially, which can always be adapted on a patient-specific basis according to existing risk factors.

### Conclusion

Patient-specific treatment of peri-implant inflammation is based on a synoptic treatment concept with special attention to therapy-relevant risk factors. The prevention of newly recurring peri-implant infections and anti-inflammatory, if possible reconstructive, treatment of peri-implant lesions is considered to be the therapeutic goal.

With successful active periodontitis treatment, the establishment of adequate oral hygiene including prosthetic and/or soft tissue conditioning, as well as, possible nicotine reduction and the adjustment of diabetes mellitus with HbA<sub>1c</sub> target value <7, significant risk factors can be eliminated and the initial conditions for the subsequent treatment of peri-implant inflammation can be created.

Peri-implant inflammation should be initially treated with non-surgical mechanical plaque removal and antimicrobial rinses. After re-evaluation, surgical mechanical debridement using access flaps, resective therapy approaches together with or without implantoplasty, or augmentative procedures may be used. In principle, resective therapy procedures together with or without implantoplasty can be used for supra-crestal bone defects (horizontal bone resorption) and augmentative measures for intrabony components such as bowl-shaped defects. In the context of patient-specific treatment of peri-implant inflammation, particular importance is accorded to follow-up care and the accurate re-evaluation of risk factors.

### Conflict of interest

P.L. Keeve is a lecturer among others for the companies Dentsply Sirona, Straumann, Hager & Meisinger, Stoma Dentalsysteme and Resorba. There is no direct cooperation with these companies for this article. No studies on humans or animals were conducted by the author for this article. The ethical guidelines stated in each case apply to the studies listed.

### References

1. Abduljabbar T et al.: Effect of Nd:YAG laser-assisted non-surgical mechanical debridement on clinical and radiographic peri-implant inflammatory parameters in patients with peri-implant disease. *J Photochem Photobiol B*, 2017; 168: 16–19
2. Adibrad M, Shahabuei M, Sahabi M: Significance of the width of keratinized mucosa on the health status of the supporting tissue around implants supporting overdentures. *J Oral Implantol*, 2009; 35(5): 232–237
3. Aguirre-Zorzano LA et al.: Prevalence of peri-implant inflammatory disease in patients with a history of periodontal disease who receive supportive periodontal therapy. *Clin Oral Implants Res*, 2015; 26(11): 1338–1344
4. Albrektsson TO, Johansson CB, Sennerby L: Biological aspects of implant dentistry: osseointegration. *Periodontol* 2000, 1994; 4: 58–73
5. Andersen H, Aass AM, Wohlfahrt JC: Porous titanium granules in the treatment of peri-implant osseous defects – A 7-year follow-up study. *Int J Implant Dent*, 2017; 3(1): 50
6. Axelsson P, Lindhe J: Effect of controlled oral hygiene procedures on caries and periodontal disease in adults. Results after 6 years. *J Clin Periodontol*, 1981; 8(3): 239–248
7. Axelsson P, Lindhe J, Nystrom B: On the prevention of caries and periodontal disease. Results of a 15-year longitudinal study in adults. *J Clin Periodontol*, 1991; 18(3): 182–189
8. Axelsson P, Nystrom B, Lindhe J: The long-term effect of a plaque control program on tooth mortality, caries and periodontal disease in adults. Results after 30 years of maintenance. *Journal of Clinical Periodontology*, 2004; 31(9): 749–757
9. Axelsson P, Paulander J, Lindhe J: Relationship between smoking and dental status in 35-, 50-, 65-, 75-year-old individuals. *J Clin Periodontol*, 1998; 25(4): 297–305
10. Bassetti M et al.: Anti-infective therapy of peri-implantitis with adjunctive local drug delivery or photodynamic therapy: 12-month outcomes of a randomized controlled clinical trial. *Clin Oral Implants Res*, 2014; 25(3): 279–287
11. Berglundh T et al.: Peri-implantitis and its prevention. *Clin Oral Implants Res*, 2019; 30(2): 150–155
12. Berglundh T, Zitzmann NU, Donati M: Are peri-implantitis lesions different from periodontitis lesions? *Journal of Clinical Periodontology*, 2011; 38: 188–202
13. Boynuegri D, Nemli SK, Kasko YA: Significance of keratinized mucosa around dental implants: a prospective com-

- parative study. *Clin Oral Implants Res*, 2013; 24(8): 928–933
14. Buchter A et al.: Sustained release of doxycycline for the treatment of peri-implantitis: randomised controlled trial. *Br J Oral Maxillofac Surg*, 2004; 42(5): 439–444
  15. Buyukozdemir Askin S et al.: Necessity of keratinized tissues for dental implants: a clinical, immunological, radiographic study. *Clin Implant Dent Relat Res*, 2015; 17(1): 1–12
  16. Carcuac O et al.: Adjunctive systemic and local antimicrobial therapy in the surgical treatment of peri-implantitis: a randomized controlled clinical trial. *J Dent Res*, 2016; 95(1): 50–57
  17. Cho-Yan Lee J et al.: Residual periodontal pockets are a risk indicator for peri-implantitis in patients treated for periodontitis. *Clinical Oral Implants Research*, 2012; 23(3): 325–333
  18. Costa FO et al.: Peri-implant disease in subjects with and without preventive maintenance: a 5-year follow-up. *J Clin Periodontol*, 2012; 39(2): 173–181
  19. Daubert DM et al.: Prevalence and predictive factors for peri-implant disease and implant failure: a cross-sectional analysis. *Periodontol J*, 2015; 86(3): 337–347
  20. de Araujo Nobre M et al.: Risk factors of peri-implant pathology. *Eur J Oral Sci*, 2015; 123(3): 131–139
  21. De Boever AL et al.: Clinical and radiographic study of implant treatment outcome in periodontally susceptible and non-susceptible patients: a prospective long-term study. *Clin Oral Implants Res*, 2009; 20(12): 1341–1350
  22. Deppe H, Horch HH, Neff A: Conventional versus CO2 laser-assisted treatment of peri-implant defects with the concomitant use of pure-phase beta-tricalcium phosphate: a 5-year clinical report. *Int J Oral Maxillofac Implants*, 2007; 22(1): 79–86
  23. Derks J et al.: Effectiveness of implant therapy analyzed in a Swedish population: prevalence of peri-implantitis. *J Dent Res*, 2016; 95(1): 43–49
  24. Derks J, Tomasi C: Peri-implant health and disease. a systematic review of current epidemiology. *J Clin Periodontol*, 2015; 42 Suppl 16: 158–171
  25. Dreyer H et al.: Epidemiology and risk factors of peri-implantitis: a systematic review. *J Periodontal Res*, 2018; 53(5): 657–681
  26. Fang Y, Svoboda KK: Nicotine inhibits human gingival fibroblast migration via modulation of Rac signalling pathways. *Journal of clinical periodontology*, 2005; 32(12): 1200–1207
  27. Ferreira SD et al.: Prevalence and risk variables for peri-implant disease in Brazilian subjects. *J Clin Periodontol*, 2006; 33(12): 929–935
  28. Froum SJ, Froum SH, Rosen PS: A regenerative approach to the successful treatment of peri-implantitis: a consecutive series of 170 implants in 100 patients with 2- to 10-year follow-up. *Int J Periodontics Restorative Dent*, 2015; 35(6): 857–863
  29. Genco RJ, Borgnakke WS: Risk factors for periodontal disease. *Periodontol 2000*, 2013; 62(1): 59–94
  30. Grand View Research Inc.: Global dental implants market analysis and segment forecasts to 2025. Grand View Research Inc. USA, 2019
  31. Graves DT, Liu R, Oates TW: Diabetes-enhanced inflammation and apoptosis – impact on periodontal pathosis. *Periodontology 2000*, 2007; 45(1): 128–137
  32. Guler B et al.: The comparison of porous titanium granule and xenograft in the surgical treatment of peri-implantitis: a prospective clinical study. *Clin Implant Dent Relat Res*, 2017; 19(2): 316–327
  33. Guntch A et al.: Effect of smoking on crevicular polymorphonuclear neutrophil function in periodontally healthy subjects. *J Periodontal Res*, 2006; 41(3): 184–188
  34. Hajishengallis G: Complement and periodontitis. *Biochemical Pharmacology*, 2010; 80(12): 1992–2001
  35. Hajishengallis G, Lambris JD: Complement and dysbiosis in periodontal disease. *Immunobiology*, 2012; 217(11): 1111–1116
  36. Hajishengallis G, Lamont RJ: Beyond the red complex and into more complexity: the polymicrobial synergy and dysbiosis (PSD) model of periodontal disease etiology. *Molecular Oral Microbiology*, 2012; 27(6): 409–419
  37. Heitz-Mayfield LJA et al.: Anti-infective surgical therapy of peri-implantitis. A 12-month prospective clinical study. *Clinical Oral Implants Research*, 2012; 23(2): 205–210
  38. Ished C et al.: Effectiveness of enamel matrix derivative on the clinical and microbiological outcomes following surgical regenerative treatment of peri-implantitis. A randomized controlled trial. *J Clin Periodontol*, 2016; 43(10): 863–873
  39. Jepsen K et al.: Reconstruction of peri-implant osseous defects: a multicenter randomized trial. *J Dent Res*, 2016; 95(1): 58–66
  40. John G et al.: Nonsurgical treatment of peri-implantitis using an air-abrasive device or mechanical debridement and local application of chlorhexidine. Twelve-month follow-up of a prospective, randomized, controlled clinical study. *Clin Oral Investig*, 2015; 19(8): 1807–1814
  41. Jordan RA et al.: The Fifth German Oral Health Study (Fünfte Deutsche Mundgesundheitsstudie, DMS V) – rationale, design, methods. *BMC Oral Health*, 2014; 14: 161
  42. Karoussis IK et al.: Long-term implant prognosis in patients with and without a history of chronic periodontitis: a 10-year prospective cohort study of the ITI Dental Implant System. *Clin Oral Implants Res*, 2003; 14(3): 329–339
  43. Keeve PL, Conrad T: Implantate im parodontal vorgeschädigten Gebiss. *der junge zahnarzt*, 2021; 12(3): 14–25
  44. Keeve PL, Khoury F: Long-term results of peri-implant conditions in periodontally compromised patients following lateral bone augmentation. *Int J Oral Maxillofac Implants*, 2017; 32(1): 137–146
  45. Keeve PL et al.: Surgical treatment of periimplantitis with non-augmentative techniques. *Implant Dent*, 2019; 28(2): 177–186
  46. Kehl M, Swierkot K, Mengel R: Three-dimensional measurement of bone loss at implants in patients with periodontal disease. *Periodontol J*, 2011; 82(5): 689–699
  47. Kelekis-Cholakakis A, Rothney J: Maintenance of implant patients: a narrative review. *Implant Dent*, 2019; 28(2): 161–172
  48. Khoury F, Buchmann R: Surgical therapy of peri-implant disease: a 3-year follow-up study of cases treated with 3 different techniques of bone regeneration. *Periodontol J*, 2001; 72(11): 1498–1508
  49. Khoury F, Hanser T: Mandibular bone block harvesting from the retromolar region: a 10-year prospective clinical study. *Int J Oral Maxillofac Implants*, 2015; 30(3): 688–697
  50. Khoury F et al.: Surgical treatment of peri-implantitis – Consensus report of working group 4. *Int Dent J*, 2019; 69 Suppl 2: 18–22
  51. Kim JS et al.: Polymorphisms in genes coding for enzymes metabolizing smoking-derived substances and the risk of periodontitis. *Journal of clinical periodontology*, 2004; 31(11): 959–964
  52. Kocher T et al.: Association between bone loss in periodontal disease and polymorphism of N-acetyltransferase (NAT2). *Journal of Clinical Periodontology*, 2002; 29(1): 21–27
  53. Koldslund OC, Scheie AA, Aass AM: The association between selected risk indicators and severity of peri-implantitis using mixed model analyses. *J Clin Periodontol*, 2011; 38(3): 285–292
  54. Koo KT et al.: Implant surface decontamination by surgical treatment of peri-implantitis: a literature review. *Implant Dent*, 2019; 28(2): 173–176

55. Lang NP, Loe H: The relationship between the width of keratinized gingiva and gingival health. *Periodontol J*, 1972; 43(10): 623–627
56. Lang NP, Tonetti MS: Periodontal risk assessment (PRA) for patients in supportive periodontal therapy (SPT). *Oral Health Prev Dent*, 2003; 1(1): 7–16
57. Lemos CA et al.: Evaluation of cement-retained versus screw-retained implant-supported restorations for marginal bone loss: A systematic review and meta-analysis. *J Prosthet Dent*, 2016; 115(4): 419–427
58. Levin L et al.: Periodontal disease as a risk for dental implant failure over time: a long-term historical cohort study. *Journal of Clinical Periodontology*, 2011; 38(8): 732–737
59. Lin, G-H, H-Chan L, H-Wang L: The significance of keratinized mucosa on implant health: a systematic review. *Journal of Periodontology*, 2013: 1–20
60. Lindquist LW, Carlsson GE, Jemt T: A prospective 15-year follow-up study of mandibular fixed prostheses supported by osseointegrated implants. *Clinical results and marginal bone loss. Clin Oral Implants Res*, 1996; 7(4): 329–336
61. Loe H, Theilade E, Jensen SB: Experimental gingivitis in man. *Periodontol J*, 1965; 36: 177–187
62. Lorenzo R et al.: Clinical efficacy of a xenogeneic collagen matrix in augmenting keratinized mucosa around implants: a randomized controlled prospective clinical trial. *Clin Oral Implants Res*, 2012; 23(3): 316–324
63. Louropoulou A, Slot DE, Van der Weijden F: The effects of mechanical instruments on contaminated titanium dental implant surfaces: a systematic review. *Clin Oral Implants Res*, 2014; 25(10): 1149–1160
64. Maminskas J et al.: The prosthetic influence and biomechanics on peri-implant strain: a systematic literature review of finite element studies. *J Oral Maxillofac Res*, 2016; 7(3): e4
65. Marrone A et al.: Prevalence and risk factors for peri-implant disease in Belgian adults. *Clin Oral Implants Res*, 2013; 24(8): 934–940
66. Mengel R, Behle M, Flores-de-Jacoby L: Osseointegrated implants in subjects treated for generalized aggressive periodontitis: 10-year results of a prospective, long-term cohort study. *Periodontol J*, 2007; 78(12): 2229–2237
67. Misch CE et al.: Implant success, survival, failure: the International Congress of Oral Implantologists (ICOI) Pisa Consensus Conference. *Implant Dent*, 2008; 17(1): 5–15
68. Mombelli A, Lang NP: The diagnosis and treatment of peri-implantitis. *Periodontol 2000*, 1998; 17: 63–76
69. Nedir R et al.: Change in crown-to-implant ratio of implants placed in grafted and nongrafted posterior maxillary sites: a 5-year prospective randomized study. *Int J Oral Maxillofac Implants*, 2019; 34(5): 1231–1236
70. Oliveira Costa F et al.: Progression of periodontitis in a sample of regular and irregular compliers under maintenance therapy: a 3-year follow-up study. *Journal of Periodontology*, 2011; 82(9): 1279–1287
71. Pesce P et al.: Systematic review of some prosthetic risk factors for peri-implantitis. *J Prosthet Dent*, 2015; 114(3): 346–350
72. Petropoulos G, McKay IJ, Hughes FJ: The association between neutrophil numbers and interleukin-1 $\alpha$  concentrations in gingival crevicular fluid of smokers and non-smokers with periodontal disease. *J Clin Periodontol*, 2004; 31(5): 390–395
73. Polyzois I: Treatment planning for periimplant mucositis and periimplantitis. *Implant Dent*, 2019; 28(2): 150–154
74. Ramanauskaite A et al.: Surgical treatment of periimplantitis with augmentative techniques. *Implant Dent*, 2019; 28(2): 187–209
75. Ravida A et al.: The effect of crown-to-implant ratio on the clinical outcomes of dental implants: a systematic review. *Int J Oral Maxillofac Implants*, 2019; 34(5): 1121–1131
76. Renvert S et al.: Factors related to peri-implantitis – a retrospective study. *Clin Oral Implants Res*, 2014; 25(4): 522–529
77. Renvert S et al.: Diagnosis and non-surgical treatment of peri-implant diseases and maintenance care of patients with dental implants – consensus report of working group 3. *Int Dent J*, 2019; 69 Suppl 2: 12–17
78. Renvert S et al.: Topical minocycline microspheres versus topical chlorhexidine gel as an adjunct to mechanical debridement of incipient peri-implant infections: a randomized clinical trial. *J Clin Periodontol*, 2006; 33(5): 362–369
79. Renvert S et al.: Mechanical and repeated antimicrobial therapy using a local drug delivery system in the treatment of peri-implantitis: a randomized clinical trial. *Periodontol J*, 2008; 79(5): 836–844
80. Renvert S et al.: Treatment of peri-implantitis using an Er:YAG laser or an air-abrasive device: a randomized clinical trial. *J Clin Periodontol*, 2011; 38(1): 65–73
81. Renvert S, Persson GR: Periodontitis as a potential risk factor for peri-implantitis. *Journal of Clinical Periodontology*, 2009; 36: 9–14
82. Renvert S, Polyzois I: Risk indicators for peri-implant mucositis: a systematic literature review. *J Clin Periodontol*, 2015; 42 Suppl 16: 172–186
83. Renvert S, Polyzois IN: Clinical approaches to treat peri-implant mucositis and peri-implantitis. *Periodontol 2000*, 2015; 68(1): 369–404
84. Rezavandi K et al.: Expression of ICAM-1 and E-selectin in gingival tissues of smokers and non-smokers with periodontitis. *J Oral Pathol Med*, 2002; 31(1): 59–64
85. Rocuzzo M et al.: Ten-year results of a three arms prospective cohort study on implants in periodontally compromised patients. Part 2: clinical results. *Clinical Oral Implants Research*, 2012; 23(4): 389–395
86. Rocuzzo M et al.: Long-term results of a three arms prospective cohort study on implants in periodontally compromised patients: 10-year data around sandblasted and acid-etched (SLA) surface. *Clin Oral Implants Res*, 2014; 25(10): 1105–1112
87. Rocuzzo M et al.: Ten-year results of a three-arm prospective cohort study on implants in periodontally compromised patients. Part 1: implant loss and radiographic bone loss. *Clinical Oral Implants Research*, 2010; 21(5): 490–496
88. Rocuzzo M et al.: Surgical therapy of single peri-implantitis intrabony defects, by means of deproteinized bovine bone mineral with 10% collagen. *J Clin Periodontol*, 2016; 43(3): 311–318
89. Rocuzzo M et al.: Long-term outcomes of implants placed after vertical alveolar ridge augmentation in partially edentulous patients: a 10-year prospective clinical study. *Clin Oral Implants Res*, 2017; 28(10): 1204–1210
90. Rohn A et al.: Prevalence of peri-implantitis in patients not participating in well-designed supportive periodontal treatments: a cross-sectional study. *Clin Oral Implants Res*, 2017; 28(3): 314–319
91. Romandini M et al.: Diagnosis of peri-implantitis in the absence of baseline data: A diagnostic accuracy study. *Clin Oral Implants Res*, 2021; 32(3): 297–313
92. Romanos GE, Nentwig GH: Regenerative therapy of deep peri-implant infrabony defects after CO<sub>2</sub> laser implant surface decontamination. *Int J Periodontics Restorative Dent*, 2008; 28(3): 245–255
93. Romeo E et al.: Therapy of peri-implantitis with resective surgery. A 3-year clinical trial on rough screw-shaped oral implants. Part I: clinical outcome. *Clin Oral Implants Res*, 2005; 16(1): 9–18
94. Romeo E et al.: Therapy of peri-implantitis with resective surgery. A 3-year clinical trial on rough screw-shaped oral

- implants. Part II: radiographic outcome. *Clin Oral Implants Res*, 2007; 18(2): 179–87
95. Roos-Jansaker AM et al.: Surgical treatment of peri-implantitis using a bone substitute with or without a resorbable membrane: a 5-year follow-up. *J Clin Periodontol*, 2014; 41(11): 1108–1114
96. Roos-Jansaker AM et al.: Nine- to four-teen-year follow-up of implant treatment. Part III: factors associated with peri-implant lesions. *J Clin Periodontol*, 2006; 33(4): 296–301
97. Ruhling A et al.: Treatment of subgingival implant surfaces with Teflon-coated sonic and ultrasonic scaler tips and various implant curettes. An in vitro study. *Clin Oral Implants Res*, 1994; 5(1): 19–29
98. Sahm N et al.: Non-surgical treatment of peri-implantitis using an air-abrasive device or mechanical debridement and local application of chlorhexidine: a prospective, randomized, controlled clinical study. *J Clin Periodontol*, 2011; 38(9): 872–878
99. Sailer I et al.: Cemented and screw-retained implant reconstructions: a systematic review of the survival and complication rates. *Clinical Oral Implants Research*, 2012; 23: 163–201
100. Schar D et al.: Anti-infective therapy of peri-implantitis with adjunctive local drug delivery or photodynamic therapy: six-month outcomes of a prospective randomized clinical trial. *Clin Oral Implants Res*, 2013; 24(1): 104–110
101. Schwarz F et al.: The prevalence of peri-implant diseases for two-piece implants with an internal tube-in-tube connection: a cross-sectional analysis of 512 implants. *Clin Oral Implants Res*, 2017; 28(1): 24–28
102. Schwarz F et al.: Peri-implantitis. *Periodontol J*, 2018; 89 Suppl 1: S267–S290
103. Schwarz F et al.: Comparison of naturally occurring and ligature-induced peri-implantitis bone defects in humans and dogs. *Clin Oral Implants Res*, 2007; 18(2): 161–170
104. Schwarz F et al.: Combined surgical therapy of advanced peri-implantitis evaluating two methods of surface decontamination: a 7-year follow-up observation. *J Clin Periodontol*, 2017; 44(3): 337–342
105. Schwarz F, Sahm N, Becker J: Combined surgical therapy of advanced peri-implantitis lesions with concomitant soft tissue volume augmentation. A case series. *Clin Oral Implants Res*, 2014; 25(1): 132–136
106. Schwarz F et al.: Surgical regenerative treatment of peri-implantitis lesions using a nanocrystalline hydroxyapatite or a natural bone mineral in combination with a collagen membrane: a four-year clinical follow-up report. *J Clin Periodontol*, 2009; 36(9): 807–814
107. Schwarz F et al.: Impact of the method of surface debridement and decontamination on the clinical outcome following combined surgical therapy of peri-implantitis: a randomized controlled clinical study. *J Clin Periodontol*, 2011; 38(3): 276–284
108. Schwarz F et al.: Impact of defect configuration on the clinical outcome following surgical regenerative therapy of peri-implantitis. *J Clin Periodontol*, 2010; 37(5): 449–455
109. Sculean A et al.: Soft-tissue management as part of the surgical treatment of periimplantitis: a narrative review. *Implant Dent*, 2019; 28(2): 210–216
110. Serino G, Strom C: Peri-implantitis in partially edentulous patients: association with inadequate plaque control. *Clin Oral Implants Res*, 2009; 20(2): 169–174
111. Shaw JE, Sicree RA, Zimmet PZ: Global estimates of the prevalence of diabetes for 2010 and 2030. *Diabetes Research and Clinical Practice*, 2010; 87(1): 4–14
112. Souza AB et al.: The influence of peri-implant keratinized mucosa on brushing discomfort and peri-implant tissue health. *Clin Oral Implants Res*, 2016; 27(6): 650–655
113. Strietzel FP et al.: Smoking interferes with the prognosis of dental implant treatment: a systematic review and meta-analysis. *J Clin Periodontol*, 2007; 34(6): 523–544
114. Swierkot K et al.: Mucositis, peri-implantitis, implant success, survival of implants in patients with treated generalized aggressive periodontitis: 3- to 16-year results of a prospective long-term cohort study. *Periodontol J*, 2012; 83(10): 1213–1225
115. Tawil G et al.: Conventional and advanced implant treatment in the type II diabetic patient: surgical protocol and long-term clinical results. *Int J Oral Maxillofac Implants*, 2008; 23(4): 744–752
116. Tomar SL, Asma S: Smoking-attributable periodontitis in the united states: findings from NHANES III. *Periodontol J*, 2000; 71(5): 743–751
117. Tsai CC et al.: Lipid peroxidation: a possible role in the induction and progression of chronic periodontitis. *J Periodontol Res*, 2005; 40(5): 378–384
118. Wang CW, Renvert S, Wang HL: Nonsurgical treatment of periimplantitis. *Implant Dent*, 2019; 28(2): 155–160
119. Wennström JL, Derks J: Is there a need for keratinized mucosa around implants to maintain health and tissue stability? *Clinical Oral Implants Research*, 2012; 23: 136–146
120. Wilson TG, Jr.: The positive relationship between excess cement and peri-implant disease: a prospective clinical endoscopic study. *Periodontol J*, 2009; 80(9): 1388–1392
121. Wilson TG, Jr., et al.: Tooth loss in maintenance patients in a private periodontal practice. *Periodontol J*, 1987; 58(4): 231–235
122. Yang SM, Park JB, Ko Y: Use of confocal microscopy for quantification of plastic remnants on rough titanium after instrumentation and evaluation of efficacy of removal. *Int J Oral Maxillofac Implants*, 2015; 30(3): 519–525
123. Zigdon H, Machtei EE: The dimensions of keratinized mucosa around implants affect clinical and immunological parameters. *Clin Oral Implants Res*, 2008; 19(4): 387–392



Photo: P. Keeve

**DR. PHILIP KEEVE L, MSC.**  
**Fachzahnarzt Zentrum Weser:**  
**Dr. Keeve + Kollegen**  
**Süntelstraße 10-12,**  
**31785 Hameln, Germany**  
**E-Mail: pl.keeve@outlook.com**