



Treatment Outcome of Regenerative Endodontic Procedures for Necrotic Immature and Mature Permanent Teeth: A Systematic Review and Meta-Analysis Based on Randomised Controlled Trials

Jiahua Li^a / Leilei Zheng^b / Baraa Daraqel^c / Jing Liu^d / Yun Hu^e

Purpose: To analyse whether the stage of apical development affects the effectiveness of regenerative endodontic treatment by comparing the outcomes for necrotic mature and immature permanent teeth treated with regenerative endodontic procedures.

Materials and Methods: Multiple databases (PubMed, Cochrane Library, Web of Science, EMBASE and OpenGrey databases) were searched through February 17th, 2022. Inclusion criteria were randomised controlled trials that included treatment of necrotic immature or mature permanent teeth using any regenerative endodontic procedures (REPs) that aimed to achieve pulp revascularisation or regeneration. The Cochrane Risk of Bias 2.0 tool was used to assess risk of bias. The included indicators were asymptomatic sign, success, pulp sensitivity, and discolouration. The extracted data were expressed by percentage for statistical analysis. The random effect model was used to explain the results. Comprehensive Meta-Analysis Version 2 was used to perform the statistical analyses.

Results: Twenty-seven RCTs were eligible for inclusion in the meta-analysis. The success rates of necrotic immature and mature permanent teeth were 95.6% (95% CI, 92.4%-97.5%; $I^2=34.9\%$) and 95.5% (95%CI, 87.9%-98.4%; $I^2=0\%$), respectively. The asymptomatic rates of necrotic immature and mature permanent teeth were 96.2% (95%CI, 93.5%-97.9%; $I^2=30.1\%$) and 97.0% (95%CI, 92.6%-98.8%; $I^2=0\%$), respectively. The treatment of immature and mature necrotic permanent teeth with REPs yields high success rates and low symptomatic rates. The incidence of positive sensitivity response for electric pulp testing in necrotic immature permanent teeth (25.2% [95% CI, 18.2%-33.8%; $I^2=0\%$]) was lower than that in necrotic mature permanent teeth (45.4% [95% CI, 27.2%-64.8%; $I^2=75.2\%$]), and this difference was statistically significant. The restoration of pulp sensitivity seems to be more evident in necrotic mature permanent teeth than in necrotic immature permanent teeth. The crown discolouration rate of immature permanent teeth was 62.5% (95% CI, 49.7%-73.8%; $I^2=76.1\%$). Necrotic immature permanent teeth have a considerable crown discolouration rate.

Conclusion: REPs for both immature and mature necrotic permanent teeth yield high success rates and promote root development. The vitality responses seem to be more evident in necrotic mature permanent teeth than in necrotic immature permanent teeth.

Key words: dental pulp necrosis, meta-analysis, regenerative endodontics

Oral Health Prev Dent 2023; 21: 141–152.
doi: 10.3290/j.ohpd.b4100877

Submitted for publication: 31.12.22; accepted for publication: 24.04.23

^a Postgraduate Student, Department of Stomatological Hospital of Chongqing Medical University, Chongqing, China. Chongqing Key Laboratory of Oral Diseases and Biomedical Sciences, Chongqing; Chongqing Municipal Key Laboratory of Oral Biomedical Engineering of Higher Education, Chongqing, China. First author, designed the study, collected the data, data cleaning, analysis of data, drafted the manuscript, read and approved the final manuscript.

^b Professor, Department of Stomatological Hospital of Chongqing Medical University, Chongqing, China. Chongqing Key Laboratory of Oral Diseases and Biomedical Sciences, Chongqing; Chongqing Municipal Key Laboratory of Oral Biomedical Engineering of Higher Education, Chongqing, China. Obtained funding, interpretation of the results and critical revision of the manuscript for important intellectual content and approved the final version of the manuscript.

^c Postgraduate Student, Department of Stomatological Hospital of Chongqing Medical University, Chongqing, China. Chongqing Key Laboratory of Oral Diseases and Biomedical Sciences, Chongqing; Chongqing Municipal Key Laboratory of Oral Biomedical Engineering of Higher Education, Chongqing, China. Data cleaning, analysis of data, interpretation of the results and critical revision of the manu-

script for important intellectual content and approved the final version of the manuscript.

^d Postgraduate Student, Department of Stomatological Hospital of Chongqing Medical University, Chongqing, China. Chongqing Key Laboratory of Oral Diseases and Biomedical Sciences, Chongqing; Chongqing Municipal Key Laboratory of Oral Biomedical Engineering of Higher Education, Chongqing, China. Designed the study, collected the data, read and approved the final manuscript.

^e Professor, Department of Stomatological Hospital of Chongqing Medical University, Chongqing, China. Chongqing Key Laboratory of Oral Diseases and Biomedical Sciences, Chongqing; Chongqing Municipal Key Laboratory of Oral Biomedical Engineering of Higher Education, Chongqing, China. Obtained funding, designed the study, read and approved the final manuscript.

Correspondence: Dr Yun Hu, Stomatological Hospital of Chongqing Medical University, No.426 Songshibei Road, Yubei District, Chongqing 401147, China.
e-mail: 500188@hospital.cqmu.edu.cn

Pulp necrosis occurring in immature and mature permanent teeth may require different treatment methods, considering the fact that this pathology can arrest the root development of immature teeth. Regenerative endodontic procedures (REPs) have been proposed for the treatment of immature teeth with pulp necrosis in clinical practice.^{43,52} The treatment provides a favourable environment for cell proliferation and tissue regeneration to promote root development by means of root canal disinfection, preservation of residual pulp tissue, induction of apical bleeding, an intracanal barrier and adequate restoration of the access cavity.

In 2007, Murray et al³⁹ of the American Association of Endodontists proposed ‘regenerative endodontic procedures’, which could better reflect the connotation of tissue engineering in pulp treatment. The ideal histophysiological process of pulp regeneration is the formation of non-mineralised pulp tissue and mineralised dentin. However, some studies^{29,57} found that the structure of the new tissues in the root canal was disordered, showing bone-like, cementum-like, and connective tissue, containing fibroblasts and blood vessels, which was not true regeneration. Therefore, on the molecular level, the term ‘guided endodontic repair (GER)’ proposed by Diogenes et al¹⁵ can be used to describe this process more accurately and conservatively. In consideration of this study’s focus on clinical and radiological results, ‘regenerative endodontic procedures’ was still used to describe this procedure.

The concept of regenerative endodontics has been extended to cover necrotic mature permanent teeth, elucidating the potential of REPs to be used as substitution therapy for mature teeth with pulp necrosis. Without the concern about thickening of root canal and apical closure, REPs still have great application potential when performed in necrotic mature permanent teeth, by virtue of their being less technique sensitive and requiring less chair time.²⁵ In contrast to conventional root canal treatment, REPs usually induce blood clotting to achieve biological obturation and encourage repair, rather than mechanical obturation e.g. with gutta-percha, resulting in the acquisition of immune defense mechanisms to resist reinfection. Despite the advantages of REPs, their clinical application in necrotic mature permanent teeth remains questionable. These doubts about the effect of REPs on necrotic mature permanent teeth mainly stem from differences in the apical foramen and cellular composition between mature and immature permanent teeth.²⁰ Regarding the apical foramen, which is the limitation for apical pathways of stem cell migration and rush of blood, it has been suggested that the success rate of pulpal healing was significantly reduced, becoming unpredictable when the diameter of the apical foramen was less than 1 mm.⁶ However, there have been successful cases of revascularisation with an apical foramen smaller than 1.0 mm in diameter.⁵⁰ As for cellular composition, which forms the biological basis of regenerative endodontics, there are more stem cells in immature permanent teeth than in mature permanent teeth.⁴⁴ Despite mechanised instrumentation in mature teeth (as opposed to passive intracanal decontamination in immature teeth), Lovelace et al³⁵ showed that induced bleeding could result in the accumulation of large numbers of undifferentiated stem cells into the root canal space of immature permanent teeth.

Similarly, Chrepa et al¹⁴ showed that induced bleeding in REPs could also bring about a substantial influx of mesenchymal stem cells (MSCs) into the root canal of mature permanent teeth, indicating a biologically similar theoretical framework. It is worth emphasising that the stage of root development is a multifactorial condition that not only involves the apical foramen and cellular composition. For tooth autotransplantation, the stage of root development was found to be significantly correlated with the prognosis, as shown by the significantly increased chance of pulp healing with divergent and parallel apical roots.²⁸ Similar studies on REPs are lacking.

Previous systematic reviews and meta-analyses summarised the effectiveness of REPs applied to immature or mature permanent teeth with pulp necrosis, but did not compare them with unified standards.^{19,43,51} Since the publication of those analyses, more studies have emerged, justifying a new systematic analysis of the existing evidence. Thus, we performed a systematic review and meta-analysis with the aim of comparing the clinical efficacy of REPs applied to necrotic immature and mature permanent teeth and exploring whether the stage of root development affects the effectiveness of REPs from a clinical perspective. The focused research question was defined according to the PICOS (population, intervention, comparison, outcome, study design) format: ‘As assessed by randomised controlled trials, is there any difference in the clinical efficacy of REPs for the treatment of immature and mature permanent teeth with pulp necrosis?’

MATERIAL AND METHODS

Protocol and Registration

This systematic review and meta-analysis was written following the Preferred Reporting Items for Systematic Reviews and Meta-Analyses (PRISMA) statement. The protocol was registered in the PROSPERO database (registration number: CRD42021242976).

Search Strategy

Electronic searches were conducted in the PubMed, Cochrane Library, Web of Science, EMBASE and OpenGrey databases. The search results, limited to the English language, covered publications up to 17th February, 2022; there were no restrictions on the year of publication of the included studies. The publications mentioned in the relevant studies were also incorporated. The search terms revolved around “regenerative endodontics” and were linked together by the Booleans “AND” and “OR”. The complete search strategies are available in Table 1. The titles and abstracts of the literature obtained from the search were screened independently by two reviewers. For publications that met the requirements, the full texts were reviewed according to the inclusion and exclusion criteria. When there was a disagreement between the two reviewers, a third reviewer joined, and the disagreement was resolved by consensus.

Eligibility and Exclusion Criteria

Eligibility and exclusion criteria were defined according to PICOS (population, intervention, comparison, outcome, study design) and language formats, as shown in Table 2.

Table 1 Complete search strategies

| Database | Search terms used |
|------------------|---|
| PubMed | (((((Endodonic, Regenerative[Title/Abstract]) OR (Regenerative Endodonic[Title/Abstract])) OR (Endodontics, Regenerative[Title/Abstract])) OR (pulp revascularization[Title/Abstract]) OR (pulpal regeneration[Title/Abstract]) OR (pulp revitalization[Title/Abstract]) OR (root canal revascularization[Title/Abstract]) OR (root maturation[Title/Abstract]) OR (regenerative endodontic*[Title/Abstract]) OR (regenerative endodontic therapy[Title/Abstract]) OR (regenerative endodontic treatment*[Title/Abstract]) OR (regenerative endodontic procedure*[Title/Abstract]) OR ("Regenerative Endodontics"[Mesh])) OR (pulp regeneration[Title/Abstract])) |
| Cochrane Library | (Regenerative Endodontic):ti,ab,kw OR (pulp revascularization):ti,ab,kw OR (pulpal regeneration):ti,ab,kw OR (pulp revitalization):ti,ab,kw OR (root canal revascularization):ti,ab,kw OR (regenerative endodontic therapy):ti,ab,kw OR (regenerative endodontic treatment):ti,ab,kw OR (regenerative endodontic procedure):ti,ab,kw OR (pulp regeneration):ti,ab,kw (Word variations have been searched) |
| Web of Science | (TS=(Regenerative Endodontic) OR TS=(pulp revascularization) OR TS=(pulpal regeneration) OR TS=(pulp revitalization) OR TS=(root canal revascularization) OR TS=(regenerative endodontic therapy) OR TS=(regenerative endodontic treatment) OR TS=(regenerative endodontic procedure) OR TS=(pulp regeneration)) AND TS=(teeth) |
| EMBASE | regenerative endodontic':ti,ab,kw OR 'pulp revascularization':ab,ti OR 'pulpal regeneration':ti,ab,kw OR 'pulp revitalization':ti,ab,kw OR 'root canal revascularization':ti,ab,kw OR 'regenerative endodontic therapy':ti,ab,kw OR 'regenerative endodontic treatment':ti,ab,kw OR 'regenerative endodontic procedure':ti,ab,kw OR 'pulp regeneration':ti,ab,kw |
| OpenGrey | Regenerative Endodontics |
| Manual search | In references lists of included studies, relevant review articles, and relevant endodontic journals |

Table 2 Eligibility and exclusion criteria

| Items | Eligibility criteria | Exclusion criteria |
|-----------------------------|---|---|
| Population | Permanent teeth with pulp necrosis | Primary teeth |
| Intervention and comparison | Treatment of necrotic immature or mature permanent teeth using any REPs that tried to achieve pulp revascularisation or regeneration regardless of the use of scaffolds, intracanal medication and stem cells | Not recounting the details of the treatment procedure |
| Outcome | Clinical and radiographic indicators including success rate, asymptomatic rate, pulp sensitivity rate, and/or discolouration rate | Less than 6 months of follow-up |
| Study design | Randomised controlled trials | In-vitro, non-randomised or animal studies |
| Language | Studies in English | Studies not in English |

Data Extraction

The extracted information, including general information, study procedure details and outcome data, was tabulated. The extracted information consisted of: first author(s), year of publication, journal name, research grouping, patient age, sample size, type of teeth, aetiology, irrigation protocol, intracanal disinfection medication, cell/type of scaffold, use of matrix, barrier material, follow-up duration, clinical symptoms and radiological results.

In addition, randomisation methods, data measurements, and statistical analysis methods were documented.

Risk of Bias

All studies included in our study were randomised controlled trials. We used the Cochrane Risk of Bias 2.0 tool which supplies a framework for assessing the risk of bias in the findings regard-

less of the type of randomised trial.⁵⁶ The evaluation was conducted independently and in duplicate by two reviewers. Any disagreement was resolved by discussion with a third author.

Study Subjects and Outcomes

Immature permanent teeth were defined as teeth with open apices, and mature permanent teeth were defined as teeth with apical diameters of less than 1 mm. The asymptomatic sign was defined as the absence of any clinical symptoms (i.e. sinus tract, swelling, pain on percussion/palpation). Success was defined as the absence of any clinical symptoms with the reduction or elimination in the size of the periapical lesion. Pulp sensitivity was defined as the positive response to sensitivity testing including heat, cold and (or) electric pulp tests. Discolouration was defined as the changes in crown surface colour.

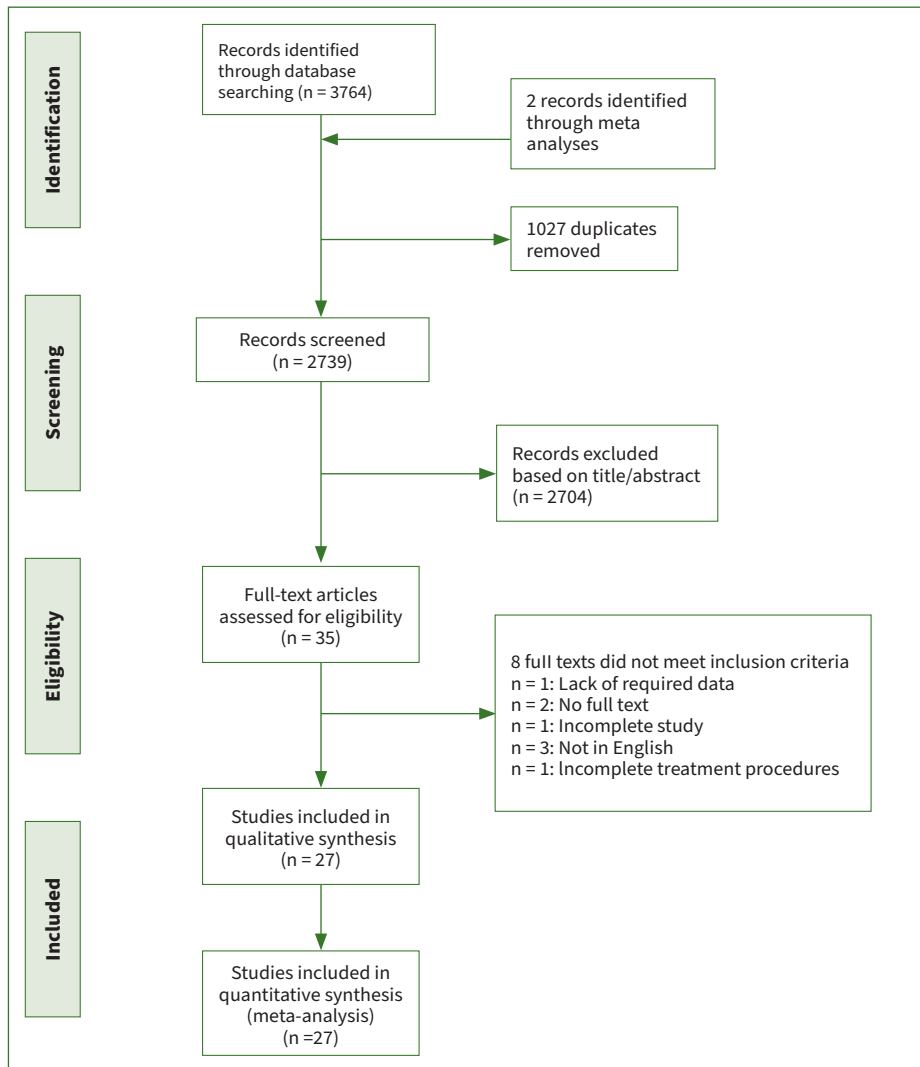


Fig 1 The flow diagram of the study screening and selecting procedure.

Statistical Analysis

The Cohen kappa test was determined to assess the reliability of the two reviewers in the literature search, the data extraction and the quality evaluation. Considering heterogeneity, the random effects model was used to explain the results. Indirect comparisons were performed using pooled estimates for each outcome according to the grouping.^{4,55} Heterogeneity was denoted by I^2 . When $I^2 > 50\%$, it indicated large heterogeneity across individual studies.²¹ Comprehensive Meta-Analysis Version 2 (Biostat; Englewood, NJ, USA) was used to perform the statistical analyses. For statistical analysis of indirect comparisons, statistical significance was set at $p \leq 0.05$.

Additional Analyses

Sensitivity analysis was performed by eliminating individual studies. Each time a study was deleted, a new meta-analysis was conducted with an evaluation of whether the effect size changed. If the result after deletion was statistically significantly different from the previous result, the study would be considered to have a statistically significant impact on the total effect size.

RESULTS

Study Selection

All kappa values were above 0.75. A total of 3764 articles were initially identified from the selected databases, and two studies were identified through a manual search. After removal of duplicates, 2739 articles were screened by reading their titles and abstracts. Thirty-five articles met the requirements of inclusion based on their titles and abstracts. Subsequently, the full-text assessment resulted in the exclusion of 8 articles, and the reasons for their exclusion are shown in the Fig 1. Ultimately, 27 articles^{1,2,5,7,10,12,17,18,23-27,34,38,40-42,45-49,53,54,58,59} adhered to the inclusion criteria for meta-analysis.

Study Characteristics

In these 27 publications, 854 teeth were included, including 676 immature and 178 mature permanent teeth. The follow-up duration range of the included studies ranged from 12 to 28.25 months. The publication year ranged from 2012 to 2022. Diagnosis of pulp necrosis and outcome assessments were

Table 3 Details of the included studies

| First author, year | Sample | Age | Tooth | Cause of necrosis | Irrigation protocol | Intracanal medication | Cell/scaffold | Use of matrix | Capping material | Follow-up duration |
|------------------------|----------|-------------|-------------|-------------------------------|---|-----------------------|------------------------|-----------------------------------|------------------|--------------------|
| EISheshtawy [18] 2020 | 31 teeth | 12.66 years | Anterior IM | Trauma/ developmental anomaly | First: 5.25% NaOCl (20 ml) Second: 2.5% NaOCl (20 ml), sterile saline (20 ml), 17% EDTA (10 ml) | TAP | BC/PRP | Collagen | MTA | 12 months |
| Jadhav [23] 2012 | 20 teeth | 19.9 years | Anterior IM | Not specified | 2.5% NaOCl | TAP | BC/PRP | Metronidazole containing collagen | RMGIC | 12 months |
| Ragab [45] 2019 | 22 teeth | 9.86 years | Anterior IM | Trauma | 5% NaOCl (20 ml)+ sterile saline | DAP | BC/PRF | NO | grey MTA | 12 months |
| Rizk [46] 2020a | 26 teeth | 9.08 years | Anterior IM | Trauma | First: 2% NaOCl (20 ml), 17% EDTA (20 ml) Second: sterile saline (20 ml), 17% EDTA (20 ml) | TAP | PRP/PRF | Collagen | MTA | 12 months |
| Aly [5] 2019 | 26 teeth | 8.96 years | Anterior IM | Trauma /caries | First: 1.5% NaOCl (20 ml), sterile saline (20 ml) Second: 17% EDTA (20 ml) | DAP | BC | NO | Biodentine/ MTA | 12 months |
| Nagata [40] 2014 | 23 teeth | 7-17 years | Anterior IM | Trauma | First: 6% NaOCl (20 ml), sterile saline (10 ml), 2% CHX (10 ml) Second: 17% EDTA (3 ml), sterile saline | TAP/CHP | BC | Collagen | MTA | 15 months |
| Jha [25] 2019 | 15 teeth | 9-15 years | M | NR | First: 2.5% NaOCl Second: 17% EDTA | TAP | BC | NO | Cavit G | 18 months |
| Rizk [47] 2019 | 26 teeth | 9.08 years | Incisor IM | Trauma | First: 2% NaOCl (20 ml), 17% EDTA (20 ml) Second: sterile saline (10 ml), 17% EDTA (20 ml) | TAP | BC/PRP | Collagen | MTA | 12 months |
| Rizk [48] 2020b | 26 teeth | 9.08 years | Incisor IM | Trauma | First: 2% NaOCl (20 ml), 17% EDTA (20 ml) Second: sterile saline (10 ml), 17% EDTA (20 ml) | TAP | BC/PRF | Collagen | MTA | 12 months |
| Arslan [7] 2019 | 28 teeth | 20.58 years | M | NR | First: 1% NaOCl (5 ml/canal), 5% EDTA (5 ml/canal) Second: 1% NaOCl (5 ml), 5% EDTA (2 ml), 5 ml distilled water | TAP | BC | NO | MTA | 12 months |
| Brizuela [12] 2020 | 18 teeth | 27.0 years | M | NR | First: 2.5% NaOCl (20 ml) Second: 17% EDTA (20 ml) | Ca(OH) 2 | BC+UC-MSC | Collagen | Biodentine | 12 months |
| Alagl [2] 2017 | 32 teeth | 9.47 years | IM | Trauma /caries | First: 2.5% NaOCl (20 ml), 0.12%CHX (10 ml), sterile saline (20 ml) Second: 17% EDTA (20 ml), saline | TAP | BC/PRP | NO | MTA | 12 months |
| Bezgin [10] 2015 | 21 teeth | 9.95 years | IM | Trauma /caries | First: 2.5% NaOCl (20 ml), 0.12% CHX (10 ml), sterile saline (20 ml) Second: 5% EDTA (20 ml), sterile saline (20 ml) | TAP | BC/PRP | NO | MTA | 18 months |
| El-Kateb [17] 2020 | 18 teeth | 25.5 years | Anterior M | Trauma/ defective restoration | First: 1.5% NaOCl (20 ml) Second: 1.5% NaOCl (20 ml), 17% EDTA (20 ml) | Ca(OH) 2 | BC | NO | Biodentine | 12 months |
| Jiang [27] 2017 | 46 teeth | 10.1 years | IM | Trauma/ developmental anomaly | First: 1.25% NaOCl saline Second: 17% EDTA | Ca(OH) 2 | BC | Bio-Gide/NO | MTA | 15.6 months |
| Lin [34] 2017 | 80 teeth | 10.5 years | IM | Trauma/ developmental anomaly | First: 1.5% NaOCl (20 ml), 17% EDTA (20 ml), 0.9% saline Second: 0.9% saline, 17% EDTA (20 ml) | TAP | BC | Collagen | MTA | 12 months |
| Nagy [41] 2014 | 24 teeth | 10.9 years | Anterior IM | NR | First: 2.6% NaOCl (10 ml) Second: 2.6% NaOCl (10 ml), sterile saline (10 ml) | TAP | BC | NO/Hydrogel | MTA | 18 months |
| Santhakumar [49] 2018 | 40 teeth | 7-12 years | Anterior IM | NR | 3% NaOCl, saline | TAP | PRF | NO | MTA | 18 months |
| Shivashankar [54] 2017 | 60 teeth | 6-28 years | Anterior IM | Trauma /caries | First: 5.25% NaOCl Second: sterile saline | TAP | BC/PRF/ PRP | NR | MTA | 12 months |
| Sharma [53] 2016 | 16 teeth | 10-25 years | Anterior IM | Trauma | 2.5% NaOCl | TAP | BC/PRF/ Collagen/ PLGA | Collagen | Glass ionomer | 12 months |
| Ulusoy [58] 2019 | 88 teeth | 8-11 years | Anterior IM | Trauma | First: 1.25% NaOCl (20 ml) Second: sterile saline (10 ml), 17% EDTA (10 ml) | TAP | BC/PRF/ PRP/PP | NO | MTA | 28.25 months |
| Narang [42] 2015 | 15 teeth | <20 years | IM | Not specified | 2.5% NaOCl | TAP | BC/PRP/ PRF | Collagen | RMGIC | 18 months |
| Youssef [59] 2022 | 20 teeth | 18-40 years | Anterior M | Not specified | First: 1.5% NaOCl (20 ml), 17% EDTA (20 ml) Second: 0.9% saline, 17% EDTA (20 ml) | Ca(OH)2 | BC/PRF | NO | MTA | 12 months |
| Abielhassan [1] 2021 | 45 teeth | 18-50 years | Anterior M | Not specified | 1.25% NaOCl, 17% EDTA+ LASER/0.2% Nano Chitosan irrigation | NR | PRF | Collagen | Biodentine | 12 months |
| Jayadevan [24] 2021 | 27 teeth | 8-30 years | Anterior IM | Trauma | First: 1.5% NaOCl, 0.9% saline, 17% EDTA Second: 0.9% saline, 17% EDTA | TAP | A-PRF/ PRF | NO | Biodentine | 12 months |
| Jiang [26] 2021 | 76 teeth | 7-15 years | IM | Trauma/ developmental anomaly | 17% EDTA | NR | BC | Bio-Gide Collagen/NO | MTA | >6 months |
| Mittal [38] 2021 | 36 teeth | 16-34 years | M | Not specified | First: 1.5% NaOCl, saline Second: 1.5% NaOCl, saline, 17% EDTA | DAP | BC/PRF | Collagen/NO/ Hydroxyapatite | Biodentine | 12 months |

CHX: chlorhexidine; CH: calcium hydroxide apexification; MTA: mineral trioxide aggregate apexification; BC: blood clot revascularisation; TAP: triple antibiotic paste; EDTA: ethylenediaminetetraacetic acid; RMGIC: resin-modified glass-ionomer cement; UC-MSC: human umbilical cord mesenchymal stem cells. NR: not reported; IM: immature; M: mature.

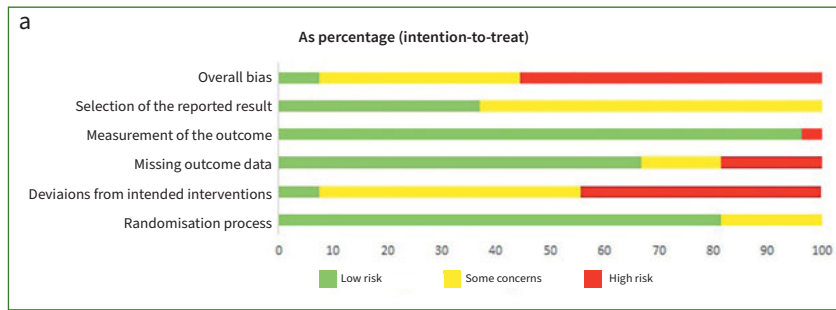
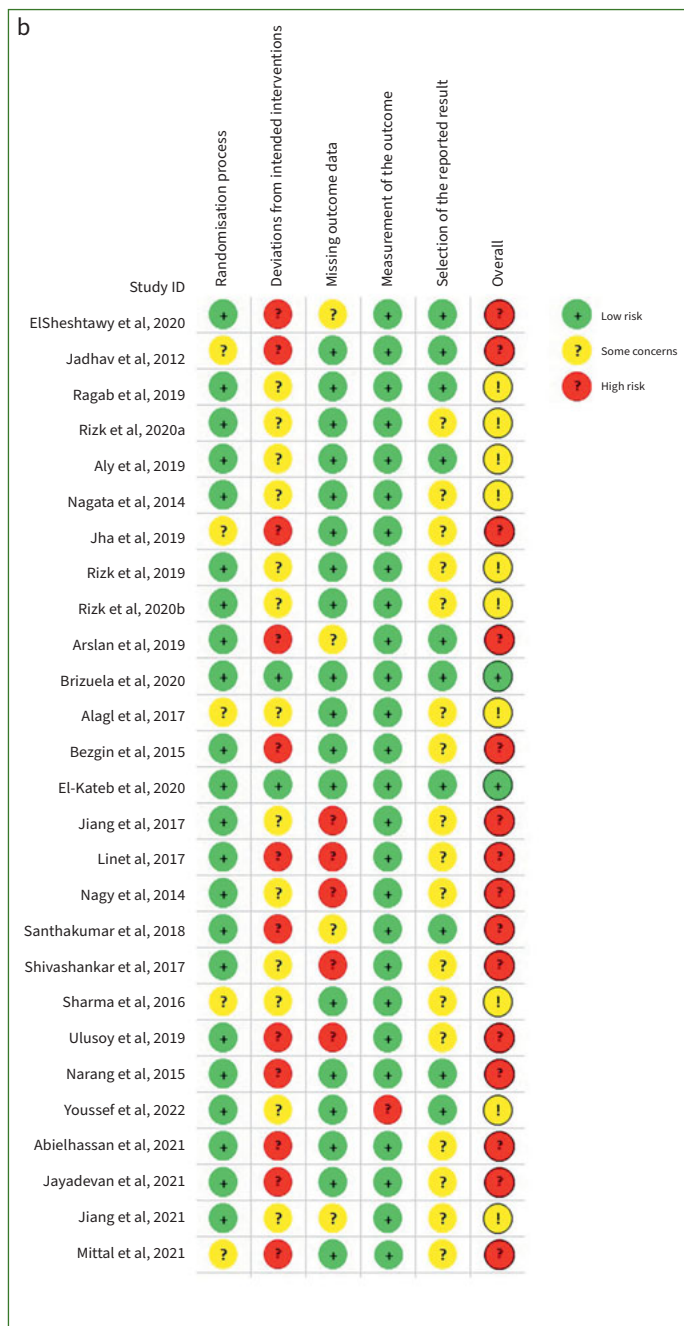


Fig 2 a. risk of bias graph; b. risk of bias summary.



based on an overall analysis taking into account the aetiology, clinical symptoms and imaging data in the included studies. Only 7 studies^{7,10,18,24,26,27,40} included all outcome indicators. The aetiology of pulp necrosis was mostly trauma, caries, and developmental anomalies. The most commonly used intracanal medication was triple antibiotic paste (TAP). The most common type of capping material was mineral trioxide aggregate (MTA). Only in one study¹² were allogenic umbilical cord mesenchymal stem cells placed into the blood clot. Grouping was accomplished through differences in the scaffold/collagen, treatment method, root canal medication, apical diameter, and capping material. Details of the included studies are summarised in Table 3.

Risk of Bias

All included studies were RCTs. Loss of follow-up led to missing outcome data in some of these studies.

1. Randomisation process: 22 trials were ranked as ‘low risk’, while 5 trials were ranked as ‘some concerns’.
2. Deviations from intended interventions: 12 trials were ranked as ‘high risk’, 13 trials were ranked as ‘some concerns’ and 2 trials were ranked as ‘low risk’.
3. Missing outcomes data: 5 trials were ranked as ‘high risk’, 4 trials were ranked as ‘some concerns’ and 18 trials were ranked as ‘low risk’.
4. Measurement of the outcome: a total of 26 trials were ranked as ‘low risk’ while one trial was ranked as ‘high risk’.
5. Selection of the reported results: 10 trials were ranked as ‘low risk’, while 17 trials were ranked as ‘some concerns’.

In the bias assessment, 15 articles were considered high risk, 10 articles were considered concerning and 2 articles were considered low risk.

The quality assessment details of the RCTs are shown in Fig 2.³⁷

Results of Individual Studies and Data Synthesis

The outcome measures of the included studies are shown in Table 4. The results are expressed as percentages. The primary outcome measure was the success rate.

Table 4 Results of the studies

| First author, year | Group | Sample | Asymptomatic sign | Success | Sensibility pulp testing | Discolouration |
|------------------------|--------------------------|----------|-------------------|-------------|---------------------------------------|----------------|
| ElSheshtawy. [18] 2020 | BC | 17 teeth | 15 (88.2%) | NR | 0 (0%)-HPT&EPT | 14 (82.4%) |
| | PRP | 13 teeth | 12 (92.3%) | | 0 (0%)-HPT&EPT | 11 (84.6%) |
| Jadhav [23] 2012 | BC | 10 teeth | 10 (100%) | 10 (100%) | NR | NR |
| | PRP | 10 teeth | 10 (100%) | 10 (100%) | | |
| Ragab [45] 2019 | BC | 11 teeth | 11 (100%) | 11 (100%) | NR | 11 (100%) |
| | PRF | 11 teeth | 11 (100%) | 11 (100%) | | 11 (100%) |
| Rizk [46] 2020a | PRP | 13 teeth | 13 (100%) | 13 (100%) | 0 (0%)-CPT&HPT&EPT | NR |
| | PRF | 12 teeth | 12 (100%) | 12 (100%) | 0 (0%)-CPT&HPT&EPT | |
| Aly [5] 2019 | Biodentine | 13 teeth | 13 (100%) | NR | NR | 1 (7.69%) |
| | MTA | 12 teeth | 11 (91.67%) | | | 7 (58.33%) |
| Nagata [40] 2014 | TAP | 12 teeth | 11 (91.67%) | 11 (91.67%) | 0 (0%)-CPT&EPT | 10 (83.3%) |
| | CHP | 11 teeth | 11 (100%) | 10 (90.9%) | 0 (0%)-CPT&EPT | 3 (27.3%) |
| Jha [25] 2019 | BC | 15 teeth | 15 (100%) | 15 (100%) | NR | NR |
| Rizk [47] 2019 | BC | 13 teeth | 13 (100%) | 13 (100%) | 0 (0%)-CPT&HPT&EPT | NR |
| | PRP | 13 teeth | 13 (100%) | 13 (100%) | 0 (0%)-CPT&HPT&EPT | |
| Rizk [48] 2020b | BC | 12 teeth | 12 (100%) | 12 (100%) | 0 (0%)-CPT&HPT&EPT | |
| | PRF | 12 teeth | 12 (100%) | 12 (100%) | 0 (0%)-CPT&HPT&EPT | |
| Arslan [7] 2019 | BC | 26 teeth | 26 (100%) | 24 (92.31%) | 13 (50%)-EPT | 10 (38.46%) |
| Briuzela [12] 2020 | BC+UC-MSc | 18 teeth | 18 (100%) | NR | 9 (50%)-CPT; 5 (28%)-HPT; 6 (33%)-EPT | NR |
| Alagl [2] 2017 | BC | 15 teeth | 15 (100%) | 15 (100%) | 13 (86.7%)-CPT&EPT | NR |
| | PRP | 15 teeth | 15 (100%) | 15 (100%) | 6 (40%)-CPT&EPT | |
| Bezgin [10] 2015 | BC | 10 teeth | 10 (100%) | 9 (90%) | 2 (20%)-CPT&EPT | 12 (60%) |
| | PRP | 10 teeth | 10 (100%) | 10 (100%) | 5 (50%)-CPT&EPT | |
| El-Kateb [17] 2020 | X3 | 9 teeth | 9 (100%) | 9 (100%) | 7 (77.8%)-CPT; 6 (66.7%)-EPT | NR |
| | X5 | 9 teeth | 9 (100%) | 9 (100%) | 8 (88.9%)-CPT; 8 (88.9%)-EPT | |
| Jiang [27] 2017 | Bio-Gide | 21 teeth | 21 (100%) | 21 (100%) | 7 (33%)-EPT | 15 (71%) |
| | BC | 22 teeth | 22 (100%) | 22 (100%) | 4 (18%)-EPT | 14 (64%) |
| Lin [34] 2017 | BC | 69 teeth | 69 (100%) | 69 (100%) | NR | 30 (43.5%) |
| Nagy [41] 2014 | BC | 10 teeth | NR | 9 (90%) | NR | NR |
| | BC+ Hydrogel | 10 teeth | | 8 (80%) | | |
| Santhakumar [49] 2018 | PRF gel | 19 teeth | 18 (94.7%) | 18 (94.7%) | NR | NR |
| | PRF membrane | 19 teeth | 18 (94.7%) | 18 (94.7%) | | |
| Shivashankar [54] 2017 | BC | 15 teeth | 15 (100%) | 15 (100%) | 2 (13.3%)-CPT&EPT | NR |
| | PRF | 20 teeth | 20 (100%) | 18 (90%) | 3 (15%)-CPT&EPT | |
| | PRP | 19 teeth | 19 (100%) | 19 (100%) | 3 (15.8%)-CPT&EPT | |
| Sharma [53] 2016 | BC | 4 teeth | 4 (100%) | 4 (100%) | NR | NR |
| | PRF | 4 teeth | 4 (100%) | 4 (100%) | | |
| | BC+Collagen | 4 teeth | 4 (100%) | 4 (100%) | | |
| | BC+PLGA | 4 teeth | 4 (100%) | 4 (100%) | | |
| Ulusoy [58] 2019 | BC | 21 teeth | 20 (95.2%) | 20 (95.2%) | 15 (71.4%)-CPT&EPT | NR |
| | PRF | 17 teeth | 16 (94.1%) | 16 (94.1%) | 11 (64.7)-CPT&EPT | |
| | PRP | 18 teeth | 18 (100%) | 18 (100%) | 11 (61.1%)-CPT&EPT | |
| | PP | 17 teeth | 17 (100%) | 17 (100%) | 13 (76.5%)-CPT&EPT | |
| Narang [42] 2015 | BC | 5 teeth | 5 (100%) | 5 (100%) | NR | NR |
| | PRF | 5 teeth | 5 (100%) | 5 (100%) | | |
| | PRP+Collagen | 5 teeth | 5 (100%) | 5 (100%) | | |
| Youssef [59] 2022 | BC | 10 teeth | NR | NR | 2 (20%)-EPT | NR |
| | PRF | 10 teeth | | | 5 (50%)-EPT | |
| Abielhassan [1] 2021 | LASER disinfection | 15 teeth | 15 (100%) | NR | 10 (66.7%)-EPT | NR |
| | Nano Chitosan irrigation | 15 teeth | 14 (93.3%) | | 11 (73.3%)-EPT | |
| | Conventional irrigation | 15 teeth | 14 (93.3%) | | 7 (46.7%)-EPT | |
| Jayadevan [24] 2021 | A-PRF | 14 teeth | 11 (78.5%) | 11 (78.5%) | 0 (0%)-CPT&EPT | 9 (82%) |
| | PRF | 13 teeth | 10 (77%) | 10 (77%) | 0 (0%)-CPT&EPT | 7 (70%) |
| Jiang .[26] 2021 | Bio-Gide Collagen | 38 teeth | 38 (100%) | 38 (100%) | 12 (31.6%)-EPT | 28 (74%) |
| | NO Collagen | 38 teeth | 38 (100%) | 38 (100%) | 7 (18.4%)-EPT | 28 (74%) |
| Mittal [38] 2021 | BC | 9 teeth | 9 (100%) | 9 (100%) | 1 (11.1%)-CPT; 0 (0%)-HPT; 0 (0%)-EPT | NR |
| | PRF | 9 teeth | 9 (100%) | 9 (100%) | 6 (66.6%)-CPT; 0 (0%)-HPT; 0 (0%)-EPT | |
| | Collagen | 9 teeth | 9 (100%) | 9 (100%) | 4 (44.4%)-CPT; 0 (0%)-HPT; 0 (0%)-EPT | |
| | Hydroxyapatite | 9 teeth | 9 (100%) | 9 (100%) | 3 (33.3%)-CPT; 0 (0%)-HPT; 0 (0%)-EPT | |

NR: no report; EPT: electrical pulp test; CPT: cold pulp test; HPT: heat pulp test; UC-MSCs: human umbilical cord MSCs; X3&X5: files in different types.

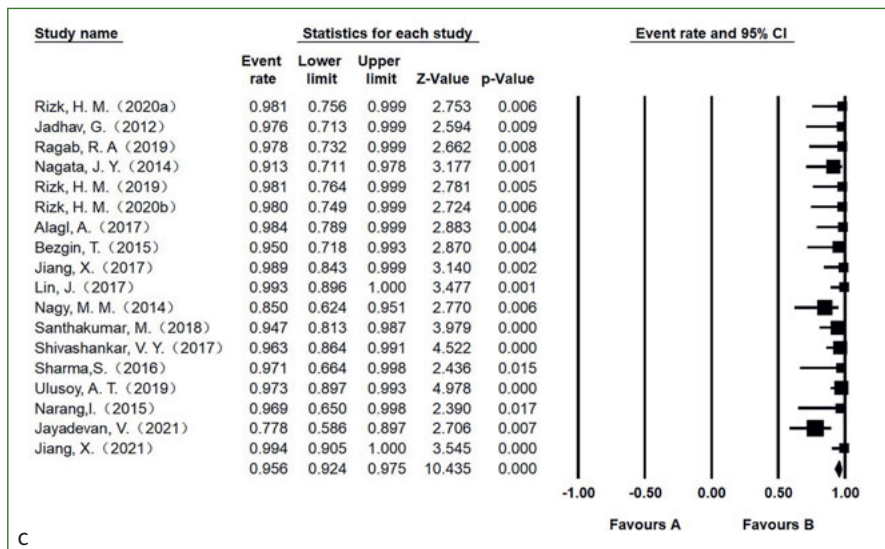
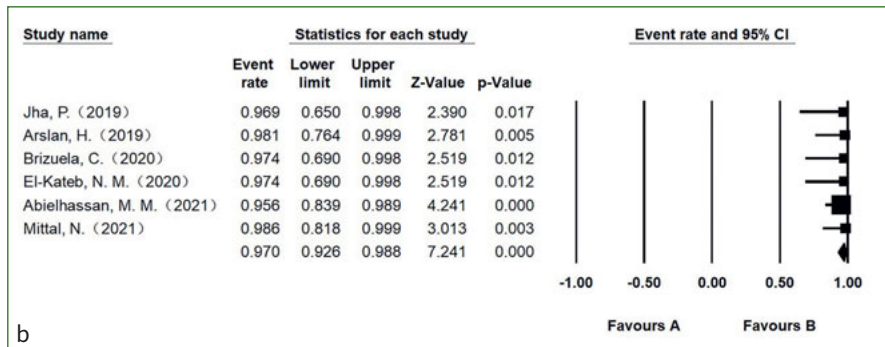
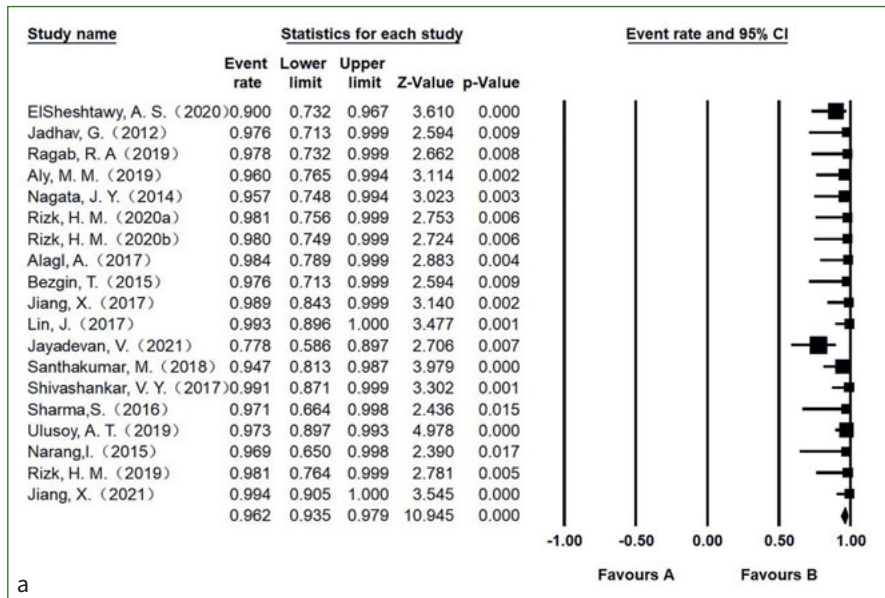


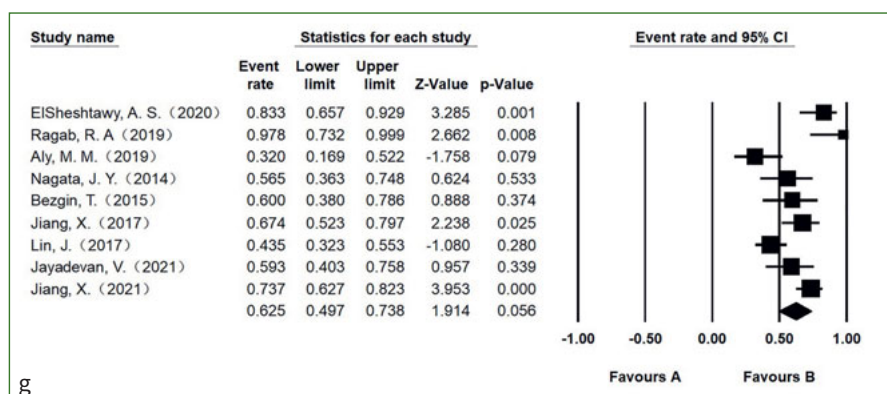
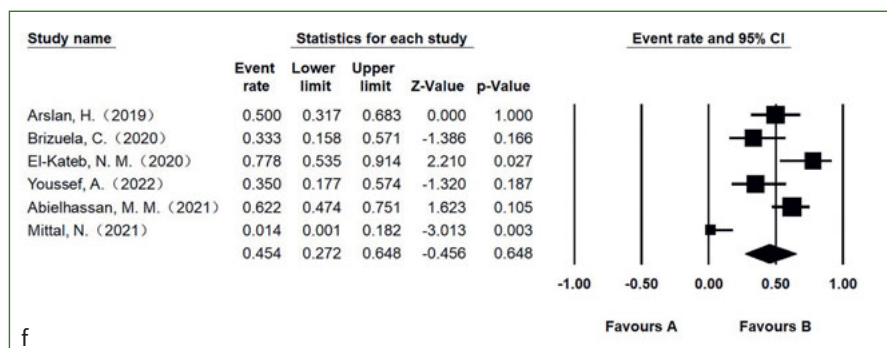
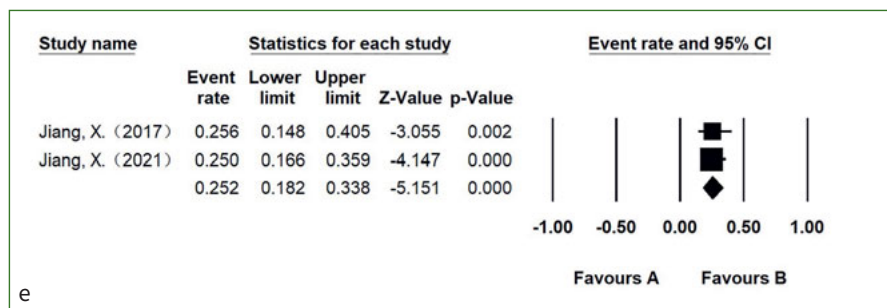
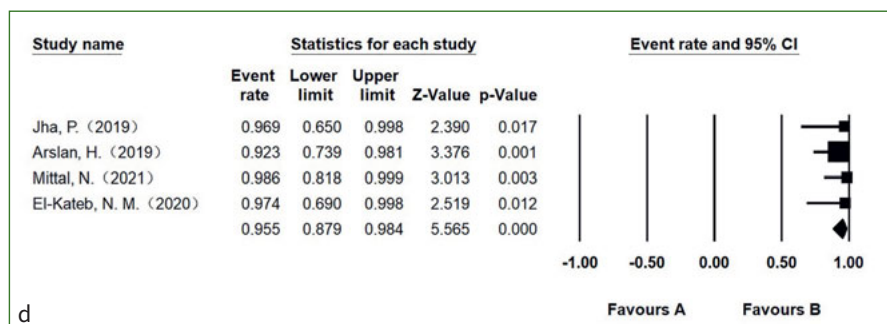
Fig 3 Forest plots of a. symptom rate of necrotic immature permanent teeth; b. symptom rate of necrotic mature permanent teeth; c. success rate of necrotic immature permanent teeth.

Asymptomatic Rate

For necrotic immature permanent teeth, a total of 19 studies reported this outcome indicator with an asymptomatic rate of 96.2% (95% CI, 93.5%-97.9%; I²=30.1%) (Fig 3a). Regarding ne-

crotic mature permanent teeth, a total of 6 studies reported this outcome indicator with an asymptomatic rate of 97.0% (95% CI, 92.6%-98.8%; I²=0) (Fig 3b). There was no statistically significant difference in the rate of asymptomatic signs be-

Fig 3 (cont'd) Forest plots of d. success rate of necrotic mature permanent teeth; e. pulp sensitivity rate of necrotic immature permanent teeth; f. pulp sensitivity rate of necrotic mature permanent teeth; g. discolouration rate of necrotic immature permanent teeth.



tween necrotic immature permanent teeth and necrotic mature permanent teeth ($p=0.68$).

Success Rate

The success rate of necrotic immature permanent teeth, reported in 18 studies, was 95.6% (95% CI, 92.4%-97.5%; $I^2=34.9\%$)

(Fig3c). The success rate of necrotic mature permanent teeth, reported in 4 studies, was 95.5% (95% CI, 87.9%-98.4%; $I^2=0$) (Fig3d). There was no statistically significant difference in the rate of success between necrotic immature permanent teeth and necrotic mature permanent teeth ($p=0.97$).

Pulp Sensitivity Rate

The pooled estimate for the rate of positive response to the electrical pulp test (EPT) in 2 necrotic immature permanent teeth studies was 25.2% (95% CI, 18.2%-33.8%; $I^2=0\%$) (Fig 3e). The pooled estimate for the rate of positive response to EPT in 6 necrotic mature permanent teeth studies was 45.4% (95% CI, 27.2%-64.8%; $I^2=75.2\%$) (Fig 3f). There was a statistically significant difference in the rate of positive response to EPT between necrotic immature permanent teeth and necrotic mature permanent teeth ($p=0.03$).

The pooled estimate for the rate of positive response to both the cold pulp test and EPT in 9 necrotic immature permanent teeth studies was 14.5% (95% CI, 4.9%-35.6%; $I^2=88.6\%$). The pooled estimate for the rate of positive response to the cold pulp test in 3 necrotic mature permanent teeth studies was 57.0% (95% CI, 31.0%-79.6%; $I^2=75.7\%$). The pooled estimate for the rate of positive response to the heat pulp test in 2 necrotic mature permanent teeth studies was 8.6% (95% CI, 0.4%-70.4%; $I^2=79.3\%$).

Discolouration Rate

Discolouration was reported in 9 studies of necrotic immature permanent teeth, with a rate of 62.5% (95% CI, 49.7%-73.8%; $I^2=76.1\%$) (Fig 3g). Only one study⁷ reported discolouration data for necrotic mature permanent teeth, with a discolouration rate of 38%.

Additional Analyses

We adopted the method of eliminating single studies and found that most of the effect sizes of the two groups did not change statistically significantly. This result indicated that these study results were stable and that the sensitivity was low. Unlike most effect sizes, the effect size of positive response to the cold pulp test in the mature permanent teeth group, the heterogeneity decreased from 75.7% to 0%, and the incidence decreased from 57.0% to 42.6% when one study¹⁷ was removed. Considering that there were only two remaining studies after it was eliminated (which may have led to larger errors) and taking into account the variety of sensitivity tests, we kept that study.

DISCUSSION

The presented evidence was acquired solely from RCTs. The results of the two groups were indirectly compared,⁴ and there was a high risk of bias. The findings were consistent, except that the results for pulp sensitivity varied widely among the studies.

Since the presence of symptoms after treatment is directly related to patient satisfaction, the presence of asymptomatic signs is considered one of the outcome indicators and is discussed separately from the success rate. The results of this study showed that both necrotic immature and mature permanent teeth had high asymptomatic rates of 96.2% and 97.0%. Symptoms may be caused by incomplete crown closure and incomplete root canal disinfection. In routine REPs, MTA used as a pulp capping material is generally considered to have excellent impermeability. However, crown leakage might occur in

the treated teeth after REPs, and the ability of MTA to resist bacterial penetration is questionable.⁹ All related studies have attempted to strike a balance between thorough disinfection vs toxicity to stem cells, but it is difficult to obtain a clear standard of root canal medication and the optimal clinical concentration.

In this study, success was defined as no symptoms, with reduction or elimination of the periapical lesion. Both necrotic immature and mature permanent teeth had high success rates of 95.6% and 95.5%, respectively, and there was no statistically significant difference between the two values. Based on the primary indicator, we deduced that there is no difference in the REP success rate between necrotic mature and immature permanent teeth, although REPs of necrotic mature permanent teeth are more challenging than those of necrotic immature permanent teeth. It is generally accepted that mature permanent teeth have fewer stem cells than do immature permanent teeth.^{22,44} Driesen et al¹⁶ reported that fully mature roots are associated with complete loss of apical papillary tissue. In addition to SCAPs, periodontal membrane stem cells and pulp stem cells around the apical region may also participate in pulp regeneration.⁴⁴ However, the presence and quantity of SCAPs in mature permanent teeth are unknown, and an abundance of stem cells in the root area does not guarantee the success of REPs.¹³ In the studies included here, bleeding in mature permanent teeth was induced by inserting K-files into the apical area to stimulate stem cell migration. As mentioned above, the migration efficiency of stem cells may be related to the size of the apical foramen. However, the study by El-Kateb et al¹⁷ showed that the success rate in necrotic mature permanent teeth with REPs was not statistically significantly affected by the diameter of the apical foramen. One of the reasons may be that root canal preparation was performed in mature permanent teeth, which may provide more room for blood clots to form. Given these contradictions, more histological evidence is needed to explain the high success rate.

A positive response to the pulp sensitivity test is considered to be the clinical sign of pulp regeneration.³² In spite of the impossibility of evaluating the root development of mature teeth, the pulp sensitivity test could still be applied to mature teeth, for biological repair in REPs makes it possible to achieve a positive response to sensitivity testing. In this systematic analysis, the pulp sensitivity rate (EPT) of necrotic immature permanent teeth was 25.2% and that of necrotic mature permanent teeth was 45.4%; the difference between these values is statistically significant. Pulp sensitivity tests in most of the included studies were temperature tests or electrical tests, which may yield false positive symptoms; these two tests have a high misdiagnosis rate in immature permanent teeth and injured teeth.^{3,33} Studies on pulp activity have suggested that blood circulation rather than the nervous system is a more accurate determinant of pulp activity.¹¹ This statement is also consistent with the post-REPs histological report⁸ that no nerve bundle was detected in the fibrous connective tissue formed in the root canal. This result suggested that REPs in necrotic mature permanent teeth may produce no less blood circulation than it does in necrotic immature permanent teeth, even without the advantage of stem cells.

Crown discolouration is a common complication in regenerative endodontic therapy. Most of the patients treated with

REPs are young people, and most of the teeth involved are anterior teeth. Discolouration of the crown affects the appearance and reduces patient satisfaction. We found that necrotic immature permanent teeth had a high rate of crown discolouration (62.5%), while only one study of necrotic mature permanent teeth mentioned crown discolouration (38.5%). Minocycline and MTA used for root canal disinfection and crown obturation have been found to be associated with crown discolouration.^{30,31} Kim et al³⁰ used TAP with minocycline as a root canal disinfectant during REPs and subsequently observed tooth discolouration. An in-vitro experiment³⁰ verified that of the three antimicrobial agents, only minocycline caused discolouration of the crown. Kohli et al³¹ found that both gray MTA and white MTA caused crown discolouration in an in-vitro study. Bismuth oxide, a component of the MTA, has been suggested as the prime cause of staining –it reacts with the collagen in dentin matrix.³⁶ Although bleaching can be used to reduce discolouration, research on the mechanism of discolouration and the materials causing it is still urgently needed.

Limitations and Strengths

This is the first time the clinical outcomes of the two types of teeth have been compared. The present analysis confirms from a clinical point of view that the stage of root development does not affect the curative effect of REPs. All the included studies were RCTs; case reports, retrospective cohort trials and prospective cohort trials were excluded. This reduced the interference of potential unknowns to some extent. The heterogeneity of the success rate and symptom rate is low, and the heterogeneity of the pulp activity rate is high, which reduces the data reliability of this indicator. We focused on indicator assessment in pooled estimates of the frequency of each outcome and compared these estimates indirectly. Due to the lack of direct comparative studies, indirect comparison results may not accurately reflect the actual situation. The necrotic immature permanent-teeth group included 20 studies, and the necrotic mature permanent-teeth group included 7 studies. The number of necrotic mature permanent teeth is far below that of necrotic immature permanent teeth, making the distribution unbalanced. This imbalance may have led to larger discrepancies between the estimated results and the actual results.

CONCLUSIONS

The clinical effect of REPs on necrotic mature permanent teeth may not be worse than that on necrotic immature permanent teeth, nor are the complications more numerous than those affecting necrotic immature permanent teeth. The stage of root development does not seem to affect the clinical effectiveness of REPs.

Based on the evidence of high bias and indirect comparison, the application of REPs to immature and mature necrotic permanent teeth yields high success rates and low symptomatic rates. Necrotic immature permanent teeth have a considerable crown discolouration rate. The restoration of pulp sensitivity seems to be more pronounced in necrotic mature permanent teeth than in necrotic immature permanent teeth. Further randomised clinical studies are needed to confirm the preliminary results of this review.

ACKNOWLEDGEMENTS

This work was supported by the Chongqing Talent Program: Innovative leading talents (Medical field, CQYC20210303384); Chongqing Medical Scientific Research Project (2018ZDXM020).

REFERENCES

- Abielhassan MM, Sabet NE, El Baz AA. Assessment of the survival and sensibility of mature anterior teeth with periapical lesion after one step regenerative approach using different disinfection maneuvers: A randomized clinical trial. *Indian J Public Health Res Devel* 2021;12(3):416–425.
- Alagl A, Bedi S, Hassan K, AlHumaid J. Use of platelet-rich plasma for regeneration in non-vital immature permanent teeth: Clinical and cone-beam computed tomography evaluation. *J Int Med Res* 2017;45(2):583–593.
- Alghaithy R, Qualtrough A. Pulp sensibility and vitality tests for diagnosing pulpal health in permanent teeth: a critical review. *Int Endod J* 2017;50(2):135–142.
- Altman D, Bland J. Interaction revisited: the difference between two estimates. *BMJ* 2003;326(7382):219.
- Aly MM, Taha SEED, El Sayed MA, Youssef R, Omar HM. Clinical and radiographic evaluation of biodentine and mineral trioxide aggregate in revascularization of non-vital immature permanent anterior teeth (randomized clinical study). *Int J Paediatr Dent* 2019;29(4):464–473.
- Andreasen J, Paulsen H, Yu Z, Bayer T, Schwartz O. A long-term study of 370 autotransplanted premolars. Part II. Tooth survival and pulp healing subsequent to transplantation. *Eur J Orthod* 1990;12(1):14–24.
- Arslan H, Ahmed HMA, Sahin Y, Yildiz ED, Gundogdu EC, Guven Y, Khalilov R. Regenerative endodontic procedures in necrotic mature teeth with periapical radiolucencies: a preliminary randomized clinical study. *J Endod* 2019;45(7):863–872.
- Arslan H, Şahin Y, Topçuoğlu H, Gündoğdu B. Histologic evaluation of regenerated tissues in the pulp spaces of teeth with mature roots at the time of the regenerative endodontic procedures. *J Endod* 2019;45(11):1384–1389.
- Becerra P, Ricucci D, Loghin S, Gibbs J, Lin L. Histologic study of a human immature permanent premolar with chronic apical abscess after revascularization/revitalization. *J Endod* 2014;40(1):133–139.
- Bezgin T, Yilmaz AD, Celik BN, Kolsuz ME, Sonmez H. Efficacy of platelet-rich plasma as a scaffold in regenerative endodontic treatment. *J Endod* 2015;41(1):36–44.
- Bhaskar S, Rappaport H. Dental vitality tests and pulp status. *JADA* (1939) 1973;86(2):409–411.
- Brizuela C, Meza G, Urrejola D, Quezada MA, Concha G, Ramírez V, et al. Cell-based regenerative endodontics for treatment of periapical lesions: a randomized, controlled phase I/II clinical trial. *J Dent Res* 2020;99(5):523–529.
- Chen M, Chen K, Chen C, Tayebaty F, Rosenberg P, Lin L. Responses of immature permanent teeth with infected necrotic pulp tissue and apical periodontitis/abscess to revascularization procedures. *Int Endod J* 2012;45(3):294–305.
- Chrepa V, Henry M, Daniel B, Diogenes A. Delivery of apical mesenchymal stem cells into root canals of mature teeth. *J Dent Res* 2015;94(12):1653–1659.
- Diogenes A, Ruparel NB, Shiloah Y, Hargreaves KM. Regenerative endodontics: A way forward. *J Am Dent Assoc* 2016;147(5):372–380.
- Driesen R, Gervois P, Vanganswinkel T, Lambrichts I. Unraveling the role of the apical papilla during dental root maturation. *Front Cell Dev Biol* 2021;9:665600.
- El-Kateb NM, El-Backly RN, Amin WM, Abdalla AM. Quantitative assessment of intracanal regenerated tissues after regenerative endodontic procedures in mature teeth using magnetic resonance imaging: a randomized controlled clinical trial. *J Endod* 2020;46(5):563–574.
- ElSheshtawy A, Nazzal H, El Shahawy O, El Baz A, Ismail S, Kang J, Ezzat K: The effect of platelet-rich plasma as a scaffold in regeneration/revitalization endodontics of immature permanent teeth assessed using 2-dimensional radiographs and cone beam computed tomography: a randomized controlled trial. *Int Endod J* 2020;53(7):905–921.
- Glynis A, Foschi F, Kefalou I, Koletsi D, Tzanetakis G: Regenerative endodontic procedures for the treatment of necrotic mature teeth with apical periodontitis: a systematic review and meta-analysis of randomized controlled trials. *J Endod* 2021;47(6):873–882.
- He L, Kim S, Gong Q, Zhong J, Wang S, Zhou X, et al. Regenerative endodontics for adult patients. *J Endod* 2017;43:557–564.
- Higgins J, Thompson S, Deeks J, Altman D. Measuring inconsistency in meta-analyses. *BMJ* 2003;327(7414):557–560.

22. Huang G, Sonoyama W, Liu Y, Liu H, Wang S, Shi S. The hidden treasure in apical papilla: the potential role in pulp/dentin regeneration and biroot engineering. *J Endod* 2008;34(6):645–651.
23. Jadhav G, Shah N, Logani A. Revascularization with and without platelet-rich plasma in nonvital, immature, anterior teeth: a pilot clinical study. *J Endod* 2012;38(12):1581–1587.
24. Jayadevan V, Gehlot PM, Manjunath V, Madhupantula SV, Lakshminanth JS. A comparative evaluation of advanced platelet-rich fibrin (A-PRF) and platelet-rich fibrin (PRF) as a scaffold in regenerative endodontic treatment of traumatized immature non-vital permanent anterior teeth: a prospective clinical study. *J Clin Exper Dent* 2021;13(5):e463–e472.
25. Jha P, Virdi MS, Nain S. A regenerative approach for root canal treatment of mature permanent teeth: comparative evaluation with 18 months follow-up. *Int J Clin Pediatr Dent* 2019;12(3):182–188.
26. Jiang X, Liu H, Peng C. Continued root development of immature teeth after regenerative endodontics with or without a collagen membrane: a randomized, controlled clinical trial. *Int J Paediatr Dent* 2022;32(2):284–293.
27. Jiang X, Liu H, Peng C. Clinical and radiographic assessment of the efficacy of a collagen membrane in regenerative endodontics: a randomized, controlled clinical trial. *J Endod* 2017;43(9):1465–1471.
28. Kafourou V, Tong H, Day P, Houghton N, Spencer R, Duggal M. Outcomes and prognostic factors that influence the success of tooth autotransplantation in children and adolescents. *Dent Traumatol* 2017;33(5):393–399.
29. Khademi AA, Dianat O, Mahjour F, Razavi SM, Younessian F. Outcomes of revascularization treatment in immature dog's teeth. *Dent Traumatol* 2014;30(5):374–379.
30. Kim J, Kim Y, Shin S, Park J, Jung I. Tooth discoloration of immature permanent incisor associated with triple antibiotic therapy: a case report. *J Endod* 2010;36(6):1086–1091.
31. Kohli M, Yamaguchi M, Setzer F, Karabucak B. Spectrophotometric analysis of coronal tooth discoloration induced by various bioceramic cements and other endodontic materials. *J Endod* 2015, 41(11):1862–1866.
32. Law A. Considerations for regeneration procedures. *J Endod* 2013, 39:S44–56.
33. Lima T, Dos Santos S, da Silva Fidalgo T, Silva E. Vitality tests for pulp diagnosis of traumatized teeth: a systematic review. *J Endod* 2019;45(5):490–499.
34. Lin J, Zeng Q, Wei X, Zhao W, Cui M, Gu J, et al. Regenerative endodontics versus apexification in immature permanent teeth with apical periodontitis: a prospective randomized controlled study. *J Endod* 2017;43(11):1821–1827.
35. Lovelace T, Henry M, Hargreaves K, Diogenes A. Evaluation of the delivery of mesenchymal stem cells into the root canal space of necrotic immature teeth after clinical regenerative endodontic procedure. *J Endod* 2011;37(2):133–138.
36. Marciano M, Costa R, Camilleri J, Mondelli R, Guimarães B, Duarte M. Assessment of color stability of white mineral trioxide aggregate angelus and bis-muth oxide in contact with tooth structure. *J Endod* 2014;40(8):1235–1240.
37. McGuinness L, Higgins J. Risk-of-bias Visualization (robvis): An R package and Shiny web app for visualizing risk-of-bias assessments. *Res Synth Methods* 2021;12(1):55–61.
38. Mittal N, Baranwal HC, Kumar P, Gupta S. Assessment of pulp sensibility in the mature necrotic teeth using regenerative endodontic therapy with various scaffolds - Randomised clinical trial. *Indian J Dent Res* 2021;32(2):216–220.
39. Murray PE, Garcia-Godoy F, Hargreaves KM. Regenerative endodontics: a review of current status and a call for action. *J Endod* 2007;33(4):377–390.
40. Nagata JY, Gomes BP, Rocha Lima TF, Murakami LS, de Faria DE, Campos GR, et al. Traumatized immature teeth treated with 2 protocols of pulp revascularization. *J Endod* 2014;40(5):606–612.
41. Nagy MM, Tawfik HE, Hashem AA, Abu-Seida AM. Regenerative potential of immature permanent teeth with necrotic pulps after different regenerative protocols. *J Endod* 2014;40(2):192–198.
42. Narang I, Mittal N, Mishra N. A comparative evaluation of the blood clot, platelet-rich plasma, and platelet-rich fibrin in regeneration of necrotic immature permanent teeth: A clinical study. *Contemp Clin Dent* 2015;6(1):63–68.
43. Ong T, Lim G, Singh M, Fial A. Quantitative assessment of root development after regenerative endodontic therapy: a systematic review and meta-analysis. *J Endod* 2020;46(12):1856–1866.e1852.
44. Paryani K, Kim S. Regenerative endodontic treatment of permanent teeth after completion of root development: a report of 2 cases. *J Endod* 2013;39(7):929–934.
45. Ragab R, Lattif A, Dokky N. Comparative study between revitalization of necrotic immature permanent anterior teeth with and without platelet rich fibrin: a randomized controlled trial. *J Clin Pediatr Dent* 2019;43(2):78–85.
46. Rizk H, Salah Al-Deen M, Emam A. Comparative evaluation of platelet rich plasma (PRP) versus platelet rich fibrin (PRF) scaffolds in regenerative endodontic treatment of immature necrotic permanent maxillary central incisors: A double blinded randomized controlled trial. *Saudi Dent J* 2020;32(5):224–231.
47. Rizk HM, Al-Deen MSS, Emam AA. Regenerative endodontic treatment of bilateral necrotic immature permanent maxillary central incisors with platelet-rich plasma versus blood clot: a split mouth double-blinded randomized controlled trial. *Int J Clin Pediatr Dent* 2019;12(4):332–339.
48. Rizk HM, Salah Al-Deen MS, Emam AA. Pulp revascularization/revitalization of bilateral upper necrotic immature permanent central incisors with blood clot vs platelet-rich fibrin scaffolds – a split-mouth double-blind randomized controlled trial. *Int J Clin Pediatr Dent* 2020;13(4):337–343.
49. Santhakumar M, Yayathi S, Retnakumari N. A clinicroadiographic comparison of the effects of platelet-rich fibrin gel and platelet-rich fibrin membrane as scaffolds in the apexification treatment of young permanent teeth. *J Indian Soc Pedodon Prevent Dent* 2018;36(1):65–70.
50. Saoud T, Sigurdsson A, Rosenberg P, Lin L, Ricucci D. Treatment of a large cystlike inflammatory periapical lesion associated with mature necrotic teeth using regenerative endodontic therapy. *J Endod* 2014;40(12):2081–2086.
51. Scelza P, Gonçalves F, Caldas I, Nunes F, Lourenço E, Tavares S, et al. Prognosis of regenerative endodontic procedures in mature teeth: a systematic review and meta-analysis of clinical and radiographic parameters. *Materials (Basel)* 2021;14(16).
52. Schmalz G, Widbiller M, Galler K. Clinical Perspectives of pulp regeneration. *J Endod* 2020;46:S161–S174.
53. Sharma S, Mittal N. A comparative evaluation of natural and artificial scaffolds in regenerative endodontics: A clinical study. *Saudi Endod J* 2016;6(1):9–15.
54. Shivashankar VY, Johns DA, Maroli RK, Sekar M, Chandrasekaran R, Karthikeyan S, et al. Comparison of the effect of PRP, PRF and induced bleeding in the revascularization of teeth with necrotic pulp and open apex: a triple blind randomized clinical trial. *J Clin Diagn Res* 2017;11(6):zc34–zc39.
55. Singh Ospina N, Rodriguez-Gutierrez R, Maraka S, Espinosa de Ycaza A, Jasim S, Castaneda-Guarderas A, et al. Outcomes of parathyroidectomy in patients with primary hyperparathyroidism: a systematic review and meta-analysis. *World J Surg* 2016;40(10):2359–2377.
56. Sterne J, Savović J, Page M, Elbers R, Blencowe N, Boutron I, et al. RoB 2: a revised tool for assessing risk of bias in randomised trials. *BMJ* 2019;366:l4898.
57. Torabinejad M, Milan M, Shabahang S, Wright KR, Faras H. Histologic examination of teeth with necrotic pulps and periapical lesions treated with 2 scaffolds: an animal investigation. *J Endod* 2015;41(6):846–852.
58. Ulusoy AT, Turedi I, Cimen M, Cehreli ZC. Evaluation of blood clot, platelet-rich plasma, platelet-rich fibrin, and platelet pellet as scaffolds in regenerative endodontic treatment: a prospective randomized trial. *J Endod* 2019;45(5):560–566.
59. Youssef A, Ali M, ElBolok A, Hassan R. Regenerative endodontic procedures for the treatment of necrotic mature teeth: a preliminary randomised clinical trial. *Int Endod J* 2022;55(4):334–346.