

# Platelet-Rich Fibrin with Bone Grafts for Regeneration of Bony Defect following Extraction of Supernumerary Teeth: A Case Report

Balamananikandasrinivasan CHANDRASEKARAN<sup>1</sup>, Nanditha SURESH<sup>2</sup>, Senthilkumar MUTHUSAMY<sup>2</sup>

*Supernumerary teeth are hyperdontic variants due to abnormalities during tooth development. Here, we report a case on regeneration of bony defect, which ensued following extraction of two supernumerary teeth in the mandibular premolar region, using a combination of bone grafts and platelet-rich fibrin. To the best of our knowledge, it is the first time synergistic use of biomaterials with bone grafts have been used for this type of management.*

**Key words:** bone graft, platelet-rich fibrin, supernumerary teeth  
*Chin J Dent Res 2017;20(4):231–234; doi: 10.3290/j.cjdr.a39223*

The development of teeth is a multi-staged event that happens in a cascaded manner. Any disruption in these intricate mechanisms results in abnormalities in terms of tooth number, structure and shape. These abnormalities may exemplify as hypodontia and hyperdontia, amelogenesis and dentinogenesis imperfecta, ectodermal dysplasia, taurodontism, fusion, gemination, and dilaceration etc. Supernumerary teeth are hyperdontic variants that exhibit diverse nature in terms of prevalence among races and location in human jaws. Their incidence among primary and permanent dentition ranges between 0.3% and 0.6% and 0.15% and 1% respectively<sup>1</sup>. Maxillary anterior region, followed by

the mandibular premolar region, were the two most common sites reported for occurrence of supernumerary teeth<sup>2</sup>. Although supernumerary teeth are usually associated with the syndromic, their occurrence has also been reported in normal individuals. In a study by Yusof et al in non-syndromic patients, multiple supernumerary teeth were found to be 60.9% in mandible and 44.8% within the mandible and occurred predominantly in the premolar region<sup>3,4</sup>. Herewith, we present a case report of partly erupted supernumerary teeth in regions 35 and 36 with its surgical management and regeneration of residual bony defect.

## Case report

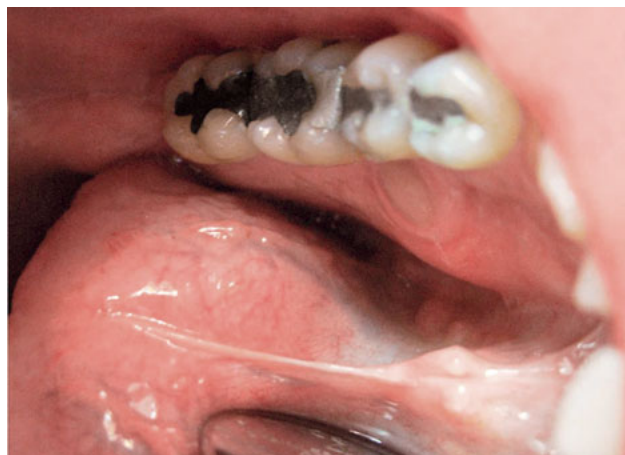A 41-year-old male patient reported to AIMST Dental Centre, Kedah, Malaysia, with dull, intermittent, localised pain in relation to the left lower premolar region. Intraoral examination revealed restored teeth 35, 36 and an exposed tooth cusp on the lingual aspect between teeth 35 and 36 (Fig 1). The presence of two supernumerary teeth was confirmed through occlusal and periapical radiographs (Fig 2). Radiographically, one of the supernumeraries resembled a premolar and the other appeared rudimentary with only a crown present. As the patient had intermittent pain in that region and since there were

1 Academic Unit of Craniofacial Clinical Care, Faculty of Dentistry, AIMST University, Kedah, Malaysia.

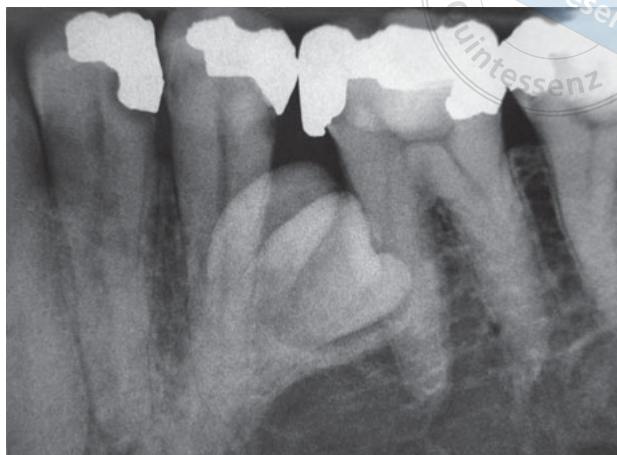
2 Academic Unit of Primary and Preventive dentistry, Faculty of Dentistry, AIMST University, Kedah, Malaysia.

All the authors were working with the Faculty of Dentistry, AIMST University, Malaysia when the case was done. Presently all the authors have moved to different positions and are no longer working in AIMST University.

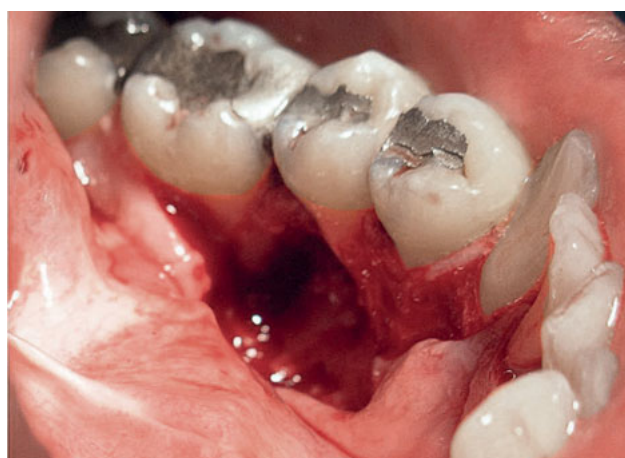**Corresponding author:** Dr Balamananikandasrinivasan CHANDRASEKARAN, Sri Meenakse Nursing Home, 45, Dharmapuri Main Road, Omalur, Salem Dt, Tamilnadu 636455, India. Tel: 91 9443593815. Email: drbalamanikanda@gmail.com.



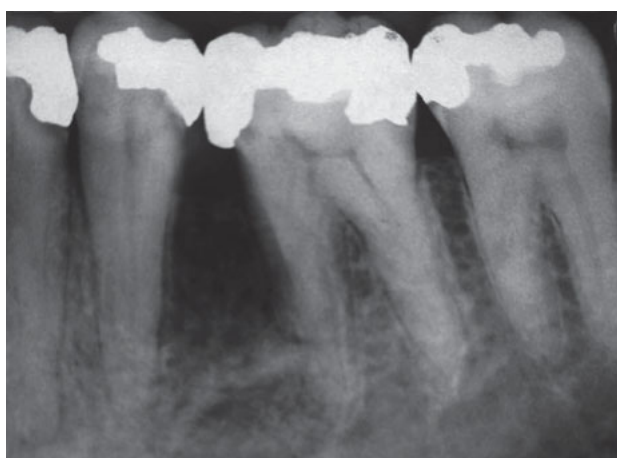**Fig 1** Preoperative clinical photograph showing exposed cusp of supernumerary teeth between teeth 35 and 36.



**Fig 2** Preoperative periapical radiograph showing supernumerary teeth.



**Fig 3** Bony defect after removal of supernumerary teeth.



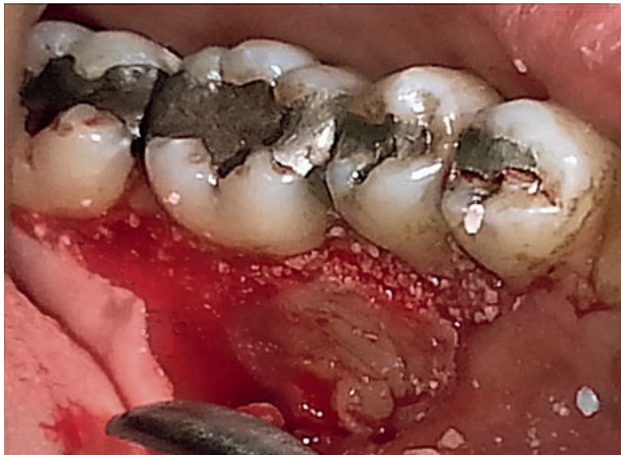**Fig 4** Periapical radiograph showing bone defect between teeth 35 and 36.

no pathological changes associated with teeth 35 and 36, surgical removal of supernumerary teeth was planned. Under local anaesthesia (LA), a mucoperiosteal flap was raised lingually and teeth were surgically removed, leaving behind a large bony defect. Bony dehiscence was observed in relation to the lingual aspect of tooth 35 and the mesio lingual aspect of tooth 36 (Figs 3 and 4). A combination of bone grafts (autograft, allograft (Puros, Zimmer Dental, CA, USA), xenograft (Osteobiol-Gen Os, Tecness Dental, Torino, Italy) and platelet-rich fibrin (PRF) was planned to augment the bony defect. Autograft was harvested from tori present below the bony defect site. The patient had 5 ml of his blood taken through an IV cannula and centrifuged at 2700 rpm for 13 min to obtain PRF. Bone grafts were placed into the defect and

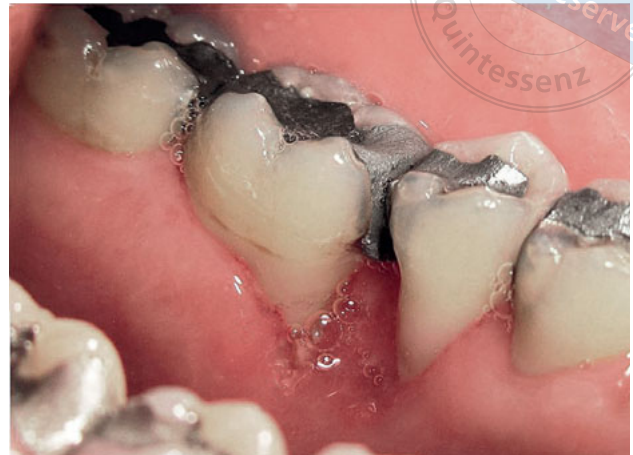covered with a PRF membrane (Fig 5). The flap was approximated with 3-0 black silk sutures and the surgical site was covered with a periodontal dressing (Coe-pac). Review was done periodically at the end of 1 week (Fig 6), 4 weeks, 3 months, 6 months and 12 months. Satisfactory bone formation was observed after 1 year in the grafted site, with ensued Class III gingival recession in relation to teeth 35 and 36 (Figs 7 and 8).

**Discussion**

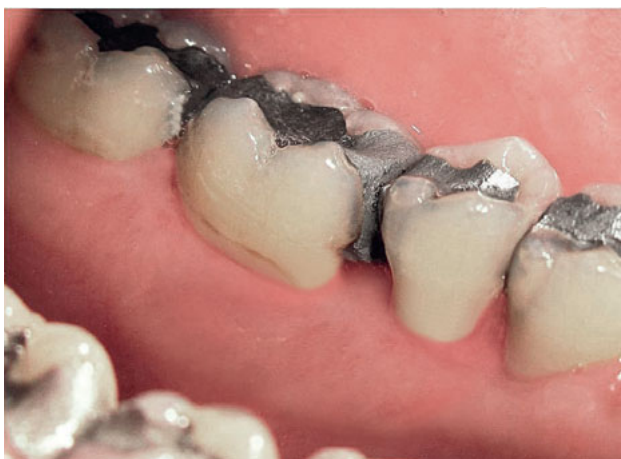An addition to the normal series of dentition is referred to as a “supernumerary tooth”. Several theories exist relating to the causes of supernumeraries, such as Atavism theory, Dichotomy theory and Dental lamina



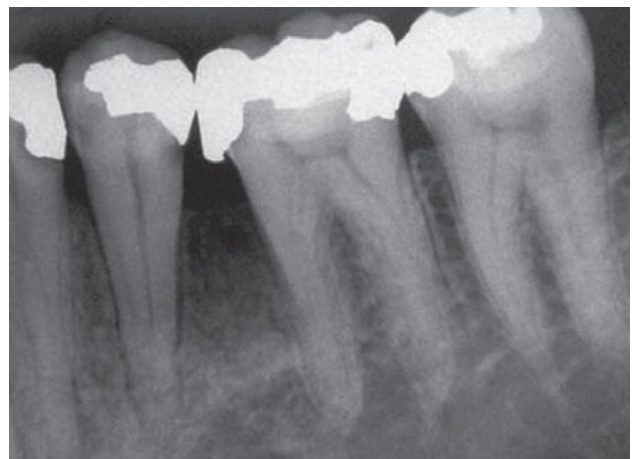**Fig 5** Clinical photograph showing filled bone defect with a combination of bone grafts and platelet-rich fibrin.



**Fig 6** 1-week postoperative photograph following suture removal.



**Fig 7** Postoperative photograph after 1 year.



**Fig 8** 1-year postoperative radiograph showing adequate bone fill between teeth 35 and 36.


hyperactivity theory. Among them, the dental lamina hyperactivity theory is the most accepted. This states that an additional tooth bud may be induced to develop from remnants of excessive dental lamina or palatal extensions of the active dental lamina, resulting in a supernumerary tooth<sup>5</sup>.

Supernumerary teeth have been classified based on number as single/multiple and according to morphology as conical, tuberculate, supplemental and odontome<sup>6</sup>. Eruption patterns of these teeth also vary depending on their orientation. Those with a normal orientation erupt while others remain impacted or assume an abnormal path of eruption<sup>7</sup>.

Controversies still persist on the definitive management of supernumerary teeth and the decision relies on

factors such as age, stage of development of supernumerary teeth, absence of adjacent teeth and the presence/absence of complications. Subsistence of supernumerary teeth in jaws can cause complications such as prevention or delay of eruption of associated permanent teeth, displacement, rotation of permanent teeth, crowding, malocclusion, cyst formation, problems related to oral hygiene and aesthetics, pain/pressure and root resorption on adjacent teeth<sup>8</sup>. Under-erupted teeth associated with complications should be preferentially extracted. In our case inadvertent pressure to adjacent teeth from the impacted supernumeraries resulted in pain, which made extraction mandatory.

The bone defect that ensued after removal was significantly large, making unaided natural bone fill



difficult. This led us to use a combination of bone grafts with PRF. Although autografts are considered to be the gold standard, harvesting a large quantity of them necessitates additional surgical site. Hence, in order to overcome this difficulty, we used a combination of autograft with cortico cancellous bone in the form of allograft and xenograft. This coalescence ensured not only sufficient bone fill, but also provided osteogenic, osteoinductive and osteoconductive effects to the surgical site. Scientific evidence supports the fact that PRF added to graft materials acts as a biological connector between different elements of the graft and acts as a matrix that enhances neoangiogenesis, capture of stem cells and migration of osteoprogenitor cells to the centre of the graft<sup>9</sup>. Besides that, it also provides growth factors such as transforming growth factor- $\beta$  (TGF- $\beta$ ), platelet-derived growth factor (PDGF), vascular endothelial growth factor (VEGF), insulin like growth factor-1 (IGF-1), fibroblast growth factor (FGF) and epidermal growth factor (EGF), which stimulates mitogenic response in the periosteum for bone repair<sup>10</sup>.

Although gingival recession was seen on the grafted site that had accentuated over the 1-year period post operatively, bone was present until two-thirds of the roots radiographically, suggesting adequate bone fill. Since the defect size was large and the graft materials used were in particulate form, containment of the graft over the bone dehiscence in relation to lingual aspects of teeth 35 and 36 were difficult. This might have resulted in gingival recession in those areas. Besides that, the patient's inadequate plaque control, despite being regularly monitored and educated, might have further accentuated this problem.

Although extraction of multiple supernumerary teeth within the same region is commonly carried out, handling its sequelae is not often reported in literature. We have presented a case report on the regeneration of post-extraction bone defect following the removal of supernumerary teeth with bone grafts and platelet-rich fibrin. Albeit the gingival recession, this unique combination

accelerated the healing process and ensured adequate bone fill. Hence, the authors feel that this approach can be used as a viable option for management of such situations.

### Conflicts of interest

The authors reported no conflicts of interest related to this study.

### Author contribution

Dr Balamanikandasrinivasan CHANDRASEKARAN designed, drafted and revised the manuscript; Dr Nanditha SURESH designed and drafted the manuscript; Dr Senthilkumar MUTHUSAMY collected data for the case.

(Received Apr 09, 2017; accepted Sep 19, 2017)

### References

1. Primosch RE. Anterior supernumerary teeth—assessment and surgical intervention in children. *Pediatr Dent* 1981;3:204–215.
2. Rajab LD, Hamdan MA. Supernumerary teeth: review of the literature and a survey of 152 cases. *Int J Paediatr Dent* 2002;12:244–254.
3. Yusof WZ. Non-syndrome multiple supernumerary teeth: literature review. *J Can Dent Assoc* 1990;56:147–149.
4. Scheiner MA, Sampson WJ. Supernumerary teeth: a review of the literature and four case reports. *Aust Dent J* 1997;42:160–165.
5. Russell KA, Folwarczna MA. Mesiodens – diagnosis and management of a common supernumerary tooth. *J Can Dent Assoc* 2003;69:362–366.
6. Arathi R, Ashwini R. Supernumerary teeth: a case report. *J Indian Soc Pedod Prev Dent* 2005;23:103–105.
7. Nazif MM, Ruffalo RC, Zullo T. Impacted supernumerary teeth: a survey of 50 cases. *J Am Dent Assoc* 1983;106:201–204.
8. Shah A, Gill DS, Tredwin C, Naini FB. Diagnosis and management of supernumerary teeth. *Dent Update* 2008;35:510–512, 514–516, 519–520.
9. Saluja H, Dehane V, Mahindra U. Platelet-Rich fibrin: A second generation platelet concentrate and a new friend of oral and maxillofacial surgeons. *Ann Maxillofac Surg* 2011;1:53–57.
10. Panda S, Ramamoorthi S, Jayakumar ND, Sankari M, Varghese SS. Platelet rich fibrin and alloplast in the treatment of intrabony defect. *J Pharm Bioallied Sci* 2014;6:127–131.