

Int Poster J Dent Oral Med 2008, Vol 10 No 02, Poster 402

## Oro-facial Implant Axis in the Anterior Maxilla: a Pilot Study

**Language:** English

**Authors:**

Dr. Hidekazu Hayashi, DDS, PhD,  
University of Florida, Center for Implant Dentistry, Gainesville, Fl., USA and Center of Implant Dentistry, Japan, Family Dental Clinic  
Implant Center 2 Saki-cho, Nara 630-8003, Japan,  
Dr. Arne F. Boeckler, University of Florida, Center for Implant Dentistry, USA and Martin-Luther-University Halle-Wittenberg,  
Department for Prosthodontics, Halle(Saale), Germany  
Dr. Roy Rosado, DMD, MS, Dr. William C. Martin, DMD, MS, Dr. James D. Ruskin MD, DMD, MS, Dr. Dean Morton, BDS, MS,  
University of Florida, Center for Implant Dentistry, USA  
Dr. Yasushi Nakajima, DDS, PhD,  
Center of Implant Dentistry, Japan

**Date/Event/Venue:**

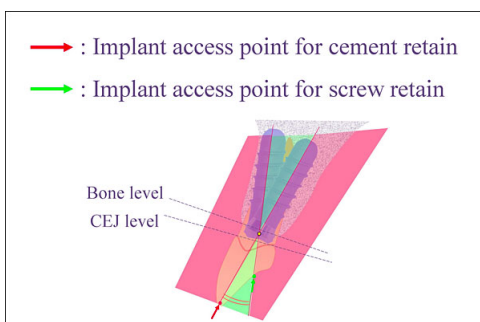
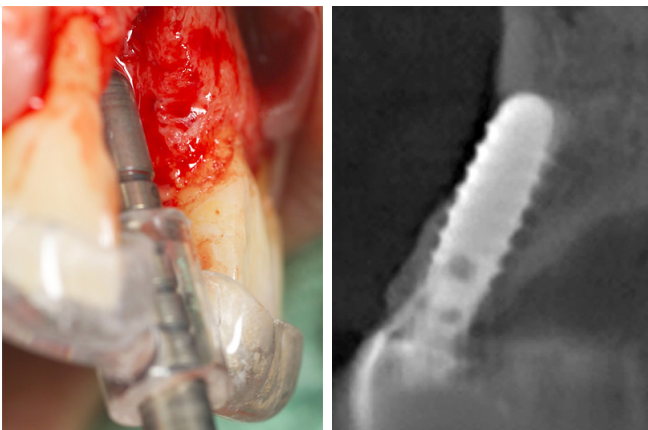
26.-28. April 2007  
ITI World Symposium  
New York City, USA

### Introduction

Screw retention is recommended for implant supported and retained prostheses in the anterior maxilla. This is because machined components have improved fit characteristics and excess cement removal is difficult when restorative margins are located greater than 2mm subgingivally.

Recently, in order to increase predictability of an aesthetic result, restorative options have increased. The use of screw-retained customized abutments in conjunction with cement retained crowns is one of these options. This procedure is associated with several advantages. Machined components can be utilized deep in the gingival sulcus and the cement line is moved coronally where it is readily accessible. The use of customized abutments also increases the degree of flexibility for the oro-facial implant axis, as restorative inclination can be modified in the abutment.

It is common for the oro-facial implant axis to change between screw and cement retention. In other words, the oro-facial implant axis needs to be set up toward the palatal side of the incisal edge for a screw retained implant prosthesis. On the other hand, the oro-facial implant axis of cement retained implant prostheses requires an implant axis that passes through the incisal edge. This gives a more ideal emergence profile and improves cement line location. The difference between these axes influences traditional contour (particularly emergence) of the prosthesis. Therefore, it is possible that differences in the oro-facial implant axis (and the use of this inclination as a measurable parameter) may help in obtaining and predicting aesthetic treatment results.

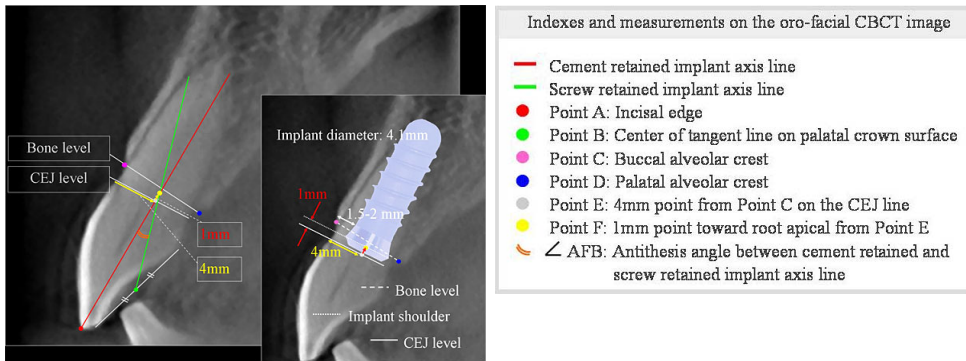


Oro-facial comfort & danger zones in implant axis

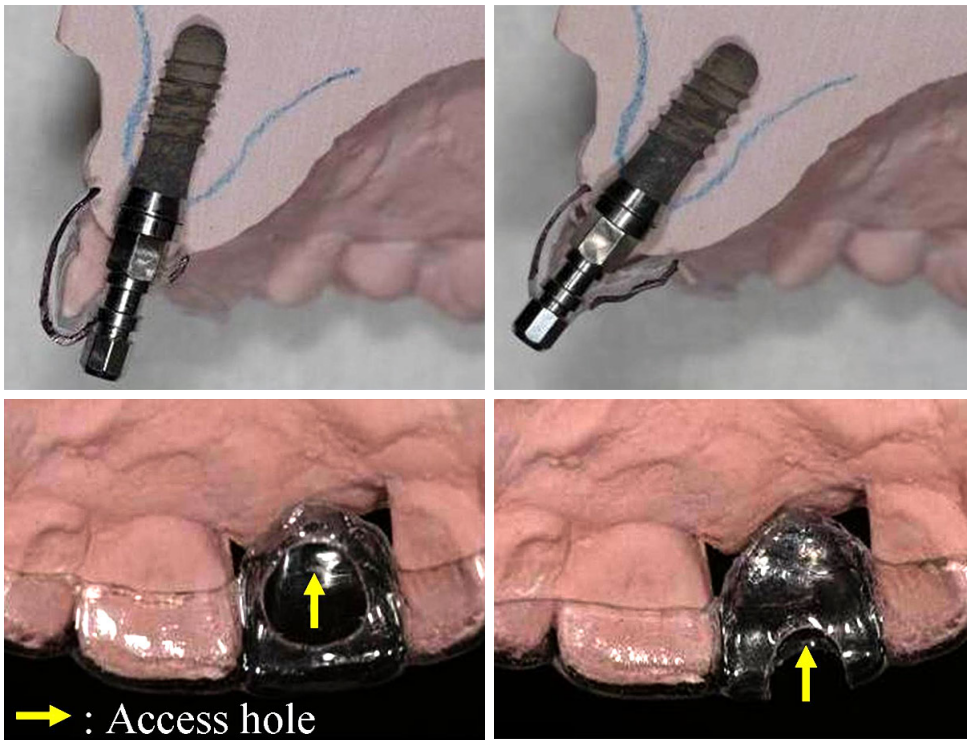
## Objectives

For this pilot study, oro-facial axis was measured using Cone-Beam CT (CBCT) images of normal teeth to consider the angle between planned implant axis for screw and cement retention.

## Material and Methods



- Indexes and measurements on the oro-facial CBCT image
- Cement retained implant axis line
  - Screw retained implant axis line
  - Point A: Incisal edge
  - Point B: Center of tangent line on palatal crown surface
  - Point C: Buccal alveolar crest
  - Point D: Palatal alveolar crest
  - Point E: 4mm point from Point C on the CEJ line
  - Point F: 1mm point toward root apical from Point E
  - ∠ AFB: Antithesis angle between cement retained and screw retained implant axis line



Screw retained

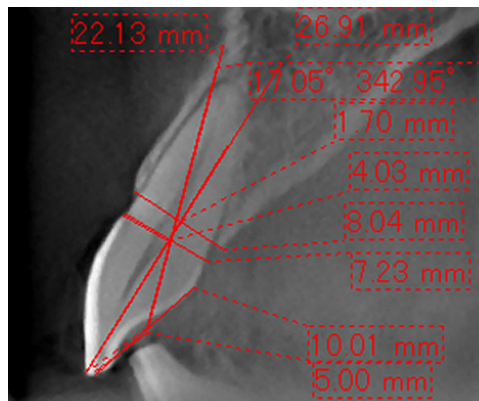
Cement retained

10 CBCT (3DX: J.Morita Co. Japan) images of normal central incisor area without periodontal disease or prosthesis as the minimum requirements of bone volume were selected. Center point of 4.1mm diameter implant was established 4mm point toward palatally from facial CEJ point to leave facial bone wall 1-2mm. (Point E) And implant shoulder depth was established 1mm point toward apically from CEJ line. (Point F) The red line (Point A-F) was established as the cement retained implant axis and the green line (Point B-F) as the screw retained implant axis. Angle AFB, Point C to D and oro-facial distance of CEJ were measured using the software bundled CBCT.

## Results

### Measured results on maxillary central incisal area [mm]

Average age of 10 sample images was 33 years old. (25 - 41 years old).  
 Subject images were 4 males and 6 females.  
 In 10 CBCT images, Average of angle AFB was 17.687°. (15.39°- 19.96°)  
 Distance of CEJ was 6.886mm, Distance of Point C to D was 7.842mm.

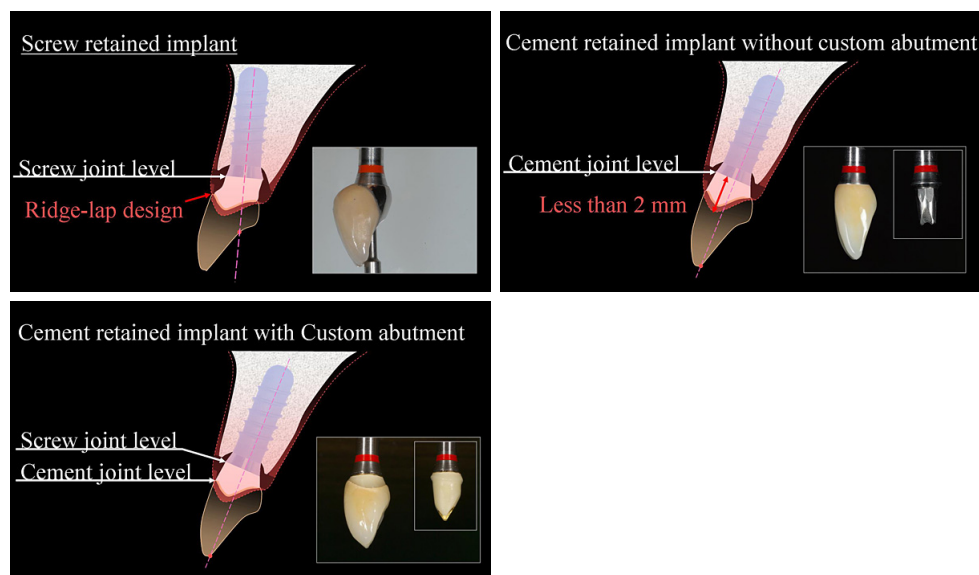


One of the measured CBCT images (Case#2)

case #	CEJ [mm]	CD [mm]	AFB [°]
1	7.09	7.52	18.16
2	7.23	8.04	17.05
3	6.18	6.73	15.39
4	6.38	8.17	17.54
5	7.22	8.11	18.73
6	6.96	8.59	19.96
7	7.1	8.22	17.03
8	6.63	7.59	15.87
9	7.06	7.74	19.69
10	7.01	7.71	17.45
<b>avg.</b>	<b>6.886</b>	<b>7.842</b>	<b>17.687</b>

## Conclusions

Proceedings of the third ITI Consensus Conference<sup>1)</sup> identified the optimal three-dimensional implant position. Accordingly, when the implant axis for screw retention inclines unfavorably in comparison to the implant axis for cement retention, the prosthesis tends to become a ridge-lap design with aesthetic compromise. The tolerance level of this angle made between implant axes planned for screw and cement retention is one of the important factors for ensuring a satisfactory emergence profile and optimal aesthetic result. Oro-facial implant axis are 15 to 20 degrees different on Screw retain and Cement retain from the point of view of incisal anatomy on maxilla. Implant axis for acquisition of ideal emergence profile is concerned so much with the emergence profile involved and the natural teeth axis. The superstructure of cement retain with custom abutment tend to be an ideal emergence profile. It seems that understanding of the oro-facial implant axis is helpful in the phase of diagnostic cast or implant placement.



The angle between screw and cement retained implant axis is 15 to 20 degrees. It seems that this angle can be set to one of the reference values in order to predict aesthetic treatment results.

## Literature

Daniel Buser, William C Martin, Urs C. Belser. Proceedings of the third ITI consensus conference. Int J Maxillofac Implants 2004; 19(Suppl): 43-61

*This Poster was submitted by Dr. Arne F. Boeckler.*

## Correspondence address:

Dr. Hidekazu Hayashi  
University of Florida  
Center for Implant Dentistry  
Gainesville, Fl.  
USA

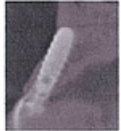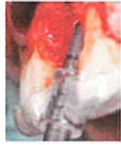Center of Implant Dentistry, Japan  
Family Dental Clinic Implant Center 2 Saki-cho  
Nara 630-8003  
Japan  
+81-742-35-8020

# Oro-facial Implant Axis in Anterior Maxilla: A pilot study

○ Halekazi Hayashi<sup>1,2</sup>, Arne Boeckler<sup>1</sup>, Roy Rosado<sup>1</sup>, William C Martin<sup>1</sup>, James D Ruckin<sup>1</sup>, Yasuhiko Nakajima<sup>2</sup>, Dean Morton<sup>1</sup>

<sup>1</sup> University of Florida Center for Implant Dentistry (CID)  
<sup>2</sup> Center of Implant Dentistry Japan (CID)

## Overview

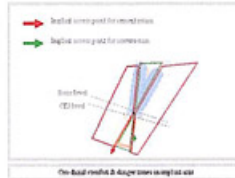


Screw retention is recommended for implant supported and retained prosthesis in the anterior maxilla. This is because machined components have improved fit characteristics and excess cement removal is difficult when restorative margins are located greater than 2mm subgingivally.

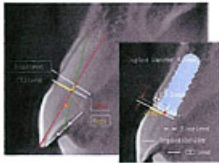
Recently, in order to increase predictability of an aesthetic result, restorative options have increased. The use of screw-retained customized abutments in conjunction with cement retained crowns is one of these options. This procedure is associated with several advantages. Machined components can be utilized deep in the gingival sulcus and the cement line is moved coronally where it is readily accessible. The use of customized abutments also increases the degree of flexibility for the oro-facial implant axis, as restorative inclination can be modified in the abutment.

It is common for the oro-facial implant axis to change between screw and cement retention. In other words, the oro-facial implant axis needs to be set up toward the palatal side of the incisal edge for a screw retained implant prosthesis. On the other hand, the oro-facial implant axis of cement retained implant prosthesis requires an implant axis that passes through the incisal edge. This gives a more ideal emergence profile and improves cement line location. The difference between these axes influences traditional contour (particularly emergence) of the prosthesis. Therefore, it is possible that differences in the oro-facial implant axis (and the use of flap inclination as a measurable parameter) may help in obtaining and predicting aesthetic treatment results.

For this pilot study, oro-facial axis was measured using Cone-Beam CT (CBCT) images of normal teeth to consider the angle between planned implant axis for screw and cement retention.

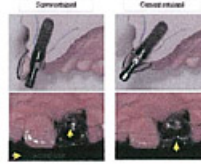


## Materials and Method



Indices and measurements on the oro-facial CBCT image

- Cement retained implant axis line
- Screw retained implant axis line
- Point A: Incisal edge
- Point B: Center of tangential line on palatal crown surface
- Point C: Buccal alveolar crest
- Point D: Palatal alveolar crest
- Point E: 4mm point from Point C on the CEJ line
- Point F: 1mm point toward root apical from Point E
- ∠ AFB: Angle between cement retained and screw retained implant axis line



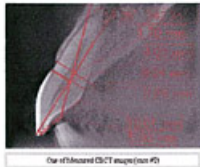10 CBCT (3D; J-Morita Co. Japan) images of normal central incisor area without periodontal disease or prosthesis as the minimum requirements of bone volume were selected.

Center point of 4 mm diameter implant was established 4mm point toward palatally from facial CEJ point to leave facial bone wall 1-2mm. (Point E) And implant shoulder depth was established 1mm point toward apically from CEJ line. (Point F)

The red line (Point A-F) was established to the cement retained implant axis and the green line (Point B-F) as the screw retained implant axis.

Angle AFB, Point C to D and oro-facial distance of CEJ were measured using the software bundled CBCT.

## Results



Case #	CEJ	Cto D	AFB
1	139	122	18.18
2	123	88	17.06
3	816	673	18.28
4	428	417	17.28
5	112	811	18.13
6	602	323	18.28
7	11	622	17.60
8	482	159	18.07
9	106	726	18.20
10	104	711	17.45
avg.	605	192	17.87

Measurements on maxillary central incisors (Max. mid)

Average age of 10 sample images was 33 years old. (25 - 41 years old)  
 Subject images were 4 males and 6 females.  
 In 10 CBCT images, Average of angle AFB was 17.687°.  
 (15.39° - 19.50°)  
 Distance of CEJ was 6.886mm. Distance of Point C to D was 7.842mm.

## Discussion

Proceedings of the third ITI Consensus Conference<sup>1)</sup> identified the optimal three-dimensional implant position. Accordingly, when the implant axis for screw retention inclines unfavorably in comparison to the implant axis for cement retention, the prosthesis tends to become a ridge-top design with aesthetic compromise. The tolerance level of this angle made between implant axes planned for screw and cement retention is one of the important factors for ensuring a satisfactory emergence profile and optimal aesthetic result.

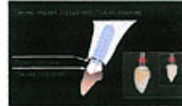
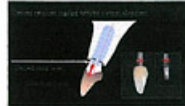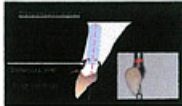
Oro-facial implant axis are 15 to 20 degrees different on Screw retain and Cement retain from the point of view of incisal anatomy on maxilla.

Implant axis for acquisition of ideal emergence profile is concerned so much with the emergence profile involved and the natural teeth axis.

The superstructure of cement retain with custom abutment tend to be an ideal emergence profile.

It seems that understanding of the oro-facial implant axis is helpful in the phase of diagnostic cast or implant placement.

1) Daniel Buser, William C Martin, Uwe C Belser. Proceedings of the third ITI consensus conference. *Int J Maxillofac Implants* 2004; 19(Suppl): 43-61



## Conclusion

The angle between screw and cement retained implant axis is 15 to 20 degrees.

It seems that this angle can be set to one of the reference values in order to predict aesthetic treatment results.