



Diagnosis and treatment of external invasive root resorption – EIRR.

Diogo P.*; Sequeira D.; Palma P.; Santos JM.
Faculty of Medicine, University of Coimbra, Portugal



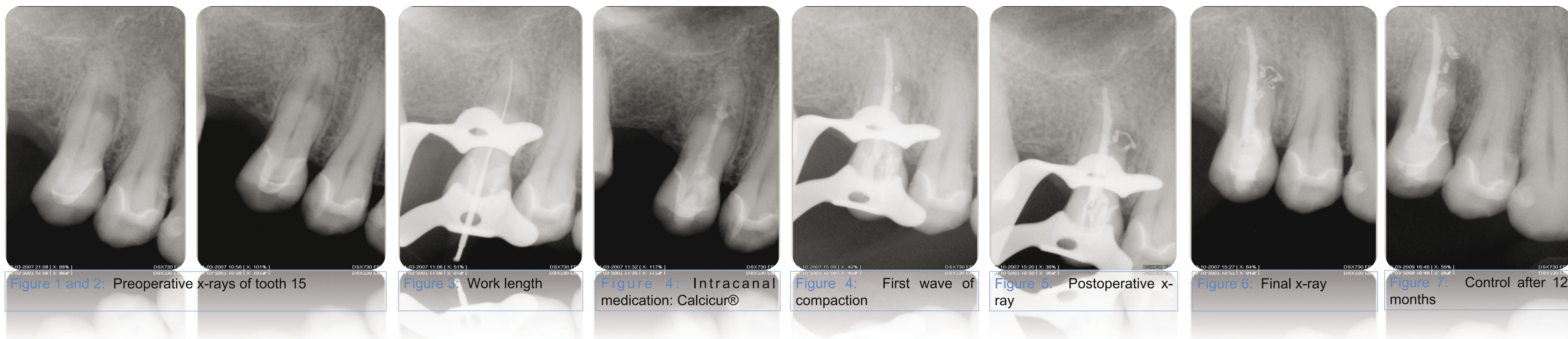
AIM

External invasive root resorption (EIRR) is an insidious and often aggressively destructive form of external root resorption, that occurs when the protective pre-cementum layer is mechanically damaged or removed which allows for the denuded areas of the root surface to be colonized by clastic cells and for the resorption to get progressively worse, which usually affects a single tooth. This type of resorption develops slowly and initially without symptoms and may occur as a late complication following dental trauma particularly where it involves damage to cementum and supporting tissues. While this resorption may be evident clinically as a pink coronal discoloration, later with enamel's cavitation, often there are no obvious external signs and the condition is occasional detected radiographically. It's characterized by the invasion of the cervical region of the root by fibrovascular tissue, which progressively resorbs dentine, enamel and cementum. The dental pulp remains protected by an intact layer of dentine and predentine until late in the process. Ectopic calcifications can be observed in advanced lesions both within the invading fibrous tissue and deposited directly onto the resorbed dentine surface. The aetiology of external invasive root resorption is unknown but trauma has been documented as a potential predisposing factor (mostly concussion), however orthodontic treatment, orthognathic and dentoalveolar surgery, periodontal therapy and tooth whitening procedure can also induce external invasive root resorption. As early diagnosis is difficult, the dentist should be aware of this pathology and severity of clinical signs that may suggest it's presence, to be self sufficient and capable of diagnosing the aforementioned dental pathology.

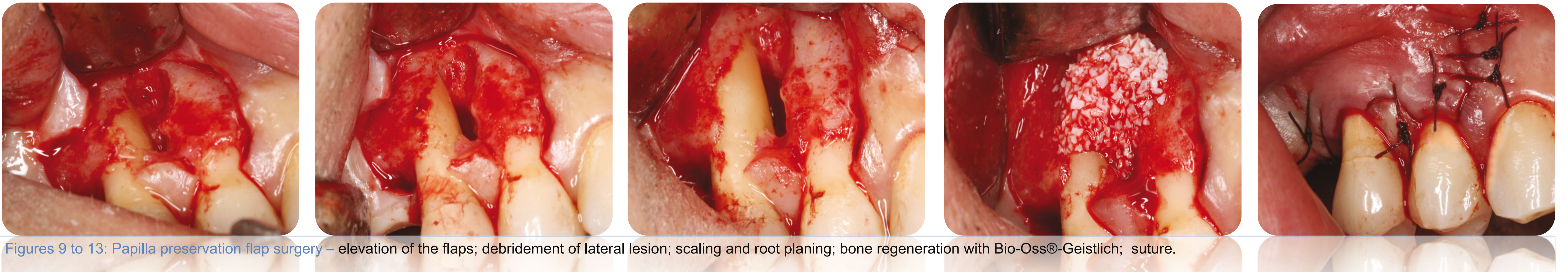
SUMMARY

Male patient, 45 years, emerged at Dental Clinic of Faculty of Medicine, University of Coimbra, Portugal, with symptoms to percussion in tooth 15, right second premolar, restored with ceramic onlay held for nearly five years without leakage, no hemorrhage on probing or periodontal pocket and by conducting periapical ortorradial observed endodontic treatment accompanied by a radiolucent area in the demarcated middle third root structure by a thin radio-opaque line that matches the outlines of the canal area overlapping the irregular external invasive root resorption which may be associated with a slight irregularity in the adjacent bone-crest. On the first moment, endodontic treatment was performed; intracanal medication was calcium hydroxide (CalciCur®–Voco) and thermoplastic obturation (SystemB®–Analytic Technology) was made aided with gutta-percha and endodontic sealer based on epoxy resin (AHPlus®–Dentsply). After 18 months, the patient appeared again with new pain symptoms, accompanied by edema and erythema of the buccal and palatal region of tooth 15. Endodontic surgery was performed with curettage of the lesion and lateral periodontal bone regeneration was made with natural bone substitute material (Bio-Oss®–Geistlich). Controls were affected after 12 and 30 months, at the time of controls and nowadays the tooth remains asymptomatic and functional.

CLINICAL CASE – ENDODONTIC TREATMENT

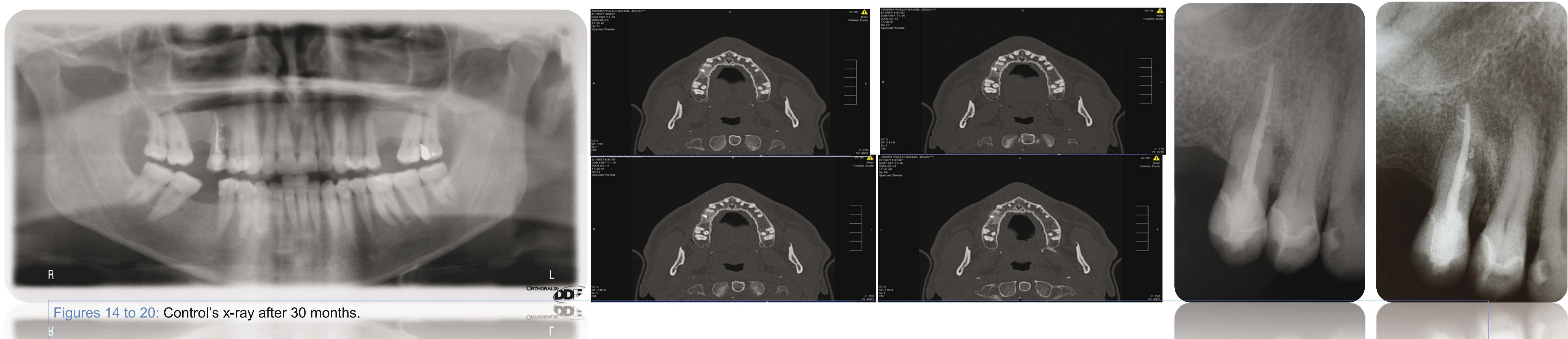


CLINICAL CASE – ENDODONTIC SURGERY



After 18 months, the patient appeared again with new pain symptoms, accompanied by edema and erythema of the buccal and palatal region of tooth 15. Endodontic surgery was performed, due to the location of lesion and successful clinical parameters of endodontic treatment, with curettage of the lesion and lateral periodontal bone regeneration was made with natural bone substitute material (Bio-Oss®–Geistlich).

CLINICAL CASE – CONTROL'S X-RAYS AND X-RAY COMPUTED TOMOGRAPHY



Controls were affected after 12 and 30 months. At the time of controls and nowadays the tooth remains asymptomatic and functional.

KEY LEARNING

- Clinical, radiologic and pathologic features of external invasive root resorption provide the basis for a clinical classification.
- Etiology of external invasive root resorption remains obscure and the knowledge of potential predisposing factors is important in assessing patients' risk.
- Treatment of external invasive root resorption should aim at the inactivation of all resorbing tissue and the reconstitution of the resorptive defect either by the placement of a suitable filling material or by the use of biological systems.
- MTA ProRoot®-Dentsply opens a range of different options for treating external invasive root resorption and had proved to be an excellent biomaterial, significantly improving the prognosis of injuries.
- External invasive root resorption require enhanced initial differential diagnosis, lacking appropriate guidance in the literature for the clinical treatment of these cases, leaving open the treatment protocol.

BIBLIOGRAPHY

- Sato S, Hasuike A, Yoshinuma N, Ito K. Invasive cervical root resorption 15 years after modified Widman flap surgery. *Journal of Oral Science*, 55:183-185, 2013.
- Arora A, Acharya S, Muliya V, Sharma P. Multiple idiopathic cervical resorption: A diagnostic dilemma; *Quintessence International*, 43:187-90, 2012.
- Kim Y, Lee CY, Kim E, Roh BD. Invasive cervical resorption: treatment challenges. *Restor Dent Endod*, 37:228-31, 2012.
- Özer SY. Diagnosis and Treatment Modalities of Internal and External Cervical Root Resorptions: Review of the Literature with Case Reports; *International Dental Research*, 1:32-37, 2011.
- Patel S, Dawood A, Wilson R, Horner K, Mannocci F. The detection and management of root resorption lesions using intraoral radiography and cone beam computed tomography – an in vivo investigation. *International Endodontic Journal*, 42: 831-38, 2009.
- Velvart P, Peters C. Soft Tissue Management in Endodontic Surgery. *Journal of Endodontics*, 31: 4-16, 2005.