



## INTRODUCTION

Caries has been pointed out by various authors as being the main factor for early tooth loss in young patients.<sup>(1)(2)</sup> It deeply influences oral health of children, even after eruption of the permanent teeth, because it causes undesired tooth movement, decreased length of arches<sup>(3)(5)(9)</sup>, change in the eruption sequence of the permanent teeth, inadequate development of mastication, swallowing, deleterious habits, speech alterations, midline deviation that can possibly lead to facial asymmetries.<sup>(6)</sup> Studies demonstrate that when primary molars are lost there will be arch decrease, which is significantly more severe in the mandible than in the maxilla, distal movement of the anterior-inferior primary teeth<sup>(1)(2)(9)</sup> and mesialization of the first permanent molar.<sup>(5)(7)</sup> Guidelines of the American Academy of Odontopediatrics claim that the use of space maintaining appliances is indicated to avoid loss of arch perimeter, maintaining the relative position of the existing teeth, the healthy development of the facial muscles and the normal establishment of the definitive occlusion.<sup>(2)</sup>

## PURPOSE

This study has the aim to demonstrate the clinical case of a young patient with premature loss of deciduous teeth. This way, we opted to use a removable space maintainer (with teeth and a screw).

## CLINICAL CASE

### CLINICAL HISTORY

- Six-year-old boy;
- Chief complaint "Treat caries" (sic);
- Pneumonia episodes and e hospitalization in May 2015, ear infections and mouth breathing.

### DIAGNOSIS

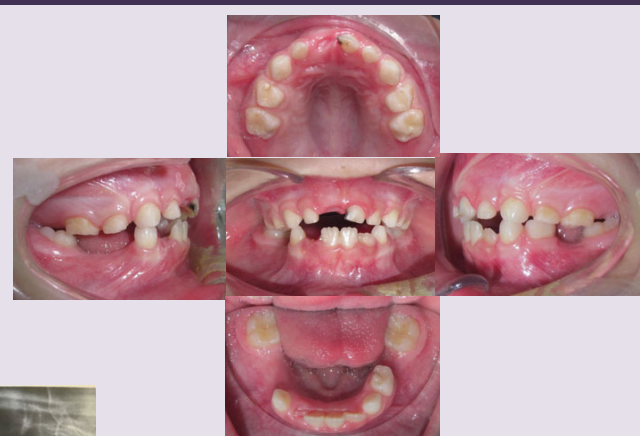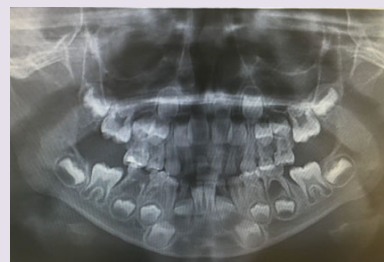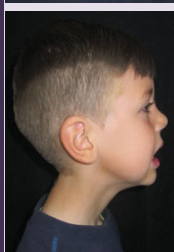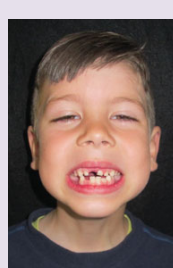
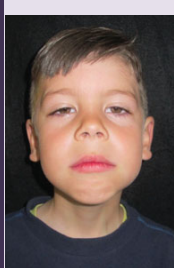- Extra oral Exam: dolichofacial pattern
- Intra oral Exam: multiple carious; with associated fistula on teeth 51, 75 and 84; midline deviation;
- Radiographic Exam: multiple carious;
- Functional Exame: mouth breathing, tongue interposition and child swallowing disorder.

### PROGNOSIS

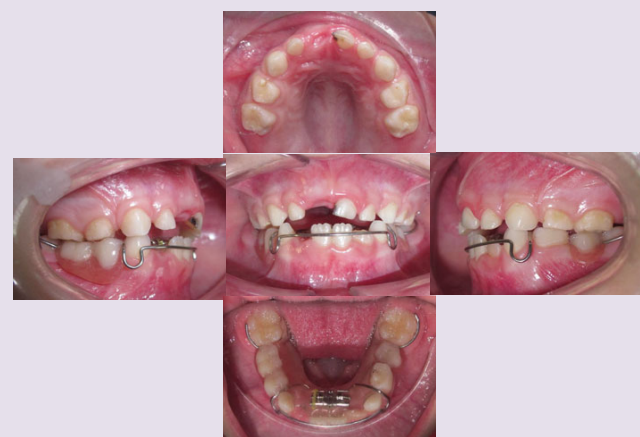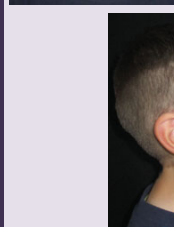
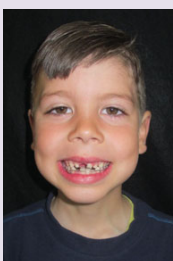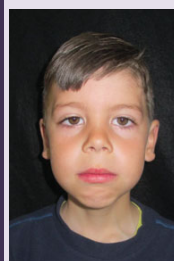- Favorable

### TREATMENT PROCEDURES

- Extraction teeth 51, 75, 84 e 85;
- Restoration on teeth 54, 55, 62, 64, 65, 73, 83 54, 55, 62, 64, 65, 73 e 83;
- Inferior removable space maintainer with a vestibular arch and an middle expansion screw



Intra and Extra oral photo and diagnosis exam.



Intra and Extra oral photo with a removable space maintainer.

## CONCLUSION

The mandibular removable appliance is for certain an important technique in maintaining the tooth space, restore physiological mastication and a good phonation. It's a functional appliance with a good patient compliance which was confirmed with a two months of follow-up.

## DISCUSSION

The maintainer space helps prevent the mesial movement of the first permanent molars when there is premature loss of deciduous molars. It prevents the loss of transverse dimension of the arches.<sup>(4)(5)</sup> Removable appliances are indicated in the absence of multiple teeth, they can be designed with acrylic teeth to replace edentulous spaces and some type of retention system. Once removed the hygiene is easier to maintain, however it requires the collaboration of the child.<sup>(4)</sup> The dentist should evaluate the variables and re-evaluate its decisions in accordance with the dynamic development of the patient's dentition.<sup>(10)</sup>

## REFERENCES

1. Tunison, W. Flores-Mir, C. ElBadrawy, H. Nasser, U. and El-Bialy, T. (2008). Dental Arch Space Changes Following Premature Loss Of Primary First Molars: A Systematic Review. *Pediatric Dentistry*, 30(4), 297-302.
2. Heilborn, J. C. A., Kuchler, E. C., Fidalgo, T. K. S., Antunes, L. A. A. and Costa, M. C. (2011). Early Primary Tooth Loss: Prevalence, Consequence and Treatment. *International Journal Dental, Recife*, 10(3), 126-130.
3. Khare, V., Nayak, P. A., Khandelwal, V. and Nayak, U. A. (2015). Case Report: Fixed functional space maintainer: novel aesthetic approach for missing maxillary primary anterior teeth. *British Medical Journal*, doi:10.1136/bcr-2013-009585
4. Clarico, S. (2013). Management of Premature Primary Tooth Loss in the Child Patient. *Journal of The California Dental Association*, 41(8), 612-618.
5. Wilson, B., Joseph, J., Bharadwaj, P. and Kaushik, P. (2014). Space Management in Pediatric Dentistry. *The Journal of Dental Practice*, 1(2), doi:10.15636/jdp/2014/v1i2/58422
6. Cobos, K.S.C., Roa, J.J.C., Corredor, D.M.N., Schmidt, V.G. and Quiñero, L.C.B. (2014). Premature Loss of Primary Teeth in Children of 0 to 8 years. *Colombia Journal of Dental Research*, 5(13).
7. Al-Dulayme, D.A. and Al-Khanqa, M.R. (2014). Mandibular dental arch dimensional changes following prematurely lost deciduous molars. *Journal of Oral and Dental Research*, 2(1), 2310-6417.
8. Goenka, P., Sarawgi, A., Marwah, N., Gumber, O. and Dutta, S. (2014). Case report: Simple Fixed Functional Space Maintainer. *International Journal of Clinical Pediatric Dentistry*, 7(3), 225-228.
9. Alexander, S. A., Askari, M. and Lewis, P. (2015). The premature loss of primary first molars: Space loss to molar occlusal relationships and facial patterns. *Angle Orthodontist*, 85(2), 218-223. doi: 10.2319/030714-160.1
10. Khanna, P., Sunda, S. and Mittal, S. (2015). "Keep My Space" - A Review Article. *International Journal of Oral Health Dentistry*, 1(1), 11-15.