




Three-dimensional Analysis of Asymmetrical Maxillary Molar Distalization Using the Indirect Palatal Miniscrew Anchorage and Distalization Appliance

Kamontip Sujaritwanid, Eduardo Yugo Suzuki, Boonsiva Suzuki
Department of Orthodontics, Faculty of Dentistry, Bangkokthonburi University, Thailand



Introduction

Maxillary molar distalization is an important alternative treatment for the correction of Class II malocclusions. The indirect Palatal Miniscrew Anchorage and Distalization Appliance (iPANDA) was designed to allow controlled movement of maxillary molar teeth during distalization. However, there is no study about the tooth movement in three dimensions using the iPANDA.

Aim of study

The purpose of this clinical study was to evaluate the dentoalveolar changes in three dimensions after asymmetrical maxillary molar distalization using iPANDA.

Materials and Methods

The study group comprised 14 patients (mean age, 22.4 ± 2.1 years) with a Class II molar dental relationship with anterior crowding. All patients were treated by nonextraction with the iPANDA for unilateral maxillary molar distalization. The second molar was separately distalized by buccal open-coil spring followed by the first molar distal movement (Fig.1).

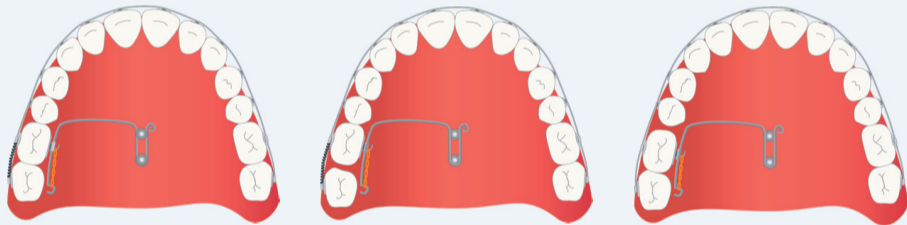


Fig. 1 The illustration of the iPANDA design for unilateral molar distalization

Three-dimensional virtual maxillary models and lateral cephalometric radiographs were obtained before (T0) and after (T1) distalization.

Model measurement

A reference plane for measurement was constructed in the sagittal, transverse, and vertical planes through the palatal miniscrews (Fig.2,3). The models were superimposed with surface-to-surface matching in the palatal area, which included the midpalatal screws of the iPANDA and the rugae as references.

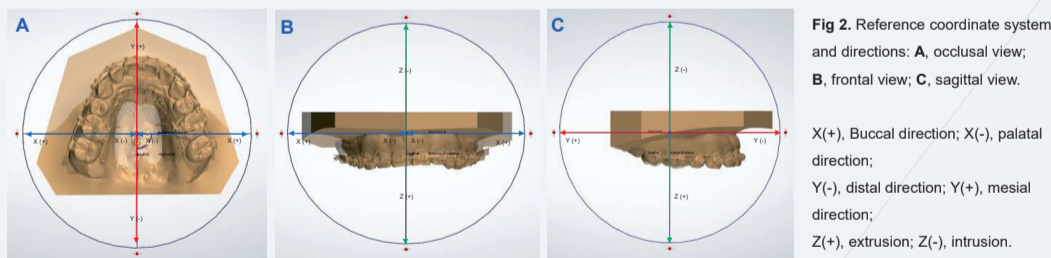


Fig 2. Reference coordinate system and directions: A, occlusal view; B, frontal view; C, sagittal view.
X(+), Buccal direction; X(-), palatal direction;
Y(-), distal direction; Y(+), mesial direction;
Z(+), extrusion; Z(-), intrusion.

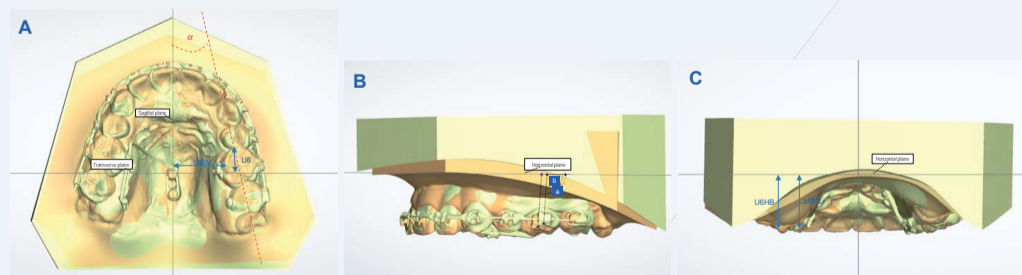


Fig 3. Measurement of the superimposed 3D digital models. A, Antero-posterior measurement (U6: distance between mesial contact point of first maxillary molar to transverse plane) and transverse measurement (U6W: distance between mesiolingual cusp tip to sagittal plane, α : angle between central groove of first maxillary molar and sagittal plane); B a, b angle measurement (angle between facial axis point and horizontal plane); C Vertical measurement (U6HB: mesiobuccal cusp tip and U6HLi: mesiolingual cusp tip to horizontal plane)

Lateral cephalometric analysis

The x-rays were superimposed at the miniscrews and investigated using SmartCeph software (Fig. 4).

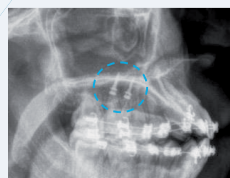
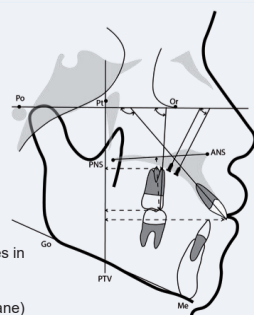


Fig 4. Cephalometric analysis: angles and distances in cephalogram measured before and after molar distalization (changes in the sagittal and vertical plane)



The linear and angular tooth changes were measured (Fig. 3,4) and analyzed using the descriptive statistics.

Results

- Class I molar and canine relationship was obtained. Maxillary second molars were controlled distalization (Fig. 5).

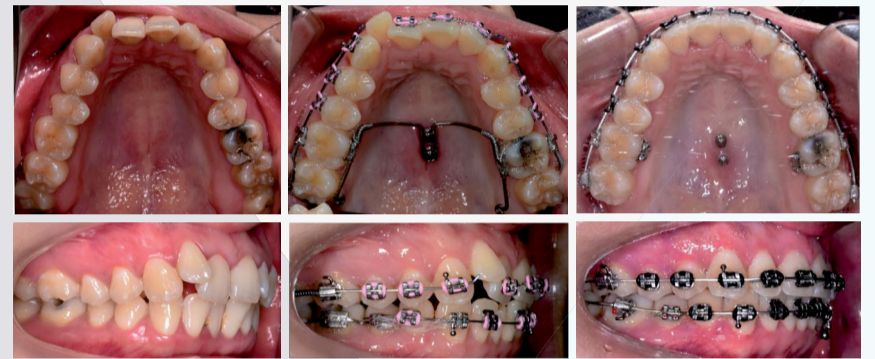


Fig 5. Clinical photo of pre and post-distalization

Model analysis

- In the sagittal plane, the first molars showed a mean linear distal movement of $1.95 \text{ mm} \pm 0.51 \text{ mm}$ and the average molar inclination was changed by $4.29^\circ \pm 2.87^\circ$ (Table1).
- In the transverse plane, slight expansion of the first molar was observed, with a mean value of $1.72 \text{ mm} \pm 0.97 \text{ mm}$; rotation of the first molars was $2.33^\circ \pm 2.11^\circ$ distal-out rotation.
- In the vertical plane, the first molars showed slight intrusion, with a mean value of $0.83 \text{ mm} \pm 0.81 \text{ mm}$.

Descriptive Statistics

| | Mean | Std. Deviation |
|-------------|-------------------------------|----------------|
| Linear (mm) | Amount of molar distalization | -1.9457 |
| | Molar width | 1.7179 |
| | Height | -0.8264 |
| Angular (°) | Rotation | 2.3321 |
| | Angulation | -4.2943 |

Table1. The values of tooth movement in the models

Lateral cephalometric analysis

Maxillary first molar crowns were distalized by mean of $1.97 \text{ mm} \pm 0.54 \text{ mm}$; root also distalized by mean of $1.54 \text{ mm} \pm 0.60 \text{ mm}$ and angulation was changed in $3.77^\circ \pm 2.17^\circ$ (Table 2).

Descriptive Statistics

| | Mean | Std. Deviation |
|-------------|---------|----------------|
| Linear (mm) | U6-PTV | -1.9650 |
| | U6r-PTV | -1.5429 |
| | U6-PP | -0.9643 |
| | U1-PTV | -1.1000 |
| Angular (°) | U6-FH | -3.7786 |
| | U1-FH | -4.7186 |
| | Mmi-FH | 2.5143 |

Table2. The values of tooth movement in the x-ray

Conclusions

Nonextraction treatment for Class II subdivision malocclusions was achieved by iPANDA for unilateral molar distalization. Controlled angulation movement of maxillary molars were observed with slight side effects in the vertical and transverse plane.

References

- Suzuki EY, Suzuki B. Maxillary molar distalization with the Indirect Palatal Miniscrew for Anchorage and Distalization Appliance (iPANDA). Orthodontics The Art and Practice of Dentofacial Enhancement 2013;14(1):e228-e41.
- Suzuki EY, Suzuki B. The Indirect Palatal Miniscrew Anchorage and Distalization Appliance. J Clin Orthod 2016;50(2):80-96.
- iPANDA (indirect Palatal Miniscrew Anchorage and Distalization Appliance) Manual, 2005
- Wilmes B, Nienkemper M, Ludwig B, et al. Esthetic Class II treatment with the Beneslider and aligners. J Clin Orthod 2012;46(7):390-8; quiz 437.
- Jang I, Tanaka M, Koga Y, et al. A novel method for the assessment of three-dimensional tooth movement during orthodontic treatment. Angle Orthod 2009;79(3):447-53.