

Is Intentional Replantation Appropriate for Treatment of Extensive Endodontic-periodontal Lesions Related to Palatogingival Groove?

Bing HAN^{1*}, Ying Yi LIU^{1*}, Kai Ning LIU², Min GAO³, Zu Hua WANG¹, Xiao Yan WANG¹

This report describes the cases of two patients with a maxillary lateral incisor with palatogingival groove and extensive endodontic-periodontal lesions. Although it is reported that acceptable periodontal status is of great importance in case selection in intentional replantation, it is suggested in this report that intentional replantation could be chosen instead of immediate extraction if extensive endodontic-periodontal lesions exist in a tooth with palatogingival groove. The gingival margin position and gingival papilla were well preserved and the bone defect was almost completely repaired. This was beneficial to the aesthetic prosthodontic treatment and implantation, although external root resorption was observed.

Key words: bone repair, endodontic-periodontal lesion, external root resorption, intentional replantation, palatogingival groove

Chin J Dent Res 2020;23(3):205–214; doi: 10.3290/j.cjdr.a45225

Palatogingival groove is a developmental anomaly that usually starts near the cingulum of the tooth and extends along the root with varying lengths. It is predominantly found on the lingual aspect of maxillary lateral incisors. It is clinically significant because of its relevance to the onset of periodontal inflammation. The incidence of palatogingival groove is reported to be between 2.8% and 18%¹. Its aetiology is still unclear, but it is speculated that it could be due to a mild form of dens invaginatus or unsuccessful formation of another root².

Multiple case reports have described treatment methods for palatogingival groove, ranging from the resec-

tion of an accessory root to periodontal regeneration, depending on the extent of the osseous defect. The treatment principles are complete eradication of microorganisms, permanent and thorough sealing of the root groove that communicates between the root canal and the periodontium, and periodontal regeneration and complete healing of the periodontium. The clinician should choose a method that eliminates the causative pathological factor to achieve a favourable outcome. During the treatment process, the clinician should first examine whether the pulp is involved in the pathological change. If the infection progresses along the groove to the apex, the apical pulp might also be involved through the apical foramen. Endodontic treatment is recommended first if the pulp is in a pathological state. For such complex cases, several methods can be used: granulation tissue removal through a flap with or without the guided tissue regeneration technique, intentional extraction of a problematic tooth to completely remove the groove and subsequent reimplantation (intentional replantation), and extraction. If the tooth needs to be preserved, the groove should be ground and sealed with filling materials.

Teeth with sufficient periodontal support after surgery could be treated with combined endodontic-periodontal treatment. It would be effective to combine nonsurgical endodontic treatment and periodontal regenerative surgery^{3,4}. Compromised periodontal sta-

1 Department of Cariology and Endodontology, Peking University School and Hospital of Stomatology, National Engineering Laboratory for Digital and Material Technology of Stomatology, Beijing Key Laboratory of Digital Stomatology, Beijing, P.R. China.

2 Department of Periodontology, Peking University School and Hospital of Stomatology, Beijing, P.R. China.

3 Department of Geriatric Dentistry, Peking University School and Hospital of Stomatology, Beijing, P.R. China.

* These authors contributed equally to this work.

Corresponding author: Dr Zu Hua WANG, Department of Cariology and Endodontology, Peking University School and Hospital of Stomatology, 22 Zhongguancun South Street, Haidian District, Beijing 100081, China. Tel: 86-10-82195385; Fax: 86-10-62173402. Email: wangzuhua@pkuss.bjmu.edu.cn

This work was supported by a grant from the Beijing Municipal Science and Technology Commission (grant no. Z121107001012027).

tus is a contraindication to surgery⁵, so for teeth without enough periodontal support after surgery, intentional replantation may be the only method to preserve them without extraction⁶.

A systematic literature search (up to May 2020) was conducted using the relevant search terms in PubMed. There were four case reports on the treatment of extensive endodontic-periodontal lesions related to palatogingival groove with modern intentional replantation^{1,6-8}. The follow-up period for these cases was no more than 18 months, thus the longer-term prognosis was uncertain.

Modern intentional replantation with careful case selection may be considered as a last resort for preserving hopeless teeth. However, the criteria for case selection remain controversial. Grzanich et al⁹ reported that acceptable periodontal status is of great importance in case selection. As teeth with extensive endodontic-periodontal lesions always have unacceptable periodontal status, it is uncertain whether intentional replantation is an appropriate treatment procedure. This report describes the cases of two patients with a maxillary lateral incisor with palatogingival groove and extensive endodontic-periodontal lesions, who were treated with modern intentional replantation.

Case reports

Case 1

A 27-year-old man with good general health presented to the Outpatient Department of Peking University School and Hospital of Stomatology complaining of pus discharge from his gingiva in his maxillary left anterior quadrant for 3 months. In the clinical examination, the maxillary left lateral incisor had an intact crown without caries or fracture, with a negative response to vitality testing and a positive response to percussion. Clinical examination revealed an apparent sinus tract on the labial gingiva between the maxillary left central incisor and lateral incisor (Fig 1a), and localised bleeding on probing and subgingival calculus (Fig 1b). Deep vertical overlap was observed in the anterior region. Occlusal trauma was present in the maxillary left lateral incisor. The maxillary left lateral incisor had grade II mobility, while the mobility of the maxillary left central incisor was within physiological limits, with a positive response to vitality testing and a negative response to percussion. A palatogingival groove was detected in the maxillary left lateral incisor, accompanied by a 12-mm periodontal pocket in the mid-palatal region. On radiographs,

an extensive periradicular radiolucency was associated with the affected tooth, and a traceable sinus tract was detected using a gutta-percha cone (Fig 1c). CBCT imaging revealed a palatogingival groove which was found to extend from the coronal third to the apical third of the root (Fig 1d). A serious bone defect was also observed around the tooth with CBCT (Figs 1e to 1h). The clinical and radiographic findings were consistent with the diagnosis of a severe endodontic-periodontal lesion associated with a palatogingival groove in the maxillary left lateral incisor. Although the prognosis was considered poor, the patient requested to keep this natural tooth. His request was considered, and an interdisciplinary treatment plan was formulated, which involved prophylaxis, scaling and root planning; root canal treatment (RCT); and intentional replantation.

Before treatment, occlusion adjustments were made in the maxillary left lateral incisor. The patient was well informed about the procedures and the possibility of poor prognosis. After the systematic periodontal treatment, RCT was completed within two visits under rubber dam isolation. During the first visit, a size 15 K-File (Dentsply Sirona, Charlotte, NC, USA) was used to obtain patency after cavity access and preparation. The root canal instrumentation was completed with nickel-titanium rotary instruments (ProTaper Universal, Dentsply Sirona) with an endodontic motor (X-Smart, Dentsply Sirona) up to a size 35 endodontic K-File (Dentsply Sirona) using the crown-down technique. Copious amounts of 5.25% sodium hypochlorite solution and 17% ethylenediaminetetraacetic acid (EDTA) gel were used as irrigants. Calcium hydroxide (Multi-Cal, Pulpdent, Watertown, MA, USA) was used as a dressing medicament for 2 weeks. During the second visit, the tooth was obturated using gutta-percha and sealer (AH Plus, Dentsply Sirona) with the vertical compaction technique (BeeFill 2in1, VDW, Munich, Germany). Ultrasonic irrigation (Satelec P5 Newtron, Acteon, Merignac, France) and an endodontic microscope (S100/OPMI Pico, Carl Zeiss Meditec, Jena, Germany) were used throughout the treatment. The access cavity was coated with a two-step self-etching adhesive (Clearfil SE Bond, Kuraray Medical, Tokyo, Japan) and filled with a light-cured composite resin (Clearfil AP-X, Kuraray Medical). A postoperative radiograph was obtained after RCT (Fig 1i).

After 2 weeks, the sinus tract had not yet healed. However, a new sinus tract was detected on the palatal gingiva. The 12-mm deep mid-palatal pocket could also be probed. We decided to perform intentional replantation. First, a minimally invasive extraction of the maxillary left lateral incisor was accomplished under

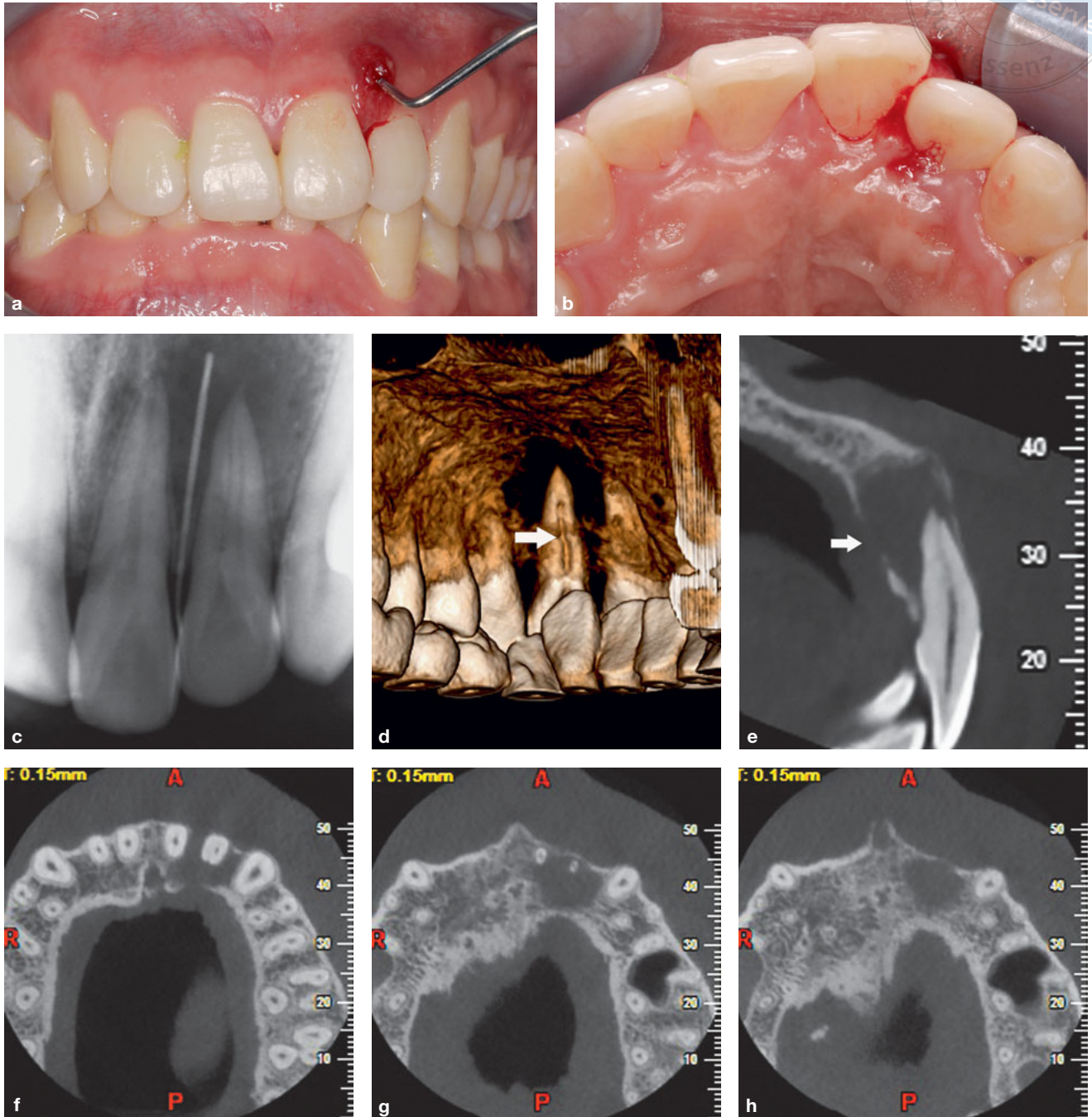


Fig 1 (a) The maxillary left lateral incisor. A preoperative clinical photograph shows a draining sinus tract on the labial gingiva. (b) A palatogingival groove was detected on the maxillary left lateral incisor, accompanied by a 12-mm periodontal pocket in the mid-palatal region. (c) A sinus tract that was traceable to the periradicular radiolucency associated with the maxillary left lateral incisor was detected with a gutta-percha cone. (d) A palatogingival groove was clearly revealed by CBCT and was found to extend from the coronal third to the apical third of the root. (e)–(h) A serious bone defect around the tooth was observed with CBCT. The tooth was considered to have a very poor prognosis.

local anaesthesia. Then, the extracted tooth was placed in a sterile saline solution. Extensive inflammatory granulation tissue in the extraction socket was scraped thoroughly. The tooth was held gently by the crown

with a physiological saline-soaked gauze (Fig 1j). The palatogingival groove was removed with a diamond bur under an endodontic microscope, and the apical 3 mm of the root apex was resected (Fig 1k). The root

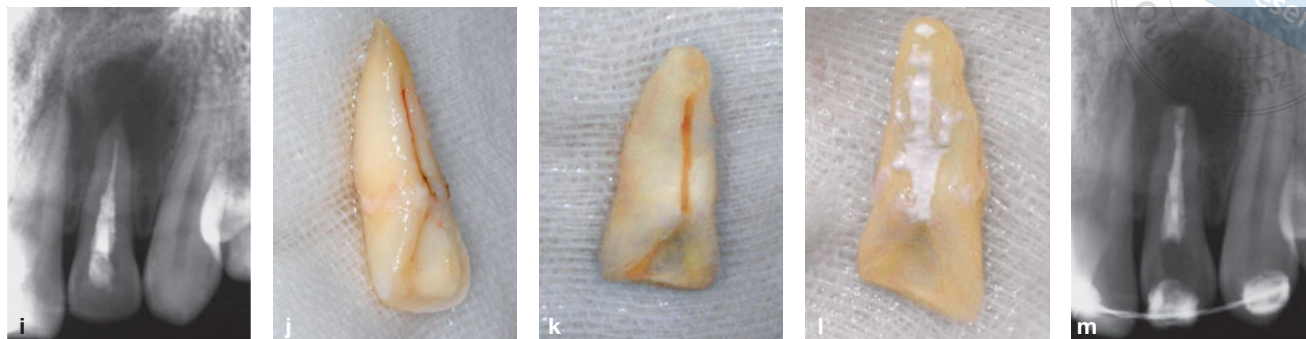


Fig 1 (cont.) (i) Radiograph taken after RCT. (j) The extracted tooth was placed in a sterile gauze soaked with saline solution. (k) The palatogingival groove was removed with a diamond bur, and the apical 3 mm of the root apex was resected and retrogradely prepared. (l) Both the palatogingival groove and the root apex were filled with MTA. (m) Radiograph taken after intentional replantation.

resection removed the end of the root containing the aberrant canals. The Satelec P5 Newtron was then used to complete the retrograde preparation. Both the palatogingival groove and the root apex were filled with Pro Root MTA (Dentsply Sirona) (Fig 1l). The tooth was then replanted into its alveolar socket and splinted with a semi-rigid splint for 4 weeks. The procedure lasted 15 minutes. The occlusion adjustment was examined and was not needed immediately after the surgery. A radiograph was taken after the treatment (Fig 1m).

At the 1-month follow-up after intentional replantation, the semi-rigid splint was dismantled. The two sinus tracts had closed thoroughly. The mobility of the tooth had changed from grade II to within physiological limits. At the 1-, 3-, 6-, 12- and 18-month follow-ups,

periapical and periodontal healing was observed as time progressed (Figs 2a to 2q). Occlusal adjustment was made at each follow-up to avoid occlusal trauma in the maxillary left lateral incisor. After replantation, the patient was asymptomatic.

Unfortunately, external root resorption was detected in the coronal and middle third of the root at the 24-month follow-up (Fig 2r). A sinus tract was also detected again (Fig 2s). The gingival margin position and gingival papilla were well preserved compared with the preoperative situation. No gingival recession was observed. The mid-palatal probing depth was 2 mm (Fig 2t). Although the extensive bone defect was almost repaired (Figs 2u and 2v), root fracture could easily occur, therefore tooth extraction was recommended.

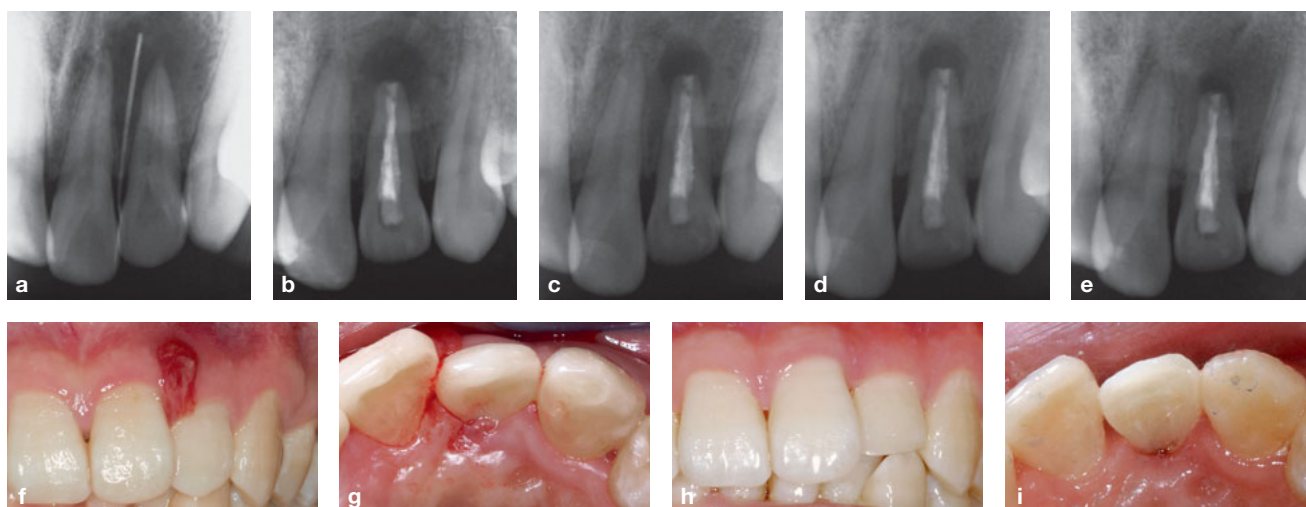


Fig 2 (a) Preoperative radiograph. (b) Radiograph taken at 3-month follow-up. (c) Radiograph taken at 6-month follow-up. (d) Radiograph taken at 12-month follow-up. (e) Radiograph taken at 18-month follow-up. (f) and (g) Preoperative clinical photographs. (h) and (i) Clinical photographs taken at 1-month follow-up.

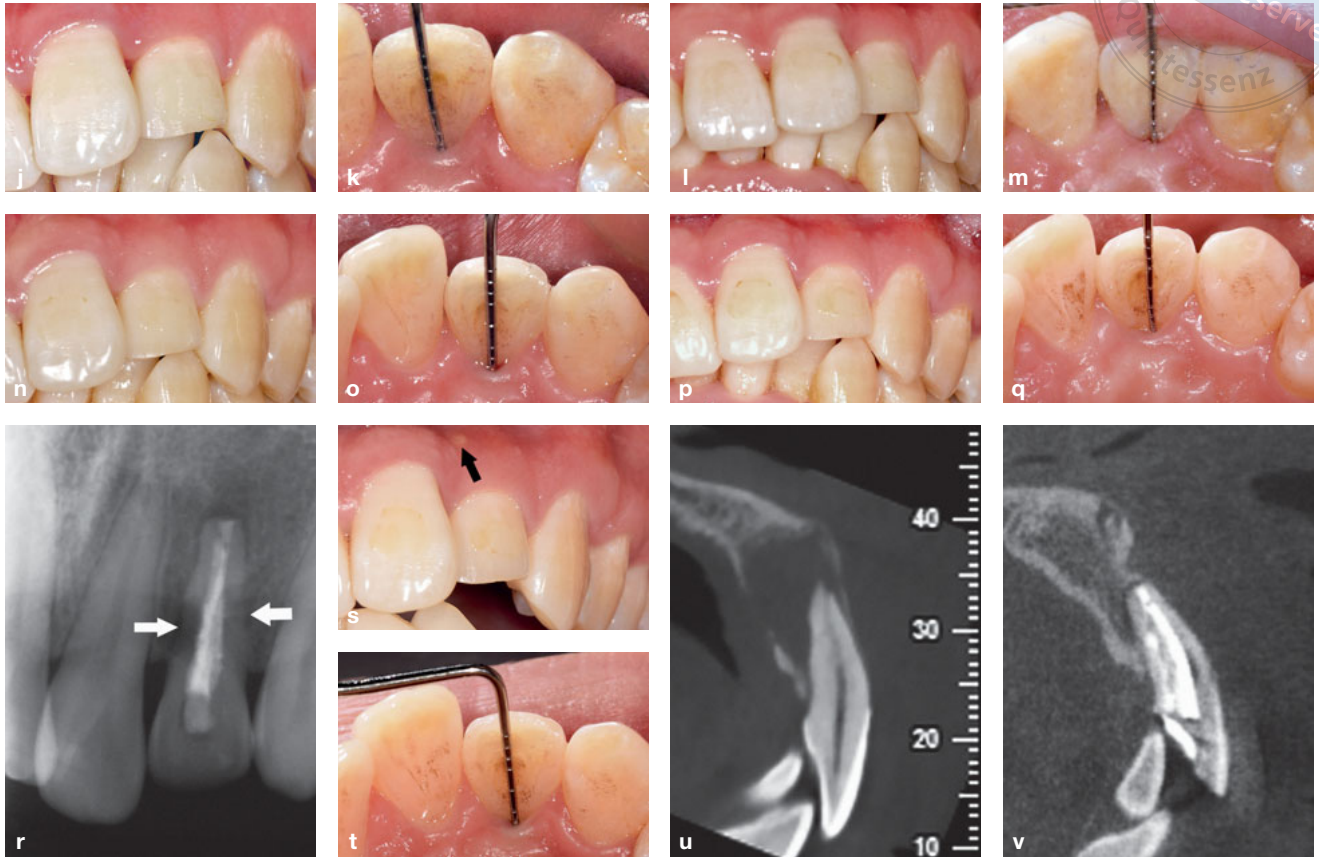


Fig 2 (cont.) (j) and (k) Clinical photographs taken at 3-month follow-up. (l) and (m) Clinical photographs taken at 6-month follow-up. (n) and (o) Clinical photographs taken at 12-month follow-up. (p) and (q) Clinical photographs taken at 18-month follow-up. (r) Postoperative radiograph taken at 24-month follow-up. External root resorption of the coronal and middle third of the root was detected at 24 months (white arrow). (s) A draining sinus tract was again detected on the labial gingiva (black arrow). The gingival margin position and gingival papilla were well preserved. (t) The mid-palatal probing depth was 2 mm. (u) Preoperative CBCT image (sagittal view) and (v) CBCT image taken at 24-month follow-up (sagittal view). The extensive bone defect was almost repaired.

Case 2

A 24-year-old woman with good general health presented to the Outpatient Department of Peking University School and Hospital of Stomatology complaining of pus discharge from the gingiva in the maxillary right anterior quadrant for 1 year. The maxillary right lateral incisor had been crowned with porcelain-fused-to-metal after RCT 3 years previously at a local dental clinic. In the clinical examination, the tooth did not show secondary caries or tooth mobility, but had a positive response to percussion. A sinus tract was also apparent on the labial gingiva between the maxillary right central incisor and lateral incisor (Fig 3a), with localised bleeding on probing and subgingival calculus. A palatogingival groove was detected in the maxillary right lateral incisor, with a 9-mm periodontal pocket in the mid-palatal region (Fig 3b). On radiographs, an extensive peri-

radicular radiolucency was associated with the affected tooth (Fig 3c). CBCT imaging revealed a palatogingival groove and extensive bone defect around the tooth (Figs 3d to 3g). The clinical examinations and radiographic findings were consistent with the diagnosis of an extensive endodontic-periodontal lesion associated with a palatogingival groove in the maxillary right lateral incisor after RCT. The patient appealed to try to preserve this natural tooth, despite the poor prognosis. As a result, an interdisciplinary treatment plan was formulated, which involved prophylaxis, scaling and root planning followed by intentional replantation.

The patient was informed of the procedures and the possibility of poor prognosis. A minimally invasive extraction of the maxillary right lateral incisor under local anesthesia was accomplished after the systematic periodontal treatment. Then, the extracted tooth was placed in a sterile saline solution. Extensive inflam-

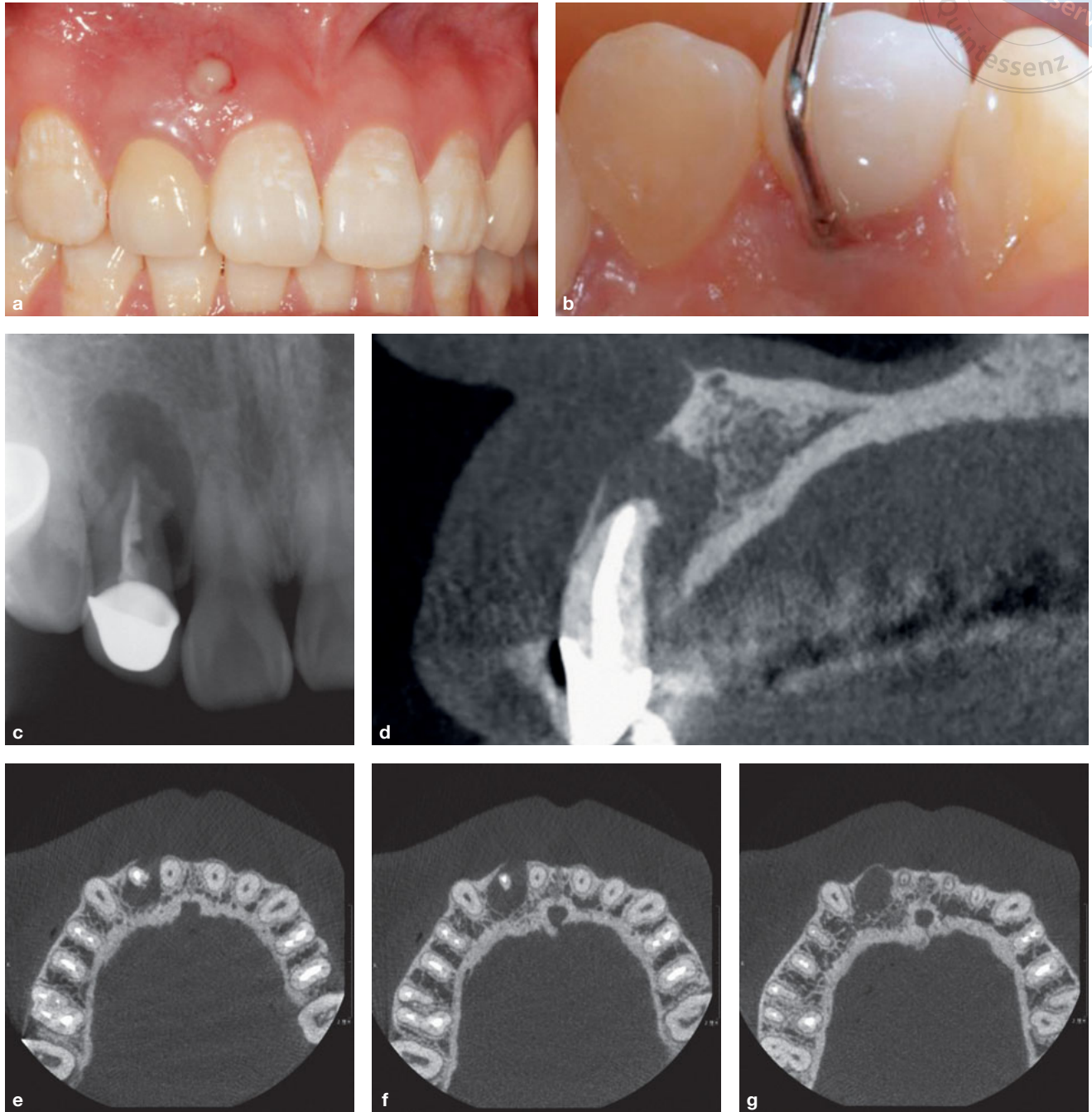


Fig 3 (a) The maxillary right lateral incisor. The preoperative clinical photograph shows a draining sinus tract on the labial gingiva. (b) A palatogingival groove was detected on the maxillary right lateral incisor, accompanied by a 9-mm periodontal pocket in the mid-palatal region. (c) On radiographs, an extensive periradicular radiolucency was associated with the affected tooth. (d)–(g) A serious bone defect was observed around the tooth with CBCT. The prognosis of the tooth was considered to be very poor.

matory granulation tissue in the extraction socket was scraped thoroughly. The tooth was held gently by the crown with a physiologic saline-soaked gauze (Fig 3h). The palatogingival groove was prepared with a diamond bur (Fig 3i) by an endodontic microscope

and filled with Pro Root MTA (Fig 3j). Then the tooth was replanted into its alveolar socket and splinted for 4 weeks with a semi-rigid splint. The procedure lasted 15 minutes and a postoperative radiograph was taken (Fig 3k).

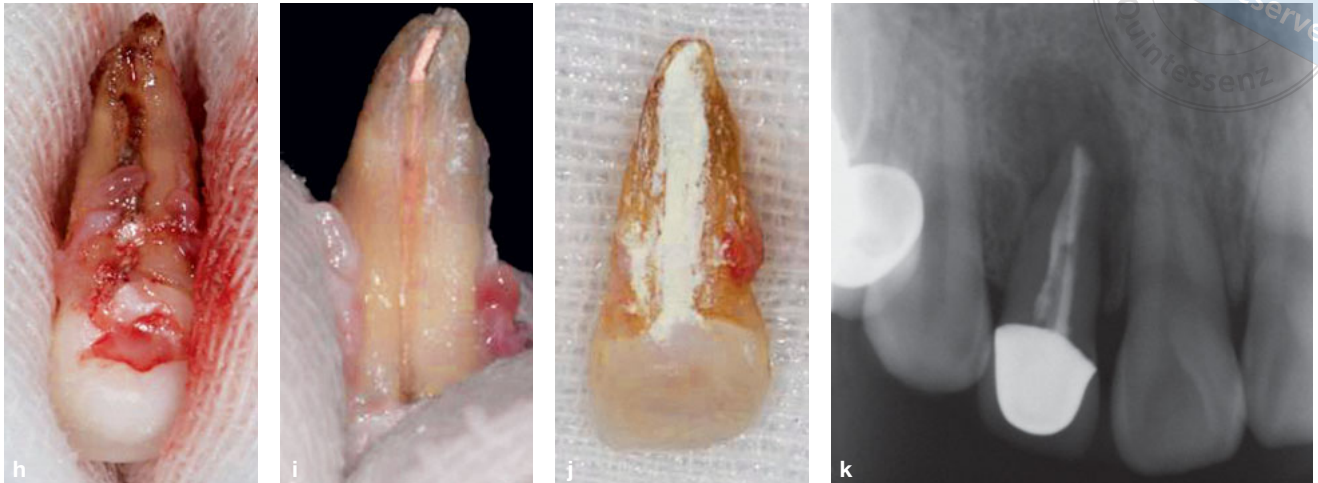


Fig 3 (cont.) (h) A palatogingival groove was clearly revealed and found to extend from the coronal third to the apical third of the root. (i) The palatogingival groove was removed with a diamond bur. (j) The palatogingival groove and root apex were filled with MTA. (k) Radiograph taken after intentional replantation.

The semi-rigid splint was dismantled at the 1-month follow-up after intentional replantation. The sinus tract had closed thoroughly. Compared with the preoperative situation (Fig 4a), at the 3-, 6- and 36-month follow-ups, periapical healing was observed as time progressed (Figs 4b to 4d). The patient was asymptomatic after replantation.

The gingival papilla was well preserved (Fig 4e) and the mid-palatal probing depth was 3 mm at the 36-month follow-up (Fig 4f), which is crucial for aesthetic restoration of anterior teeth. Unfortunately, external root resorption of the root was detected during this visit (Fig 4g). Although the extensive bone defect was almost repaired compared with the preoperative situation (Figs 4h and 4i), root fracture could easily occur and tooth extraction was therefore recommended.

Discussion

Intentional replantation is not a new procedure; according to Dryden and Arens¹⁰, it was used in the 18th century. Although it is not a frequently used treatment because of the wide variance in reported success rates¹¹⁻¹⁵, it may be considered as a last resort for preserving hopeless teeth⁹. A recent meta-analysis revealed a mean survival rate of 88% (95% confidence interval, 81 to 94%) for intentionally replanted teeth. During case selection, acceptable periodontal status is necessary⁹.

Although the reported incidence of palatogingival groove is not uncommon (between 2.8% and 18%), case reports on palatogingival groove with extensive

endodontic-periodontal lesions treated with intentional replantation are relatively few and most are followed up within 2 years^{1,6-8}. In the present case, intentional replantation was the only method to preserve the tooth because of the extensive bone defect, but the periodontal status of this case was obviously unacceptable.

The sinus tract after RCT was associated with the uncontrolled infection because the cause of the disease had not been resolved. In the present cases with serious bone defects and complicated root anatomy, it was essential to control inflammation if the tooth needed to be replanted. The groove space should be eliminated by grinding the groove and sealing it with a filling material, for example MTA. It has been verified that cement-like tissues form on the surface of MTA, which confirms regeneration of the periodontal ligament¹⁷. For the modern intentional replantation procedure, performing atraumatic extraction using state-of-the-art equipment, instruments and materials and minimal extra-alveolar time and maintaining an aseptic technique are the key factors for success⁹. All these procedures intend to control inflammation and promote tissue repair.

Although intentional replantation is an effective therapeutic decision for this type of deformity, the long-term prognosis is not certain. External root resorption and ankylosis may occur during the follow-up period¹⁸. For example, the prognosis of the cases in this paper was very good during the early 2- or 3- year follow-ups until external root resorption was observed.

During the treatment process, abundant inflammatory granulation tissue was found around the root. It was

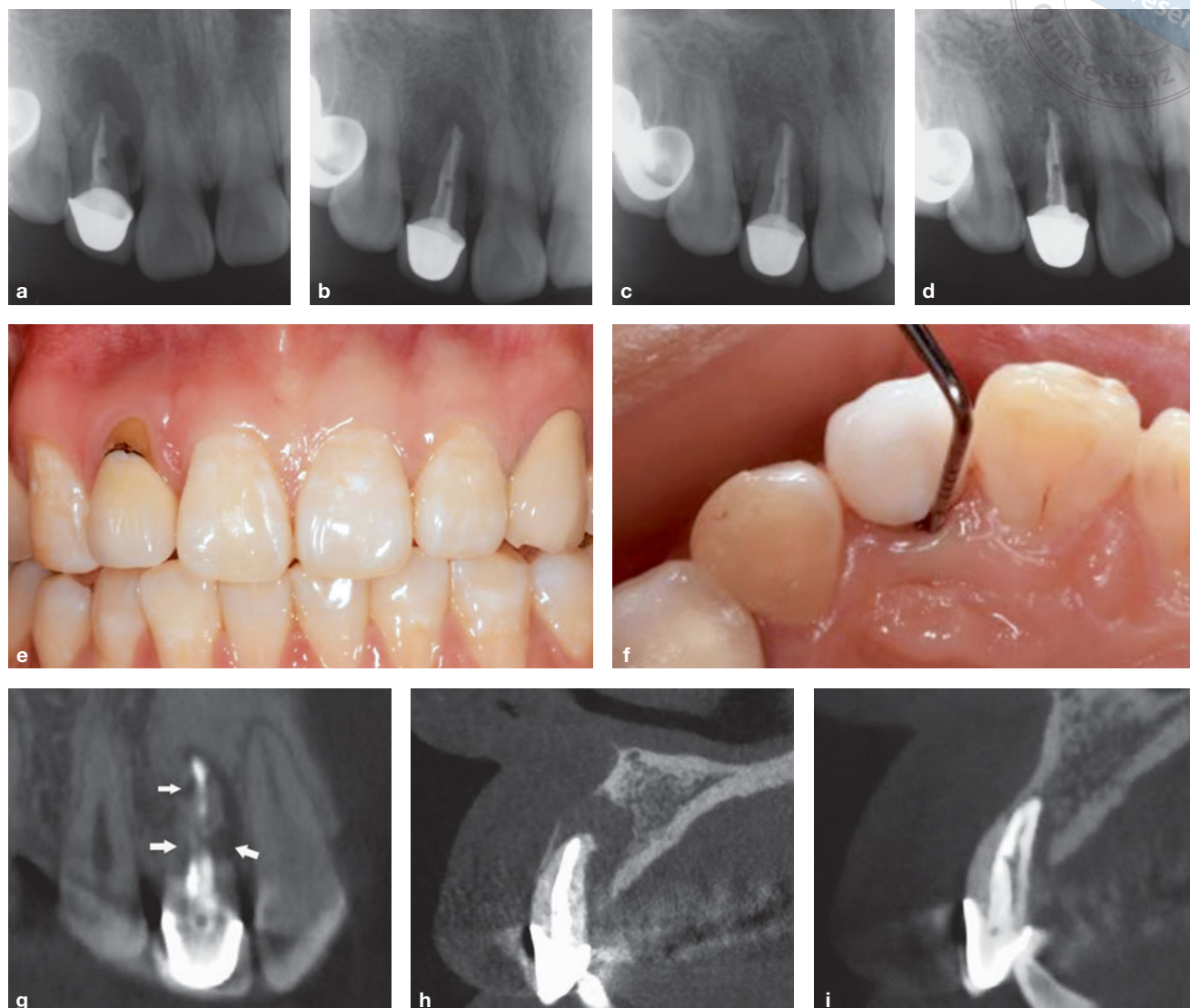


Fig 4 (a) Preoperative radiograph. (b) Radiograph taken at 3-month follow-up. (c) Radiograph taken at 6-month follow-up. (d) Radiograph taken at 36-month follow-up. Periapical healing was observed as time progressed compared with the preoperative situation. (e) and (f) At 36-month follow-up, the gingival papilla was well preserved, which is crucial for aesthetic restoration of anterior teeth. The mid-palatal probing depth was 3 mm. (g) External root resorption of the root was detected at 36 months (white arrow). (h) Preoperative CBCT image (sagittal view) and (i) CBCT image taken at 36-month follow-up (sagittal view). The extensive bone defect was almost repaired.

speculated that the periodontal ligament and intermediate cementum might be destroyed during the progress of the disease. The dentinal tubules are then open and communicate with inflammatory resorptive cells within the periodontal ligament and alveolar bone, causing root resorption¹⁹.

When serious endodontic-periodontal lesions are observed in a tooth with a palatogingival groove, especially in cases that are impossible to treat with periodontal surgery, it seems difficult for both dentist and

patient to choose between intentional replantation and extraction.

We sought to analyse whether modern intentional replantation or extraction should be chosen before treatment. Extensive alveolar bone defects (width and height deficiency) were observed at the first visit. If the tooth was extracted, the bone loss would continue to occur after tooth extraction, especially in the first few months²⁰. According to HVC ridge classification²¹, the hard tissue defect was classified as a C-1 defect at that

time; this meant that both the horizontal and vertical bone defects were larger than 7 mm. The bone defect in these cases would be difficult to using either a fixed prosthesis or an implant²¹. Because the result of vertical bone augmentation is poorly predictable, there is still a high risk of aesthetic problems such as black triangles even if a large block graft is used before implant insertion^{22,23}. In addition, even if an implant is not recommended for the restoration after extraction, it would still be very difficult to correct the bone defect and the aesthetic result would not be promising, regardless of whether a fixed prosthesis or removable partial denture was used²³. For these two cases, the bone defects were almost completely repaired after the first visit. The gingival margin position and gingival papilla were well preserved in case 1. The gingival papilla was well preserved and the slight gingival recession was corrected by periodontal surgery in case 2. The gingival recession in case 2 may be attributed to the thin periodontal biotypes, which are at greater risk of gingival recession²⁴. Although external root resorption ultimately occurred, the functional and aesthetic results were predictable irrespective of the type of prosthetic treatment.

Conclusion

In conclusion, if serious endodontic-periodontal lesions are diagnosed in a tooth with a palatogingival groove, intentional replantation could be chosen as the treatment method rather than immediate extraction. Inflammation can be controlled with the modern intentional replantation protocol, and the bone defect can be repaired over time. Even though external root resorption or ankylosis might occur due to the destroyed periodontal ligament and intermediate cementum, the repaired bone could be beneficial to the aesthetic prosthodontic treatment and implantation. This treatment could be considered as a transitional option even if it failed to preserve the teeth over the course of the follow-ups.

Acknowledgements

The authors thank the patients for their participation.

Conflicts of interest

The authors declare no conflicts of interest related to this study.

Author contribution

Drs Bing HAN, Ying Yi LIU, Kai Ning LIU and Min GAO contributed to the data acquisition; Drs Bing HAN and Ying Yi LIU contributed to the data analysis and prepared the manuscript; Dr Zu Hua WANG contributed to the conception, design and revision of the manuscript; Professor Xiao Yan WANG revised the manuscript.

(Received Dec 29, 2019; accepted Jun 04, 2020)

References

- Garrido I, Abella F, Ordinola-Zapata R, Duran-Sindreu F, Roig M. Combined endodontic therapy and intentional replantation for the treatment of palatogingival groove. *J Endod* 2016;42:324–328.
- Kerezoudis NP, Siskos GJ, Tsatsas V. Bilateral buccal radicular groove in maxillary incisors: case report. *Int Endod J* 2003;36:898–906.
- Cho YD, Lee JE, Chung Y, et al. Collaborative management of combined periodontal-endodontic lesions with a palatogingival groove: a case series. *J Endod* 2017;43:332–337.
- Sooratgar A, Tabrizzade M, Nouralahi M, Asadi Y, Sooratgar H. Management of an endodontic-periodontal lesion in a maxillary lateral incisor with palatal radicular groove: a case report. *Iran Endod J* 2016;11:142–145.
- Monaghan L, Jadun S, Darcey J. Endodontic microsurgery. Part one: diagnosis, patient selection and prognoses. *Br Dent J* 2019;226:940–948.
- Tan X, Zhang L, Zhou W, et al. Palatal radicular groove morphology of the maxillary incisors: a case series report. *J Endod* 2017;43:827–833.
- Yan H, Xu N, Wang H, Yu Q. Intentional replantation with a 2-segment restoration method to treat severe palatogingival grooves in the maxillary lateral incisor: a report of 3 cases. *J Endod* 2019;45:1543–1549.
- Forero-López J, Gamboa-Martínez L, Pico-Porras L, Niño-Barrera JL. Surgical management with intentional replantation on a tooth with palato-radicular groove. *Restor Dent Endod* 2015;40:166–171.
- Grzanich D, Rizzo G, Silva RM. Saving natural teeth: intentional replantation—protocol and case series. *J Endod* 2017;43:2119–2124.
- Dryden JA, Arens DE. Intentional replantation. A viable alternative for selected cases. *Dent Clin North Am* 1994;38:325–353 [erratum 1994;28:8].
- Caffesse RG, Nasjleti CE, Castelli WA. Long-term results after intentional tooth replantation in monkeys. *Oral Surg Oral Med Oral Pathol* 1977;44:666–678.
- Raghoobar GM, Vissink A. Results of intentional replantation of molars. *J Oral Maxillofac Surg* 1999;57:240–244.
- Bender IB, Rossman LE. Intentional replantation of endodontically treated teeth. *Oral Surg Oral Med Oral Pathol* 1993;76:623–630.
- Kingsbury BC Jr, Wiesenbaugh JM Jr. Intentional replantation of mandibular premolars and molars. *J Am Dent Assoc* 1971;83:1053–1057.
- Weine FS. The case against intentional replantation. *J Am Dent Assoc* 1980;100:664–668.
- Torabinejad M, Dinsbach NA, Turman M, Handysides R, Bahjri K, White SN. Survival of intentionally replanted teeth and implant-supported single crowns: a systematic review. *J Endod* 2015;41:992–998.
- Bartols A, Roussa E, Walther W, Dörfer CE. First evidence for regeneration of the periodontium to mineral trioxide aggregate in human teeth. *J Endod* 2017;43:715–722.

18. Andersson L. Dentoalveolar ankylosis and associated root resorption in replanted teeth. Experimental and clinical studies in monkeys and man. *Swed Dent J Suppl* 1988;56:1–75.
19. Gunraj MN. Dental root resorption. *Oral Surg Oral Med Oral Pathol Oral Radiol Endod* 1999;88:647–653.
20. Araújo MG, Lindhe J. Dimensional ridge alterations following tooth extraction. An experimental study in the dog. *J Clin Periodontol* 2005;32:212–218.
21. Wang HL, Al-Shammari K. HVC ridge deficiency classification: a therapeutically oriented classification. *Int J Periodontics Restorative Dent* 2002;22:335–343.
22. Bashutski JD, Wang HL. Common implant esthetic complications. *Implant Dent* 2007;16:340–348.
23. Simion M, Jovanovic SA, Tinti C, Benfenati SP. Long-term evaluation of osseointegrated implants inserted at the time or after vertical ridge augmentation. A retrospective study on 123 implants with 1-5 year follow-up. *Clin Oral Implants Res* 2001;12:35–45.
24. Cortellini P, Bissada NF. Mucogingival conditions in the natural dentition: narrative review, case definitions, and diagnostic considerations. *J Periodontol* 2018;89(Suppl 1):S204–S213.

