

Masashi Makino

# Treatment of deep bite with 'gummy smile' using clear aligners and temporary anchorage devices: a case report



Masashi Makino

**Key words** clear aligner, deep bite, gummy smile, incisor intrusion, temporary anchorage devices

*In adult cases of deep bite requiring retraction of the maxillary anterior teeth, bringing about vertical intrusion using an aligner appliance alone is considered difficult. The present case involved a patient with Angle Class II, division 2 malocclusion, presenting with the chief complaints of excessive gingival display and crowding. Temporary anchorage devices were placed in the maxillary alveolar gingiva, and intrusion of the maxillary anterior teeth was performed using precision cuts and traction via elastics in the anterior region of the aligner. This report presents the treatment results that were achieved in a short period of time using these mechanics.*

## Introduction

Class II malocclusion is common among the population of Japan and other Asian countries, often in association with deep bite. Some Class II patients also have a 'gummy smile' with gingival exposure  $\geq 4$  mm when smiling<sup>1</sup>. In cases of adult mandibular retrusion, where no further mandibular advancement can be expected, such cases require retrac-

tion of the maxillary anterior teeth with simultaneous intrusion. Orthodontic intrusion is classified as relative intrusion by crown tipping or absolute intrusion by vertical movement of the root in the direction of the tooth axis. In adult cases of deep bite requiring retraction of the maxillary anterior teeth, bringing about vertical intrusion using an aligner appliance alone is considered difficult<sup>2</sup>, as palatal root torque is also required<sup>3</sup>. The use of palatal bite ramps on the maxillary anterior teeth is the treatment of choice to achieve vertical intrusion with regular aligners, but this force system has low predictability, depending as it does on biting, and the resulting orthodontic force is thus intermittent. To ensure reliable treatment outcomes within a shorter time period, a force system that exerts continuous orthodontic force using temporary anchorage devices (TADs) for anchorage is needed. When a fixed appliance is used, adequate results can reportedly be obtained from intrusion using elastic chains with TADs in the maxillary alveolar gingiva<sup>4-9</sup>. Here, the present author reports satisfactory results from treatment using TADs with an aligner appliance applying similar mechanics.

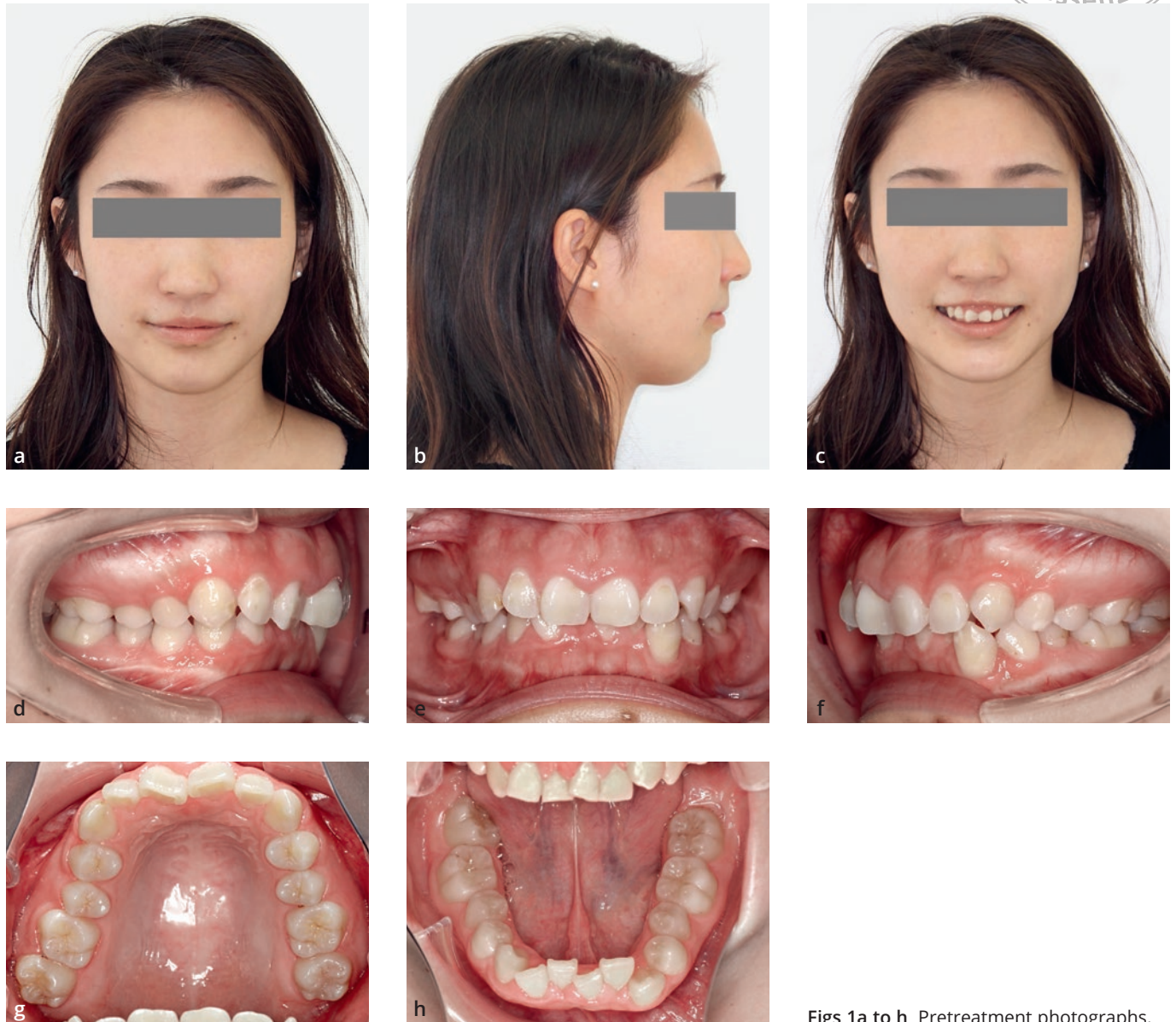## Case presentation

The patient was a 21-year-old woman with the chief complaints of crowding and excessive gingival display (Fig 1). On extraoral examination, the profile showed tension in the

---

Masashi Makino, DDS  
Doctor, Makino Orthodontic Clinic, Yachiyo, Chiba, Japan

**Correspondence to:** Dr Masashi Makino, Private practice, Makino Orthodontic Clinic, 1-2-19-201 Midorigaoka, Yachiyo, Chiba, 276-0049, Japan. Email: makino.ortho@gmail.com



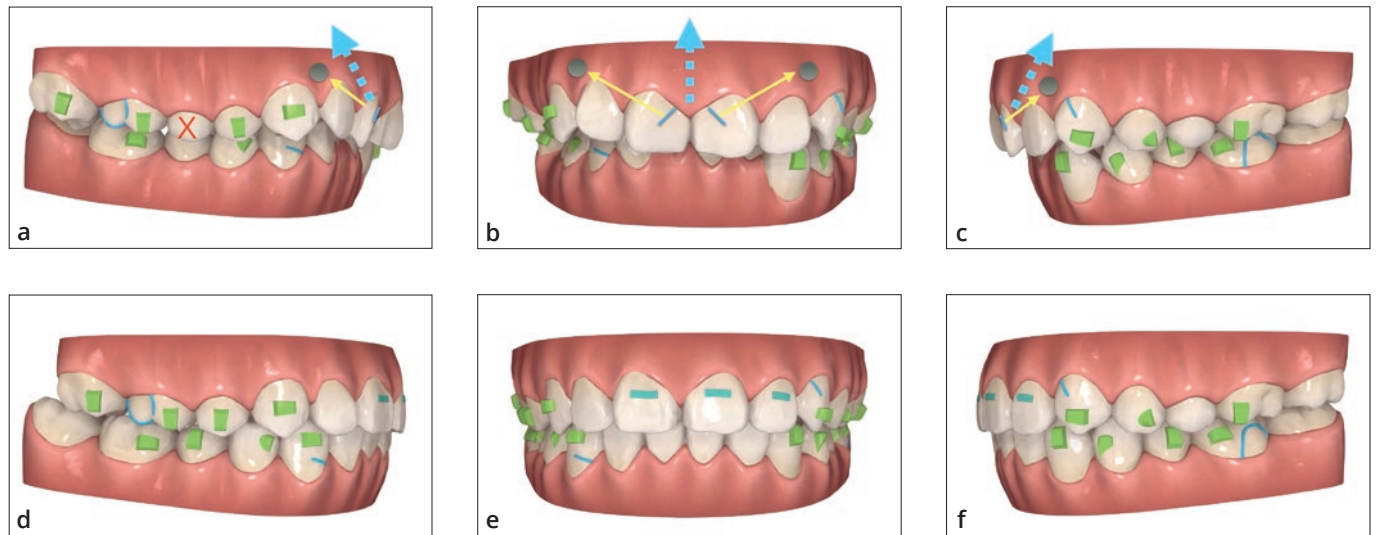
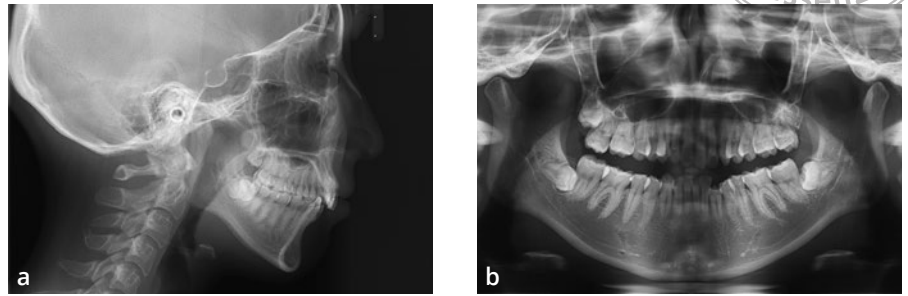
Figs 1a to h Pretreatment photographs.

lower lip when the lips were closed. The frontal view showed bilateral symmetry, and excessive gingival display with gingival exposure of 4 mm in the maxillary anterior region. Intraoral examination showed a deep bite due to excess horizontal and vertical overlap. The molar relationship was Class II on the right and Class II tendency on the left. In addition, scissor bite of the right second molars and crowding of the maxillary and mandibular anterior teeth were apparent.

No tooth root abnormalities were evident from panoramic radiography (Fig 2). With regard to the number of

teeth, no third molar tooth germ was observed in the maxillary right position. Analysis of the lateral cephalogram showed skeletal Class II (ANB 7.5 degrees) high-angle (mandibular plane angle 38 degrees). The incisor axis showed palatal inclination for the maxillary teeth and labial inclination for the mandibular teeth. The upper lip showed retrusion and the lower lip showed protrusion with respect to the E-line, with poor balance between the upper and lower lips. Based on these findings, the patient was diagnosed with Angle Class II, division 2 with excessive gingival display.

**Figs 2a and b** Pretreatment radiographic examination.



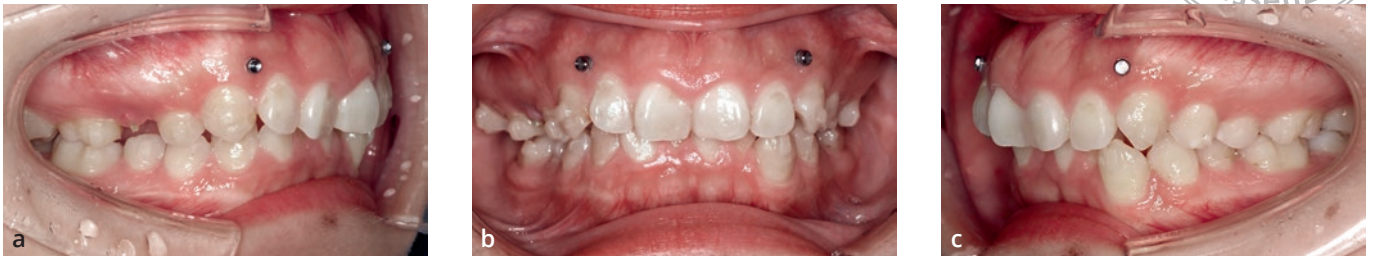**Figs 3a to f** First ClinCheck simulation: (a-c) initial and (d-f) final.

### Treatment plan

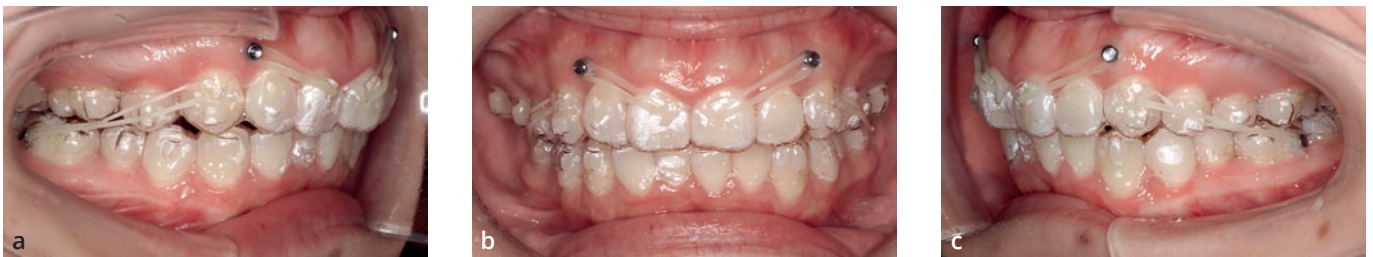Aligners (Invisalign; Align Technology, San Jose, CA, USA) were used in accordance with the expressed desires of the patient for an aesthetically acceptable orthodontic appliance. The treatment plan was formulated using analysis of existing types of orthodontic treatment as well as simulation software (ClinCheck; Align Technology) (Fig 3).

- On the right side, the plan was to correct the canine relationship to full Class II and achieve a Class II finish through extraction of the maxillary right second premolar (tooth 15 according to FDI notation), as this would help provide space for alignment of the maxillary right second molar (tooth 17), which exhibited scissor bite. Class III elastic was used (to the distal) to upright the mandibular right second molar (tooth 47). The maxillary right third molar (tooth 18) was awaiting eruption during the retention period.
- Another treatment plan was considered to achieve Class I, by extraction of the maxillary right third molar and distalisation of the maxillary right molars (teeth 16 to 18). However, at the request of the patient, extraction of the maxillary right second premolar was selected, as this would be advantageous in avoiding the surgical invasiveness of extracting the impacted maxillary right third molar and shortening the treatment period.
- On the left, bearing in mind that no third molar was present, the aim was to achieve Class I through distalisation of the maxillary molars in association with interproximal enamel reduction (IPR).
- Intrusion and retraction of the maxillary anterior teeth were performed using TADs (ACR; BioMaterials Korea, Seoul, Korea). These were placed bilaterally in the maxillary alveolar gingiva. Precision cuts were made, and full-time traction was provided by elastics when the

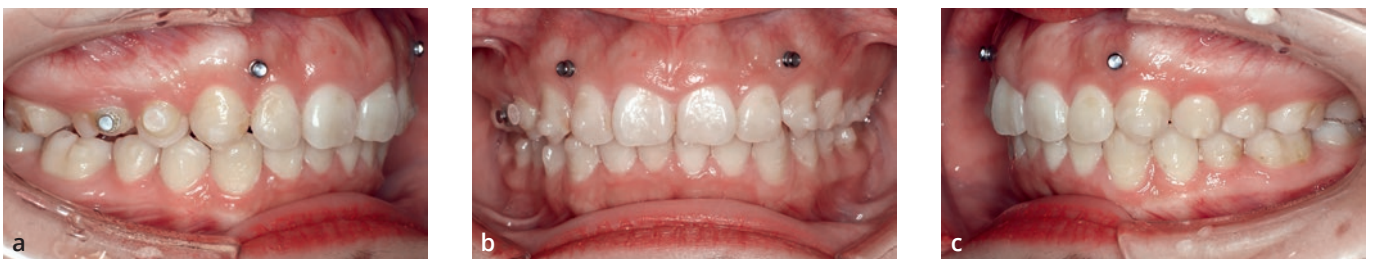



Figs 4a to c Treatment progress photographs at 1 month.



Figs 5a to c Treatment progress photographs with aligner at 8 months.



Figs 6a to c Treatment progress photographs at 14 months.

aligners were worn. In the first stage, the amount of intrusion of the maxillary anterior teeth was set at 2 mm, taking into account improvement of the gingival display.

- For the scissor bite on the right side, the plan was to apply extra crown torque to the maxillary and mandibular right second molars using cross elastics as required.
- Crowding of the mandibular anterior teeth was reduced while carrying out flaring to improve the deep bite. Bite ramps were fitted to the palatal side of the maxillary anterior teeth to provide efficient intrusion of the anterior mandibular teeth. IPR (0.5 mm) was performed for the mandibular left molars that were crowded due to lack of alignment space.

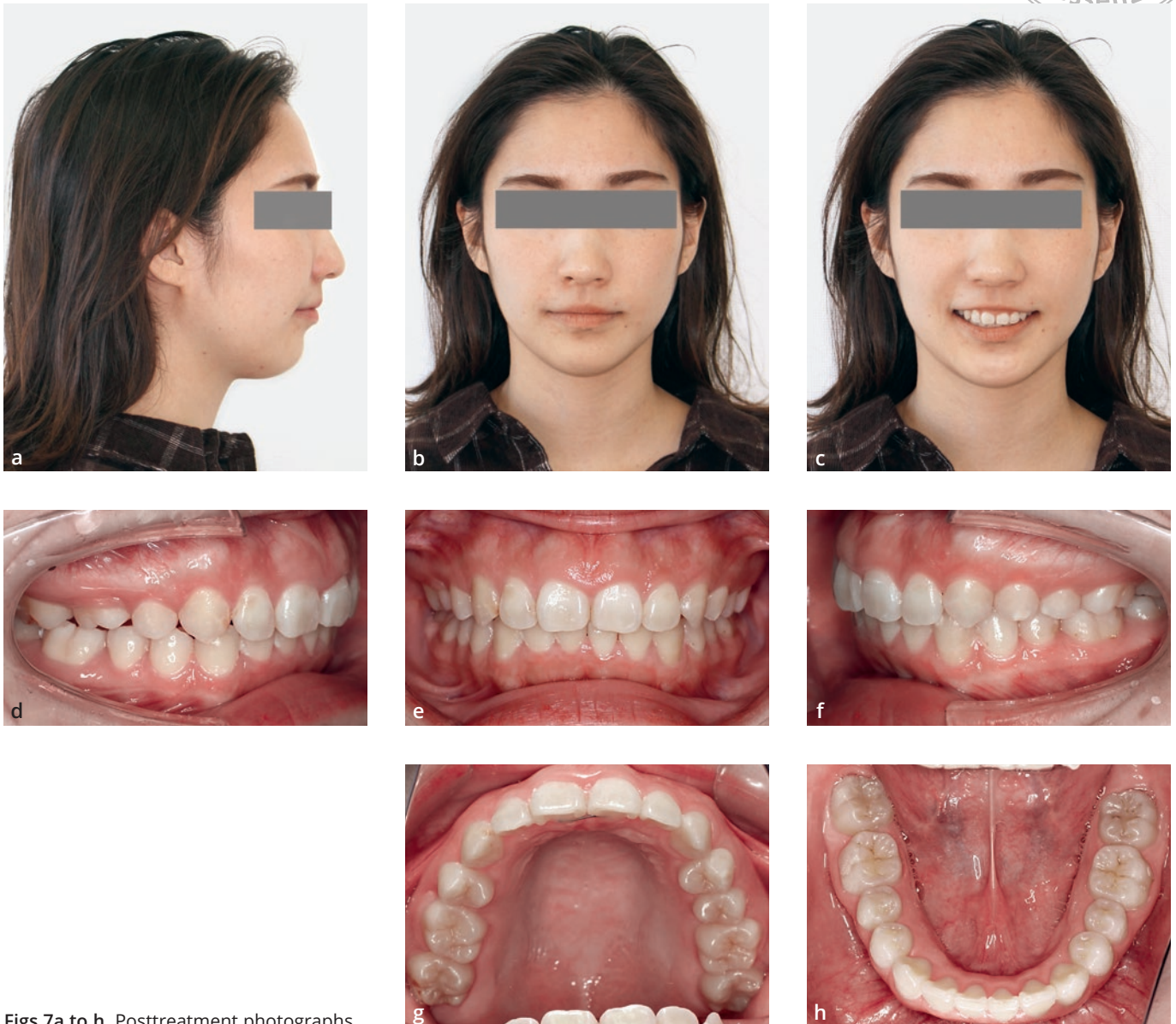### Treatment progress

In the first stage, the deep bite was proactively improved (Fig 4). One miniscrew (diameter, 1.3 mm; length, 6.5 mm)

was placed on either side, and intrusion of the maxillary anterior teeth was commenced by means of elastics (1/8", 4.0-oz force)<sup>10</sup>. Monitoring was performed at each examination to ensure that no pulpitis had occurred in the maxillary anterior teeth as a result of the intrusion. With the anterior mandibular teeth, flaring was induced at the same time as improvement of the mandibular crowding. Class III elastic was used for 4 months, until the maxillary right second molar was upright.

In the second stage, the amount of intrusion of the anterior maxillary teeth was checked and absence of root resorption was confirmed on the cephalogram, and a treatment plan was again drawn up for intrusion of the anterior maxillary teeth<sup>11</sup>. Class II elastics were also used on both sides to reduce the horizontal overlap (Fig 5).

In the third stage, a decision was made to maintain the positions of the maxillary anterior teeth, as no further intru-



Figs 7a to h Posttreatment photographs.

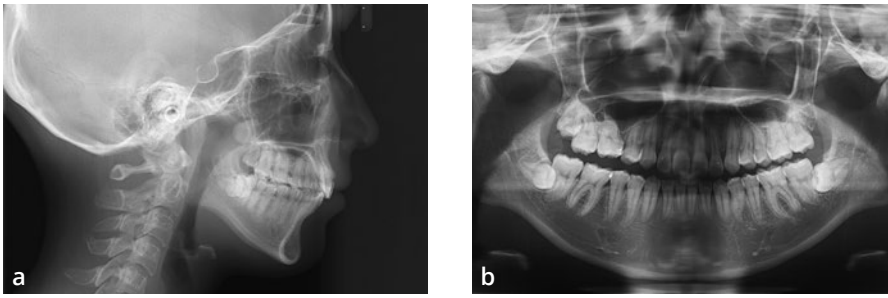
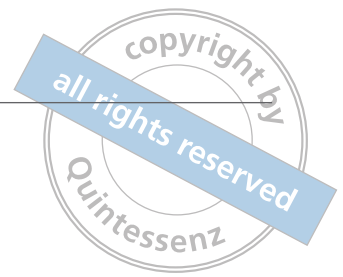sion of the maxillary anterior teeth was evident from the previous plan. Cross elastics were used, as insufficient improvement was seen in the scissor bite on the right side (Fig 6). Following treatment, a bonded retainer was fitted between the maxillary central incisor and mandibular canine. A bite plate-type retainer was used for the maxilla<sup>12</sup>.

#### Treatment overlap

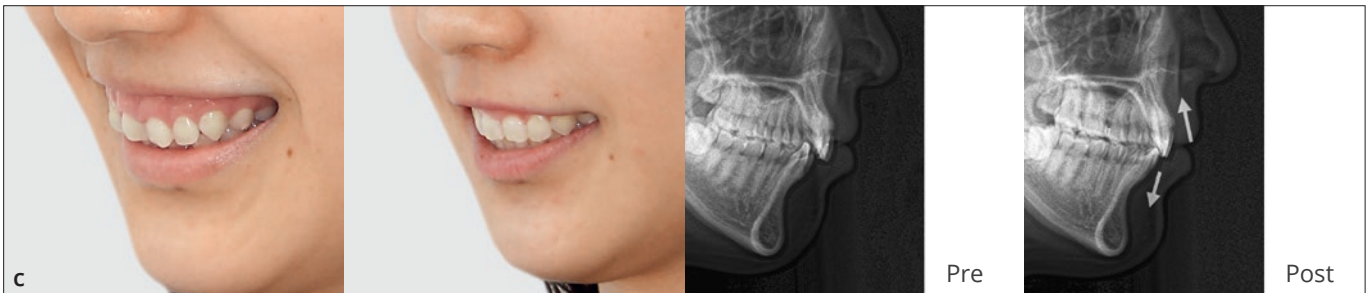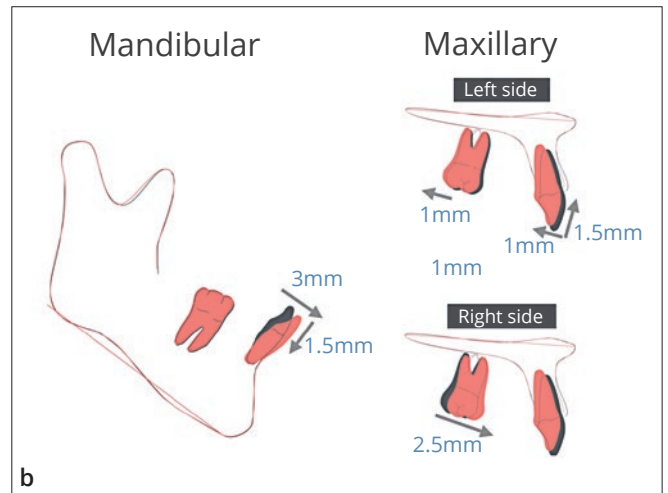
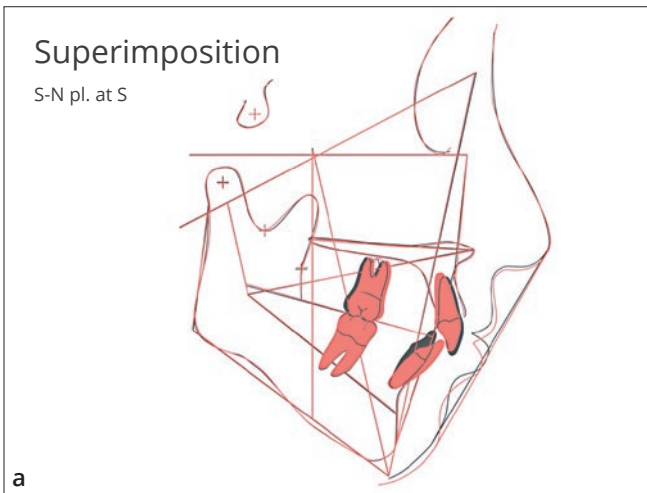
A total of 69 (21 + 23 + 25) aligner stages were used. The patient showed good compliance with aligner use time, and

the treatment period was 18 months (Fig 7). Crowding was improved and the amount of gingiva exposed during smiling was reduced, and the patient was fully satisfied with the aesthetic appearance. No evidence of root resorption of the anterior maxillary teeth was noticeable on the panoramic radiographs (Fig 8). Cephalometric superposition confirmed 1.5 mm vertical intrusion and 1.0 mm retraction of the maxillary anterior teeth, and 1.5 mm intrusion and 3.0 mm flaring of the mandibular anterior teeth. For the maxillary first molar, 2.5 mm of mesial movement was ob-





**Figs 8a and b** Posttreatment radiographic examination.



**Figs 9a to c** Cephalometric superimposition (pretreatment in grey, posttreatment in red) and smile line change.

served on the right side and 1.0 mm of distal movement on the left side. In closure of the maxillary right second premolar extraction space, movement of the tooth body was planned, but slight tipping became evident. The inclination of the maxillary anterior teeth was improved by 3 degrees on U1-SN, and appropriate horizontal and vertical overlap were obtained (Fig 9). The molar relationship showed satisfactory occlusion of full Class II on the right side and Class I on the left. The E-line to lip balance of the upper and lower lips was improved.

## Discussion

In cases of clear aligner orthodontic treatment where intrusion of the maxillary anterior teeth is necessary, the degree of difficulty varies according to whether relative intrusion is possible. The most straightforward cases are those in which the anterior teeth are made to intrude, while anterior teeth with palatal inclination are tipped in a labial direction<sup>13</sup>. Following these are cases in which anterior teeth with labial inclination are tipped in a palatal direction. The most diffi-

Table 1 Cephalometric measurements

Measurement		Norm	Initial	Final	Change
Skeletal	SNA (degrees)	82.0	73.0	73.0	0.0
	SNB (degrees)	80.0	65.5	65.5	0.0
	ANB (degrees)	2.0	7.5	7.5	0.0
	MP-FH (degrees)	28.2	37.0	37.0	0.0
Dental	U1-SN (degrees)	104.0	85.0	88.0	3.0
	U1-APo (mm)	6.2	7.5	6.5	-1.0
	L1-MP (degrees)	90.0	90.0	103.0	13.0
	L1-APo (mm)	3.0	0.0	3.0	3.0
	Horizontal overlap (mm)	2.5	6.5	2.5	-4.0
	Vertical overlap (mm)	2.5	5.5	2.5	-3.0
Soft tissue	E-line to upper lip (mm)	1.0	-3.5	-2.5	1.0
	E-line to lower lip (mm)	2.0	0.5	-1.0	-1.5

cult cases are those in which palatally inclined anterior teeth are made to intrude while applying retraction (Fig 10). This is because vertical intrusion carried out with aligners alone results in the application of a strong moment to the molars, as the anchorage, and can cause mesial tipping of the molars. Using TADs as anchorage is advisable to avoid this undesirable reaction. In the present case, the amount of vertical intrusion of the maxillary anterior teeth was 1.5 mm. The amount of true intrusion of maxillary anterior teeth with deep bite has been reported as up to around 1.5 mm<sup>14</sup>, and sufficient intrusion was thus considered to have been obtained in the present case. Due to the camouflage treatment of skeletal Class II, the improvement of inclination of the maxillary anterior teeth was small.

For the placement of the miniscrew used to achieve intrusion of the maxillary anterior teeth, insertion in the attached gingiva between the lateral incisor and canine on the right and left sides is recommended (Fig 11). One advantage of such placement is that it is easy to ascertain the anatomical position of the anterior tooth roots under observation with the naked eye, so that there is little risk of the screw erroneously coming too close to the tooth roots, even without preparing a surgical guide<sup>15</sup>. A second advantage is that few problems are encountered with inflammation of soft tissues, such as the oral mucosa or frenulum of the

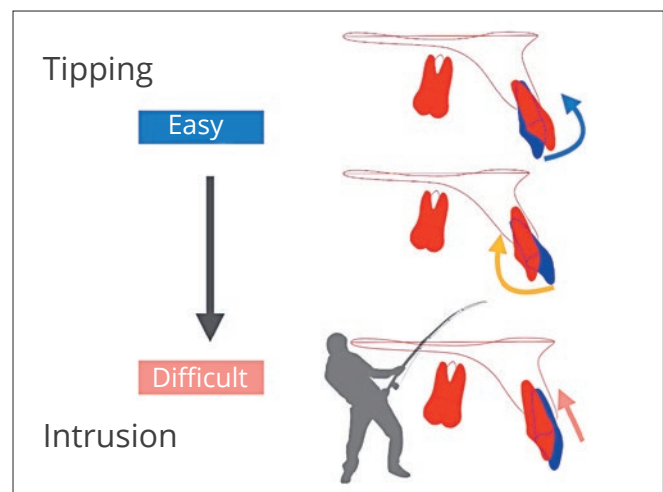
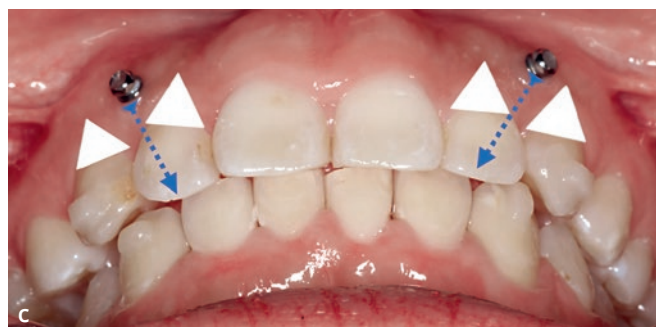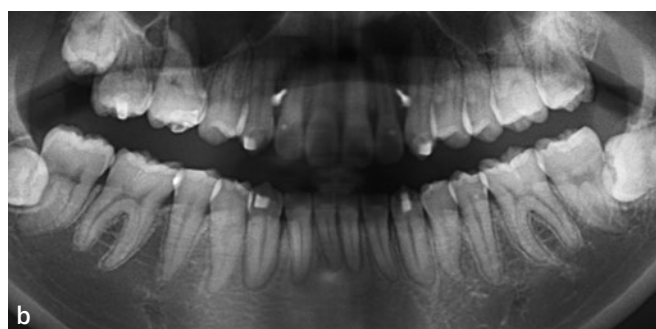
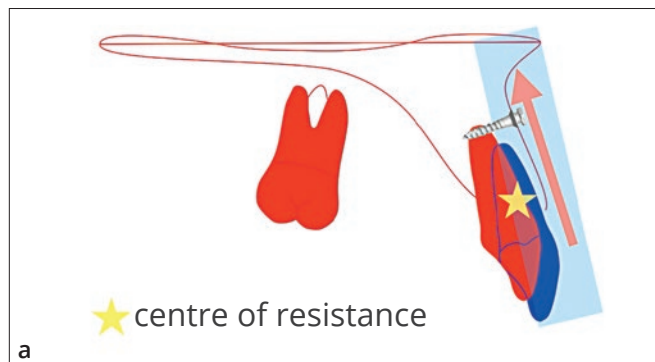


Fig 10 Difficulty of deep bite correction.

upper lip<sup>16</sup>. From a biochemical perspective, the positions of the heads of the miniscrews on which the elastics are hooked are aligned with the centre of resistance of the maxillary anterior tooth roots in the sagittal plane<sup>17</sup>, and such a position can therefore be considered effective for vertical intrusion. In the present case, the force system with elastics pulling from both sides provided retraction while intruding the maxillary anterior tooth towards the tooth



**Figs 11a to c** Advantage of placing TADs on maxillary anterior alveolar gingiva.

axis, ensuring the screw was never in the vicinity of the tooth root during movement. These mechanics provide a continuous force system, and the treatment period can be considerably shortened to 18 months.

## Conclusion

Vertical intrusion of maxillary anterior teeth carried out with aligners alone is difficult. TADs placed in the maxillary alveolar gingiva combined with aligner treatment were effective for controlling vertical intrusion of the maxillary anterior teeth in an adult case of Class II, division 2 with extraction.

## Declaration

The author declares there are no conflicts of interest.

## References

1. Dym H, Pierre R 2nd. Diagnosis and treatment approaches to a “gummy smile”. *Dent Clin North Am* 2020;64:341–349.
2. Karthickeyan SS. Dentoskeletal morphology in Class I and Class II malocclusion with increased overbite. *Am J Orthod Dentofacial Orthop* 2019;156:710–711.
3. Ke Y, Zhu Y, Zhu M. A comparison of treatment effectiveness between clear aligner and fixed appliance therapies. *BMC Oral Health* 2019;19:24.
4. Ma H, Feng Y, Pu P, Ren Y, Gu Z. Angelalign treatment of an adult with excessive overjet and a missing mandibular premolar: A case report. *J Aligner Orthod* 2019;3:93–105.
5. Shu R, Huang L, Bai D. Adult Class II division 1 patient with severe gummy smile treated with temporary anchorage devices. *Am J Orthod Dentofacial Orthop* 2011;140:97–105.
6. Saga AY, Araújo EA, Antelo OM, Meira TM, Tanaka OM. Nonsurgical treatment of skeletal maxillary protrusion with gummy smile using headgear for growth control, mini-implants as anchorage for maxillary incisor intrusion, and premolar extractions for incisor retraction. *Am J Orthod Dentofacial Orthop* 2020;157:245–258.
7. Wang XD, Zhang JN, Liu DW, et al. Nonsurgical correction using mini-screw-assisted vertical control of a severe high angle with mandibular retrusion and gummy smile in an adult. *Am J Orthod Dentofacial Orthop* 2017;151:978–988.
8. Pithon MM. Nonsurgical treatment of severe Class II malocclusion with anterior open bite using mini-implants and maxillary lateral incisor and mandibular first molar extractions. *Am J Orthod Dentofacial Orthop* 2017;151:964–977.
9. Kim TW, Kim H, Lee SJ. Correction of deep overbite and gummy smile by using a mini-implant with a segmented wire in a growing Class II division 2 patient. *Am J Orthod Dentofacial Orthop* 2006;130:676–685.
10. Chang S, Schupp W, Haubrich J, Yeh WC, Tsai MS, Tabancis M. Aligner therapy in treating bimaxillary dentoalveolar protrusion. *J Aligner Orthod* 2019;3:277–301.
11. Costopoulos G, Nanda R. An evaluation of root resorption incident to orthodontic intrusion. *Am J Orthod Dentofacial Orthop* 1996;109:543–548.
12. Danz JC, Greuter C, Sifakakis I, Fayed M, Pandis N, Katsaros C. Stability and relapse after orthodontic treatment of deep bite cases—a long-term follow-up study. *Eur J Orthod* 2014;36:522–530.
13. Werneck EC, Mattos FS, Cotrim-Ferreira FA, Prado RF, Silva MG, Araújo AM. Upper incisors’ positions after extraction. *Int J Orthod Milwaukee* 2014;25:41–45.
14. Ng J, Major PW, Heo G, Flores-Mir C. True incisor intrusion attained during orthodontic treatment: a systematic review and meta-analysis. *Am J Orthod Dentofacial Orthop* 2005;12:212–219.
15. Gurdan Z, Szalma J. Evaluation of the success and complication rates of self-drilling orthodontic mini-implants. *Niger J Clin Pract* 2018;21:546–552.
16. Shigeeda T. Root proximity and stability of orthodontic anchor screws. *J Oral Sci* 2014;56:59–65.
17. Geramy A, Sodagar A, Hassanpour M. Three-dimensional analysis using finite element method of anterior teeth inclination and center of resistance location. *Chin J Dent Res* 2014;17:37–42.