



Deep Plane Cervicofacial Flap for Reconstruction of Large Oncosurgical Defects of the Cutaneous Face and Neck

Wei Liang CHEN¹, Zhi Quan HUANG¹, Zhao Hui YANG¹, Ke WANG¹, Da Ming ZHANG¹

Objective: To evaluate the reliability of the deep plane cervicofacial flap to repair large defects of the cutaneous face and neck.

Methods: Nine patients with malignant tumours were treated with extensive resection. The large defects of the cutaneous face and neck were repaired using deep plane cervicofacial flaps based on the superficial musculoaponeurotic system. The subjects were seven male and two female patients, ranging in age from 56 to 74 years (mean 68.2). The size of the defects ranged from 4 × 3 to 10 × 8 cm (mean 6.1 × 5.9 cm).

Results: Apart from mild facial contour deficiency following minor flap necrosis in one patient, excellent functional and cosmetic outcomes were achieved with good skin colour and texture matching in all patients. The follow-up periods ranged from 6 to 18 months (mean 10.7) and all of the patients were still alive without recurrence.

Conclusion: The deep plane cervicofacial flap is reliable with excellent vascularity. Moreover, it is easy to harvest, compatible with the principles of oncologic resection and the method of choice for repairing major defects of the cutaneous face and neck following tumour resection.

Key words: cervicofacial flap, face and neck defects, reconstruction, rotation flap, superficial musculoaponeurotic system (SMAS)

Face and neck defects are a reconstructive challenge – technically, functionally and cosmetically. Defects on the cheek surface of 30% or less can be repaired adequately by direct closure or by local flaps, which provide better aesthetic results than free-skin grafts¹. The surgical treatment of malignant tumours of the face and neck often involves extensive surgery, and more complex surgical techniques are required in large oncosurgical defects of the face and neck. The deep plane cervicofacial flap (DPCFF) is based on the superficial musculoaponeurotic system (SMAS). The cervical rotation flap is an excellent alternative to other pedicled or microsurgical free flaps². The blood supply and reliability of cervicofacial rotation-advancement flaps for cheek reconstruction is improved greatly by dissecting the flap

in the deep plane³. Inferiorly based cervicofacial advancement-rotation flaps are the workhorse for large cheek and lower eyelid defects⁴. Tan and MacKinnon reported that the DPCFF provides a simple solution for a variety of cheek defects and an excellent alternative to regional or free tissue transfer⁵. The present study describes the authors' experience with the DPCFF to repair primary large cutaneous defects of the face and neck after tumour resection.

Materials and Methods

Nine patients with malignant tumours (five basal cell carcinomas and four squamous cell carcinomas) in the face and neck were treated at the Department of Oral and Maxillofacial Surgery, the Second Affiliated Hospital of Sun Yat-sen University, during June 2004 and July 2006. There were seven male and two female patients, ranging in age from 56 to 74 years (mean 68.2). All patients underwent extensive resection of their lesions, and four patients underwent ipsilateral radical neck dissection. The defects were located in the suborbital (n = 4), pre-

1 Department of Oral and Maxillofacial Surgery, the Second Affiliated Hospital of Sun Yat-sen University, Guangzhou, P.R. China.

Corresponding author: Dr Wei Liang CHEN, Department of Oral and Maxillofacial Surgery, the Second Affiliated Hospital of Sun Yat-sen University, 107 Yan-jiang Road, Guangzhou 510120, P.R. China. Tel: 86-20-81332429; Fax: 86-20-81332853; Email: drchen@vip.163.com

auricular (n = 2) and buccomandibular (n = 3) regions. The size of the defects ranged from 4 × 4 to 10 × 8 cm (mean 6.1 × 5.9 cm). The defects were reconstructed using a DPCFF based on the SMAS. The flap donor area was closed directly. Three patients received adjuvant treatment (Table 1).

Surgical technique

To reconstruct suborbital defects, the DPCFF was designed with a high lateral arch over the temple so that it could be suspended above the lateral canthus (Fig 1a and 1b). Following resection of the suborbital tumour, the excision defect was extended to include the lower eyelid (Fig 1c). The incision for the flap was begun over the first operable region and continued preauricularly onto the mastoid process (Fig 1d). Initially, the pre-auricular dissection was carried out in the subcutaneous plane anteriorly for 1 cm, from where the dissection was deepened to the plane just deep to the SMAS. The flap was raised in the sub-SMAS plane toward the skin defect in a manner similar to a deep plane facelift; the flap was sutured at its deep aspect to the periosteum of the lateral orbital rim to prevent ectropion of the lower eyelid (Figs 1e and 1f).

To reconstruct preauricular defects or buccomandibular defects, the DPCFF was designed by incorporating the neck dissection incision as required (Fig 2a). Similarly, the plane of dissection of the flap was beneath the platysma muscle and superficial layer of the deep cervical fascia, and this plane developed cephaladly until it was contiguous with the lower limit of the cheek defect. The skin and platysma were used beginning over the operable region and continued preauricularly onto the mastoid process. The incision was then continued along

the anterior edge of the trapezius muscle, the lateral third of the clavicle and extended into the pectoral region up to the third or fourth intercostal space. The anterior border of the DPCFF was separated from the strap muscles and raised anteriorly. A radical neck dissection was performed if cervical metastasis was present. The dissection was combined superficial to the SMAS in the face and combined in the subplatysmal plane in the cervical region (Fig 2b). The flap created was then rotated to the defect (Figs 2c and 2d).

Results

Apart from a mild facial contour deficiency following minor flap necrosis in one patient, excellent functional and cosmetic outcomes with good skin colour and texture matches were achieved in all patients, without ectropion and retraction of the lower eyelid. The follow-up period ranged from 6 to 18 months (mean 10.7) and all of the patients were without recurrence up to that time. All flaps were transferred successfully, and the facial aesthetics were satisfactory in all patients. One minor flap failure occurred in the region closest to the pedicle of the DPCFF (case 5). The complications were treated with local conservative methods; the wounds underwent delayed healing. The origin and histological type of the tumours, and treatment for each patient are detailed in Table 1.

Discussion

The SMAS is a superficial investing layer in the head and neck area, and was first described by Mitz and Peyronie⁶. It is a distinct musculo-aponeurotic layer that lies deep to the subcutaneous fatty tissue of the face, superficial to the

Table 1 Demographic, clinical and outcome characteristics of the treatment for each patient

Case/age/sex	Location/diagnosis	Skin defect (cm)	Radical neck dissection	Flap complications	Adjuvant treatment	Follow-up (months)
1/65/M	SB/BCC	4 × 4	No	No	No	12
2/72/M*	BM/SCC	10 × 8	Yes	No	RT	8
3/75/M	SB/BCC	4 × 4	No	No	No	6
4/66/M	BM/SCC	7 × 6	Yes	No	RT	12
5/72/M*	BM/SCC	10 × 8	Yes	Minor flap necrosis	CT	8
6/74/M	SB/BCC	4 × 4	No	No	No	10
7/66/F	PA/SCC	6 × 5	No	No	No	18
8/68/F	SB/BCC	4 × 4	No	No	No	7
9/56/M	PA/BCC	6 × 6	Yes	No	No	15

BCC, basal cell carcinoma; BM, buccomandibular; CT, chemotherapy; F, female; M, male; PA, preauricular; RT, radiotherapy; SB, suborbital; SCC, squamous cell carcinoma; *history of radiation

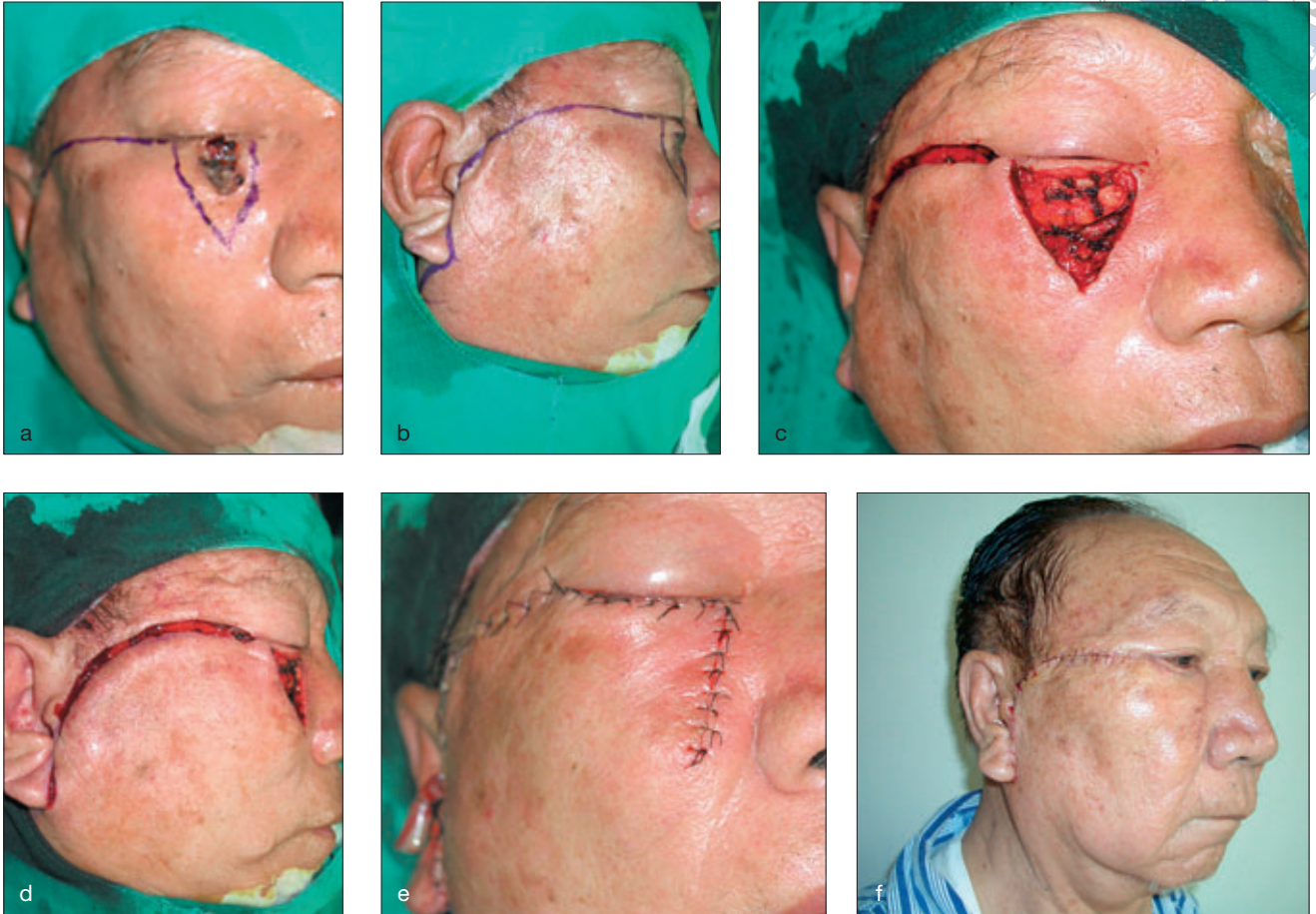

Fig 1 Case 1: (a and b) Planned tumour resection and deep plane cervicofacial flap (DPCFF). (c) The suborbital defect measured 4 × 4 cm following tumour resection. (d) The DPCFF was reflected. (e) The flap was sutured. (f) Lateral view 10 days post-operatively.

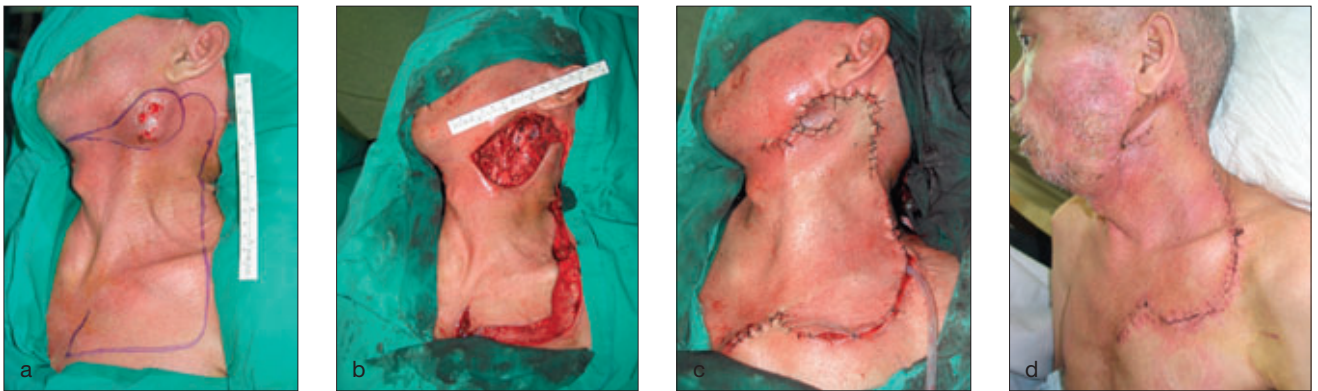


Fig 2 Case 2: (a) Outline of the planned tumour resection and DPCFF. (b) The flap was raised in the sub-superficial musculo-aponeurotic system, and the buccomandibular defect measured 10 × 8 cm following tumour resection and radical neck dissection. (c) The flap was rotated to the defect in the cheek. (d) Lateral view 10 days post-operatively.

parotid fascia and is in continuity with the platysma muscle⁷. The muscles of facial expression are considered part of the SMAS layer, with a branch of the facial nerve supplying these muscles lying deep in the SMAS.

In the present study, nine patients underwent a DPCFF based on the SMAS to reconstruct defects of the face and neck. The DPCFF can cover a 10 × 8 cm defect of the skin. All patients achieved an acceptable appearance.

Minor flap necrosis occurred in one of the two patients who received definitive radiotherapy prior to surgery and repair with a DPCFF. The radiation likely affected the flap. Nevertheless, partial necrosis of the DPCFF can cause facial deformity. The DPCFF is an anatomical and functional unit that has several aesthetic advantages, including good skin texture, colour and flexibility matching the remaining facial skin⁸.

The DPCFF based on the SMAS has several advantages. It is a versatile reconstruction technique in head and neck surgery and provides a simple solution for a variety of cheek defects as an excellent alternative to regional or free-tissue transfer. In addition, it can be used when simultaneous parotidectomy, neck dissection or facial reanimation procedures are required. This composite musculo-fascio-cutaneous unit is reliable with excellent vascularity because it has an axial blood supply. Division of the facial suspensory ligaments during elevation of the flap in the sub-SMAS plane increases the mobility of this flap, which facilitates transfer⁵. It is more mobile, more reliable, thicker and more adaptable. It can be used in complex cheek defects that involve the periosteum, or even in full-thickness defects. The quality of the results obtained using this flap represents a considerable advance in facial reconstruction⁹. Chen et al¹⁰ found that the temporal myofacial and facial-cervico-pectoral flaps (used to provide both inner and outer linings for large full-thickness cheek defects following ablative oral cancer surgery) were technically easy and reliable, and considered the technique to be a useful method for reconstructing large full-thickness cheek defects.

References

1. Wallis A, Donald P. Lateral face reconstruction with the medial-based cervicopectoral flap. *Arch Otolaryngol Head Neck Surg* 1988;114:729-733.
2. Cook TA, Israel JM, Wang TD, Murakami CS, Brownrigg PJ. Cervical rotation flaps for midface resurfacing. *Arch Otolaryngol Head Neck Surg* 1991;117:77-82.
3. Kroll SS, Reece GP, Robb G, Black J. Deep-plane cervicofacial rotation-advancement flap for reconstruction of large cheek defects. *Plast Reconstr Surg* 1994;94:88-93.
4. Becker FF, Langford FP. Deep-plane cervicofacial flap for reconstruction of large cheek defects. *Arch Otolaryngol Head Neck Surg* 1996;122:997-999.
5. Tan ST, MacKinnon CA. Deep plane cervicofacial flap: a useful and versatile technique in head and neck surgery. *Head Neck* 2006;28:46-55.
6. Mitz V, Peyronie M. The superficial musculo-aponeurotic system (SMAS) in the parotid and cheek area. *Plast Reconstr Surg* 1976;58:80-88.
7. Gosain AK, Yousif NJ, Madiedo G, Larson DL, Matloub HS, Sanger JR. Surgical anatomy of the SMAS: a reinvestigation. *Plast Reconstr Surg* 1993;92:1254-1263.
8. Soler-Presas F, Cuesta-Gil M, Borja-Morant A, Concejo-Cútoli C, Acero-Sanz J, Navarro-Vila C. Midface soft tissue reconstruction with the facio-cervico-pectoral flap. *J Craniomaxillofac Surg* 1997;25:39-45.
9. Delay E, Lucas R, Jorquera F, Payement G, Foyatier JL. Composite cervicofacial flap for reconstruction of complex cheek defects. *Ann Plast Surg* 1999;43:347-353.
10. Chen W, Zeng S, Li J, Yang Z, Huang Z, Wang Y. Reconstruction of full-thickness cheek defects with combined temporalis myofacial and facial-cervico-pectoral flaps. *Oral Surg Oral Med Oral Pathol Oral Radiol Endod* 2007;103:e10-15.

