

Ankylosis of Temporomandibular Joint Caused by Psoriatic Arthritis: A Report of Four Cases with Literature Review

Zhi Hui WANG¹, Yan Ping ZHAO¹, Xu Chen MA¹

Psoriatic arthritis (PsA) is an inflammatory joint disease associated with psoriasis. PsA is often confused with other diseases such as osteoarthritis and rheumatoid arthritis. PsA involving temporomandibular joints (TMJs) are uncommon: only 19 articles with 43 cases have been documented in the literature. TMJ ankylosis caused by PsA is rare, with only six cases having been reported. The authors present four cases of ankylosis of the TMJ secondary to PsA and review the literature. The findings of this study suggest that more attention should be paid to psoriasis patients with TMJ symptoms and proper treatment should be taken to prevent irreversible TMJ damage.

Key words: psoriatic arthritis, temporomandibular joint, ankylosis, radiographic

Psoriasis is a common, inflammatory, relapsing skin disease, which may involve any of the body's joints with multifactorial etiopathogenesis, including genetic and environmental factors¹. The phenotype of psoriasis can be subdivided into plaque, inverse, erythrodermic, pustular, guttate, and psoriatic arthritis (PsA). PsA is an inflammatory seronegative arthritis associated with psoriasis, which is usually diagnosed years after the occurrence of psoriatic skin disease². It is reported that psoriasis affects approximately 2% of the population, and that 6 to 42% of the patients with psoriasis will develop PsA^{1,2}. It is believed that the incidence of PsA has increased in the last three decades, possibly because of the growing awareness of the diagnosis of PsA by physicians.

PsA can occur in persons of almost any age, but mostly between ages 30 and 50 without gender predilection. PsA most often affects the smaller joints, including the hands and feet, followed by hips, knees,

ankles, and wrists³. The common symptoms of PsA are stiffness, pain, swelling, as well as tenderness of the joints, surrounding ligaments and tendons². Generally, PsA is considered a benign arthropathy compared with rheumatoid arthritis (RA). But without proper treatment, the persistent inflammation in and around the joint may cause severe physical limitations and disability².

Although the association between psoriasis and arthritis has drawn attention since the early 19th century in French literature⁴, it is not until 1965 that the first case of PsA involving temporomandibular joint (TMJ) was reported⁵. Since then, only 19 articles with 43 cases of PsA affecting TMJs have been documented in the literature, most of which were reported 20 years ago⁴⁻²². Cases of TMJ ankylosis related to PsA are rarely documented, with only six previously reported cases (five bony ankylosis^{9,11,15,17} and one fibrous ankylosis⁸). In this study, the authors report four cases of patients with PsA demonstrating bilateral TMJ ankylosis and review the literature.

¹ Department of Oral Radiology and Center for TMD and Orofacial Pain, Peking University School and Hospital of Stomatology, Beijing, P.R. China

Corresponding author: Dr Yan Ping ZHAO, Department of Oral Radiology and Center for TMD, Peking University School and Hospital of Stomatology, #22 Zhongguancun Nandajie, Haidian District, Beijing 100081, P.R. China. Tel: 86-10-82195323; Fax: 86-10-62136628; E-mail: kqzha@bjmu.edu.cn

Case reports

Case 1

A 28-year-old man was referred to the authors' hospital and complained of right TMJ pain and limitation of mouth opening for a year. He had a history of psoriasis

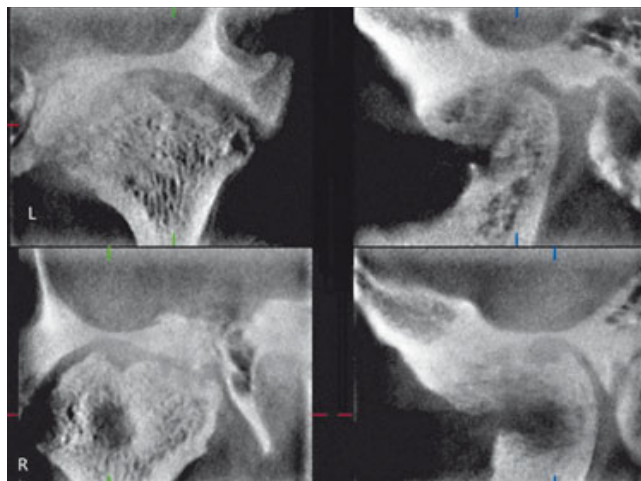
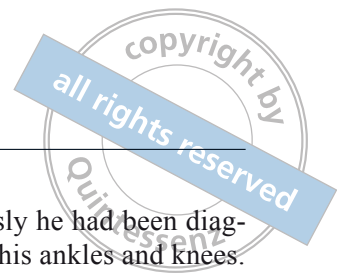

Fig 1 CBCT images of bilateral TMJ showing anterior-media joint space narrowing, aggressive erosion, and irregular proliferation of bilateral condyles and fossa.

for 10 years and 5 years previously he had been diagnosed with PsA, which involved his ankles and knees. After the patient underwent systemic therapies such as acitretin phototherapy, tropical therapy, and traditional Chinese herbal remedies, his skin lesions had been controlled and pain in the joints relieved. His TMJ pain was associated with other joint symptoms without any treatment. During the past year, he has suffered from persistent right TMJ pain with gradually reduced mouth opening. The patient denied other systematic diseases.

Physical examination showed limited mouth opening with the maximal interincisal distance of 12 mm without deviation. He had restricted lateral and protrusive mandible movement, as well as pain in the right TMJ region during palpation. Clinical examination also showed erythematous desquamative lesions on the patient's neck, trunk, and upper arms. There was no swelling of knees or ankles.

Panoramic radiographs showed that the contour of the bilateral mandibular condyles was blurred. Cone beam computed tomography (CBCT) images (3DX Multi Image Micro CT) revealed extensive destruction and proliferation of the bilateral condyle (Fig 1). A radiograph of the knees revealed proliferation and sharpened lateral parts of the intercondyle eminence, which might result from degenerative change. The radiographs of the ankles did not reveal any abnormality. The patient was diagnosed with ankylosis of the TMJs involved in PsA.

Case 2

A 47-year-old man complained of limited mouth opening for approximately 3 years with aggravation in the past 6 months. He had a history of psoriasis for over 28 years along with mild pain and stiffness of knees for 4 years without joint swelling. After being treated with traditional Chinese herbal remedies and glucocorticoids, his skin lesions and joints pain were mitigated, but then relapsed when he stopped taking the medication. He denied other medical history.

His mouth opening was reduced to 1 mm without tenderness on palpation in the TMJ and masticatory muscles. He had a pruritic rash predominately on his forehead, neck, trunk, arms and legs, mostly covered with white scales. Pitting, discoloration, subungual hyperkeratosis and onycholysis were observed on his fingernails and toenails. He had no swelling on his knees or hands. Laboratory tests showed that his full blood count was normal, the erythrocyte sedimentation rate (ESR) was 23 mm/h (normal range given is 0–15),

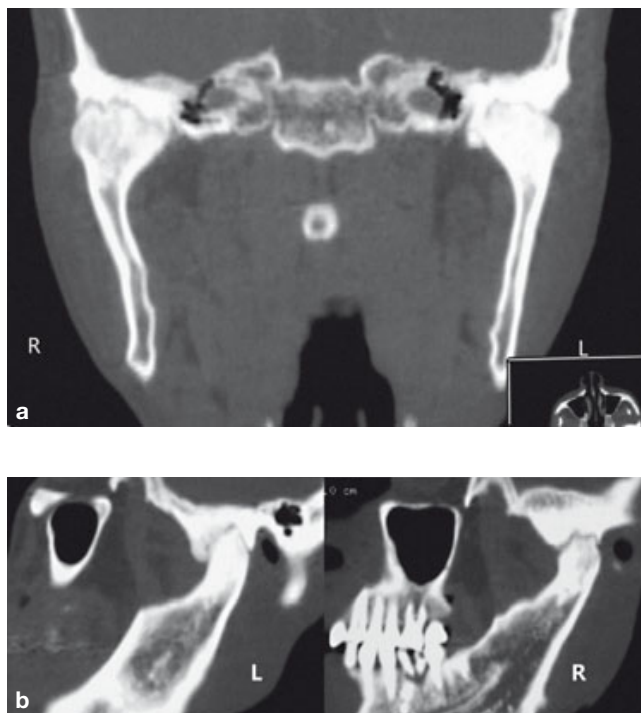


Fig 2 Coronal image (a) and sagittal image (b) of CT scan showing bilateral joint space narrowing, sclerosing and irregular proliferation of the condyle and fossa.

and the rheumatoid factor (RF) was 43.44 IU/ml (reference range < 30 IU/ml). Radiographs of his hands and knees were normal. A CT scan of the TMJ displayed bilateral condyle ankylosis (Fig 2). He was diagnosed with TMJ ankylosis secondary to PsA.

Case 3

A 44-year-old man complained of the inability to open his mouth for 6 months. He had a history of psoriasis of skin and nails for 24 years as well as polyarthritis of hips, shoulders, lumbar, and cervical spine for 5 years. His joint pain was aggravated by motion with decreased range of cervical motion. He responded poorly to the treatment with traditional Chinese medicine and glucocorticoids. Also he could not open his mouth fully when receiving dental treatment a year previously. He did not have any history of TMJ pain.

His mouth opening was limited to 15 mm with restricted lateral and protrusive movement of the mandible. His forced mouth opening increased to 18mm and the mandible deviated to the left at opening. He had a rigid cervical spine with the head in a slightly flexed position. Skin rashes presented over his body and the affected fingernails were pitted and discolored. Laboratory data showed negative for IgG-rheumatoid factor, human leukocyte antigen B27, and anti-cyclic citrullinated peptide antibody, but the level of immunoglobulin A, C-reactive protein, and antistreptolysin O were higher than the normal range.

A CT scan of the TMJ revealed a narrowing of the joint space due to proliferation of the bilateral condyle (Fig 3). Radiographs of the cervical spine showed degenerative changes, including osteophytes on the posterior borders of the vertebrae with nuchal ligament calcification. These findings suggested a diagnosis of TMJ fibrous ankylosis caused by psoriatic arthritis.

Case 4

A 45-year-old woman asked for treatment of limited mouth opening that had persisted for 3 years. She denied pain in the TMJ region. She has had skin lesions caused by psoriasis for the past 21 years. She did not receive regular treatment of psoriasis, so her skin lesions were not controlled.

Her mouth opening was restricted to 2 mm without condylar translation. She had extensive skin and nail psoriasis lesions. A CT scan of the TMJ demonstrated a proliferative change on the bilateral condyles (Fig 4). A radiograph of the hands was normal. The patient was diagnosed with TMJ ankylosis associated with PsA.

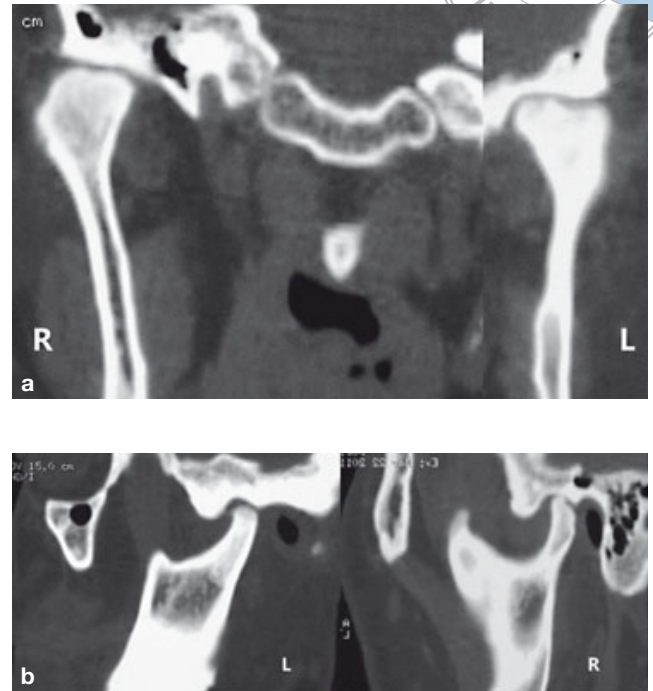


Fig 3 Coronal image (a) and sagittal image (b) of CT scan demonstrating bilateral joint space narrowing, erosion of left condyle and sclerosis and proliferation of bilateral condyles.

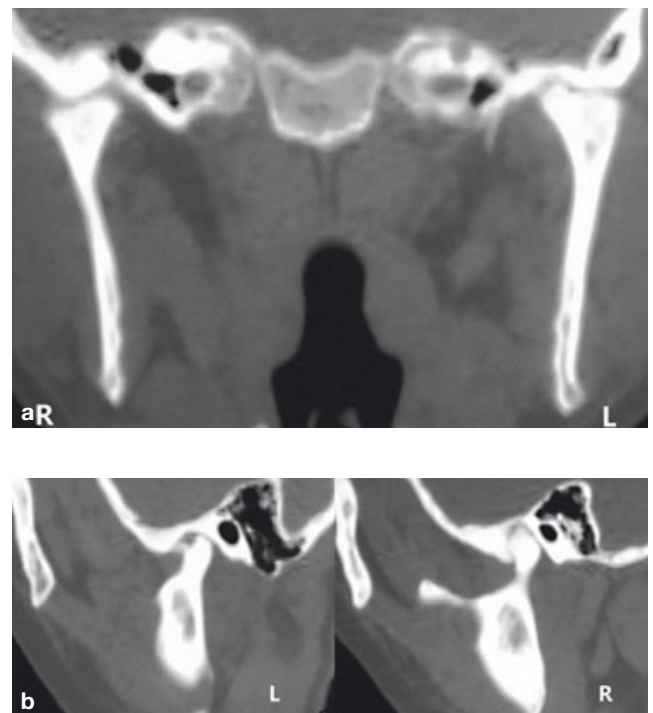

Fig 4 Coronal image (a) and sagittal image (b) of CT scan revealing bilateral joint space narrowing, irregular surface of the condyle, sclerosing and bony adhesion of the condyle with articular eminence and fossa.

Table 1 Epidemiological and clinical data of collected cases of psoriatic arthritis involving TMJ

Author	Age (yr)	Sex	Limited mouth opening*	TMJ pain	Tenderness on TMJ	TMJ involvement
Franks ⁵	40	F	1	1	1	Unilateral
Lundberg and Ercison ⁶	17–64	F3, M8	2	NS	NS	NS
Lowry ⁴	37	M	1	1	1	Unilateral
Blair ⁷	28–66	F4, M3	1	3*	4*	NS
Rasmussen and Bakke ⁸	36	M	1	1	1	Unilateral
	33	M	-	1	2	Unilateral
	24	F	1	1	1	Unilateral
	52	F	1	1	1	Unilateral
Stimson and Leban ⁹	28	M	1	2	2	Bilateral
Wood and Stankler ¹⁰	31	M	1	1	1	Bilateral
	33	F	1	2	2	Bilateral
Kudryk ¹¹	42	F	1	2	NS	Bilateral
Avrahmi ¹²	58	M	-	1	1	Unilateral
	35	M	NS	1	1	Unilateral
	43	M	-	1	1	Unilateral
Baetz and Kleinberg ¹³	40	F	1	2	1	Bilateral
Wilson ¹⁴	37	F	1	1	1	Bilateral
Koorbusch ¹⁵	34	M	1	2	2	Bilateral
	42	M	1	-	-	Bilateral
Larheim ¹⁶	34	F	NS	1	1	Unilateral
Miles ¹⁷	51	M	1	2	NS	Bilateral
	40	M	NS	2	NS	Bilateral
Ulmansky ¹⁸	66	F	NS	2	NS	Bilateral
Yamamoto ¹⁹	52	F	NS	1	NS	Unilateral
Alstergen ²⁰	62	F	NS	1	2	Unilateral
Lamazza ²¹	29	M	1	2	NS	Bilateral
Farronato ²²	36	F	1	1	1	Unilateral

*: Number of patient; NS: not specified; -: negative.

Discussion

In review of the 43 reported cases of PsA involving TMJ, there is a male predilection (24:19) and the average age of onset is 43.3 (Table 1). TMJ lesions could occur before, during, or after other joints. The most common clinical findings are pain in the TMJ region (27/43), TMJ tender to palpation (22/43), and limited mouth opening (21/43) (Table 1). Unilateral involvement of TMJs in patients with PsA is more common than bilateral involvement (5:3).

These features are in accordance with the findings of Rasmussen and Bakke⁸. Moreover, some clinical studies reported that muscle tenderness on palpation and joint sounds were the most frequent symptoms¹ in TMJ, while restricted mouth opening was not prominent in PsA patients²³. It could be inferred that the symptoms of PsA affecting TMJ are unspecific.

Routine clinical assessments often underestimate the amount of joint damage, both in the patients diagnosed as PsA and in the patients who have psoriasis without

Table 2 Radiographic findings of collected cases of psoriatic arthritis involving TMJ

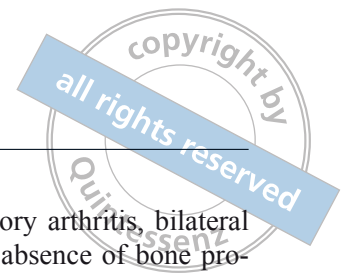
Author	Erosion	Osteophyte	Sclerosis	Cyst formation	Flattening	Joint space narrowing	Ankylosis *
Franks ⁵	1	-	-	-	-	-	-
Lundberg and Ercison ⁶	17	18	-	-	-	-	-
Lowry ⁴	-	1	-	-	-	-	-
Blair ⁷	2	-	-	-	3	-	-
Rasmussen and Bakke ⁸	1	-	-	-	-	-	1
	1	-	-	-	-	-	-
	1	-	-	-	1	-	-
**	-	-	-	-	-	-	-
Stimson and Leban ⁹	-	-	-	-	-	2	1
Wood and Stankler ¹⁰	2	-	-	-	-	-	-
**	-	-	-	-	-	-	-
Kudryk ¹¹	-	-	-	-	-	2	1
Avrahmi ¹²	1	-	-	-	-	-	-
	1	-	-	-	-	-	-
	1	-	-	-	-	-	-
Baetz and Kleinberg ¹³	2	-	-	-	-	-	-
Wilson ¹⁴	2	-	-	-	2	-	-
Koorbusch ¹⁵	2	-	2	-	-	-	1
	2	-	2	-	-	-	1
Larheim ¹⁶	2	-	-	-	-	-	-
Miles ¹⁷	-	-	2	-	-	2	1
	-	2	2	-	-	-	-
Ulmansky ¹⁸	NS	NS	NS	NS	NS	NS	NS
Yamamoto ¹⁹	-	1	-	-	-	-	-
Alstergen ²⁰	2	-	-	1	1	-	-
Lamazza ²¹	2	-	-	-	2	-	-
Farronato ²²	1	-	-	-	-	-	-

*Number of patient; ** These two PsA patients have TMJ symptom without radiological abnormality.

apparent joint involvement²⁴. Therefore, radiographic examination is necessary for all patients suspected of PsA. Conventional radiography is still the most widely used imaging method in diagnosing PsA. Some researchers have recommended CT and magnetic resonance imaging (MRI)¹⁵. CT imaging is unreliable to show soft tissue changes in the early stage of TMJ arthritis before bone destruction, while MRI is a more sensitive tool than radiography in assessing soft tissue and bone involvement in inflammatory arthritis in

PsA²⁴. Among previously reported cases, erosion is the most common radiographic change in PsA patients with TMJ involvements (37/63) (Table 2), which is in accordance with the findings of Lundberg⁶. Other radiographic findings such as bony proliferation (22/63), bone surface flattening (8/63), and sclerosis (6/63), are also typical changes in TMJs of PsA patients.

PsA has been considered a milder rheumatic disease not yielding significant functional damage. In the rheumatic process of PsA patients, new bone formation at



the enthesis may lead to joint infusion and intra-articular bone ankylosis²⁵. Gisoni et al reported that the prevalence of ankylosis in PsA patients was as high as 23.9%, mostly affecting the hands and feet²⁶. However, ankylosis of the TMJ has been seldom reported, with only six cases documented in the literature. Ankylosis is the late stage of PsA, resulting in severe joint dysfunction.

In accordance with the five previously reported TMJ bony ankylosis cases^{9,11,15,17}, the above mentioned four patients showed some distinctive clinical and radiographic characteristics, compared with previous non-ankylosis cases. First, all of the presented cases were bilateral TMJ involvements, whereas unilateral involvement was common in previous non-ankylosis cases. Second, the chief complaint of the patients was limited mouth opening without prominent pain in the TMJ region, while pain along with swelling and limited mouth opening were the common symptoms of previous non-ankylosis cases. Finally, radiographic features of PsA could be grouped into destructive and proliferative changes. Bony proliferative change was the main radiographic feature in the findings of this study, while previous reports indicated that destructive changes were the main radiographic findings in non-ankylosis cases. In addition, the presented four cases also showed some unique features different from previously reported TMJ bony ankylosis cases. First and foremost, the pain of TMJ in the four patients is mild and only the first patient could recall the pain in the TMJ region. In comparison, most TMJ ankylosis cases in the literature had persistent TMJ pain for a long time. Moreover, the symptoms of other joints in the presented cases were mild and there was no evident joint damage due to the PsA process radiographically, while in contrast, among previous cases, the psoriasis arthritic change of other joints could be revealed by radiographs and two patients had a history of other joint surgery due to PsA involvement.

The radiographic features of PsA are unspecific, thus it is difficult to distinguish PsA from other inflammatory arthritic diseases¹⁵ and degenerative diseases¹⁶. Erosion is a typical change found not only in PsA but also in degenerative osteoarthritis and rheumatoid arthritis. However, erosion tends to be central in osteoarthritis while it may be central, marginal, or periarticular in patients with PsA³. Both osteoarthritis and PsA may present marginal osteophytes, but periosteal new bone formation and enthesitis are the hallmarks of PsA instead of osteoarthritis. PsA and RA are distinguished by different joint distributions and the presence or absence of bone proliferation. Specifically, RA is

suggested by diffused inflammatory arthritis, bilateral symmetric involvement, and the absence of bone proliferation. Additionally, bone destruction in RA involvement of TMJ has proved to be rather rapid¹⁶, which is not in consistency with radiological findings of the four reported cases. Radiographs of these cases showed erosion on different areas of condyle and bone proliferation on the periosteal area. As a seronegative inflammatory arthritis, PsA is usually negative for rheumatoid factor. Although rheumatoid factor was detected in case 2, the patient could not be diagnosed with RA because 5% of the normal population could also show positive for rheumatoid factor¹.

The findings of this study suggest that PsA affecting TMJ may develop slowly with mild symptoms. Ankylosis is a severe joint deformity that may occur in the TMJ in the rheumatic process of PsA patients. Because of the low incidence of TMJ involvement in PsA and the nonspecific symptoms and radiographic findings in TMJ of PsA patients, the diagnosis of TMJ involvement is often neglected. More attention should be paid to PsA patients with TMJ symptoms. If PsA involving the TMJ is diagnosed, treatment should be initiated to alleviate symptoms and as far as possible to inhibit structural damage, especially ankylosis.

References

1. Dervis E. The prevalence of temporomandibular disorders in patients with psoriasis with or without psoriatic arthritis. *J Oral Rehabil* 2005;32:786–793.
2. Gottlieb A, Korman NJ, Gordon KB, et al. Guidelines of care for the management of psoriasis and psoriatic arthritis: Section 2. Psoriatic arthritis: overview and guidelines of care for treatment with an emphasis on the biologics. *J Am Acad Dermatol* 2008;58:851–864.
3. Zayas VM, Monu JUV. Imaging of Psoriatic Arthritis. *Contemporary Diagnostic Radiology* 2008;31:1–6.
4. Lowry JC. Psoriatic arthritis involving the temporomandibular joint. *J Oral Surg* 1975;33:206–208.
5. Franks AS. Temporomandibular joint arthrosis associated with psoriasis. Report of a case. *Oral Surg Oral Med Oral Pathol* 1965;19:301–303.
6. Lundberg M, Ericson S. Changes in the temporomandibular joint in psoriasis arthropathica. *Acta Derm Venereol* 1967;47:354–358.
7. Blair GS. Psoriatic arthritis and the temporomandibular joint. *J Dent* 1976;4:123–128.
8. Rasmussen OC, Bakke M. Psoriatic arthritis of the temporomandibular joint. *Oral Surg Oral Med Oral Pathol* 1982;53:351–357.
9. Stimson CW, Leban SG. Recurrent ankylosis of the temporomandibular joint in a patient with chronic psoriasis. *J Oral Maxillofac Surg* 1982;40:678–680.
10. Wood N, Stankler L. Psoriatic arthritis of the temporomandibular joint. *Br Dent J* 1983;154:17–18.
11. Kudryk WH, Baker GL, Percy JS. Ankylosis of the temporomandibular joint from psoriatic arthritis. *J Otolaryngol* 1985;14:336–338.
12. Avrahami E, Garti A, Weiss-Peretz J, Yaron M. Computerized tomographic findings in the temporomandibular joint in patients with psoriatic arthritis. *J Rheumatol* 1986;13:1096–1098.

13. Baetz K, Klineberg I. Psoriatic arthritis of the temporomandibular joint. Case report. *Aust Dent J* 1986;31:335–339.
14. Wilson AW, Brown JS, Ord RA. Psoriatic arthropathy of the temporomandibular joint. *Oral Surg Oral Med Oral Pathol* 1990; 70: 555–558.
15. Koorbusch GF, Zeitler DL, Fotos PG, Doss JB. Psoriatic arthritis of the temporomandibular joints with ankylosis. Literature review and case reports. *Oral Surg Oral Med Oral Pathol* 1991;71:267–274.
16. Larheim TA, Smith HJ, Aspestrand F. Rheumatic disease of temporomandibular joint with development of anterior disk displacement as revealed by magnetic resonance imaging. A case report. *Oral Surg Oral Med Oral Pathol* 1991;71:246–249.
17. Miles DA, Kaugars GA. Psoriatic involvement of the temporomandibular joint. Literature review and report of two cases. *Oral Surg Oral Med Oral Pathol* 1991;71:770–774.
18. Ulmansky M, Michelle R, Azaz B. Oral psoriasis: report of six new cases. *J Oral Pathol Med* 1995;24:42–45.
19. Yamamoto T, Watanabe K, Nishioka K. Temporomandibular arthritis in a patient with psoriasis vulgaris under systemic etretinate therapy. *Dermatology* 2004;209:77.
20. Alstergren P, Larsson PT, Kopp S. Successful treatment with multiple intra-articular injections of infliximab in a patient with psoriatic arthritis. *Scand J Rheumatol* 2008;37:155–157.
21. Lamazza L, Guerra F, Pezza M, et al. The use of etanercept as a non-surgical treatment for temporomandibular joint psoriatic arthritis: a case report. *Australian Dental Journal* 2009;54:161–165.
22. Farronato G, Garagiola U, Carletti V, et al. Psoriatic arthritis: temporomandibular joint involvement as the first articular phenomenon. *Quintessence Int* 2010;41:395–398.
23. Kononen M. Subjective symptoms from the stomatognathic system in patients with psoriatic arthritis. *Acta Odontol Scand* 1986;44:377–383.
24. Offidani A, Cellini A, Valeri G, Giovagnoni A. Subclinical joint involvement in psoriasis: magnetic resonance imaging and X-ray findings. *Acta Derm-Venereol* 1998;78:463–465.
25. Jacobson JA, Girish G, Jiang Y, Resnick D. Radiographic evaluation of arthritis: inflammatory conditions. *Radiology* 2008;248:378–389.
26. Gisondi P, Girolomoni G, Sampogna F, et al. Prevalence of psoriatic arthritis and joint complaints in a large population of Italian patients hospitalised for psoriasis. *Eur J Dermatol* 2005;15:279–283.