

# Root Canal Morphology of Mandibular Incisors with Double Root Canals in a Chinese Population

Jun Xin ZHU<sup>1</sup>, Ying ZHAO<sup>2</sup>, Ying Tao DONG<sup>2</sup>, Zu Hua WANG<sup>1</sup>, Gang LI<sup>3</sup>, Mu Qing LIU<sup>3</sup>, Xiao Yan WANG<sup>1</sup>

**Objective:** To investigate the bilateral symmetry of double root canals, variation in root canal bifurcation and position of canal orifices in mandibular incisors in a Chinese population.

**Methods:** A total of 149 subjects with mandibular incisors with two canals were selected from 866 patients based on CBCT images and divided into three groups: group 1 (< 21 years), group 2 (21–40 years) and group 3 (> 40 years). The prevalence of bilateral symmetry of double root canals (type III and type V), the distance between the cemento-enamel junction (CEJ) and the bifurcation (D1) and the distance between the two canal orifices (D2) were calculated and analysed.

**Results:** The bilateral symmetry of type III for mandibular central incisors (MCIs) (44.4%) was significantly lower than that for mandibular lateral incisors (MLIs) (63.4%). D1 was greater in group 1 ( $4.63 \pm 1.35$  mm) than in group 2 ( $3.99 \pm 1.02$  mm) and group 3 ( $3.90 \pm 1.95$  mm). D2 was shorter in MCIs ( $0.65 \pm 0.20$  mm) than in MLIs ( $0.74 \pm 0.22$  mm).

**Conclusion:** Special attention is required in the root canal treatment of mandibular incisors, especially in patients aged above 21 years.

**Key words:** bilateral symmetry, CBCT, double root canals, mandibular incisors

*Chin J Dent Res* 2020;23(3):199–204; doi: 10.3290/j.cjdr.a45224

Root canal debridement and good quality hermetic obturation are essential for successful endodontic treatment<sup>1</sup>. Owing to the complexity and variation of the root canal system, intricate canal spaces like the apical delta<sup>2</sup> and isthmus<sup>3</sup> or multiple canals in a single root<sup>4</sup> pose a great challenge to dental clinicians in root canal preparation and obturation. It has been reported that mandibular anterior teeth exhibit a high prevalence of

two canals in a single root. Based on previous research, the reported prevalence of two canals in a single root in incisors ranges from 10% to 65.5% and can be influenced by ethnic background and detection method<sup>5–25</sup>.

When two root canals are present in the root of a mandibular incisor, the bifurcation of the two canals usually starts from the junction between the coronal third and middle third of the root<sup>13,19,24</sup>. The distance from the bifurcation to the anatomical apex presents large variation, but in most cases ranges from 6 to 12 mm<sup>7</sup>. The anatomical apex is invisible to the naked eye in clinical situations, thus if the mean distance between the bifurcation and the cemento-enamel junction (CEJ) and between the labial and lingual canal orifices in the mandibular incisors can be determined, this information would provide valuable guidance for the detection of the lingual root canal.

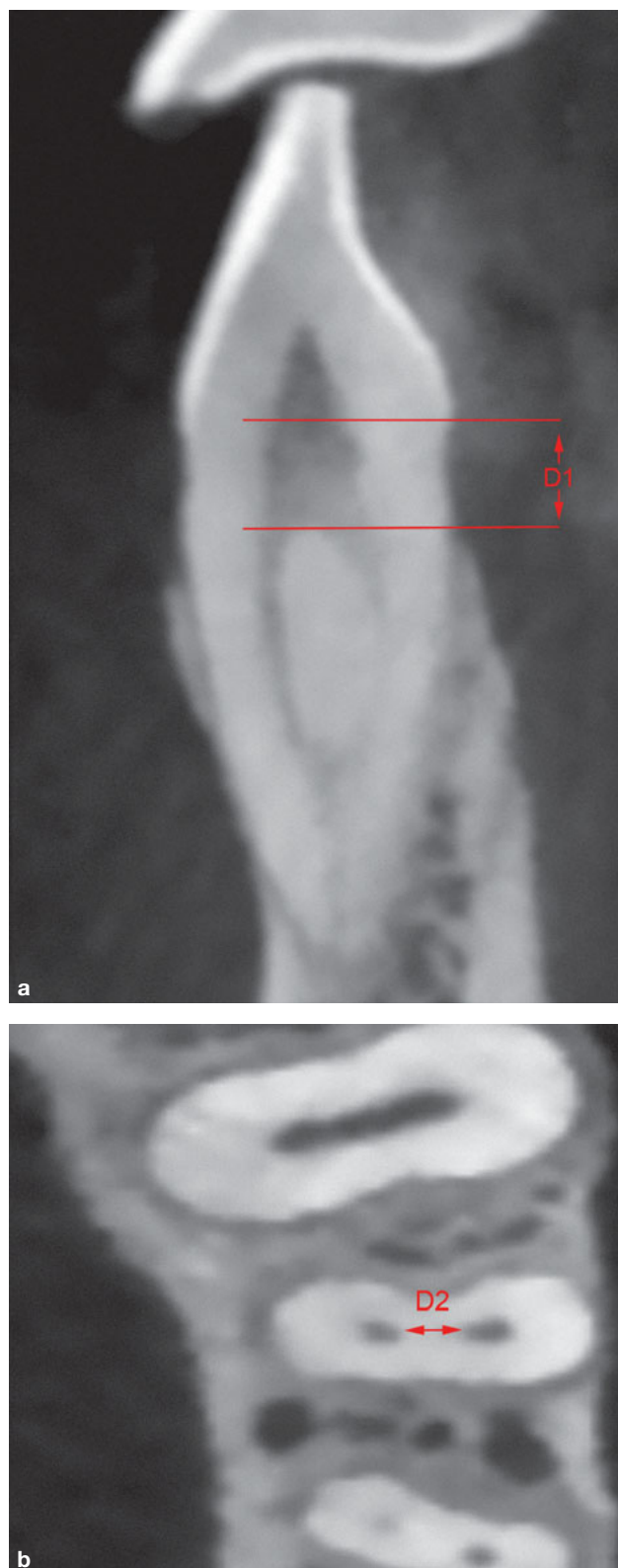Since CBCT was introduced in dentistry in 1998, it has become an indispensable technique for clinicians<sup>26–28</sup>. Although its single radiation dose is higher than that of conventional periapical radiography, CBCT has proven to be invaluable for various clinical purposes, especially for obtaining detailed data on the root canal system<sup>29</sup>. Compared with conventional intraoral

1 Department of Cariology and Endodontology, Peking University School and Hospital of Stomatology, National Engineering Laboratory for Digital and Material Technology of Stomatology, Beijing Key Laboratory of Digital Stomatology, Beijing, P.R. China.

2 Department of Conservative Dentistry, Beijing Chongwen Hospital of Stomatology, Beijing, P.R. China.

3 Department of Radiology, Peking University School and Hospital of Stomatology, National Engineering Laboratory for Digital and Material Technology of Stomatology, Beijing Key Laboratory of Digital Stomatology, Beijing, P.R. China.

**Corresponding author:** Dr Xiao Yan WANG, Department of Cariology and Endodontology, Peking University School and Hospital of Stomatology, 22# Zhongguancun South Avenue, HaiDian District, Beijing 100081, P.R. China. Tel: 86-10-82195525; Fax: 86-10-82195525. Email: wangxiaoyan@pkuss.bjmu.edu.cn



**Fig 1** CBCT images of double root canals. **(a)** Distance between the CEJ and the root canal bifurcation (D1) in a sagittal section view of the double root canals. **(b)** Shortest distance in the transverse plane between the two canal orifices (D2) in an axial section view of the double root canals.

radiography, CBCT is very powerful for excluding the overlaps caused by other tissues and thus allows better observation of the 3D structure of the tooth<sup>30,31</sup>. Previous studies have demonstrated anatomical symmetry in the number of roots and root canal systems between bilateral homonym teeth<sup>32,33</sup>. However, these studies focused primarily on premolars and molars, and limited information is available on the root canal system in the mandibular anterior teeth.

Previous research has indicated that missing the second root canal is the main reason for the failure of root canal treatment of mandibular incisors<sup>18</sup>. Observation of the root canal morphology of mandibular incisors with two canals, including the locations of root canal bifurcation and canal orifices, may reduce the risks involved in clinical treatment and improve the success rate of root canal therapy for mandibular incisors. Therefore, this study aims to observe the root canal morphology and investigate the bilateral symmetry of double root canals, the distance between the root canal bifurcation and the CEJ, and the distance between the two canal orifices in mandibular incisors in a Chinese population using CBCT.

### Materials and methods

CBCT images of patients who presented at our imaging centre at Peking University School and Hospital of Stomatology from October 2012 to July 2013 were retrospectively collected and evaluated. A total of 866 patients were enrolled, fulfilling the following criteria:

- the mandibular incisors in the images were completely developed;
- the mandibular incisors were without restorations, cervical caries lesions, root caries lesions, root resorption, apical periodontitis, periodontal disease, horizontal/vertical loss, root canal treatment or traumatic injuries.

The CBCT images were acquired as part of a subsidiary examination undertaken before treatments such as orthodontic procedures, placement of dental implants and treatment of dentomaxillofacial traumas. The study was approved by our institutional review board (PKUSSIRB-201520035).

All images were obtained using a NewTom VG CBCT (QR, Verona, Italy) at 110 kV with slice spacing and thickness both set at 0.15 mm, and the voxel size was 0.15 mm. Two endodontists recorded and measured the images separately using the NNT Viewer software. When the two endodontists were unable to achieve conformity, a second evaluation was performed

after 2 weeks, and a third experienced endodontist was involved to achieve a final consensus.

Among the 866 patients, 149 patients who had at least one mandibular incisor in which two root canals could be detected and in whom homonym teeth could be observed were selected. According to Vertucci's classification<sup>6</sup>, the configurations of double root canals are assigned to all types except type I and VIII. As type III and type V made up almost all the canal system types in the mandibular incisors in this study, the prevalence of bilateral symmetry of type III and type V in mandibular central or lateral incisors was calculated as  $P = n / N$ , where  $n$  was the number of patients with the same root canal configuration in the homonym teeth and  $N$  was the number of patients with double root canals in mandibular incisors on at least one side.

The 149 patients were then divided into three age groups: group 1, < 21 years ( $n = 30$ ); group 2, 21–40 years ( $n = 83$ ); and group 3, > 40 years ( $n = 36$ ). For each incisor with two canals, the long axis was set under free angulation of 3D slices on multiplanar reconstruction images, and the largest sagittal slice parallel to the long axis was selected. The perpendicular distance between the CEJ and the bifurcation (D1) (Fig 1a) was then measured. Further, the shortest distance between the canal orifices (D2) was recorded on the first axial image where two orifices could be clearly distinguished (Fig 1b). D1 and D2 were recorded in groups 1, 2 and 3. Statistical analyses were conducted using SPSS version 20.0 software (SPSS, Chicago, IL, USA). A chi-square test was used to compare the difference in prevalence of bilateral symmetry between mandibular central and lateral incisors. A one-way analysis of variance (ANOVA) was conducted to compare the differences between the quantitative data. Differences were considered statistically significant when  $P < 0.05$ .

**Table 1** Number of patients with the same root canal configuration.

Tooth	Type III	Type V	N
Central incisors	28	5	63
Lateral incisors	90	9	142

N, number of patients with double root canals in mandibular central or lateral incisors on at least one side

**Table 2** Mean  $\pm$  standard deviation of D1 (mm) in the different groups.

Tooth	Group 1	Group 2	Group 3	Total
Central incisors	4.52 $\pm$ 1.05	4.11 $\pm$ 1.17	3.87 $\pm$ 1.08	4.16 $\pm$ 1.15
Lateral incisors	4.69 $\pm$ 1.49	3.94 $\pm$ 0.95	3.91 $\pm$ 2.12	4.06 $\pm$ 1.46
Incisors	4.63 $\pm$ 1.35 <sup>a</sup>	3.99 $\pm$ 1.02 <sup>b</sup>	3.90 $\pm$ 1.95 <sup>b</sup>	4.08 $\pm$ 1.38
N	30	83	36	149

D1, distance between the root canal bifurcation and the CEJ; N, number of patients with mandibular incisors with two canals on at least one side; <sup>a,b</sup>, different letters indicate a significant difference between the groups ( $P < 0.05$ )

## Results

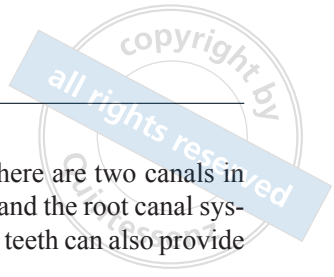
### *Bilateral symmetry of double root canals*

Of the 149 patients with incisors with two canals on at least one side, 56 patients had both central and lateral incisors with two canals on at least one side simultaneously, 7 patients had central incisors with two canals, and 86 patients had lateral incisors with two canals.

Among the 63 patients with central incisors with two canals on at least one side, 28 had teeth with type III root canal configuration on both sides and 5 had teeth with type V root canal configuration. Among the 142 patients with lateral incisors with two canals on at least one side, 90 had teeth with type III root canal configuration on both sides and 9 had teeth with type V root canal configuration (Table 1). Consequently, the bilateral symmetry of type III was 44.4% (28/63) for mandibular central incisors, which was significantly lower than that for mandibular lateral incisors (63.4%, 90/142) ( $P = 0.01$ ). The bilateral symmetry of type V for mandibular central incisors (7.9%, 5/63) was similar to that for mandibular lateral incisors (6.3%, 9/142) ( $P = 0.68$ ).

### *Distance between the root canal bifurcation and the CEJ (D1)*

The values of the perpendicular distance between the root canal bifurcation and the CEJ in the mandibular incisors (D1) are shown in Table 2. The value of D1 in all mandibular incisors was  $4.08 \pm 1.38$  mm for all ages. Furthermore, the values of D1 in group 1 were significantly higher than those in group 2 ( $P = 0.00$ ) and group 3 ( $P = 0.00$ ), while no significant difference was detected between group 2 and group 3 ( $P = 0.93$ ).



*Distance between the two canal orifices (D2)*

The values of the distance between the two canal orifices in the mandibular incisors (D2) are shown in Table 3. The value of D2 was  $0.65 \pm 0.20$  mm for mandibular central incisors, which was shorter than that for mandibular lateral incisors ( $0.74 \pm 0.22$  mm) ( $P = 0.00$ ).

**Discussion**

Mandibular anterior teeth exhibit far greater variation in root canal morphology than maxillary anterior teeth<sup>34</sup>. Mandibular lateral incisors have a much higher incidence of double root canals than mandibular central incisors<sup>24</sup>. In the majority of mandibular anterior teeth with two canals, the bifurcation is located in the coronal and middle third of the root<sup>7</sup>; our previous study revealed similar findings<sup>35</sup>. To the best of the authors' knowledge, limited information is available on the bilateral symmetry of double canals in incisors. Lin et al<sup>24</sup> observed 1,412 mandibular incisors in CBCT and found that 92.7% of the central incisors and 89.2% of the lateral incisors had the same canal configurations. The study emphasised analysis of the canal configurations, without sufficient data on the bilateral symmetry of double canals. Kayaoglu et al<sup>23</sup> observed 6,253 teeth in a Turkish population using CBCT and found that the bilateral symmetry of double canals in mandibular central and lateral incisors was 45.0% and 29.0% respectively. In their study, all root canal configurations with the exception of type I and type VIII were considered as two canals and were not classified further, which was not extremely symmetrical in the root canal system. Our results showed that the bilateral symmetry of type III in mandibular lateral incisors was more prevalent than that in central incisors, and no significant difference was found in the prevalence of bilateral symmetry of type V between mandibular central and lateral incisors. Furthermore, over half of the patients with mandibular incisors with double canals on at least one side had the same root canal configuration in their homonym teeth. Dental practitioners should therefore check the canal number of

mandibular incisors carefully if there are two canals in the contralateral homonym teeth, and the root canal system of the contralateral homonym teeth can also provide significant guidance.

It is extremely difficult to identify and locate a tiny lingual root canal in mandibular incisors, but this is paramount for long-term successful outcomes. In this study, we explored the perpendicular distance between the bifurcation and the CEJ (D1), and between the two canal orifices (D2). A previous study reported that the distance between the bifurcation and the anatomic apex ranged from 6 mm to 12 mm in most mandibular incisors with double canals<sup>7</sup>. This finding will have clinical significance if the bifurcation can be identified by a visible anatomic landmark. The lowest position of the CEJ is usually located on the lingual or labial side and can be easily accessed and detected by a periodontal probe. Therefore, we chose this point as the landmark in the present study. We found that the mean distance between the root canal bifurcation and the CEJ was  $4.08 \pm 1.38$  mm in the mandibular incisors. This suggests that clinicians should examine the region below the CEJ cautiously during mandibular incisor root canal therapy. Furthermore, the distance between the bifurcation and the CEJ in patients aged under 21 years was greater than the average distance for subjects aged over 21 years. Secondary dentine continuously accumulates on the inside of the root canal wall, and accumulation of dentine on the furcation area that occurs with ageing will particularly increase the height of the bifurcation position<sup>36</sup>, which may be reflected in our CBCT results.

In the present study, we found that the distance between the two canal orifices in mandibular incisors ranged from 0.5 mm to 1.0 mm, suggesting that the lingual wall of the access cavity should be sufficiently removed. In accordance with previous studies<sup>13,22</sup>, extension of the coronal cavities in the incisogingival direction is also recommended in the present study. Overall, the prepared access cavity must provide a clear and unobstructed pathway to each orifice and must be designed in such a way as to avoid interference with the often difficult intracanal procedures to follow<sup>37</sup>.

**Table 3** Mean  $\pm$  standard deviation of D2 (mm) in the different groups.

Tooth	Group 1	Group 2	Group 3	Total
Central incisor	$0.66 \pm 0.19$	$0.67 \pm 0.21$	$0.58 \pm 0.12$	$0.65 \pm 0.20^a$
Lateral incisor	$0.72 \pm 0.24$	$0.75 \pm 0.21$	$0.71 \pm 0.22$	$0.74 \pm 0.22^b$
N	30	83	36	149

D2, distance between the two canal orifices; N, number of patients with mandibular incisors with two canals on at least one side; <sup>a,b</sup>, different letters indicate a significant difference between the teeth ( $P < 0.05$ )

Clinically, use of a magnification tool such as an operating microscope is an effective way to avoid missing a root canal<sup>38</sup>.

Tooth dimensions can vary between men and women<sup>39,40</sup>. The present study did not take this influence factor into consideration. The effect of ethnic background was also not taken into consideration. Therefore, further studies considering the tooth dimensions and ethnic are necessary.

## Conclusion

Within the limitations of the present study, in a Chinese population, the prevalence of bilateral symmetry of type III is higher in mandibular lateral incisors than in mandibular central incisors. The root canal bifurcation is further from the CEJ in patients aged < 21 years than in older patients, with an average of  $4.08 \pm 1.38$  mm. The distance between the two canal orifices is shorter in mandibular central incisors than in mandibular lateral incisors.

## Acknowledgements

The authors thank Prof Cheng Fei ZHANG from the University of Hong Kong and Prof Kai Yuan FU from Peking University School and Hospital of Stomatology for their help with this work.

## Conflicts of interest

The authors declare no conflicts of interest related to this study.

## Author contribution

Drs Jun Xin ZHU, Ying ZHAO, Ying Tao DONG, Zu Hua WANG, Mu Qing LIU and Gang LI carried out the study; Dr Jun Xin ZHU drafted and revised the manuscript; Drs Zu Hua WANG and Gang LI helped to revise the manuscript; Dr Xiao Yan WANG designed the study and was involved in the revision and final review of the manuscript.

(Received Jul 28, 2019; accepted Mar 09, 2020)

## References

1. Ingle JI, Bakland LK. Endodontics, ed 4. Baltimore: Williams & Wilkins, 1994.
2. Simon G. The apical delta and root canal therapy. *Quintessence Int (Berl)* 1971;2:25–27.
3. Hsu YY, Kim S. The resected root surface. The issue of canal isthmuses. *Dent Clin North Am* 1997;41:529–540.
4. England MC Jr, Hartwell GR, Lance JR. Detection and treatment of multiple canals in mandibular premolars. *J Endod* 1991;17:174–178.
5. Benjamin KA, Dowson J. Incidence of two root canals in human mandibular incisor teeth. *Oral Surg Oral Med Oral Pathol* 1974;38:122–126.
6. Vertucci FJ. Root canal anatomy of the human permanent teeth. *Oral Surg Oral Med Oral Pathol* 1984;58:589–599.
7. Han T, Ma Y, Yang L, Chen X, Zhang X, Wang Y. A study of the root canal morphology of mandibular anterior teeth using cone-beam computed tomography in a Chinese subpopulation. *J Endod* 2014;40:1309–1314.
8. Leoni GB, Versiani MA, Pécora JD, de Sousa-Neto MD. Micro-computed tomographic analysis of the root canal morphology of mandibular incisors. *J Endod* 2014;40:710–716.
9. Milanezi de Almeida M, Bernardineli N, Ordinola-Zapata R, et al. Micro-computed tomography analysis of the root canal anatomy and prevalence of oval canals in mandibular incisors. *J Endod* 2013;39:1529–1533.
10. Kaffe I, Kaufman A, Littner MM, Lazarson A. Radiographic study of the root canal system of mandibular anterior teeth. *Int Endod J* 1985;18:253–259.
11. Klein RM, Blake SA, Nattress BR, Hirschmann PN. Evaluation of x-ray beam angulation for successful twin canal identification in mandibular incisors. *Int Endod J* 1997;30:58–63.
12. Nattress BR, Martin DM. Predictability of radiographic diagnosis of variations in root canal anatomy in mandibular incisor and premolar teeth. *Int Endod J* 1991;24:58–62.
13. Rankine-Wilson RW, Henry P. The bifurcated root canal in lower anterior teeth. *J Am Dent Assoc* 1965;70:1162–1165.
14. Walker RT. The root canal anatomy of mandibular incisors in a southern Chinese population. *Int Endod J* 1988;21:218–223.
15. Al-Qudah AA, Awawdeh LA. Root canal morphology of mandibular incisors in a Jordanian population. *Int Endod J* 2006;39:873–877.
16. Boruah LC, Bhuyan AC. Morphologic characteristics of root canal of mandibular incisors in North-East Indian population: an in vitro study. *J Conserv Dent* 2011;14:346–350.
17. Calişkan MK, Pehlivan Y, Sepetçioğlu F, Türkün M, Tuncer SS. Root canal morphology of human permanent teeth in a Turkish population. *J Endod* 1995;21:200–204.
18. Kartal N, Yanıkoğlu FÇ. Root canal morphology of mandibular incisors. *J Endod* 1992;18:562–564.
19. Madeira MC, Hetem S. Incidence of bifurcations in mandibular incisors. *Oral Surg Oral Med Oral Pathol* 1973;36:589–591.
20. Rahimi S, Milani AS, Shahi S, Sergiz Y, Nezafati S, Lotfi M. Prevalence of two root canals in human mandibular anterior teeth in an Iranian population. *Indian J Dent Res* 2013;24:234–236.
21. Sert S, Aslanalp V, Tanalp J. Investigation of the root canal configurations of mandibular permanent teeth in the Turkish population. *Int Endod J* 2004;37:494–499.
22. Altunsoy M, Ok E, Nur BG, Aglarci OS, Gungor E, Colak M. A cone-beam computed tomography study of the root canal morphology of anterior teeth in a Turkish population. *Eur J Dent* 2014;8:302–306.
23. Kayaoglu G, Peker I, Gumusok M, Sarikir C, Kayadugun A, Ucok O. Root and canal symmetry in the mandibular anterior teeth of patients attending a dental clinic: CBCT study. *Braz Oral Res* 2015;29: S1806-83242015000100283.

24. Lin Z, Hu Q, Wang T, et al. Use of CBCT to investigate the root canal morphology of mandibular incisors. *Surg Radiol Anat* 2014;36:877–882.
25. Liu J, Luo J, Dou L, Yang D. CBCT study of root and canal morphology of permanent mandibular incisors in a Chinese population. *Acta Odontol Scand* 2014;72:26–30.
26. Metska ME, Aartman IH, Wesselink PR, Özok AR. Detection of vertical root fractures in vivo in endodontically treated teeth by cone-beam computed tomography scans. *J Endod* 2012;38:1344–1347.
27. Mozzo P, Procacci C, Tacconi A, Martini PT, Andreis IA. A new volumetric CT machine for dental imaging based on the cone-beam technique: preliminary results. *Eur Radiol* 1998;8:1558–1564.
28. Tyndall DA, Rathore S. Cone-beam CT diagnostic applications: caries, periodontal bone assessment, and endodontic applications. *Dent Clin North Am* 2008;52:825–841.
29. Silva EJ, Nejaim Y, Silva AV, Haiter-Neto F, Cohenca N. Evaluation of root canal configuration of mandibular molars in a Brazilian population by using cone-beam computed tomography: an in vivo study. *J Endod* 2013;39:849–852.
30. Estrela C, Bueno MR, Leles CR, Azevedo B, Azevedo JR. Accuracy of cone beam computed tomography and panoramic and periapical radiography for detection of apical periodontitis. *J Endod* 2008;34:273–279.
31. Lofthag-Hansen S, Huumonen S, Gröndahl K, Gröndahl HG. Limited cone-beam CT and intraoral radiography for the diagnosis of periapical pathology. *Oral Surg Oral Med Oral Pathol Oral Radiol Endod* 2007;103:114–119.
32. Tian YY, Guo B, Zhang R, et al. Root and canal morphology of maxillary first premolars in a Chinese subpopulation evaluated using cone-beam computed tomography. *Int Endod J* 2012;45:996–1003.
33. Zhang R, Yang H, Yu X, Wang H, Hu T, Dummer PMH. Use of CBCT to identify the morphology of maxillary permanent molar teeth in a Chinese subpopulation. *Int Endod J* 2011;44:162–169.
34. Da Silva EJ, de Castro RW, Nejaim Y, et al. Evaluation of root canal configuration of maxillary and mandibular anterior teeth using cone beam computed tomography: an in-vivo study. *Quintessence Int* 2016;47:19–24.
35. Zhao Y, Dong YT, Wang XY, et al. Cone-beam computed tomography analysis of root canal configuration of 4674 mandibular anterior teeth [in Chinese]. *Beijing Da Xue Xue Bao Yi Xue Ban* 2014;46:95–99.
36. Hess W. *The Anatomy of Root Canals in the Teeth of the Permanent Dentition*. New York: William Wood & Co, 1925.
37. Janik JM. Access cavity preparation. *Dent Clin North Am* 1984;28:809–818.
38. Yoshioka T, Kobayashi C, Suda H. Detection rate of root canal orifices with a microscope. *J Endod* 2002;28:452–453.
39. Bishara SE, Jakobsen JR, Abdallah EM, Garcia AF. Comparisons of mesiodistal and buccolingual crown dimensions of the permanent teeth in three populations from Egypt, Mexico, and the United States. *Am J Orthod Dentofacial Orthop* 1989;96:416–422.
40. Ling JY, Wong RW. Tooth dimensions of Southern Chinese. *Homo* 2007;58:67–73.