

THE USE OF A CERAMIC FRAGMENT FOR A DIASTEMA CLOSURE: CLINICAL CASE

Gameiro A.^{*1}, Simões MB.², Amorim T.³, Fonseca L.⁴, Azul AC.⁵

¹ Médico Dentista em Formação Voluntária - Instituto Superior de Ciências da Saúde Egas Moniz ² Médica Dentista ³ Assistente convidado da Unidade Curricular de Medicina Dentária Conservadora - Instituto Superior de Ciências da Saúde Egas Moniz ⁴ Técnico laboratorial de prótese dentária ⁵ Professora Auxiliar e Regente da Unidade Curricular de Medicina Dentária Conservadora - Instituto Superior de Ciências da Saúde Egas Moniz

CLINICAL CASE DESCRIPTION: Male patient, healthy, aged 23, previous orthodontic treatment, unhappy with the aesthetics of his smile (Fig. 1). Following anamnesis and a clinical and radiographic evaluation, multiple caries lesions, teeth showing amelogenesis imperfecta and an antero-superior diastema were diagnosed (Fig. 2 - 4). Treatment plan involved an at-home dental bleaching, the aesthetic restorative treatment with composite resin of the caries lesions and teeth with amelogenesis imperfecta as well as a ceramic mini-veneer to close the diastema between teeth 12 and 13 (Fig. 5 - 6).

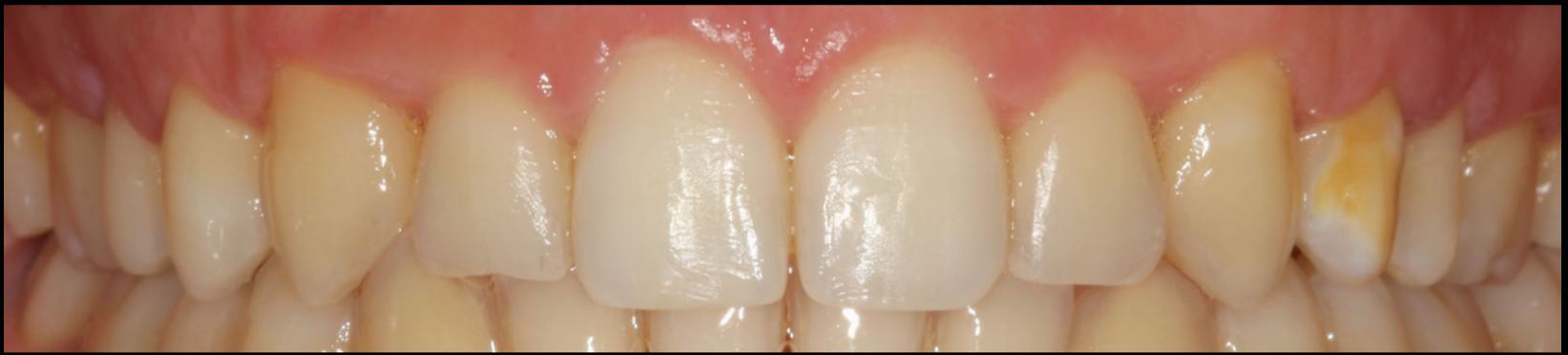

Fig. 1 - Initial intra-oral photo

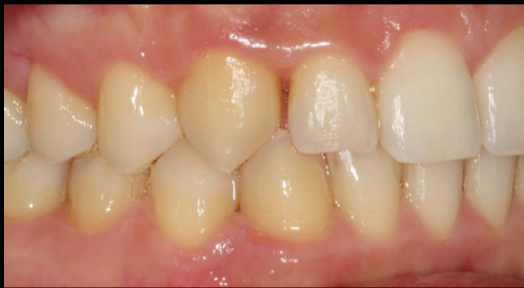

Fig. 2 - Initial intra-oral lateral photo

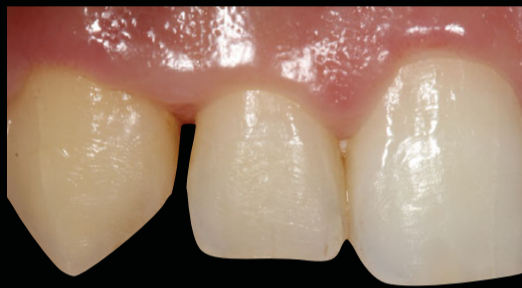

Fig. 3 - Initial Close-up

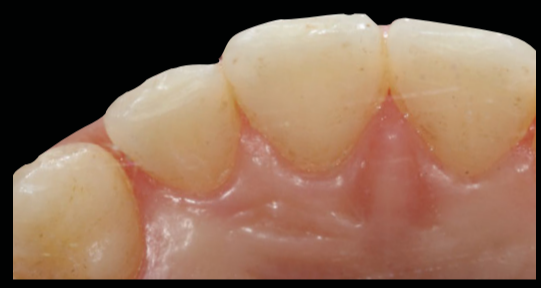

Fig. 4 - Intra-oral incisal perspective photo

DISCUSSION: Ceramic and composite are used in dentistry due to their ability in providing aesthetic results that mimic natural teeth. Ceramic is a biocompatible material, enabling the proper light reflection/ transmission (1) (Fig. 7). The cementation protocol is currently well documented (2) (Fig. 8 - 9). The correct treatment planning allows to maintain the color and shape stability (Fig. 10 - 11), displaying good mechanical strength when subjected to masticatory forces. (3).

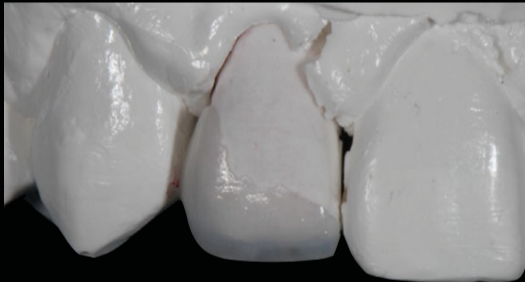


Fig. 5 - Ceramic fragment in the model

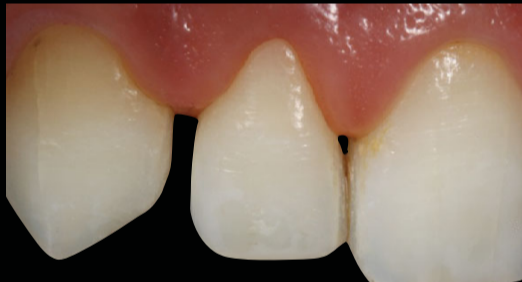

Fig. 6 - Cosmetic contouring

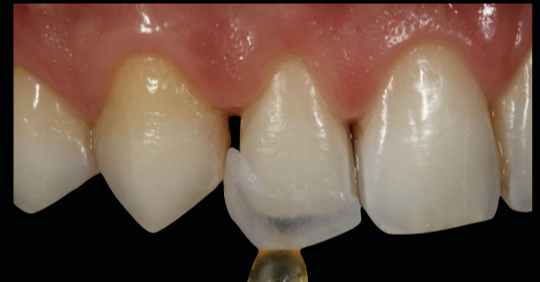

Fig. 7 - Try-in of the ceramic fragment

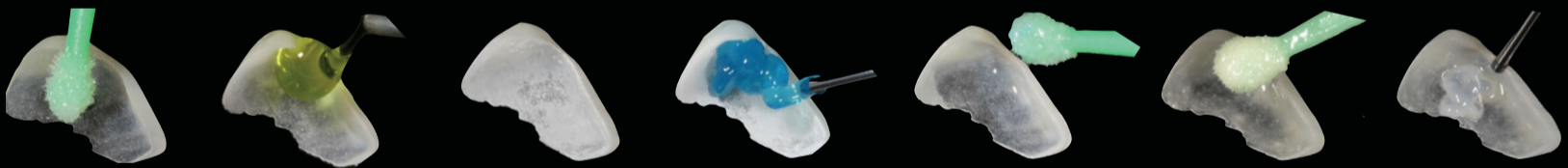


Fig. 8 - Sequence of the ceramic fragment preparation protocol

CONCLUSIONS: Through this treatment, the rehabilitation of the function and aesthetics of the smile was possible (Fig. 12 - 14). Ceramic fragments are an excellent choice due to their minimally invasive procedure and highly esthetic results.

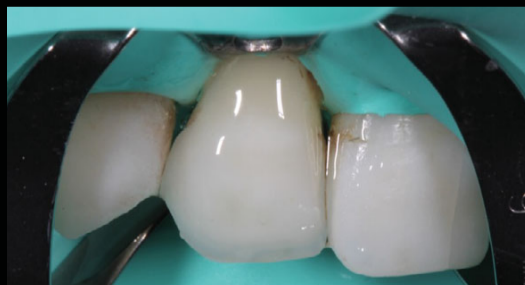

Fig. 9 - Photo immediately after cementation

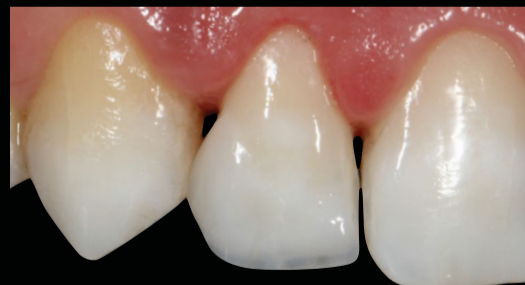

Fig. 10 - Close-up after cementation and removal of rubber dam

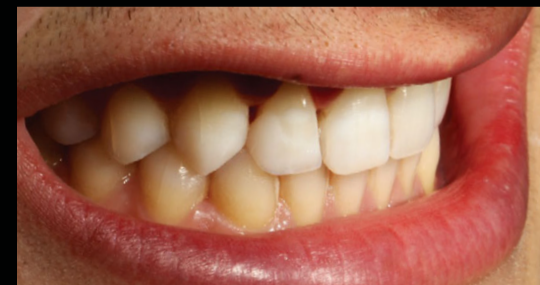

Fig. 11 - Extra-oral photo after cementation

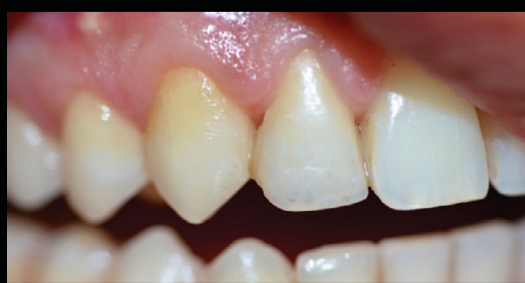

Fig. 12 - 6 months follow-up

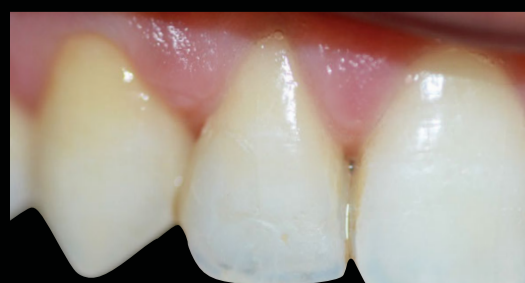

Fig. 13 - 6 months close-up follow-up

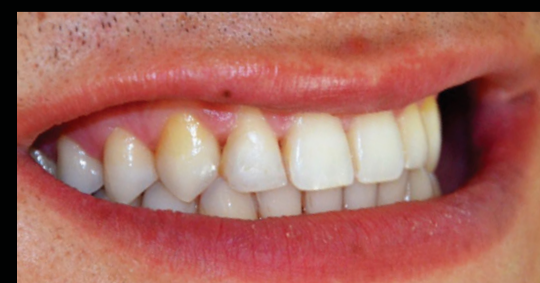

Fig. 14 - Final smile photo - 6 months follow-up

REFERENCES:

1. Andrade OS De, Romanini JC, Hirata R. Ultimate Ceramic Veneers: A Laboratory-Guided Ultraconservative Preparation Concept for Maximum Enamel Preservation. 2012;29-43.
2. Magne P, Belsor U. Bonded Porcelain Restorations, in the Anterior Dentition: A Biomimetic Approach. Chicago: Quintessence Books; 2002: p.343
3. Beier US, Kapferer I, Burtscher D, Dumfahrt H. Clinical performance of porcelain laminate veneers for up to 20 years. Int J Prosthodont [Internet]. 2012;25(1):79-85. Available from: <http://www.ncbi.nlm.nih.gov/pubmed/22259802>