

# RECOGNITION AND MANAGEMENT OF PALATO-GINGIVAL GROOVE: A HIDDEN TRACT IN THE MAXILLARY LATERAL INCISOR

Dr. Aparna Kaushik,<sup>1</sup> Dr. Jyoti Yadav,<sup>1</sup> Dr. Geetanjali Sharma,<sup>1</sup> Dr. Nishi Tanwar,<sup>1</sup> Dr. Rajinder Kumar Sharma,<sup>1</sup> Dr. Shikha Tewari<sup>1</sup>

<sup>1</sup> Department of Periodontics, Post Graduate Institute of Dental Sciences, Rohtak, Haryana, India

## INTRODUCTION:

Palato-gingival groove (PGG) is a developmental anomaly. It acts as a plaque retentive site which can lead to endodontic or periodontal disease or combined periodontal-endodontic disease. Withers et al. observed that the prevalence of palato-gingival groove was 8.5%, among which 2.33% were in maxillary incisors. Most PGGs (93.8%) were in maxillary lateral incisors.

**CHIEF COMPLAINT:** A 32-year-old, systemically healthy female reported to the Department of Periodontology, PGIDS, Rohtak with a chief complaint of dirty teeth.

## CLINICAL PRESENTATION:

Probing depth at all sites were in range of 2-3mm except the maxillary right lateral incisor, where the disto-palatal aspect revealed 7mm probing depth and clinical attachment loss (CAL) of 5mm. Bleeding on probing was present. No mobility or tenderness was observed.

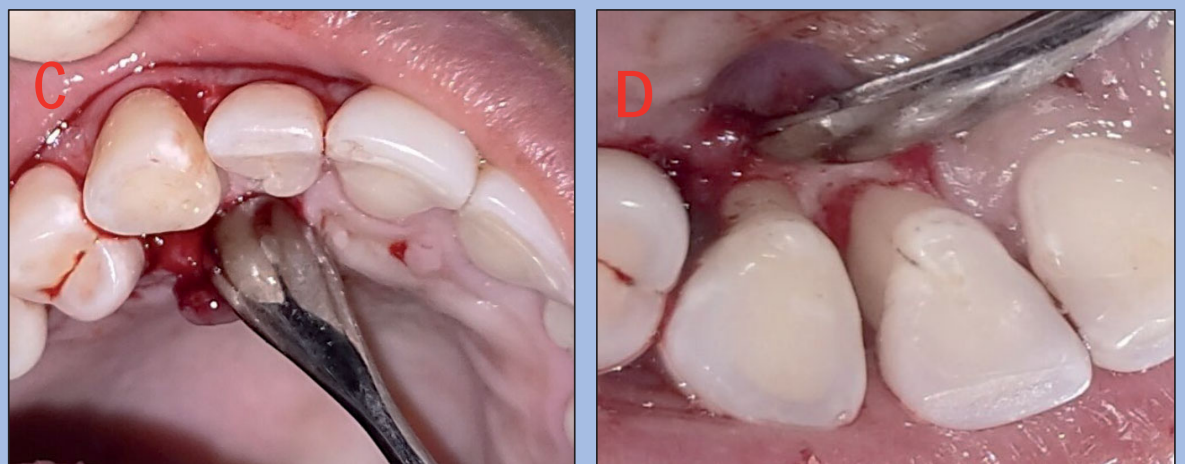
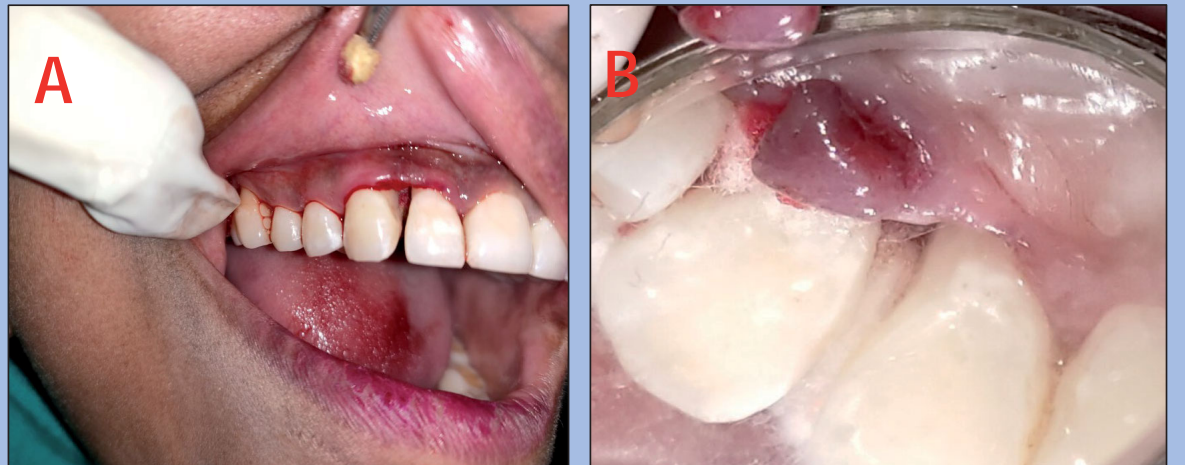**RADIOGRAPHICALLY:** revealed an isolated bone defect associated with the distal aspect of lateral incisor.

## METHODOLOGY

Non surgical treatment:

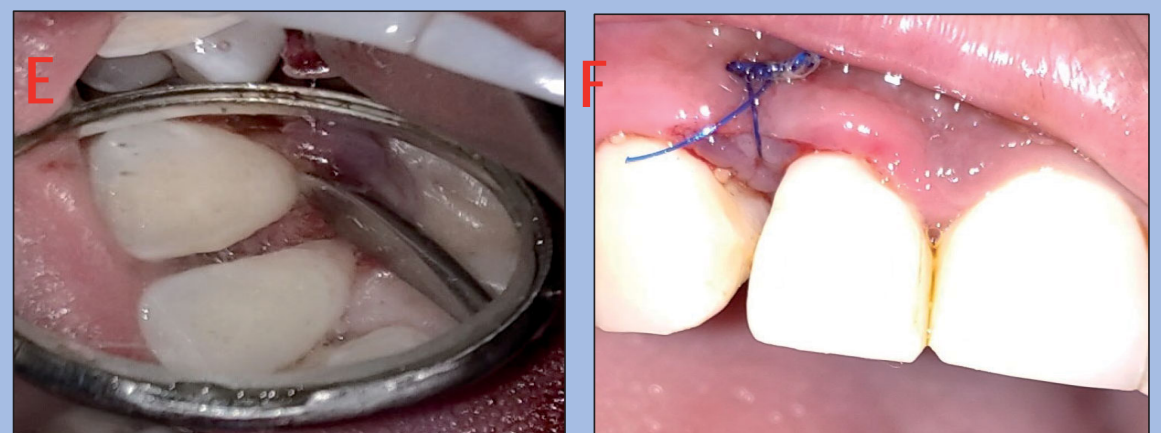
Phase 1 periodontal therapy was given.

Surgical treatment



A,B,C,D

Modified papilla preservation technique was chosen and a full thickness flap was elevated to expose the groove. After raising the periodontal flap, a gingival groove extending to the junction of the coronal and middle third of the root was evident.

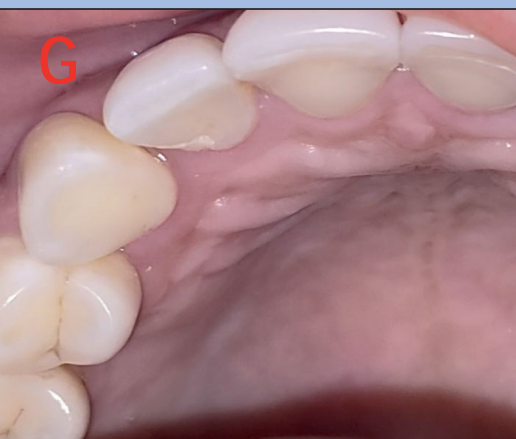

E,F

The groove was prepared and restored with GIC. Interrupted suture was given. Analgesics and antibiotics were prescribed.

G

At 6 months' follow up: Probing depth reduced from 7 mm to 2mm; the gain in CAL was 5mm, and BOP was absent



**CONCLUSION:** Eradication of plaque and sealing the groove are successful in management of palato-gingival groove. Early detection of palato-gingival groove is important as it can prevent further periodontal breakdown.

## REFERENCES:

- Withers JA, Brunsvold MA, Killoy WJ, Rahe AJ. The relationship of palato-gingival grooves to localized periodontal disease. J Periodontol 1981;52:41-44.
- Kim HJ, Choi Y, Yu MK, Lee KW, Min KS. Recognition and management of palatogingival groove for tooth survival: a literature review. Restor Dent Endod. 2017 May;42(2):77-86.
- Lekshmi MS, Sharma S, Gupta SR, Sharma S, Kumar V, Chawla A, Logani A. Prevalence and radiological characteristics of palatogingival groove: A retrospective cone-beam computed tomography study in an Indian cohort. J Conserv Dent. 2021 Jul-Aug;24(4):359-363.