

Parotidectomy for Treatment of Chronic Obstructive Parotitis

Lei ZHANG¹, Chuan Bin GUO¹, Min Xian HUANG¹, Da Quan MA¹, Guang Yan YU¹

Objective: *To assess the effects of superficial parotidectomy on the treatment of chronic obstructive parotitis.*

Materials and Methods: *Between 1995 and 2005, 17 patients (median age, 43 years; range 23 to 63) with chronic obstructive parotitis received parotidectomy after failure of conservative treatments. They had continued symptoms for 3 to 10 years. Patients were diagnosed by sialography prior to surgery and were subjected to superficial parotidectomy. The anterior part of the main ducts was preserved in four cases, and the entire main ducts were removed in the remaining 13 cases.*

Results: *A total of 16 patients had complete resolution of their symptoms following surgery. One case displayed persistent facial swelling for 4 months, resulting from an infection of the residual ducts; the symptoms disappeared after the removal of the ducts. Temporary facial paralysis occurred after surgery in seven cases, with complete recovery of all cases 6 to 12 months later.*

Conclusions: *Parotidectomy is an effective surgical approach for the patients with chronic obstructive parotitis who fail to respond positively to conservative treatment and with symptoms recurring frequently. Superficial parotidectomy is the surgical technique of choice. It is essential to remove the entire main duct to prevent the recurrence of facial swelling.*

Key words: *chronic parotitis, facial nerve, operation, parotid, parotidectomy*

Chronic obstructive parotitis (COP) is a relatively common inflammatory condition characterised by intermittent bouts of parotid pain, recurrent swelling and mucopurulent discharge^{1,2}. Clinically, COP is induced by various local factors that cause retardation or obstruction of salivary flow, resulting in retrograde infec-

tion. Histopathological changes include the destruction of acinar elements, duct ectasia, irregular proliferation of peripheral ducts and fibrous tissue, and periductal aggregations of chronic inflammatory cells²⁻⁴.

Treatment options include both conservative methods, such as gland massage, systemic antibiotics, injection of antibiotics into the duct, dilation of the duct, sialogogues, traditional Chinese medicine (TCM), or surgical options, such as parotidectomy and ligation of the duct^{5,6}. Recently, sialoendoscopy has also been used with good results in the treatment of COP^{7,8}. Parotidectomy is the most common treatment option not only for parotid tumours, but also for non-tumour diseases, including COP, and nodular Sjögren's syndrome. How-

¹ Department of Oral and Maxillofacial Surgery, Peking University School and Hospital of Stomatology, Beijing, P.R. China.

Corresponding author: Dr. Guang Yan YU, Department of Oral and Maxillofacial Surgery, Peking University School and Hospital of Stomatology, Beijing, 100081, P.R. China. Tel: 86-10-62191099. Fax: 86-10-62174302. E-mail: gyyu@263.net

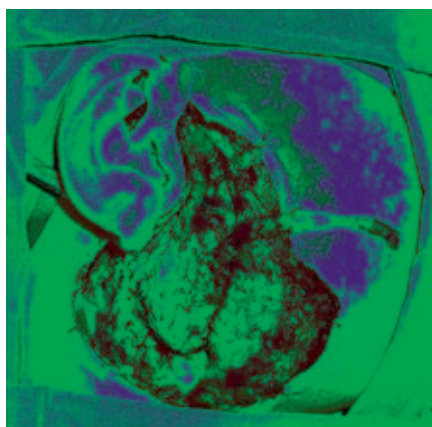
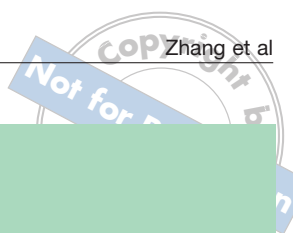

Fig 1a Superficial parotidectomy with removal of total main duct.

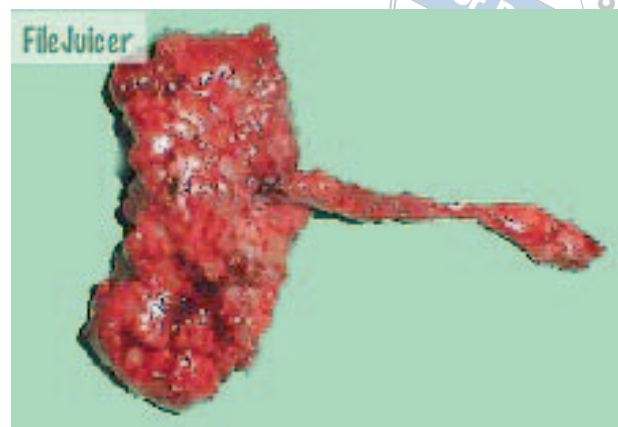

Fig 1b The superficial lobe of the parotid gland was removed with main duct.

ever, differences exist in the surgical characteristics and management of tumour versus non-tumour diseases.

The purpose of the current study was to assess the surgical management of COP and to evaluate the effects and critical key points of parotidectomy on COP patients at the Peking University School and Hospital of Stomatology.

Materials and Methods

Patients and methods

Patients with COP (n = 17; 5 males, 12 females; median age 43 years; age range 23–63) were diagnosed and treated at the Peking University School and Hospital of Stomatology between January 1995 and March 2006. Sialography was performed in all cases to support the diagnosis of COP^{1,2}. A detailed history was taken, including past history, treatment and clinical symptoms. Patients received conservative treatments for a period of 3 to 10 years, with unsatisfactory results, and suffered from recurrent swelling of the parotid gland. All patients underwent superficial parotidectomy. Diagnosis of non-specific or chronic obstructive sialadenitis was confirmed by histopathological examination.

Post-surgical complications included haematoma, saliva fistula and infection of the wound. Long-term follow-up was carried out for all 17 patients. Observation focused on the recurrence of symptoms, the emergence of facial paralysis and Frey's syndrome.

Operative procedures

Surgery was performed under general anaesthesia. Surgical removal began with a standard preauricular/cervi-

cal incision in a 'lazy S' fashion. The incision extended upward and forward 1–2 cm longer than usual in order to expose the anterior margin and main duct of the parotid gland. A skin flap was raised below the parotid fascia to reduce the post-surgical occurrence of Frey's syndrome. At the anterior margin of the parotid gland, the main duct was dissected, with the longest possible dissection length, near the ductal orifice. A circling incision was made around the ductal orifice inside the mouth and the whole duct was dissected. The entire main duct was removed from the extra-oral incision (Fig 1a).

Retrograde dissection was used as an alternative technique to dissect the facial nerve. Peripheral branches of the facial nerve were first traced. Further dissection of the nerve was meticulously carried out, up to the bifurcation or main trunk of facial nerve. The facial nerve was then protected and the superficial lobe of the parotid gland was removed (Fig 1b). The residual gland was carefully sutured to avoid salivary fistula. A suction drainage was maintained for 48 hours after the operation. Vitamin B1 (100 mg) and B12 (500 µg) injections were prescribed twice daily in cases of post-surgical facial paralysis or weakness. Physical therapy and training of facial muscles was initiated as soon as possible after surgery⁹, with facial muscle training continued at home until facial nerve function was completely recovered. Patients were followed-up for facial nerve function 6 and 12 months after surgery.

Results

The most frequent symptoms prior to surgery were intermittent bouts of parotid pain and recurrent swelling,

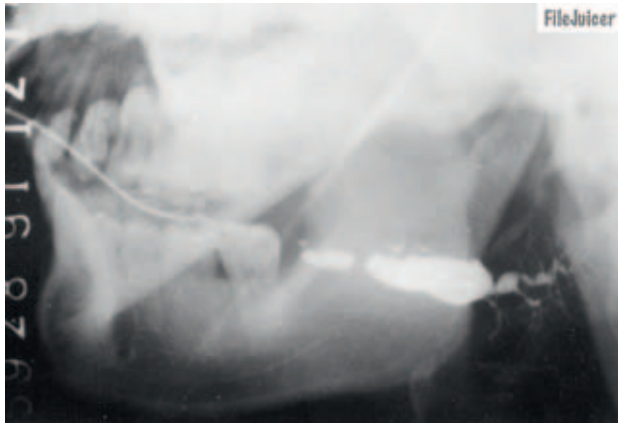

Fig 2 Sialograms showed that the main duct was severely dilated, extending to branching ducts with atrophy of acini.

with salty discharges as well as pus from the parotid ductal orifice when the parotid gland was milked. There was one case of pronounced symptoms, with parotid mass and without clear circumscription. No facial paralysis was reported prior to surgery.

All patients had a history of chronic relapsing and remitting disease within a 3 to 10 year period. Recurrent episodes lead to progressive damage to the salivary duct system, predisposing patients to develop more frequent and prolonged inflammatory episodes. Systemic antibiotics and iodine oil perfusion were used in all 17 cases, with unsatisfactory results. Additionally, TCM was used in four cases, also with little benefit.

Sialograms showed that the main duct of patients was severely dilated, extending to branching ducts, with acinar atrophy (Fig 2). According to the Wang's standard, all the patients were classified as type IV^{2,4}. The operative wounds healed well after surgery, without haematoma, saliva fistula and wound infection.

The duration of follow-up ranged from 10 months to nine years with a mean of 4.7 years. Complete resolution of symptoms was achieved in 16 cases. One patient had recurrent swelling in the operated region, mainly due to infection of the anterior part of the main duct, which was not removed following parotidectomy. Swelling had resolved after further excision of residual ducts under local anaesthesia. Although mild post-operative facial nerve palsy occurred in seven cases, all cases were resolved within a 6 to 12 month period with the use of post-operative therapy. There were no cases of permanent facial nerve palsy. Frey's syndrome occurred in three cases. However, none of them required specific management, as symptoms were mild.

Discussion

The treatment of COP has been controversial. The use of conservative therapies, including systemic antibiotics, gland massage, injection of antibiotics into the duct, dilation of the duct, sialogogues and TCM have been commonly prescribed for the treatment of COP¹⁰⁻¹². Although results are relatively satisfactory in patients with early stages of COP, they are mostly ineffective for severe and recurrent cases. Surgical therapies, including parotidectomy and ligation of the duct, have been mainly used in severe cases for which conservative treatments have been proven ineffective and for patients who suffer from recurrent parotid swelling, glandular sclerosis and duct dilation¹³⁻²¹. Although ligation of the parotid duct has also been used to treat COP, the therapeutic results have been unsatisfactory due to the retardation of saliva and the formation of abscesses in the residual ducts^{14,15}. The current consensus among physicians is to opt for early surgical management for patients with recalcitrant disease, rather than to wait for the formation of fistulae or abscesses¹⁶. However, the choice of optimal surgical technique, the amount of glandular resection as well as the need for ligation of the main parotid duct are still under debate. Additionally, there is no consensus on the use of superficial parotidectomy versus near-total parotidectomy.

In 1978, Casterline and Jacques reported 28 parotidectomies in 26 patients with chronic parotitis¹⁷. A total of 17 near-total parotidectomies were performed, without significant complications or recurrence of symptoms. The remaining 11 patients underwent superficial parotidectomies, with one patient displaying recurrence of symptoms 12 days after surgery. Based on their experience, they advocated near-total parotidectomy with removal of the parotid duct¹⁷. They concluded that near-total parotidectomy could be performed safely and should be the procedure of choice in patients with chronic, relapsing parotid sialadenitis¹⁷. Near-total parotidectomy is characterised by the resection of the superficial lobe of the parotid, followed by piecemeal removal of the deep lobe between the branches of the facial nerve to reduce the risk of recurrent sialadenitis. Researchers have advocated the use of this technique as symptoms persisted in a minority of patients following superficial parotidectomy. Arriaga and Myers¹⁶ suggested total parotidectomy with facial nerve dissection should be used in patients with chronic parotitis who failed to respond to medical management, with surgical management used at early stages of disease to avoid the formation of fistulae or abscesses. More recently, Moody et al¹⁴ reported the results of a retrospective study of 46 su-

perforial parotidectomies for the treatment of chronic parotitis. He advocated a policy of routine near-total parotidectomy based on an 11% failure incidence of superficial parotidectomy in their series that was salvaged by near-total parotidectomy¹⁴.

However, the use of this technique has been controversial. O'Brien and Murrant¹⁸ reported a series of 17 successful consecutive parotidectomies for the treatment of chronic sialoadenitis; near total and superficial parotidectomies were also reported to be equally effective. These data were reviewed by Bhatti et al¹⁵ for the surgical management of patients with chronic nonspecific parotid sialadenitis. They reported 17 patients treated by superficial parotidectomy, with two cases of infection of the parotid duct remnant. No recurrence of deep lobe sialadenitis or fistula formation was found, suggesting superficial parotidectomy had a high rate of success, with minimal long-term complications¹⁵. Similar results were obtained by Sadeghi et al¹⁹, Amin et al²⁰ and Motamed et al⁶, in which no significant differences in recurrence rates were observed between superficial parotidectomy and near-total parotidectomy.

Recently Nouraei et al²¹ presented a retrospective review of 36 parotidectomies for sialadenitis. The incidence of treatment failure requiring re-intervention following superficial parotidectomy was approximately 5%. Additionally, patients undergoing re-intervention did not require a salvage near-total parotidectomy to achieve successful symptom resolution. Clinical data suggested there were no statistical differences between the two techniques with respect to the likelihood of symptom resolution. However, some patients who underwent near-total parotidectomy may have been left with significant residual symptoms, suggesting superficial parotidectomy was aesthetically preferable to more radical surgery. They advocated the use of superficial parotidectomy as the treatment of choice, with near-total parotidectomy reserved only for patients with evidence of extensive deep lobe involvement at surgery. While Nouraei et al emphasised that the choice of surgical procedures should always be taken into consideration with the severity of the disease, they suggested that superficial parotidectomy should be the procedure of choice for patients with chronic parotid sialadenitis.

The proper management of the parotid main duct has also been debated. Casterline and Jaques¹⁷ advocated that near total parotidectomy, with removal of the parotid duct, could be safely performed and was the procedure of choice for patients with COP. However, Bhatti et al¹⁵ reported two cases of infection of the parotid duct remnant after surgery. Moody et al¹⁴ reported 46 superficial parotidectomies, of which 23 cases displayed ductal lig-

ation. Nouraei et al²¹ identified parotid duct ligation as an independent predictor of post-operative facial nerve dysfunction, although it did not confer any additional therapeutic benefits, leading them to suggest the avoidance of duct ligation during surgical operation.

In the present study, superficial parotidectomy was performed in all 17 cases. Resection of the superficial lobe and the total main duct of the parotid effectively relieved symptoms and inducement of infection. Chronic obstructive parotitis was caused by obstruction of the duct and saliva retardation, resulting in retrograde infection. Duct atresia and acinar atrophy resulted in the inhibition of glandular secretion and symptom amelioration. We found no occurrence of recurrent swelling resulting from inflammation of the residual gland in the deep lobe. Although we observed a single case of recurrent swelling, it resulted from inflammation of the residual main duct and was resolved by further removal of the duct, suggesting that total removal of the main duct is more important than parenchyma resection.

Protection of the facial nerve is critical during parotidectomy²², and is more difficult in the COP patients due to inflammatory fibrosis of the gland and close adhesiveness of the facial nerve with glandular tissues. Our data suggested the use of superficial parotidectomy with the entire duct was sufficient for COP. It is associated with a low incidence of incomplete symptom resolution requiring further intervention. Further dissection of the facial nerves and excess removal of the glandular parenchyma might increase the risk of facial nerve damage. Additionally, preservation of the parotid deep lobe is less damaging to the facial nerve.

In order to decrease damage to the facial nerve, special attention to a few points is required. When dissecting above the facial nerve, one should try to avoid exposure of nerve sheath. Humid rather than dry gauze should also be used when the parotid gland is open. In instances of bleeding, scraping the wound with the gauze should be avoided. Additionally, the facial nerve should be covered with moist gauze once it has been dissected, to avoid exposing the facial nerve for an extended period of time.

Vitamins B1 and B12 should be prescribed in cases of post-operative facial paralysis or weakness. Also, the use of physical therapy and training of facial muscles is suggested to facilitate the recovery of the facial nerve and avoid atrophy of facial muscles⁹. Patients were given a video CD made by the hospital depicting live demonstration for training of facial muscles, as it is more convenient for the patients to train their facial muscles at home.

Sialoendoscopy has been used for the diagnosis and treatment of COP, with excellent results obtained in

some cases^{7,8}. However, there is little evidence to support its use in type IV patients with severe COP, for which surgery is the treatment option. For most patients, superficial parotidectomy, with removal of total main duct, is safe, effective and ideal for patients with severe COP and for whom more conservative methods have proven unsatisfactory.

Acknowledgement

The authors are grateful to Dr. Eddie C.K. Yau for revision of the manuscript.

References

- Baurmash HD. Chronic recurrent parotitis: a closer look at its origin, diagnosis and management. *J Oral Maxillofac Surg* 2004;62:1010-1018.
- Wang S, Zou Z, Wu Q, Sun K, Ma X, Zhu X. Chronic suppurative parotitis: a proposed classification. *Chin Med J (Engl)* 1996;109:555-560.
- Zou ZJ, Wang SL, Zhu JR, Wu QG, Yu SF. Chronic obstructive parotitis. Report of ninety-two cases. *Oral Surg Oral Med Oral Pathol* 1992;73:434-440.
- Wang SL, Zou ZJ, Wu QG, Sun KH. Sialographic changes related to clinical and pathologic findings in chronic obstructive parotitis. *Int J Oral Maxillofac Surg* 1992;21:364-368.
- Zou ZJ, Zhang G, Zhang ZY. Perfusion of chronic obstructive parotitis. Abstracts of Sino-America Saliva Research Conference 1998:53-56 (in Chinese).
- Motamed M, Laugharne D, Bradley PJ. Management of chronic parotitis: a review. *J Laryngol Otol* 2003;117:521-526.
- Qi SR, Liu XY, Li JY, Wang SL. Sialographic, sialoendoscopic and irrigation fluid study in chronic obstructive parotitis. *Zhonghua Kou Qiang Yi Xue Za Zhi* 2005;40:275-279 (in Chinese).
- Yu CQ, Yang C, QIU WL, Hu BP, Shen N, Zheng LY. The etiology and drug perfusion treatment of chronic obstructive parotitis under sialoendoscopy. *Zhong Guo Kou Qiang He Mian Wai Ke Za Zhi* 2003;1:155-158 (in Chinese).
- Shi XJ, Yu GY, Chen Y, Yang ZH. A clinical study on physiotherapy for treatment of traumatic facial nerve injury. *Xian Dai Kou Qiang Yi Xue Za Zhi* 2005;19:449-451 (in Chinese).
- Yu Guang-yan (ed). *Diseases of the Salivary Gland*. Beijing: Beijing Medical University and Union Medical University Publishing House, 1994;88-90 (in Chinese).
- Antoniades D, Harrison JD, Epivatianos A, Papanayotou P. Treatment of chronic sialadenitis by intraductal penicillin or saline. *J Oral Maxillofac Surg* 2004;62:431-434.
- Wang SL, Li J, Zhu XZ, Sun T, Dong H, Zhang YG. Gland atrophy following retrograde injection of methyl violet as a treatment in chronic obstructive parotitis. *Beijing Kou Qiang Yi Xue* 2000;8:59-63 (in Chinese).
- Nahlieli O, Bar T, Shacham R, Eliav E, Hecht-Nakar L. Management of chronic recurrent parotitis: current therapy. *J Oral Maxillofac Surg* 2004;62:1150-1155.
- Moody AB, Avery CM, Walsh S, Sneddon K, Langdon JD. Surgical management of chronic parotid disease. *Br J Oral Maxillofac Surg* 2000;38:620-622.
- Bhatty MA, Piggot TA, Soames JV, McLean NR. Chronic non-specific parotid sialadenitis. *Br J Plast Surg* 1998;51:517-521.
- Arriaga MA, Myers EN. The surgical management of chronic parotitis. *Laryngoscope* 1990;100:1270-1275.
- Casterline PF, Jaques DA. The surgical management of recurrent parotitis. *Surg Gynecol Obstet* 1978;146:419-422.
- O'Brien CJ, Murrant NJ. Surgical management of chronic parotitis. *Head Neck* 1993;15:445-449.
- Sadeghi N, Black MJ, Frenkiel S. Parotidectomy for the treatment of chronic recurrent parotitis. *J Otolaryngol* 1996;25:305-307.
- Amin MA, Bailey BMW, Patel SR. Clinical and radiological evidence to support superficial parotidectomy as the treatment of choice for chronic parotid sialadenitis: a retrospective study. *Br J Oral Maxillofac Surg* 2001;39:348-352.
- Nouraei SA, Ismail Y, McLean NR, Thomson PJ, Milner RH, Welch A. Surgical treatment of chronic parotid sialadenitis. *J Laryngol Otol* 2006;14:1-5.
- Yu GY. The management of facial nerve during protidectomy. *Kou Qiang He Mian Wai Ke Za Zhi* 2006;16:1-4 (in Chinese).