

Unilateral loss of occlusal support during deciduous dentition and its consequences to the growing mandibular condyle.

Language: English

Authors: Ingo Springer, Bernd Fleiner

Dept. of Oral and Maxillofacial Surgery Christian Albrecht University of Kiel, Germany (Head: Prof. Dr. Dr. F. Härle)

Date/Event/Venue:

15.10.98-17.10.98

122. Jahrestagung der DGZMK gemeinsam mit der 12. Jahrestagung der Deutschen Gesellschaft für Zahnerhaltung
Maritim Congress Centrum Bremen



DGZMK-Poster-Award 2000 for the best poster in 1999

Introduction

- Loss of supporting zones may lead to altered functional load of the condylar process of the mandible¹ (C.m.).
- Alterations of the functional load may lead to changes of the shape and the structure of the growing C.m.^{2,3}.
- The changes of the growth and structure of the growing C.m. are examined three-dimensionally.

Material and Methods

- The first molars of 8 eight-month-old micropigs are removed unilateral (Fig.3); experimental term: 4 months
Ipsilateral: loaded condyle, here named C.m. **B**
® Contralateral: unloaded condyle, here C.m. **Y**
Preparation: undecalcified serial sagittal sections (Fig.2), microradiography, fluorescence microscopy (intravital polychrome sequence labeling), lightmicroscopy (Goldner)
- Vertical growth: measurement of the distance between the fluorescent band and articular surface (Fig.4)
® Ratio of the vertical growth of the unloaded condyle over the loaded condyle: Quotient $q_g = C.m. Y / C.m. B$
- Articular surface curve C: the vertical growth during the experimental period is part of a virtual radius r: $C = 1 / r$
- Trabecular bone volume in relation to non-mineralized medullar space in %: it is calculated by planimetry to acquire a measure for the spongy bone density
® Ratio of the trabecular bone volume of the unloaded over the loaded side: Quotient $q_v = C.m. Y / C.m. B$
- Ratio of the total amount of bone produced by the unloaded condyle over the loaded condyle: $RTAB = q_g \times q_v$.

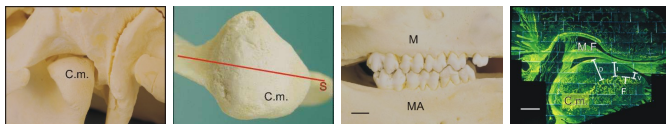


Fig. 1: Condyle of mandible (C.m.), dorsal view, pig, 8 month, (line: 1cm)

Fig. 2: Condyle of mandible (C.m.), cranial view, section-line (S), (line: 1cm)

Fig. 3: Occlusal support, maxilla (M), mandible (MA), (line: 1cm)

Fig. 4: Undecalcified sagittal section, fluorescence microscopy, condyle (C.M.), mandibular fossa (M.F.), fluorochrome band (F), measurement of vertical growth: Ventral, Intermediary, Dorsal, (line: 5mm)

Results

VERTICAL GROWTH AND ARTICULAR SURFACE CURVE

- $q_g = C.m. Y / C.m. B = 1.56$ ($p=0.0029$) (Difference C.m. minus C.m. circa $10.5 \mu m$ per day, Fig.5a)
- ® The average vertical growth of the unloaded side is about 1.56 times higher compared to the loaded side
- ® The average articular surface curve is less on the unloaded side than on the loaded side according to $C = 1 / r$.

- q_g increases from dorsomedial with 1.33 to ventrolateral with 2.38 in line with axis a ($p=0.0311$) (Fig.5b)
- Ⓡ An additional ventrolateral flattening of the over all less curved unloaded condyle is found.

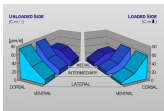


Fig. 5a: Condylar growth of C.m.Ý and C.m.ß per day [μm]




Fig.5b: Ratio of the vertical growth:
 $q_g = \text{C.m. Ý} / \text{C.m. ß}$

TRABECULAR BONE VOLUME

- C.m.ß: 48.65 vol%; C.m.Ý: 41.27 vol%; difference = 7.38 vol% ($p=0.0018$)
- Ⓡ The spongy bone density of the un-loaded side is lower. This difference is greatest ventral ($p=0.001$) (Fig.6a-c).
- Ⓡ Increased growth correlates to decreased spongy bone density.
- $q_v = \text{C.m. Ý} / \text{C.m. ß} = 0.85$ ($p=0,0014$)
- $\text{RTAB} = q_g \times q_v = 1.33$
- Ⓡ The total amount of bone added to the unloaded condyle is 1.33 times higher than on the loaded side. Thus, the effect of increased growth exceeds the effect of decreased trabecular bone volume.

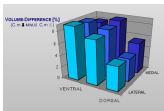


Fig. 6a: Difference of the trabecular bone volume. C.m. minus C.m.




Fig. 6b,c: Microradiography, central sagittal section of the unloaded condyle (a, C.m.) and loaded Condyle (b, C.m.). Mandibular fossa (M.F.). C.m. shows a lower trabecular bone volume. (lines: 5mm)

LIGHTMICROSCOPIC EXAMINATION

- C.m.Ý with a higher thickness of the cartilage layer than C.m.ß (Fig. 7a,b)
- Defects of the condylar cartilage and subchondral bone (higher Frequency in C.m.ß), substitution by fibrous tissue, limited regeneration (Fig. 7c,d)

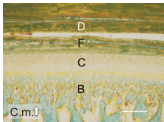


Fig. 7a,b: Central sagittal sections, Goldner stained, unloaded (a, C.m.Ý) and loaded Condyle (b, C.m.ß). Bone (B), cartilage (C), fibrous tissue layer (F), discus (D), (lines: 50 μm)

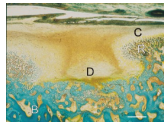



Fig. 7c: Central sagittal section, Goldner stained, bone (B), defect (D), regeneration (R), cartilage (C), (line: 100 μm)




Fig. 7d: Central sagittal section, microradiography, defekt (D), mandibular condyle (C.m.), mandibular fossa (M.F.), (line: 5mm)

Discussion and Conclusions

- The adaptive mechanisms of the growing man-dibular condyle are not sufficient.
- The reestablishment of the occlusion by the advancing second dentition can lead to a stabilization of the articular imbalance.
- Non-physiological loss of occlusal support in juveniles may justify a temporary application of a splint.

Literature

1. NEUNER, O.: Klassifizierung und Symptomatik der Überlastungsathropatien des Kiefergelenkes. *Schweiz Monatsschr Zahnmed* 1972, 82, 601 - 21
2. STUTZMANN, J. UND PETROVIC, A.: Tierexperimentelle Untersuchungen über Zusammenhänge zwischen Zunge, Musculus pterygoideus lateralis, mandibulärem Kondylenknorpel und Gaumennaht. *Fortschr Kieferorthop* 1975, 36, 354-73
3. KNAK, G., JÜLICH, R., VIERUS, H.: Der Einfluß von experimentell erzeugten Alterationen der Okklusion auf die Morphologie des Kiefergelenkes der Ratte. *Dtsch Stomatol* 1973, 23, 422 - 8

Poster Faksimile:

TAFEL
8

Unilateral Loss of Occlusal Support during Deciduous Dentition and its Consequences to the Growing Mandibular Condyle

Springer, I. N. G., Fleiner, B.

Clinic for Oral- and Maxillofacial Surgery,
 Christian Albrecht University of Kiel, Germany (Head: Prof. Dr. Dr. F. Härle)

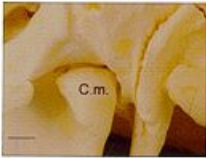


Fig. 1. Condyle of mandible (C.m.), dorsal view, pig, 8 month, (line: 1cm)

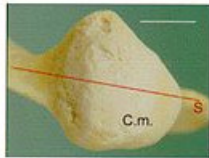


Fig. 2. Condyle of mandible (C.m.), cranial view, section-line (S), (line: 1cm)

INTRODUCTION

- Loss of supporting zones may lead to altered functional load of the condylar process of the mandible¹ (C.m.)
- Alterations of the functional load may lead to changes of the shape and the structure of the growing C.m.^{2,3}
- The changes of the growth and structure of the growing C.m. are examined three-dimensionally.

LITERATURE

1. NEUBER, G.: Klassifizierung und Symptomatik der Überlastungsaffektion des Kiefergelenkes. *Schweiz. Monatsschr. Zahnmed.* (1972) 82, 601 - 27
2. STUTTMANN, J. und PETROVIC, A.: Tierexperimentelle Untersuchungen über Zusammenhänge zwischen Zunge, Musculus pterygoideus lateralis, mandibulärem Kndylusknorpel und Gaumensegel. *Fortschr. Kieferorthop.* (1975) 36, 354-73
3. KNAX, G., JÜLICH, R., VIEHLE, H.: Der Einfluss von experimentell erzeugten Alterationen der Okklusion auf die Morphologie des Kiefergelenkes der Ratte. *Zsch. Stomatol.* (1973) 23, 422-5

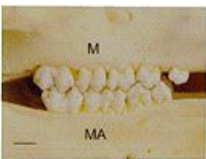

Fig. 3. Occlusal support, maxilla (M), mandible (MA), (line: 1cm)

MATERIAL UND METHODS

- The first molars of 8 eight-month-old micropigs are removed unilateral (Fig.3), experimental term: 4 months → Ipsilateral: loaded condyle, here named C.m. ↓
 Contralateral: unloaded condyle, here C.m. ↑
 Preparation: undecalcified serial sagittal sections (Fig.2), microradiography, fluorescence microscopy (intravital polychrome sequence labeling), lightmicroscopy (Goldner)
- Vertical growth: measurement of the distance between the fluorescent band and articular surface (Fig.4) → Ratio of the vertical growth of the unloaded condyle

- over the loaded condyle: Quotient $q_1 = \frac{C.m. \uparrow}{C.m. \downarrow}$
- Articular surface curve C: the vertical growth during the experimental period is part of a virtual radius $r: C = 1 / r$
- Trabecular bone volume in relation to non-mineralized medullar space in %: it is calculated by planimetry to acquire a measure for the spongy bone density → Ratio of the trabecular bone volume of the unloaded over the loaded side: Quotient $q_2 = \frac{C.m. \uparrow}{C.m. \downarrow}$
- Ratio of the total amount of bone produced by the unloaded condyle over the loaded condyle: $RTAB = q_1 \times q_2$




Fig. 4. Undecalcified sagittal section, fluorescence microscopy, condyle (C.M.), mandibular fossa (M.F.), fluorescent band (F), measurement of vertical growth. Ventral, pteremodary, Dorsal, (line: 5mm)

RESULTS

VERTICAL GROWTH AND ARTICULAR SURFACE CURVE

- $q_1 = \frac{C.m. \uparrow}{C.m. \downarrow} = 1.56$ ($p=0.0029$) (Difference $C.m. \uparrow$ minus $C.m. \downarrow$ circa 10.5 μm per day, Fig.5a)
- The average vertical growth of the unloaded side is about 1.56 times higher compared to the loaded side
- The average articular surface curve is less on the unloaded

- side than on the loaded side according to $C = 1 / r$.
- q_1 increases from dorsomedial with 1.33 to ventrolateral with 2.38 in line with axis a ($p=0.0311$) (Fig.5b) → An additional ventrolateral flattening of the over all less curved unloaded condyle is found

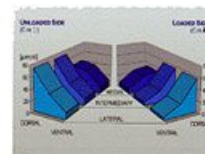


Fig. 5a. Condylar growth of C.m. ↑ and C.m. ↓ per day [μm]

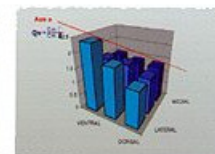


Fig. 5b. Ratio of the vertical growth $q_1 = \frac{C.m. \uparrow}{C.m. \downarrow}$

TRABECULAR BONE VOLUME

- $C.m. \downarrow$: 48.65 vol%, $C.m. \uparrow$: 41.27 vol%, difference = 7.38 vol% ($p=0.0018$)
- The spongy bone density of the unloaded side is lower. This difference is greatest ventral ($p=0.001$) (Fig.6a-c)
- Increased growth correlates to decreased spongy bone density.

- $q_2 = \frac{C.m. \uparrow}{C.m. \downarrow} = 0.85$ ($p=0.0014$)
- $RTAB = q_1 \times q_2 = 1.33$
- The total amount of bone added to the unloaded condyle is 1.33 times higher than on the loaded side. Thus, the effect of increased growth exceeds the effect of decreased trabecular bone volume.

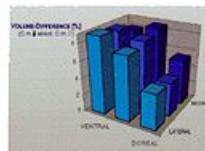


Fig. 6a. Difference of the trabecular bone volume: $C.m. \downarrow$ minus $C.m. \uparrow$

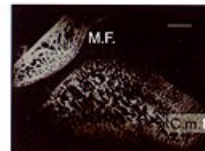
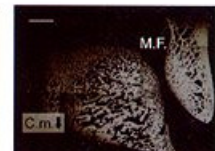


Fig. 6b,c. Microradiography, central sagittal section of the unloaded condyle (a, C.m. ↑) and loaded Condyle (b, C.m. ↓). Mandibular



fossa (M.F.). C.m. ↑ shows a lower trabecular bone volume. (lines: 5mm)

LIGHTMICROSCOPIC EXAMINATION

- $C.m. \uparrow$ with a higher thickness of the cartilage layer than $C.m. \downarrow$ (Fig. 7a,b)
- Defects of the condylar cartilage and

- subchondral bone (higher Frequency in $C.m. \downarrow$), substitution by fibrous tissue, limited regeneration (Fig. 7c,d)

DISCUSSION

- The adaptive mechanisms of the growing mandibular condyle are not sufficient.
- The reestablishment of the occlusion by the advancing second dentition can lead to a stabilization of the articular imbalance
- Non-physiological loss of occlusal support in juveniles may justify a temporary application of a splint.

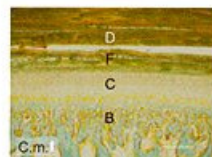


Fig. 7a,b. Central sagittal sections, Goldner stained, unloaded (a, C.m. ↑) and loaded Condyle (b, C.m. ↓). Bone (B), cartilage (C).

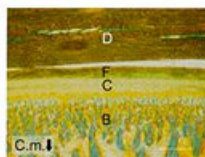


Fig. 7c,d. Central sagittal section, Goldner stained, bone (B), defect (D), regeneration (R), cartilage (C), (line: 50 μm)

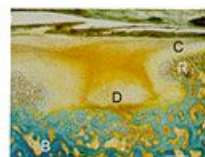


Fig. 7e. Central sagittal section, Goldner stained, bone (B), defect (D), regeneration (R), cartilage (C), (line: 100 μm)

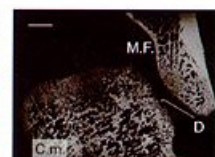


Fig. 7d. Central sagittal section, microradiography, defect (D), mandibular condyle (C.m.), mandibular fossa (M.F.), (line: 5mm)