

RÓJ R.¹, MORAWIEC T.², KOWNACKI P.², WRZOŁ M.², ROSAK P.¹, WIATRAK K.², BOGACZ M.², KASPERSKI J.¹

1- Department of Prosthetic Dentistry, Chair of Prosthetics and Dental Materials, School of Medicine with the Division of Dentistry in Zabrze, Medical University of Silesia in Katowice, Plac Akademicki 17, 41-902 Bytom, Poland

2- Department of Oral Surgery, Chair of Cranio-Maxillo-Facial and Oral Surgery, School of Medicine with the Division of Dentistry in Zabrze, Medical University of Silesia in Katowice, Plac Akademicki 17, 41-902 Bytom, Poland

Introduction: Bilateral and Unilateral edentulous areas located posterior to the remaining natural teeth occurs in patients with reduced dental arch leads to the adoption of increased occlusal forces in the front of arch leading to pathological tooth wear. This condition is referred to as posterior bite collapse. As a consequence there is a reduction of vertical and horizontal height of occlusion and posterior change in the position of joint head of the temporomandibular joint. Restoration of unilateral and bilateral missing teeth using implants reconstruct of the continuity of the dental arches, but should also pay attention to the severity of dysfunction changes in a motor masticatory system.

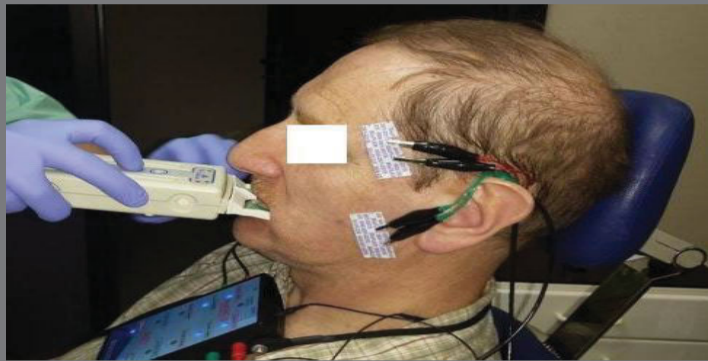


Fig. 1

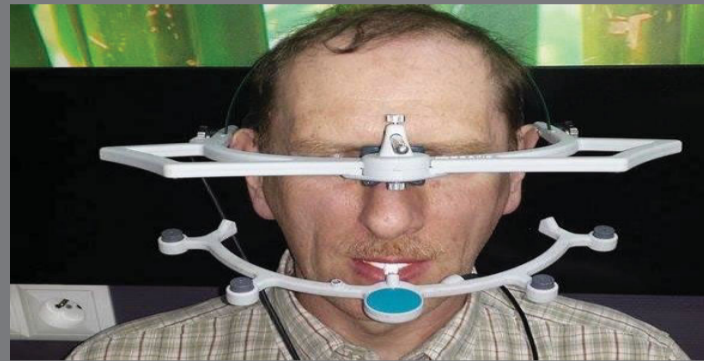

Fig. 2

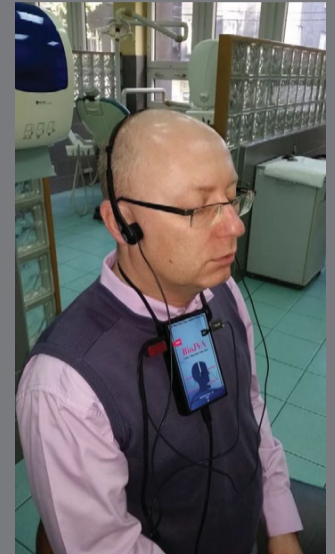


Fig. 3

The aim of the study was to evaluate the temporal muscle and masseter tension, axiography analysis, vibroacoustic analysis and dynamic analysis of occlusion in patients with bilateral and unilateral edentulous areas located posterior to the remaining natural teeth in patients with dental implant treatment.

Material and Methods: A total of 5 people aged 47 to 74 years (2 men and 3 women). The study was conducted at the Specialist Dental Clinic (Katowice, Poland). For the evaluation of degree TMJ dysfunction was used the Helkimo index. The patient survey was conducted using electromyographic BioEMG III (Bioresearch, Milwaukee, USA), which included 2 pairs of muscles: the front part of the temporal and masseter muscles in order to monitor potential changes (Fig.1). At the same time carried out an analysis of registration of vibration in the temporomandibular joint on the right and left using BioJVA (Bioresearch, Milwaukee, USA) (Fig.2). Headphones with an accelerometer placed directly in the area of both joints and was connected to an amplifier vibration. Electronic analysis also uses ultrasonic diagnostic system JMA (Zebris Medical GmbH, Isny im Allgäu, Germany) (Fig.3). Patients masticatory function were analyzed in the individual conditions of static and dynamic occlusion in new restorations, as well as the free movement of the jaw.

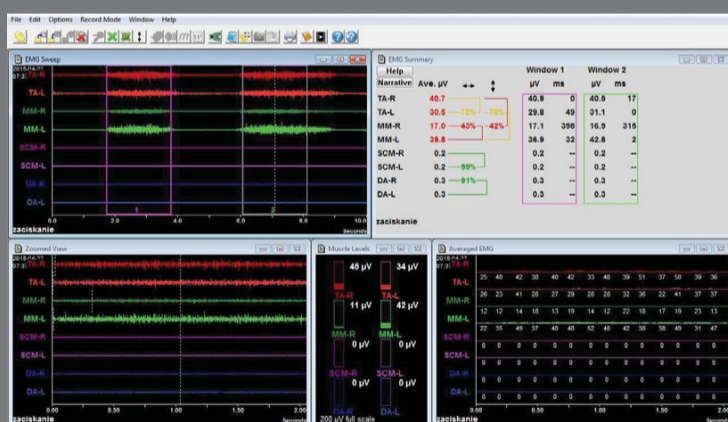


Fig. 4

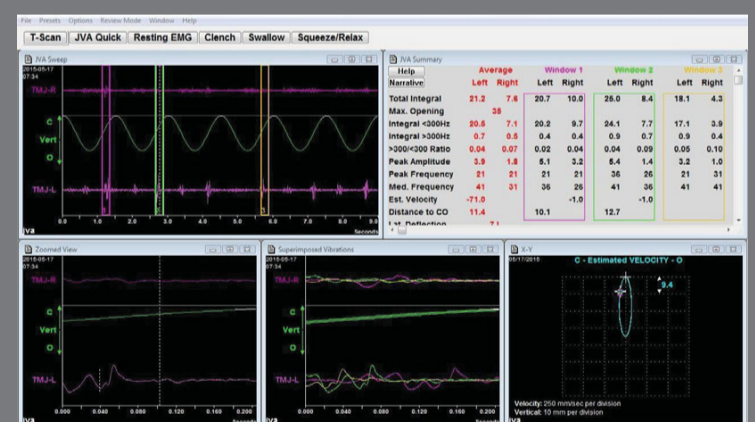


Fig. 5

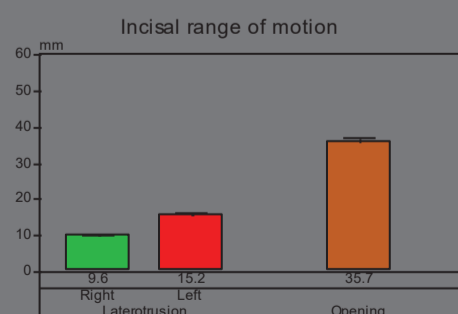


Fig. 6a

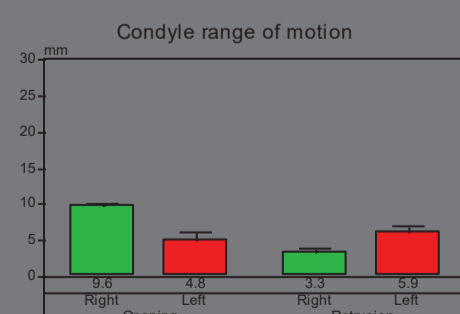


Fig. 6b

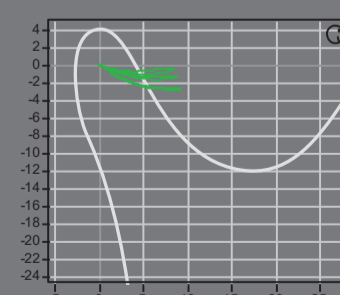


Fig. 6c

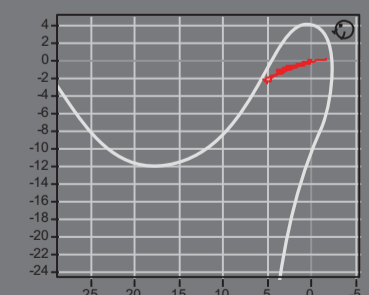


Fig. 6d

Conclusions: The parameters like length of the condylar path (Fig. 6a, Fig. 6b, Fig. 6c, Fig. 6d) muscle tension (Fig. 4), clicking intensity (Fig.5) may be a significant value characterising the degree of intensification of the TMD patients with posterior bite collapse.