

# Dental Implants after Horizontal Bone Augmentation using a Titanium Membrane in the Maxilla: A Case Report



**BUDUNELİ N\***, **GÜMÜŞ P.** *Ege University, School of Dentistry, Department of Periodontology, İzmir, Turkey;*

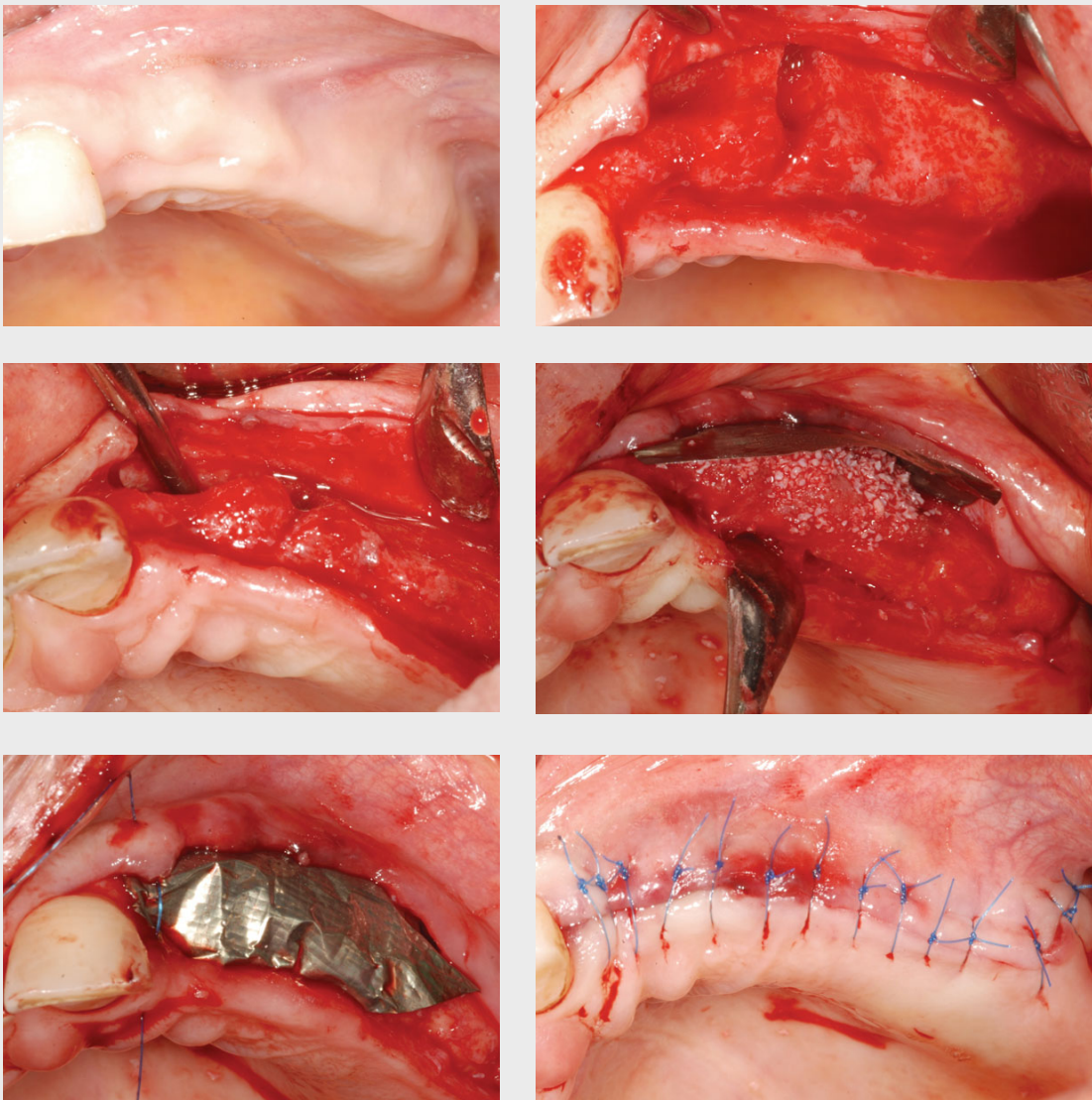
**ÇÖMLEKOĞLU ME.** *Ege University, School of Dentistry, Department of Prosthodontics, İzmir, Turkey.*



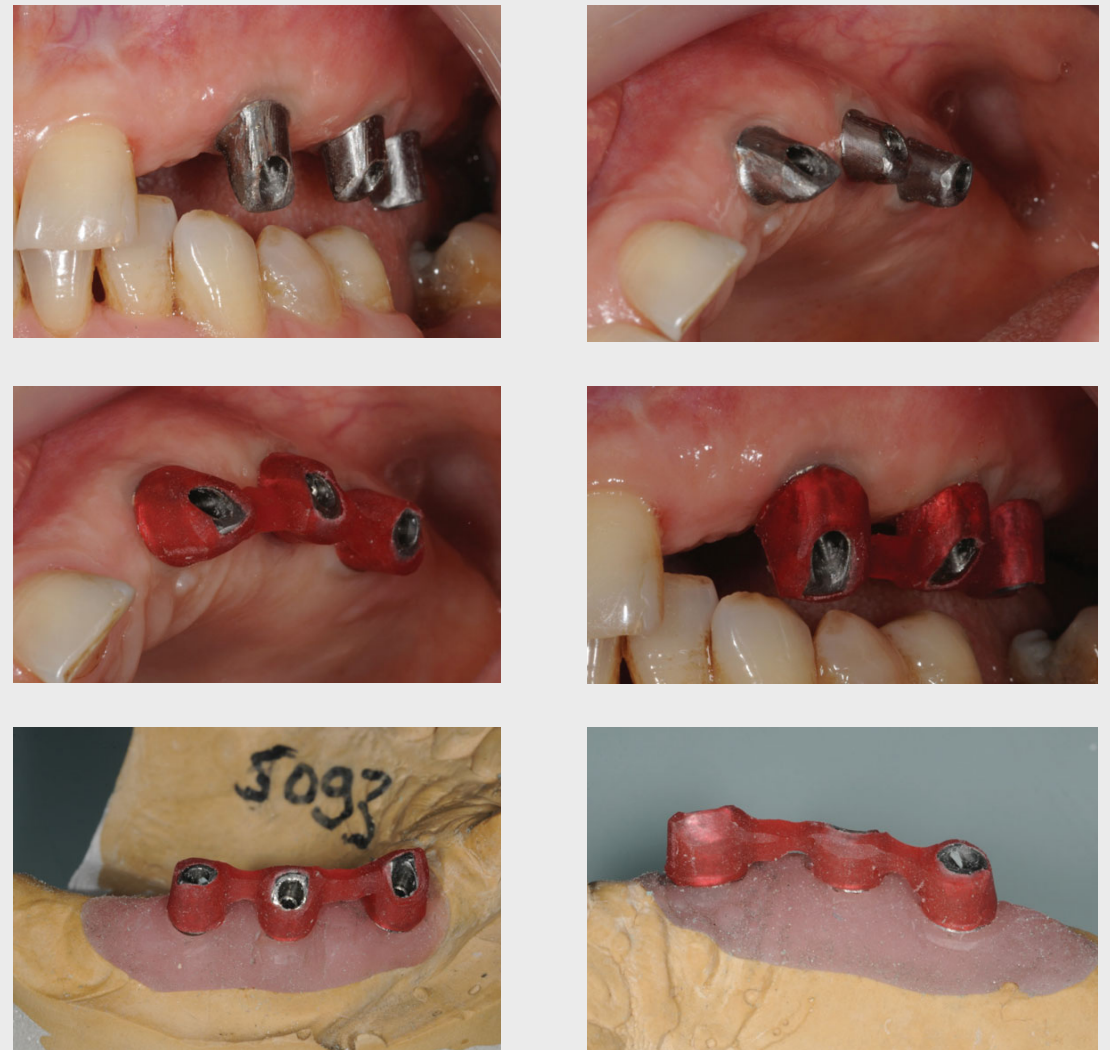\* Ege University, School of Dentistry, Dept. of Periodontology, Bornova-35100, İzmir, Turkey. Phone:+90 232 3114556 [nurcan.buduneli@ege.edu.tr](mailto:nurcan.buduneli@ege.edu.tr)

**Background:** Reliable implant-supported rehabilitation of an edentulous alveolar ridge needs sufficient volume of bone. In order to achieve a prosthetic-driven positioning, bone graft techniques may be required. **Aim:** To demonstrate the success of Conelog dental implants in the horizontally augmented maxillary arch.

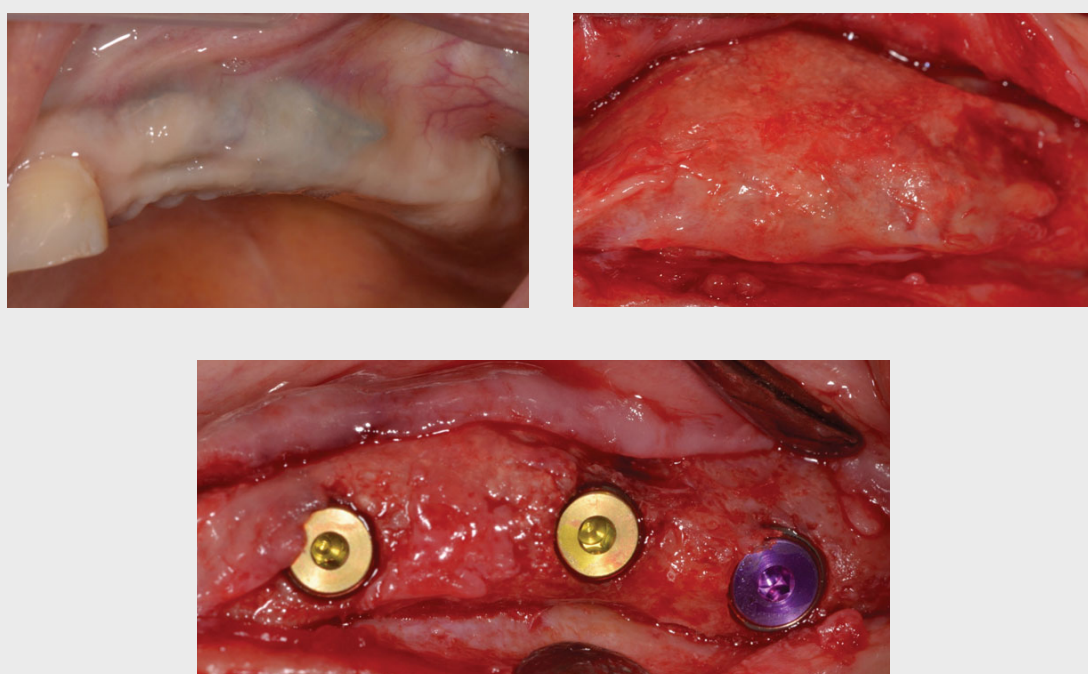
## Case



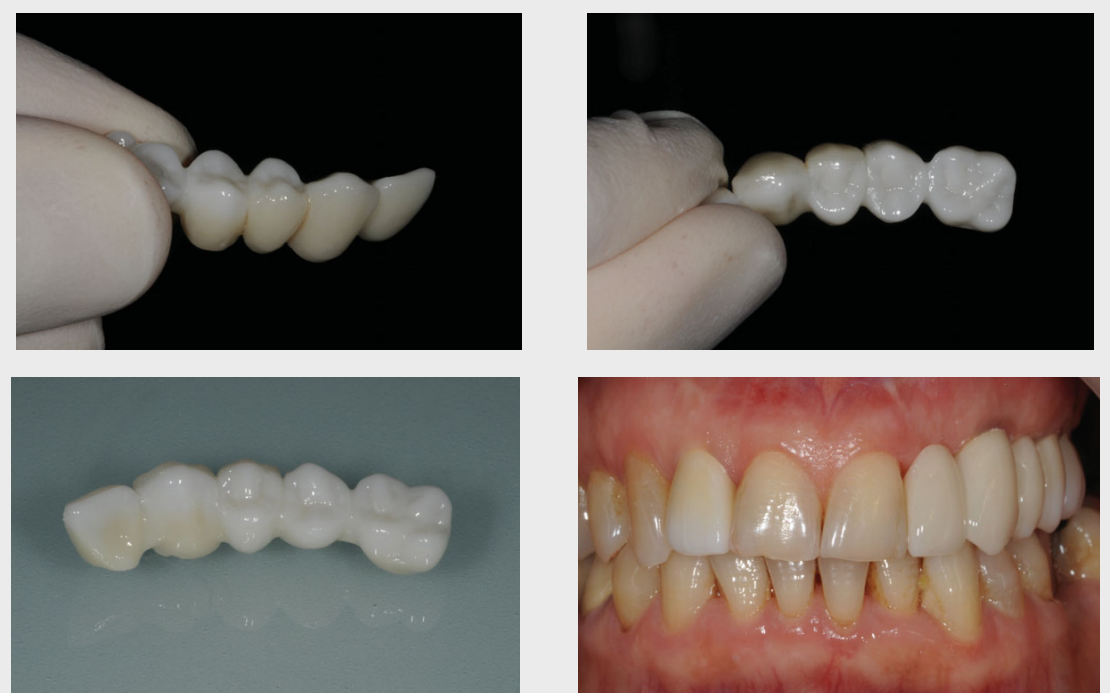A 64-year-old female patient with missing left lateral, canine, premolars and molars, had an atrophic ridge on the maxillary left edentulous side. This atrophic ridge was augmented with a xenogeneic bone graft (Bio-Oss, Geistlich Pharma) and titanium membrane (Frios BoneShields, Dentsply) fixed with pins (Frios, Dentsply).



Adequately selected prefabricated titanium abutments were milled in the laboratory in appropriate insertion angles through gingival replica guidance for optimal soft tissue contour, also for aesthetic concerns. For passive fit of the fixed dental prosthesis (FDP), the restoration was first made by a pattern resin (GC, Japan) in the laboratory and further checked intraorally before definitive fabrication of the restoration.



After 6 months, three dental implants (Conelog; 3.8x11mm, 3.8x11mm and 4.3x11mm, respectively) were placed in an optimal three-dimensional position in the canine, second premolar and second molar regions into the newly formed bone.



After ensuring the passive fit of the FDP, a lateral anterior cantilever designed monolithic zirconia FDP was fabricated, tried-in and glazed after final occlusal adjustments. The definitive restoration was luted with a resin cement (Premier, USA).

**Conclusion:** The patient was followed for 2 years and exhibited uneventful progress about the bone levels and periodontal health. This case report suggests that bone level dental implants allow proper primary stability followed by augmentation procedures performed using xenogeneic bone graft and titanium membrane in the reconstruction of the atrophic maxilla.