

# Prosthetic soft tissue conditioning in single implant restorations - Clinical Case Report -

FERNANDES, L\*; CARVALHO, L\*\*; DOMINGOS, J\*\*

\* Oral Surgery and Prosthodontic Department, **MALOCLINIC ALMADA**  
\*\* Prosthodontic Department, **MALOCLINIC ALMADA**

## INTRODUCTION

The most common complication of losing teeth is alveolar bone reabsorption and apical migration of soft tissue, challenging aesthetics and harmony, especially in the anterior sector<sup>1</sup>, which sets boundaries in single implant restorations. This kind of treatment consists in a series of stages that include implant site development, implant surgery, provisionalization and definitive restoration fabrication/maintenance<sup>2-3</sup>. Surgery must be planned within some boundaries. Implant must be placed 2 to 4mm apically of the expected gingival margin position, 2mm of facial bone is recommended and implant should be positioned slightly palatal to the incisal edge and should be 2mm away from adjacent teeth and 3mm away from other implants<sup>4</sup>. Soft tissue conditioning assumes a major role in obtaining the correct papillae growth as well as a harmonious gingival contour. It's through the modification and modulation of the provisional restoration that we will optimize the aesthetics and function of the restoration of the missing elements<sup>3,5</sup>. In order to achieve a correct soft tissue conditioning, it should be used a provisional crown, to be modified in increments as to condition a natural and well integrated emergence profile. This is done by filling and maximizing the soft tissue volume<sup>4</sup>. When the conditioned soft tissue is stable and supported, casts are made using specific techniques in order to alter the impression abutment as to achieve a acrylic resin accurate transfer of peri-implant soft tissue emergence profile. This is done so the lab can accurately reproduce the correct anatomy and gingival contour<sup>1,5</sup>. The goal of this clinical case report was to evaluate factors and technics used on the optimal treatment and conditioning of peri-implant soft tissues that allow us to achieve a harmonious and aesthetic restoration.

## CLINICAL CASE DESCRIPTION

Caucasian patient, male and 70 years, attended the appointment showing absence of the tooth 11, his main complaint was the type of this rehabilitation (removable acrylic prosthesis 1 element). The main goal would be to give back the aesthetic and functional role. (Fig 1, 2 e 3)

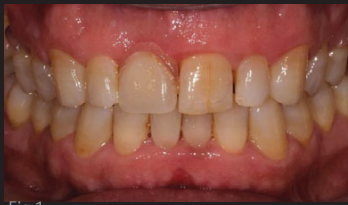

Fig 1

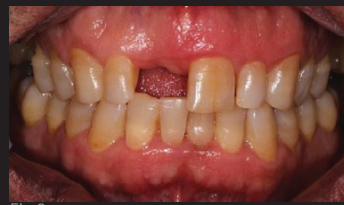

Fig 2

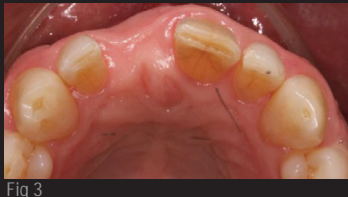

Fig 3

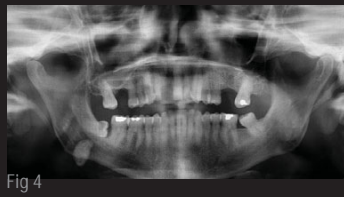

Fig 4

After clinical and imagiological examination (Fig 4), it was found that, although limited bone thickness availability, conditions were sufficient for implant placement and immediate loading.

## SURGICAL PROCEDURE

Infiltrative anesthesia with Articaine 72mg / 1,8ml and adrenaline 0,009mg / 1,8ml (Artinibsa, Inibsa, Barcelona, Spain); Supracrestal incision extending from the mesial papilla tooth 21 to the mesial papilla tooth 12, without using discharge; Detachment of the flap muco-periosteal, starting at the level of the papilla and extending all along the incision. (Fig 5 and 6)

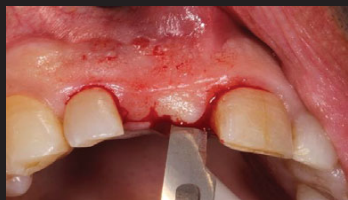

Fig 5

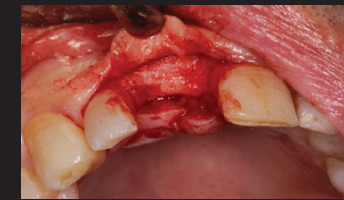

Fig 6

Implant placement Nobel Speedy Groovy 4x15mm (Nobel Biocare AB Sweden) in the region of the tooth 11, respecting the biological principles in order to optimize the final result. (Fig 7, 8 e 9)

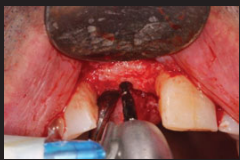

Fig 7

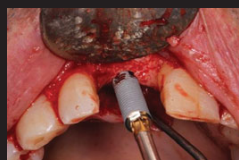

Fig 8

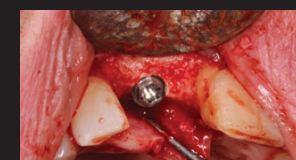


Fig 9

Straight Abutment 2mm placement with a torque of 25N (Multi-unit Abutment, Nobel Biocare AB Sweden). (Fig 10, 11 e 12)

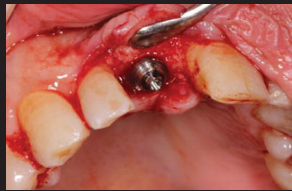

Fig 10

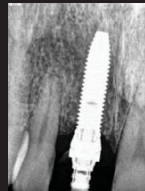

Fig 11

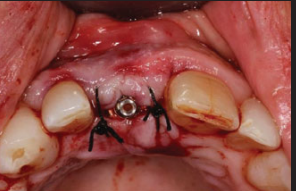

Fig 12

## PROSTHETIC PROCEDURE

Adaptation and placement of immediate provisional crown. (Fig 13)

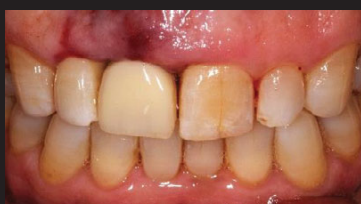

Fig 13

After 6 months, the straight abutment (multi-unit abutment 2mm) was removed and proceeded to changes in the temporary crown with a new anti-rotational abutment, placed directly to the head of the implant. (Fig 14 e 15)

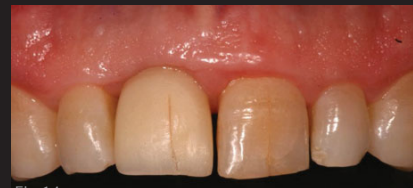

Fig 14

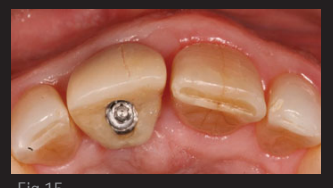

Fig 15

The temporary crown has been progressively modified to improve the three-dimensional shape of the soft tissue to obtain the desired result. (Fig 16 e 17)

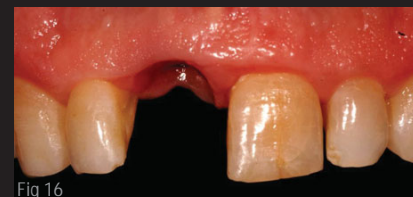

Fig 16

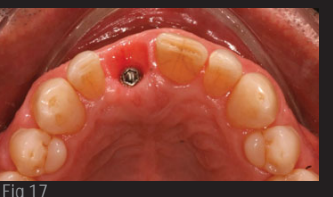


Fig 17

Final impression was made according to the open tray technique with individualization of the impression abutment with acrylic auto-polymerizable resin (Pattern Resin LS; GC America, Inc. Alsic), silicone putty consistency (Flexitime Easy Putty Heraeus Kulzer GmbH, Hanau, Germany) and light body consistency (Heraeus Kulzer flexitime Correct Flow GmbH, Hanau, Germany).

Photographic intraoral record and panoramic rx at final stage. (Fig 18,19, 20, 21 e 22)

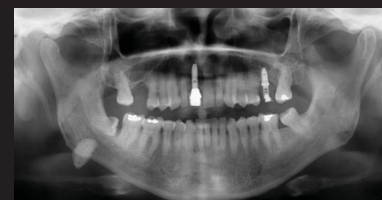


Fig 18

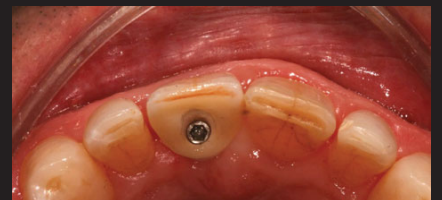

Fig 19

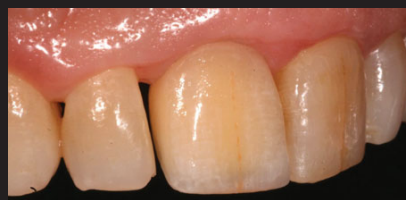

Fig 20

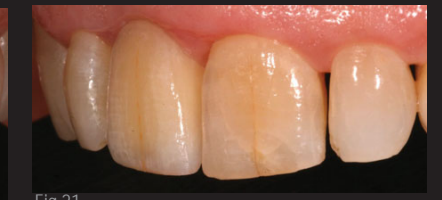

Fig 21

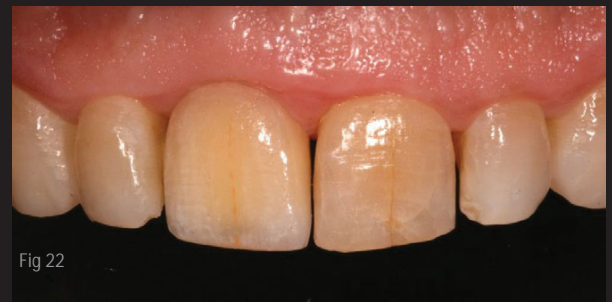

Fig 22

## CONCLUSIONS AND CLINICAL IMPLICATIONS

Soft tissue morphology and gingival contour can be improved through conditioning promoted by a provisional crown customization. Material, surgical technique, tridimensional implant location, gingival biotype, bone quantity and quality, adjacent teeth support and post-surgical care are limiting factors concerning the final outcome. Nonetheless, there are also socio-psychological factors that influence the adequate aesthetics, such as parafunctional habits, post-surgical care motivation, oral hygiene techniques and maintenance appointments.

## Bibliografy

1. Indirect implant-supported fixed provisional restoration in the esthetic zone: fabrication technique and treatment workflow. Shor A, Schuler R, Goto Y. J Esthet Restor Dent. 2008;20(2):82-95. discussion 96-7. doi: 10.1111/j.1708-8240.2008.00156.x. 2. Factors that influence the position of the peri-implant soft tissues: a review. Sorni-Broker M, Peñarrocha-Diago M, Peñarrocha-Diago M. Med Oral Patol Oral Cir Bucal. 2009 Sep 1;14(9):e475-9. 3. [https://doi.org/10.1016/j.cpr.2010.08.004](#). 4. Considerations of implant abutment and crown contour: critical contour and subcritical contour. Su H, Gonzalez-Martin O, Weisfeld A, Lee E. Int J Periodontics Restorative Dent. 2010 Aug;30(4):335-43. 5. Accurate transfer of peri-implant soft tissue emergence profile from the provisional crown to the final prosthesis using an emergence profile cast. Elian N, Taboutian C, Jalbout ZN, Cassi A, Cho SC, Fromm S, Tarrow DP. J Esthet Restor Dent. 2007;19(6):306-14. discussion 315. 6. Procedure for obtaining proper contour of an implant-supported crown: a clinical report. Tarlow JL. J Prosthet Dent. 2002 Apr;87(4):416-8. 7. A simplified method to develop optimal gingival contours for the single implant-supported, metal-ceramic crown in the aesthetic zone. Kinsel RP, Capoferri D. Pract Proced Aesthet Dent. 2008 May;20(4):231-6. quiz 237. 8. Restoring implants in the esthetic zone after sculpting and capturing the perimplant tissues in rest position: a clinical report. Spyropoulou PE, Razzoog M, Sierraalta M. J Prosthet Dent. 2009 Dec;102(6):345-7. doi: 10.1016/S0022-3913(09)60189-X. 9. Immediate single-tooth implants in the anterior maxilla: 3-year results of a case series on hard and soft tissue response and aesthetics. Cosyn J, Eghball A, De Bruyn H, Collys K, Cleymaet R, De Rouck T. J Clin Periodontol. 2011 Aug;38(8):746-53. doi: 10.1111/j.1600-051X.2011.01748.x. 10. Soft tissue preservation and pink aesthetics around single immediate implant restorations: a 1-year prospective study. Cosyn J, De Bruyn H, Cleymaet R. Clin Implant Dent Relat Res. 2013 Dec;15(6):847-57. doi: 10.1111/j.1708-8208.2012.00448.x. 11. An alternative technique for the accurate transfer of perimplant soft tissue contour. Man Y, Qu Y, Dam HG, Gong P. J Prosthet Dent. 2013 Feb;109(2):135-7. doi: 10.1016/S0022-3913(13)60031-1. 12. Preoperative gingival conditioning as a guide for implant installation and to achieve proper dentogingival contours. de Jesus Tavares RR, Malheiros AS, Benatti BB, Tonetto MR, Bandeca MC. J Contemp Dent Pract. 2013 May;14(3):560-6. 13. The use of CAD/CAM technology to fabricate a custom ceramic implant abutment: a clinical report. Bertolini Mde M, Kempen J, Lourenco EJ, Telles Dde M. J Prosthet Dent. 2014 May;111(5):362-6. doi: 10.1016/j.prosdent.2013.08.016. 14. Interdental Implant Papillae Growth up with Temporary Abutment displaced at Monthly Intervals. Al-Jubouri MU. J Contemp Dent Pract. 2015 May;16(5):422-6.