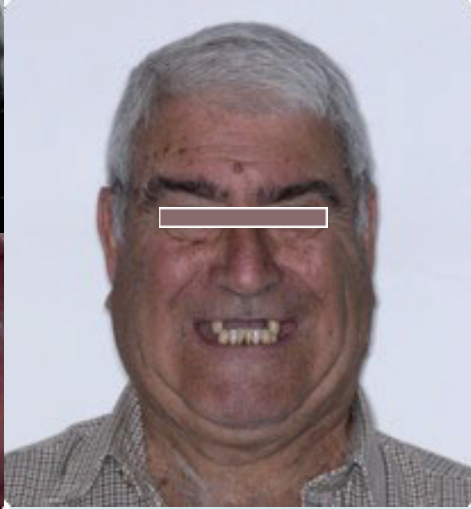
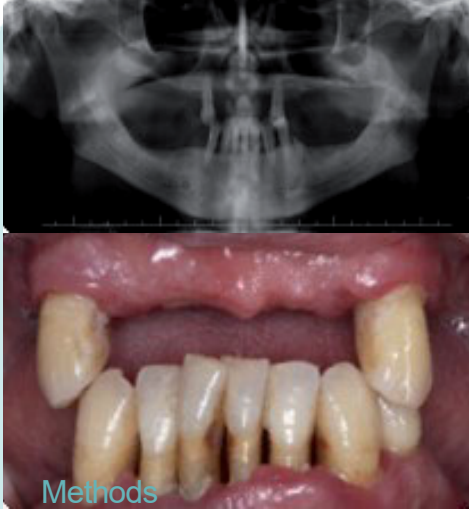
Integration of DICOM and STL files for oral rehabilitation with implant guided surgery.



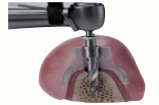Antonio Meaños Somoza, Irene C. García Martínez, Carlos Carrascosa Milo, Ignacio Sanz Sánchez, Guillermo Pradés Ramiro

Master of Restorative Dentistry based on New Technologies of Complutense University (Madrid)



Introduction

Guided surgery optimises the accuracy of implant placement in a more safe, predictable and efficient situation by using a **flapless** surgery technique.



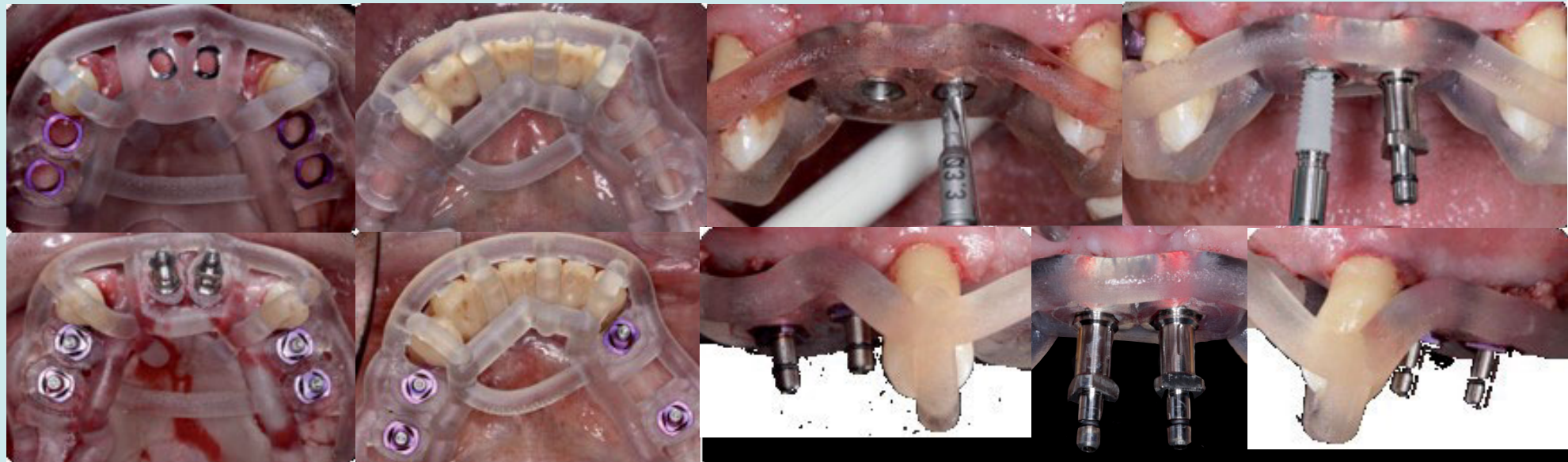
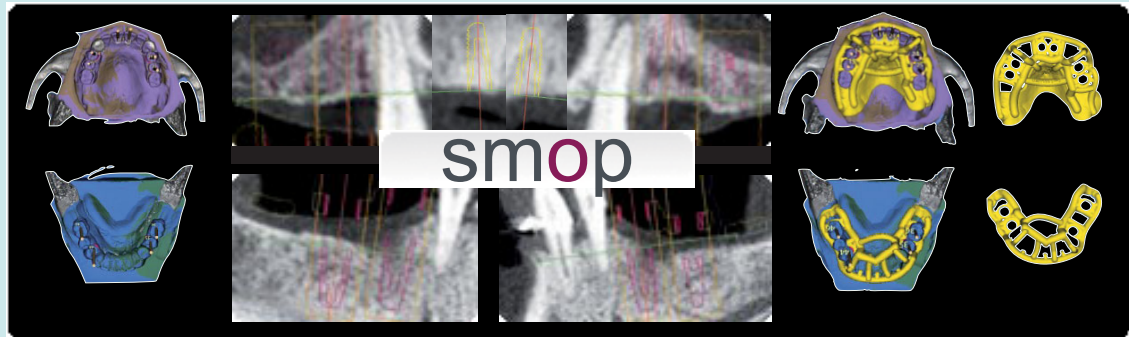Aim

To present a multidisciplinary case report in a partially edentulous patient using a digital workflow, which included the **computer assisted implant planning** and the implant placement with **static guided surgery**.

Methods

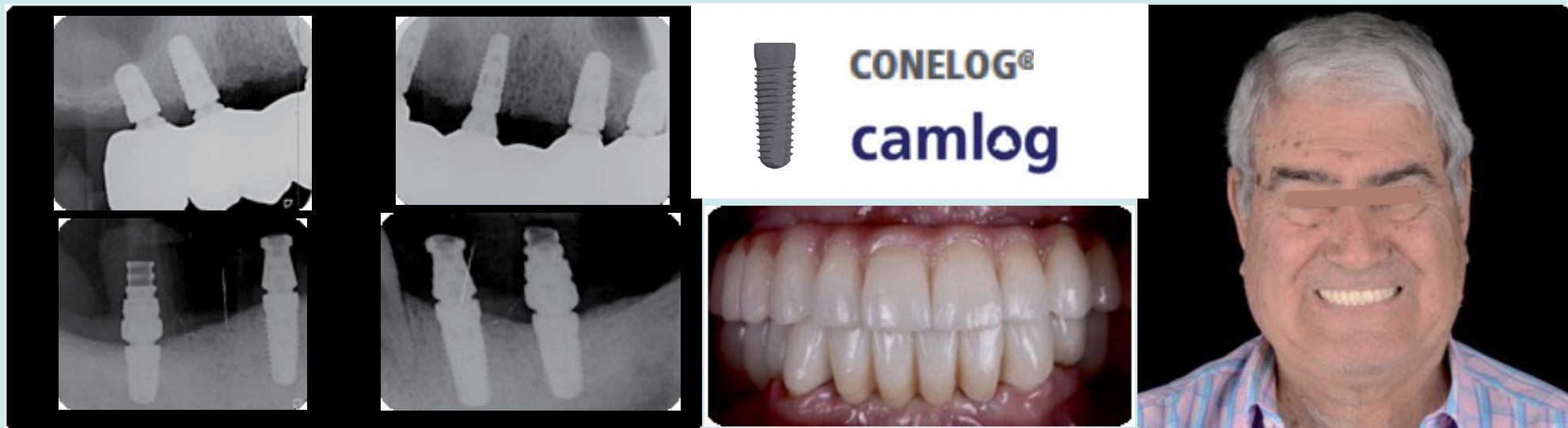Digital planning

- DICOM files from the CBCT were aligned and matched with the STL files obtained from the intraoral situation and from the diagnostic wax-up using SMOP Implant Planning System (Smop, Swissmeda, Zurich, Switzerland).
- The template was designed using the same software and printed.



Implant placement

- We planned the placement of ten Conelog implants (Camlog, Biotechnologies AG, Switzerland) in positions: 1.5. , 1.4. , 1.1. , 2.1. , 2.4. , 2.5. , 3.5. , 3.6. , 4.4. and 4.6 was planned according to the protocol for guided surgery.



Results

Implants were placed satisfactory based on the computer assisted planning. Function and aesthetics were reestablished as desired by the patient.

Computer assisted implant planning and guided surgery may offer **clinical advantages** in terms of **patient morbidity**, **time**, optimization of **available bone** and **accuracy** regarding implant position.

Conclusions



Bibliography